

Left-sided thoracoscopy in the prone position for surgery of distal esophageal benign pathologies

SAGE Open Medical Case Reports
2: 2050313X14521393
© The Author(s) 2014
Reprints and permissions:
sagepub.co.uk/journalsPermissions.nav
DOI: 10.1177/2050313X14521393
sco.sagepub.com



Adamu Issaka, Hasan Volkan Kara, Barkin Eldem, and Hasan F Batirel

Abstract

Exposure of the distal esophagus can be achieved by a wide variety of surgical approaches. The standard procedure is mostly by laparoscopy. In cases where laparoscopy is relatively contraindicated, thoracoscopy is preferred. In this case, exposure of the distal esophagus from the aorta, heart and lung is technically challenging using thoracoscopy in the right lateral decubitus position. Surgery in the prone position for esophageal cancer has been successfully described in previous literature. We present our experience with left-sided thoracoscopy in the prone position in three patients with benign distal esophageal pathologies. This approach provided a much better exposure of the distal esophagus and enabled a successful surgery to be done in all patients with less manipulation of the lung.

Keywords

Thoracoscopy, prone position, esophagus, benign pathologies

Introduction

Exposure of the distal esophagus can be achieved by a variety of surgical approaches. In this era of advanced minimally invasive surgery, laparoscopy has become the standard approach for distal pathologies of the esophagus. Some surgeons still prefer a left thoracoscopy approach for esophageal pathologies such as achalasia and epiphrenic diverticula.^{1,2} Exposure of the distal thoracic esophagus is technically challenging with thoracoscopy approach in the right lateral decubitus position. We present our experience with the left thoracoscopic approach in the prone position in three patients with distal esophageal benign pathologies.

Patients

The first patient was a 72-year-old female with symptoms of dysphagia, chest pain and weight loss. She was diagnosed with vigorous achalasia in the distal esophagus with previous history of subtotal gastrectomy.

The second patient was a 65-year-old male chronic obstructive pulmonary disease (COPD) patient with symptom of dysphagia. His complaints increased in the last 6 months resulting in weight loss. He was diagnosed with distal esophageal diverticula and achalasia (Figure 1).

The third patient was a 65-year-old female with dysphagia and weight loss. She was diagnosed with achalasia and previous history of unsuccessful balloon dilatation on two

occasions and laparotomy for intestinal obstruction and cholecystectomy.

Surgical technique and outcome

Informed consent was obtained from all patients preoperatively. All patients were intubated with a double-lumen tube and rigid esophagoscopy performed to aspirate undigested food particles initially in the supine position. Nasogastric tube was inserted and the patients were positioned in the prone position with two silicone semi-cylindrical pads placed vertically under the chest and a pillow under the knee. The left side of the patients was placed to the edge of the operating table and both arms semi-flexed over the head. The face of the patients lay on foamed pads that are specially designed to accommodate the face and eyes. The whole chest and back were prepped. A 2-cm camera port incision on the sixth intercostal space (ICS) 2 cm posterior to the posterior axillary

Marmara University Faculty of Medicine, Department of Thoracic Surgery, The Ministry of Health of Turkey – Marmara University Hospital, Istanbul, Turkey

Corresponding Author:

Hasan F Batirel, Marmara University Faculty of Medicine, Department of Thoracic Surgery, The Ministry of Health of Turkey – Marmara University Hospital, 7th Floor, Fevzi Cakmak Mah., Mimar Sinan Cad., No: 41, Ust Kaynarca, Pendik, Istanbul 34899, Turkey.
Email: hbatirel@marmara.edu.tr

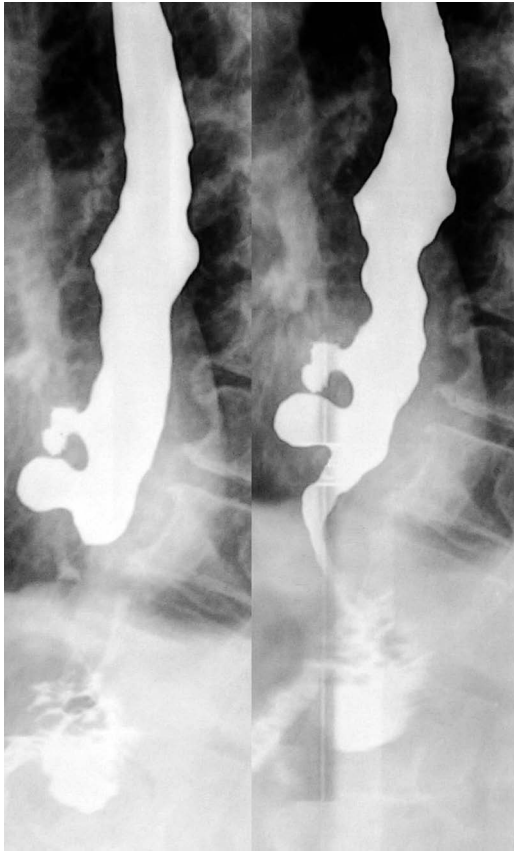

Figure 1. Two small diverticula in the distal esophagus and a tight gastroesophageal junction on barium swallow.

line was done. Two other incisions (1 cm each) were placed behind the tip of the scapula in the fourth ICS and paravertebrally in the eighth ICS. An extra 1-cm incision in the seventh ICS posterior axillary line was necessary in the second and third patients for traction (Figure 2). The thoracic cavity was insufflated with carbon dioxide and long esophageal myotomy was performed using hook electrocautery or ultrasonic shears (Figure 3). Significant inflammation and adhesions were present in all patients. Contralateral pneumothorax necessitating a chest tube insertion occurred during dissection in the second patient. Air was injected rapidly through a nasogastric tube to check for any esophageal leakage after myotomy. A single 28-Fr chest tube was placed in all patients. Operating times ranged from 120 to 180 min. The first and third patients were discharged on the third postoperative day. While the second patient with COPD had hypercapnia postoperatively and was kept intubated for 24 h and discharged on the fifth postoperative day. All patients had significant improvement in their symptoms and gained weight after the operation.

Discussion

During the last decade, distal esophagus through the left chest has lost its popularity with laparoscopic techniques

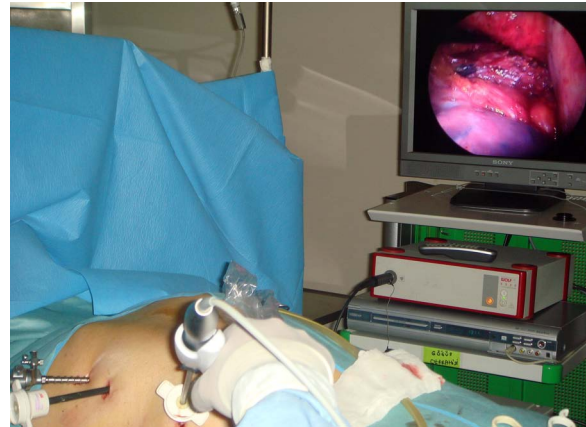

Figure 2. Patient in the prone position with excellent ergonomics showing the position of the three ports and surgical instruments in place.

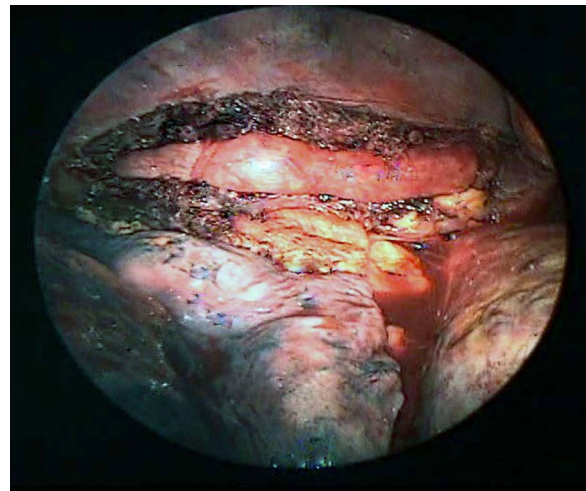


Figure 3. Intraoperative view of long esophagomyotomy performed in the prone position.

becoming the standard surgical approach for achalasia and epiphrenic diverticula.^{3,4} The advantages of prone position in esophageal pathologies were first reported by Palanivelu et al.⁵ as better exposure, ergonomics for the surgeon, shorter operating times, and better oxygenation of the patient.

In our first patient, the preference of this approach was due to the subtotal gastrectomy with probable intra-abdominal adhesions. In the second patient, a long esophageal myotomy was necessary. The third patient had multiple approaches with laparotomy for intestinal obstruction and cholecystectomy and hence intra-abdominal adhesions. In the prone position, we were able to explore the esophagus more proximally from the left side, which would have been difficult with high risk of pneumothorax using the laparoscopic approach because of limited exposure. While in the lateral decubitus position, the lung tends to fall posteriorly

and blood accumulates over the esophagus making dissection relatively difficult and continuous manipulation of the lung parenchyma. Our experience with these patients revealed the better exposure of the distal half of the esophagus with clearer view of the lung, crura, and aorta in comparison to laparoscopy or lateral decubitus thoracoscopy (Figure 3). A peanut inserted from the fourth port was used to elevate the aorta or depress the central diaphragm for better exposure. The other two working ports (superior and inferior) placed on the same line facilitate ergonomic dissection. Operating time may shorten with experience, as in the case of thoracoscopic esophageal cancer dissection in the prone position.⁵

The difficulty in positioning patients in the prone position can be easily overcome with less effort as the neurosurgeons use this position quite often.

Conclusion

Left thoracoscopic approach in the prone position exposes the distal esophagus better and appears to be practical and easy for benign esophageal pathologies as well. Maneuvering of the lung parenchyma is limited minimizing unforeseen lung injury. This approach would be an alternative in distal esophageal pathologies where laparoscopy is relatively contraindicated.

Declaration of conflicting interests

Drs Adamu Issaka, Hasan Volkan Kara, Barkin Eldem and Hasan F. Batirel have no conflicts of interest or financial ties to disclose.

Funding

This research received no specific grant from any funding agency in the public, commercial, or not-for-profit sectors.

References

1. Gaissert HA, Lin N, Wain JC, et al. Transthoracic Heller myotomy for esophageal achalasia: analysis of long-term results. *Ann Thorac Surg* 2006; 81: 2044–2049.
2. Agrawal D, Meekison L and Walker WS. Long-term clinical results of thoracoscopic Heller's myotomy in the treatment of achalasia. *Eur J Cardio-thorac* 2008; 34: 423–426.
3. Mattioli S, Ruffato A, Lugaresi M, et al. Long-term results of the Heller-Dor operation with intraoperative manometry for the treatment of esophageal achalasia. *J Thorac Cardiovasc Surg* 2010; 140: 962–969.
4. Fernando HC, Luketich JD, Samphire J, et al. Minimally invasive operation for esophageal diverticula. *Ann Thorac Surg* 2005; 80: 2076–2080.
5. Palanivelu C, Prakash A, Senthilkumar R, et al. Minimally invasive esophagectomy: thoracoscopic mobilization of the esophagus and mediastinal lymphadenectomy in prone position—experience of 130 patients. *J Am Coll Surg* 2006; 203: 7–16.