

Letters to the Editor

J Med Genet 2000;37:297–298

Can hair be used to screen for breast cancer?

EDITOR—The use of hair as a biopsy tissue has been considered for some time. For instance, in the case of breast cancer, raised zinc levels in head hair have been reported.¹ Besides, *x* ray diffraction patterns of hair are rich and have attracted much attention for 70 years.² However, its potential use as a diagnostic indicator of disease was only suggested a short time ago.³ Most recently, James *et al*⁴ reported that *x* ray diffraction of hair taken from women diagnosed with breast cancer (and those at high risk by virtue of a proven *BRCA1/BRCA2* mutation) showed a diffuse ring. They claimed a 100% correlation with the disease, advocating the use of pubic hair as a simple non-invasive screening method for breast cancer. The use of pubic hair was suggested in view of possible damage to the head hair from cosmetic treatments. Despite this note of caution, the study of James *et al*⁴ was based on 12 pubic hair samples with only eight from cancer affected subjects. Here, we report a detailed double blind study from 109 women belonging to five clinically distinct groups as well as a normal population group and show that there is no correlation between the diffuse ring and breast cancer or breast cancer predisposition.

The present work was initiated in November 1998 to provide an independent double blind study on clinically well controlled samples because of our concerns with the study of James *et al*⁴ for which a major proportion of the samples was provided by two of us (AH and DGRE). Both diffraction and *x* ray fluorescence data have been obtained. Diffraction data were collected on station 2.1 with the multiwire area detector and the fluorescence data on station 7.1 of the UK Synchrotron Radiation Source (SRS). The use of a multiwire detector allowed on line alignment of hair within seconds and enabled efficient diffraction data collection from a large number of samples. Six groups of subjects were selected including a normal population group. For each subject, head and pubic hair were collected and reference numbers assigned in a random manner. The identities of samples were kept blinded until all data were analysed. Each woman was asked to provide information on whether they had had any hair treatment (perm, dye, etc) or were on medication. No hair treatment was reported for pubic hair and thus here only results from pubic hair (108 samples) are discussed. Results of head hair are included in table 1

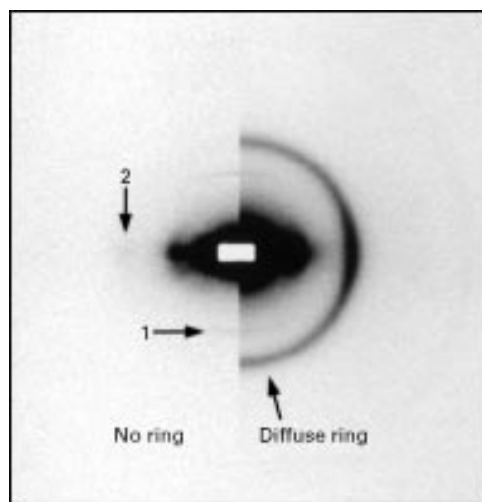


Figure 1 X ray diffraction patterns from the pubic hair of women diagnosed with breast cancer. The left half represents the pattern with no ring, the right half shows the diffuse ring. The first strong meridional reflection (arrow 1) is used for normalising the patterns, arrow 2 shows the equatorial reflection, which gets intensified in cases when the diffuse ring appears.

for completeness. The groups consisted of 27 unaffected controls aged 26–60 years, 21 isolated cases of breast cancer (<31 years) who had been screened negative for *BRCA1/BRCA2* mutations, and three cases aged over 60 years not so tested. The remaining groups came from a set of 43 families with proven *BRCA1/BRCA2* mutations: 25 affected mutation carriers, 10 unaffected mutation carriers, and 23 unaffected close female relatives who tested negative for the known mutations in the family.

Diffraction patterns could be grouped into two categories: one characterised by a diffuse ring at 4.78 ± 0.10 nm and one with no ring present (fig 1). The occurrence of this ring is well known from *x* ray patterns of both keratins and muscle and is ascribed to lipid crystals resulting from degradation processes.⁵ Contrary to the observation of James *et al*,⁴ the pubic hair of only 12 of 49 (25%) women with breast cancer showed the diffuse ring. This is only slightly larger than in the normal population group, where about 20% of the pubic hair samples showed the ring. In the case of the affected group who tested positive for a *BRCA1* or *BRCA2* mutation, 56% of the pubic hair samples showed no ring and only 24% of the pubic hair samples showed the ring. Table 1 provides a detailed summary of diffraction results for all six groups. A statistical analysis for pubic hair samples was performed to determine

Table 1 Proportion of subjects in each of six groups whose diffraction patterns show or do not show the diffuse ring

	Pubic hair						Head hair					
	N	U-	U+	A-	A+	Anh	N	U-	U+	A-	A+	Anh
Ring* (%)	5 (19)	6 (26)	6 (67)	5 (24)	6 (24)	1 (33)	15 (56)	15 (65)	7 (70)	10 (48)	7 (28)	1 (33)
No ring (%)	22 (81)	17 (74)	3 (33)	16 (76)	19 (76)	2 (67)	12 (44)	8 (35)	3 (30)	11 (52)	18 (72)	2 (67)
Total = 217	27	23	9†	21	25	3	27	23	10	21	25	3

N = control from normal population. U = unaffected (known not to have breast cancer). A = affected (known to have breast cancer). +/- = tested positive/negative for mutations in *BRCA1* and *BRCA2* genes. nh = no family history.

*Includes complete and partial ring. James *et al*⁴ suggest that pubic hair should be used for diagnostic purposes; 50% of all head hair samples show the ring in contrast to only 27% of pubic hair samples. This difference may arise from hair treatment among other factors.

†One woman supplied only head hair.

whether there was an association between the presence of the diffuse ring and breast cancer. There were 49 samples from women with breast cancer and 59 from unaffected women. A χ^2 value of 0.86 was obtained. For 1% significance, a value of 6.63 and for 5% significance, a value of 3.84 is required. Thus, it can be concluded that there is no measurable association between the diffuse ring and breast cancer. The trace element (Zn, Cu, Fe, and S) analysis of intact hair showed no correlation with the ring structure in the diffraction pattern or with the subjects' group. The women in the normal population group whose hair had shown the diffuse ring were examined and shown not to have breast cancer.

Our x ray diffraction data do not support the recent claim that hair from breast cancer patients or those at high risk (*BRCA1/BRCA2* mutation carriers) show a distinct diffuse ring. This conclusion for breast cancer diagnosis was also reached on a much smaller study of head hair only.⁶ In our study, diffraction patterns from 75% (37 of 49) of the breast cancer patients do not show this ring. Moreover, the χ^2 test shows no association between the diffuse ring and breast cancer and, as such, the claim that x ray diffraction of pubic hair can be used as a screening

method for breast cancer or breast cancer predisposition is invalid.

ANTHONY HOWELL*
J GÜNTHER GROSSMANN†
KAN C CHEUNG‡
LALJI KANBI‡
D GARETH R EVANS§
S SAMAR HASNAIN†‡

*CRC Department of Medical Oncology, Christie Hospital NHS Trust, Wilmslow Road, Manchester M20 4BX, UK

†CLRC Daresbury Laboratory, Warrington WAA 4AD, Cheshire, UK

‡Faculty of Applied Sciences, DeMontfort University, Leicester LE1 9BH, UK

§Department of Medical Genetics, St Mary's Hospital, Manchester M20 8LR, UK

Correspondence to: Dr Evans, Gevans@central.cmht.nwest.nhs.uk

- 1 Wiesener W, Gorner W, Niese S, Grund W, Hennig M, Mende T. Neutron activation analytical determination of trace elements in human hair. *Isotopenpraxis* 1981;17:278-82.
- 2 Astbury WT, Woods HJ. The X-ray interpretation of the structure and elastic properties of hair keratin. *Nature* 1930;126:913-14.
- 3 James VJ, Yue DK, McLennan SV. Changes in the molecular structure of human hair in insulin-dependant diabetes. *Biochem Biophys Res Commun* 1997;233:76-80.
- 4 James V, Kearsley J, Irving T, Amemiya Y, Cookson D. Using hair to screen for breast cancer. *Nature* 1999;398:33-4.
- 5 Fraser RDB, MacRea TP, Rogers GE, Filshie BK. Lipids in keratinised tissues. *J Mol Biol* 1963;7:90-1.
- 6 Briki F, Busson B, Salicru B, Esteve F, Doucet J. Breast-cancer diagnosis using hair. *Nature* 1999;400:226.

J Med Genet 2000;37:298-300

Mutation analysis of *SMAD2*, *SMAD3*, and *SMAD4* genes in hereditary non-polyposis colorectal cancer

EDITOR—Transforming growth factor- β (TGF- β) family members are known to be involved in the regulation of cell proliferation, differentiation, and apoptosis.¹ Members of the TGF- β family include TGF- β s, activins, and bone morphogenetic proteins (BMPs). Their signals are mediated to the cell nucleus by a network of transmembrane serine/threonine kinase receptors and their downstream effectors, the SMAD proteins.² SMAD proteins play a key role in intracellular TGF- β signalling and inactivating mutations of *SMADs*, such as *SMAD2*, *SMAD3*, and *SMAD4*, provide resistance of cells to TGF- β induced growth inhibition.

To date, eight human *SMADs* have been identified. Two of them, *SMAD2* and *SMAD4*, have been reported to be mutated in a subset of colorectal carcinomas.³⁻⁶ Germline mutations of *SMAD4* have been found in patients with juvenile polyposis, a condition predisposing to colorectal cancer.⁷⁻¹⁰

SMAD3 mutations have not been reported in human cancers. In a recent study by Arai *et al*,¹¹ *SMAD3* mutations were analysed in 35 sporadic colorectal and 15 HNPCC cancers and no mutations were found. Targeted disruption of the *SMAD3* gene in mice has been reported to lead to development of colorectal cancer,¹² though other studies have not detected a clear association.^{13 14} No genetic alterations in other *SMADs* have been reported in malignancy.

Hereditary non-polyposis colorectal cancer (HNPCC) is an autosomal dominantly inherited cancer susceptibility syndrome, associated with germline mutations in five DNA mismatch repair genes: *MLH1*, *PMS1*, *PMS2*, *MSH2*, and *MSH6*.¹⁵⁻¹⁹ Inactivation of both alleles of a mismatch repair gene results in microsatellite instability (MSI) that is a hallmark of HNPCC tumours.²⁰⁻²³ The genes responsible for microsatellite stable (MSS) HNPCC are still unknown.

Loss of growth inhibition by TGF- β is an important step in colon tumorigenesis and in HNPCC tumours with MSI this is mainly the result of frameshift mutations within a polyadenine sequence repeat in the TGF- β type II receptor (*TGF β R2*) gene.²⁴ It has been proposed that mutations in *TGF β R2* could underlie the cancer predisposition in MSS HNPCC,²⁵ and also that other genes involved in the TGF- β pathway are candidates for MSS HNPCC.²⁶

Chromosomal deletions are common genetic alterations in cancer and they are targeted at tumour suppressor loci.^{27 28} Previous studies have shown that one copy of chromosome 18q is lost in over 70% of sporadic colorectal cancers.²⁹⁻³² The *DCC* (deleted in colorectal cancer) gene has been suggested as a candidate target gene in this region and loss of expression of *DCC* has also been reported in colorectal cancers.³³ However, mutations in the coding region of *DCC* seem to be rare³⁴ and the position of *DCC* as a candidate tumour suppressor is not clear. Two other candidate genes, *SMAD4* and *SMAD2*, have recently been identified at the same 18q region^{3 35} emphasising the possible role of the *SMAD* genes in colorectal tumorigenesis. The aim of the present study was to investigate whether germline mutations in *SMAD2*, *SMAD3*, and *SMAD4* underlie microsatellite stable HNPCC.

Mutation screening was performed in 14 Finnish HNPCC kindreds from which lymphoblastoid cell lines were available. Based on genealogical evidence the families are unrelated, though the existence of early common ancestors cannot be excluded. One affected subject per family was included in the study. Of the kindreds, six fulfilled the Amsterdam criteria for HNPCC.³⁶ Other patients represent familial HNPCC-like colorectal cancer (CRC); the number of patients with CRC or endometrial cancer ranged from two to six per family (average three) (table 1). All kindreds selected for this study have previously been shown to be *MLH1* and *MSH2* mutation negative.³⁷ In three kindreds, DNA from tumour tissue had not been available. From 10 families one and in one family two colorectal cancer samples were available and no evidence of MSI had been detected (table 1). The study

Table 1 Features of the families studied. Six out of 14 families fulfilled the traditional Amsterdam criteria, eight patients represent familial colorectal cancer. All except three kindreds displayed microsatellite stable tumours; in F33, F65, and F74 the MSI/MSS status was unknown (tumour sample not available). Sites of cancer and age at diagnosis (in parentheses) in proband and first degree relatives are presented

HNPCC family	Criteria for diagnosis	MSI/MSS status	Sites of cancers and age of diagnosis in proband and first degree relatives
F 31	Amsterdam criteria	MSS	CRC (38, 39, 48, 62) small intestine (39)
F 33	Familial CRC	Not known	CRC (34, 40, 44, 50), cervix (40), liver (71)
F 42	Familial CRC	MSS	CRC (61, 67), stomach (56), breast (69)
F 44	Familial CRC	MSS	CRC (33, 53)
F 46	Familial CRC	MSS	CRC (54), cervix (?)
F 56	Amsterdam criteria	MSS	CRC (24, 43, 51, 52, 76)
F 65	Amsterdam criteria	Not known	CRC (32, 41, 54), liver (?)
F 68	Familial CRC	MSS	CRC (66, 68)
F 70	Familial CRC	MSS	CRC (?)
F 74	Amsterdam criteria	Not known	CRC (64, 67)
F 75	Familial CRC	MSS	CRC (?)
F 76	Familial CRC	MSS	CRC (41, 45)
F 80	Amsterdam criteria	MSS	CRC (47, 67), melanoma (70)
F 84	Amsterdam criteria	MSS	CRC (43, 56, 59), breast (44)

CRC = colorectal cancer.

was approved by the ethical committee of the Department of Medical Genetics, University of Helsinki.

Total cellular RNA was extracted from lymphoblasts by RNA extraction kit (QIAGEN). The *SMAD2*, *SMAD3*, and *SMAD4* genes were amplified from RNA using an RT-PCR procedure. First, 20 µl cDNA was created from 0.8 µg of RNA using standard random priming methods with Mu-MLV reverse transcriptase (Promega) and RNase inhibitor (Promega). The cDNA sequences for *SMAD2*, *SMAD3*, and *SMAD4* were derived from GenBank database (accession numbers U65019, U76622, and U44378, respectively). PCR primers for cDNA amplification were designed using the Primer3 server (<http://www-genome.wi.mit.edu/cgi-bin/primer/primer3.cgi>).

Table 2 PCR primers for cDNA amplification were designed using the Primer3 server. Each gene was divided into five fragments, covering the whole coding region of the gene. The forward (F) and reverse (R) primers and size of the each PCR product are listed below

Gene/fragment	Primer sequence (5'→3')	Product size (bp)
<i>SMAD2</i>	F: ATGTCGTCCATCTTGCCATT	
Fragment 1	R: CCTTTTCGATGGGATACCTG	365
<i>SMAD2</i>	F: CCAGGTCTCTTGATGGTCGT	
Fragment 2	R: TATATCCAGGAGGTGGCGTT	354
<i>SMAD2</i>	F: TATTCCAGAAACGCCACCTC	
Fragment 3	R: GCACTCAGCAAAAACCTTCCC	400
<i>SMAD2</i>	F: TGCCACGGTAGAAATGACAA	
Fragment 4	R: AAGGGGATCCCATCTGAGTT	413
<i>SMAD2</i>	F: AATGTGCACCATAAGAATGAGTT	
Fragment 5	R: TTCCATGGGACTTGATTGGT	202
<i>SMAD3</i>	F: CCAGCCATGTCGTCCATC	
Fragment 1	R: AAGGCGAACTCACACAGCTC	344
<i>SMAD3</i>	F: ATGTCATCTACTGCCGCTG	
Fragment 2	R: ATTGGGGGATAGGTTTGGAG	377
<i>SMAD3</i>	F: TGGCTACCTGAGTGAAGATGG	
Fragment 3	R: CCTCCGATGTAGTAGAGCCG	357
<i>SMAD3</i>	F: TAGGGCTGCTCTCCAATGTC	
Fragment 4	R: TGTCTCCTGTACTCCGCTCC	349
<i>SMAD3</i>	F: GGCTTTGAGGCTGTCTACCA	
Fragment 5	R: AACATCCACCTCTGGGTTTG	382
<i>SMAD4</i>	F: TTTCCAAAGGATCAAATTCG	
Fragment 1	R: TTGTGAAGATCAGGCCACCT	385
<i>SMAD4</i>	F: GATCTATGCCCGTCTCTGGA	
Fragment 2	R: GTGGAAGCCACAGGAATGTT	387
<i>SMAD4</i>	F: CTGCCAACTTTCCCAACATT	
Fragment 3	R: GGGTCCACGATCCATCAAC	436
<i>SMAD4</i>	F: CCATTCCAATCATCCTGCT	
Fragment 4	R: CGATGACACTGACGCAAAATC	480
<i>SMAD4</i>	F: GATTTGCGTCAGTGTATCG	
Fragment 5	R: TGATAAGGTTAAGGGGCCCA	378

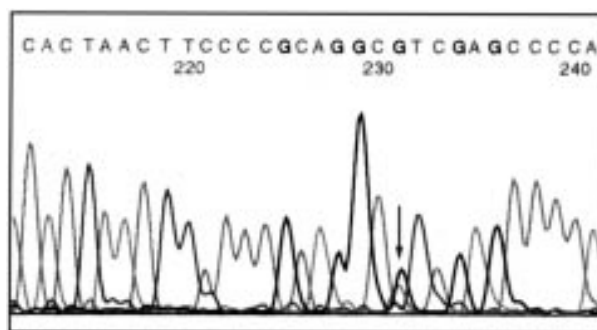


Figure 1 *SMAD3* polymorphism identified by sequencing. Adenine has changed to guanine (marked by an arrow), which is predicted to convert isoleucine to valine at amino acid 170.

Each gene was divided into five fragments, covering the whole coding region of the gene. The forward (F) and reverse (R) primers and size of each PCR product are listed in table 2.

The PCR reactions were carried out in a 50 µl reaction volume including 2 µl of cDNA, 1 × PCR reaction buffer (Perkin Elmer Applied Biosystems Division), 200 µmol/l of each dNTP (Finnzymes), 0.8 µmol/l of each primer, and 2 units of *AmpliTaq* GOLD polymerase (PE/ABI). The $MgCl_2$ concentration was 1.5 mmol/l for *SMAD2* fragments 1 and 2, *SMAD3* fragment 3, and all *SMAD4* fragments. For all other fragments the $MgCl_2$ concentration was 2.5 mmol/l. *SMAD3* fragment 2 reaction also included 10% of DMSO. The PCR conditions are available upon request.

After PCR, 5 µl of the PCR product was run on a 3% agarose (NuSieve) gel to verify the specificity of the PCR reaction. The rest of the PCR product was purified using QIAquick PCR purification Kit (QIAGEN). Direct sequencing of the PCR products was performed using the ABI PRISM Dye Terminator or ABI PRISM dRhodamine cycle sequencing kits (PE/ABI). Cycle sequencing products were electrophoresed on 6% Long Ranger gels (FMC Bioproducts) and analysed on an Applied Biosystems model 373A or 377 DNA sequencer (PE/ABI).

To screen for the presence of a base substitution in *SMAD3* in controls, restriction enzyme digestion was performed. *HgaI* (New England BioLabs) digestion was used to detect A to G change in *SMAD3* exon 3 at codon 170. New PCR primers for genomic exon 3 amplification were designed using the Primer3 server. The primers were: 5'-ATCGCACTGAGCCACCTCT (forward) and 5'-CCCACGTGCCTACCTCTG (reverse). The PCR reactions were carried out in a 50 µl reaction volume including 100 ng genomic DNA, 1 × PCR reaction buffer (PE/ABI), 200 µmol/l of each dNTP (Finnzymes), 0.8 µmol/l of each primer, 2 units of *AmpliTaq* GOLD polymerase (PE/ABI), and 1.5 mmol/l of $MgCl_2$. The following PCR cycles were used for amplification: 10 minutes at 95°C, 40 cycles of 45 seconds at 95°C, 45 seconds at 56°C, one minute at 72°C, and final extension for 10 minutes at 72°C. *HgaI* cuts the PCR fragment (187 bp) that contains the substitution into two fragments (134 bp and 53 bp in size) whereas the wild type fragment lacks the restriction site and is not digested. The digestion was performed in 1 × NEBuffer (New England BioLabs) at 37°C overnight. After digestion, the PCR products were electrophoresed through a 3% agarose gel.

In this work we analysed *SMAD2*, *SMAD3*, and *SMAD4* mutations in 14 familial colon cancer kindreds, 11 of these displaying at least one MSS tumour. The microsatellite analysis data derived typically from one single tumour per family suggest that these kindreds do not segregate DNA mismatch repair gene mutations, but does not exclude this possibility. Previous studies had evaluated *MLH1* and

MSH2 mutations in the series with negative results.³⁷⁻³⁸ *SMAD* gene mutation analysis was performed by automated sequencing covering the translated region of the genes. Genetic alterations were not detected in *SMAD2* or *SMAD4* in any of these patients. In *SMAD3*, three discrepancies were detected between GenBank sequence (U76622) and sequences from our patients, firstly the A to G change at the third position of codon 103 (exon 2). Homozygous A to G change was seen in 11 of our 14 patients and in three of them the substitution was heterozygous. This discrepancy has been reported earlier and the variant does not cause any amino acid change.⁹⁻¹¹ A second, silent change detected was a C to T transition at nucleotide 907 (exon 6). This change was homozygous and it was present in one of our 14 HNPCC patients (in family 31). The frequency of these variants in the normal population was not analysed, as the changes were silent. The third change was an adenine to guanine transition at nucleotide 545, which is predicted to convert isoleucine to valine at amino acid 170 (fig 1). This change was detected in two patients (in families 65 and 75). For this variant, 110 Finnish controls were analysed by restriction enzyme digestion (*HgaI*). Seven out of 110 controls displayed the change (6.4%). To compare further the frequency of this polymorphism in colon cancer patients and controls, 132 patients were included in the analysis. Taken together, in the 14 HNPCC patients and 132 colon cancer patients the frequency of this polymorphism was 8.9% (13/146). From those 13 cancer patients who had valine instead of isoleucine at codon 170, four turned out to be familial. Segregation of the polymorphism was analysed in two of these families where DNA from multiple family members was available and the polymorphism did not segregate with cancer in these families.

SMAD2, *SMAD3*, or *SMAD4* mutations were not found in any of our patients using a cDNA based mutation analysis. It should be noted that like all other mutation detection methods, this method may miss a subset of mutations. Also, the potential existence of founder mutations in the Finnish population may have hampered our efforts to detect *SMAD* gene defects in HNPCC. However, it is likely that defects of *SMAD2*, *SMAD3*, or *SMAD4* are not a common cause of familial colon cancer. Further work is necessary to unravel the molecular background of MSS HNPCC.

We thank Siv Lindroos, Liisa Suksi, and Päivi Laiho for technical assistance. This study was supported by grants from the Finnish Cancer Society, the Academy of Finland, Emil Aaltonen Foundation, Finnish Cultural Foundation, Sigrid Juselius Foundation, and Biocentrum Helsinki.

S ROTH*
M JOHANSSON*
A LOUKOLA*
P PELTOMÄKI†
H JÄRVINEN‡
J-P MECKLIN§
L A AALTONEN*

*Department of Medical Genetics, Haartman Institute, PO Box 21, (Haartmaninkatu 3), 00014 University of Helsinki, Finland

†Human Cancer Genetics Program, Comprehensive Cancer Centre, Ohio State University, Columbus, Ohio, USA

‡Second Department of Surgery, Helsinki University Central Hospital, Helsinki, Finland

§Department of Surgery, Jyväskylä Central Hospital, Jyväskylä, Finland

Correspondence to: Dr Aaltonen, lauri.aaltonen@helsinki.fi

- Heldin CH, Miyazono K, ten Dijke P. TGF- β signalling from cell membrane to nucleus through SMAD proteins. *Nature* 1997;390:465-71.
- Hata A, Shi Y, Massague J. TGF- β signalling and cancer: structural and functional consequences of mutations in SMADs. *Mol Med Today* 1998;6:257-62.

- Eppert K, Scherer SW, Ozcelik H, et al. MADR2 maps to 18q21 and encodes a TGF β -regulated MAD-related protein that is functionally mutated in colorectal carcinoma. *Cell* 1996;86:543-52.
- Thiagalingam S, Lengauer C, Leach FS, et al. Evaluation of candidate tumour suppressor genes on chromosome 18 in colorectal cancers. *Nat Genet* 1996;13:343-6.
- Takagi Y, Kohmura H, Futamura M, et al. Somatic alterations of the DPC4 gene in human colorectal cancers in vivo. *Gastroenterology* 1996;111:1369-72.
- Miyaki M, Iijima T, Konishi M, et al. Higher frequency of Smad4 gene mutation in human colorectal cancer with distant metastasis. *Oncogene* 1999;20:3098-103.
- Howe JR, Roth S, Ringold JC, et al. Mutations in the SMAD4/DPC4 gene in juvenile polyposis. *Science* 1998;280:1086-8.
- Houlston R, Bevan S, Williams A, et al. Mutations in DPC4 (SMAD4) cause juvenile polyposis syndrome, but only account for a minority of cases. *Hum Mol Genet* 1998;7:1907-12.
- Roth S, Sistonen P, Salovaara R, et al. SMAD genes in juvenile polyposis. *Genes Chrom Cancer* 1999;26:54-61.
- Friedl W, Kruse R, Uhlhaas S, et al. Frequent 4-bp deletion in exon 9 of the SMAD4/MADH4 gene in familial juvenile polyposis patients. *Genes Chrom Cancer* 1999;25:403-6.
- Arai T, Akiyama Y, Okabe S, Ando M, Endo M, Yuasa Y. Genomic structure of the human SMAD3 gene and its infrequent alterations in colorectal cancers. *Cancer Lett* 1998;122:157-63.
- Zhu Y, Richardson JA, Parda LF, Graff JM. SMAD3 mutant mice develop metastatic colorectal cancer. *Cell* 1998;94:703-14.
- Yang X, Letterio JJ, Lechleider RJ, et al. Targeted disruption of SMAD3 results in impaired mucosal immunity and diminished T cell responsiveness to TGF- β . *EMBO J* 1999;18:1280-91.
- Datto MB, Frederick JP, Pan L, Borton AJ, Zhuang Y, Wang XF. Targeted disruption of Smad3 reveals an essential role in transforming growth factor β -mediated signal transduction. *Mol Cell Biol* 1999;19:2495-504.
- Leach FS, Nicolaides NC, Papadopoulos N, et al. Mutations of mutS homolog in hereditary nonpolyposis colorectal cancer. *Cell* 1993;75:1215-25.
- Bronner CE, Baker SM, Morrison PT, et al. Mutation in the DNA mismatch repair gene homologue hMLH1 is associated with hereditary non-polyposis colon cancer. *Nature* 1994;368:258-61.
- Papadopoulos N, Nicolaides NC, Wei YF, et al. Mutation of mutL homolog in hereditary colon cancer. *Science* 1994;263:1625-9.
- Nicolaides NC, Papadopoulos N, Liu B, et al. Mutations of two PMS homologues in hereditary nonpolyposis colon cancer. *Nature* 1994;371:75-80.
- Miyaki M, Konishi M, Tanaka K, et al. Germline mutation of MSH6 as the cause of hereditary nonpolyposis colorectal cancer. *Nat Genet* 1997;17:271-2.
- Aaltonen LA, Peltomäki P, Leach FS, et al. Clues to the pathogenesis of familial colorectal cancer. *Science* 1993;260:812-16.
- Ionov Y, Peinado MA, Malkhosyan S, Shibata D, Perucho M. Ubiquitous somatic mutations in simple repeated sequences reveal a new mechanism for colonic carcinogenesis. *Nature* 1993;363:558-61.
- Thibodeau SN, Bren G, Schaid D. Microsatellite instability in cancer of the proximal colon. *Science* 1993;260:816-19.
- Hemminki A, Peltomäki P, Mecklin JP, et al. Loss of the wild type MLH1 gene is a feature of hereditary nonpolyposis colorectal cancer. *Nat Genet* 1994;8:405-10.
- Markowitz S, Wang J, Myeroff L, et al. Inactivation of the type II TGF- β receptor in colon cancer cells with microsatellite instability. *Cell* 1995;268:1336-8.
- Lu SL, Kawabata M, Imamura T, et al. HNPCC associated with germline mutation in the TGF- β type II receptor gene. *Nat Genet* 1998;19:17-18.
- Grady WM, Myeroff LL, Swinler SF, et al. Mutational inactivation of transforming growth factor β receptor type II in microsatellite stable colon cancers. *Cancer Res* 1999;59:320-4.
- Knudson AG. Antioncogenes and human cancer. *Proc Natl Acad Sci USA* 1993;90:10914-21.
- Vogelstein B, Kinzler KW. *The genetic basis of human cancer*. New York: McGraw-Hill, 1998.
- Vogelstein B, Fearon ER, Hamilton SR, et al. Genetic alterations during colorectal-tumor development. *N Engl J Med* 1988;319:525-32.
- Korn WM, Yasutake T, Kuo WL, et al. Chromosome arm 20q gains and other genomic alterations in colorectal cancer metastatic to liver, as analyzed by comparative genomic hybridization and fluorescence in situ hybridization. *Genes Chrom Cancer* 1999;25:82-90.
- Ried T, Knutzen R, Steinbeck R, et al. Comparative genomic hybridization reveals a specific pattern of chromosomal gains and losses during the genesis of colorectal tumors. *Genes Chrom Cancer* 1996;15:234-45.
- Meijer GA, Hermsen MA, Baak JP, et al. Progression from colorectal adenoma to carcinoma is associated with non-random chromosomal gains as detected by comparative genomic hybridisation. *J Clin Pathol* 1998;51:901-9.
- Featon ER, Cho KR, Nigro JM, et al. Identification of a chromosome 18q gene that is altered in colorectal cancers. *Science* 1990;247:49-56.
- Cho KR, Oliner JD, Simons JW, et al. The DCC gene: structural analysis and mutations in colorectal carcinomas. *Genomics* 1994;19:525-31.
- Hahn SA, Schutte M, Hoque AT, et al. DPC4, a candidate tumor suppressor gene at human chromosome 18q21.1. *Science* 1996;271:350-3.
- Vasen HF, Mecklin JP, Khan PM, Lynch HT. The International Collaborative Group on Hereditary Non-Polyposis Colorectal Cancer (ICG-HNPCC). *Dis Colon Rectum* 1991;34:424-5.
- Nyström-Lahti M, Wu Y, Moiso AL, et al. DNA mismatch repair gene mutations in 55 kindreds with verified or putative hereditary non-polyposis colorectal cancer. *Hum Mol Genet* 1996;5:763-9.
- Holmberg M, Kristo P, Chadwicks RB, et al. Mutation sharing, predominant involvement of the MLH1 gene and description of four novel mutations in hereditary nonpolyposis colorectal cancer. *Hum Mutat* 1998;11:482.

Novel mutation in the *MYOC* gene in primary open angle glaucoma patients

EDITOR—Glaucoma is the world's leading cause of irreversible blindness¹ and is characterised by progressive optic disc cupping with corresponding visual field loss. Both intraocular pressure (IOP) and positive family history are risk factors for the development of the disease.² Juvenile open angle glaucoma (JOAG) is a subtype of open angle glaucoma characterised by an early onset (10 to 35 years of age) and autosomal dominant inheritance with high penetrance,³ a characteristic which has led several authors to investigate affected families in an attempt to identify a gene or genes associated with this condition.⁴⁻¹⁰ With the use of genetic linkage analysis in families with JOAG, a genetic locus (GLC1A) was recognised on chromosome 1q21-q31.⁴ The gene associated with GLC1A has been identified and it codifies a 57 kDa protein named trabecular meshwork induced glucocorticoid response protein (TIGR),¹⁰ also known as myocilin (MYOC).¹¹ The *MYOC* gene is composed of three exons of 604, 126, and 785 bp, respectively.¹² During screening for mutations in the *MYOC* gene in 25 unrelated Brazilian patients with JOAG, an unreported mutation (Cys433Arg) was detected, present in seven of them.

Patients were followed at the Glaucoma Service of the State University of Campinas, Brazil. They underwent an ocular examination, including gonioscopy by Posner lens, applanation tonometry, slit lamp biomicroscopy, optic nerve evaluation, and automated perimetry (Humphrey 630, program 30-2). JOAG was defined as the presence of characteristic bilateral optic nerve damage and visual field loss in the presence of an open angle in subjects younger than 36 years of age. Each patient included in this study came from different families according to interview data. The study was approved by the Ethics Committee of the State University of Campinas. At the time of the ocular examination, the mean age of JOAG patients was 25.52 years (SD 6.99), ranging from 10 to 35 years, and the mean IOP was 29.96 mm Hg (SD 13.00). Thirteen patients (52%) were male and 12 patients (48%) were female; 13 (52%) were white, 11 (44%) were black, and one (4%) was Asian. Some of the patients had been taking antiglaucomatous medication or had undergone surgical procedures for IOP control and showed IOP levels lower than 22 mm Hg at the time of examination. Fourteen patients (56%) had a positive family history.

Genomic DNA from peripheral blood (withdrawn from the antecubital vein) was prepared using DNAzolTM Reagent according to the manufacturer's instructions (GIBCO/BRL, Gaithersburg, MD). Primers were designed to amplify the three exons of the *MYOC* gene, according to the reported sequence (GenBank accession numbers U85257 and Z98750). Exon 3 was the first to be analysed, since this is the region where the majority of the mutations have been found.¹² SSCP analysis was performed on a Pharmacia PhastSystem (Pharmacia, Uppsala, Sweden) using a 20% homogeneous polyacrylamide gel. Samples with abnormal mobility shifts were sequenced using Thermo Sequenase Cycle Sequencing Kit with γ -³²P ATP (Amersham Life Science Inc, Cleveland, Ohio), according to the manufacturer's instructions.

Seven patients (28%) showed a point mutation in exon 3, a heterozygous T to C transition at nucleotide position 1374 leading to a cysteine (Cys) 433 for arginine (Arg) substitution. The SSCP pattern shows two abnormal

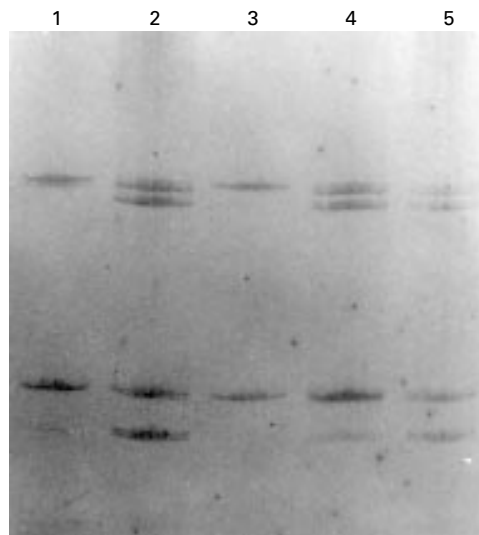


Figure 1 Silver stained SSCP gel showing the 195 bp PCR product encompassing amino acids 412 to 476 of the *MYOC* gene. Lane 1: control sample. Lanes 2-5: samples of JOAG patients. Samples 2, 4, and 5 show abnormal mobility shifts as compared with the control.

mobility shifts (figs 1 and 2). Analysis through SSCP and restriction digestion with *FokI* was performed in 130 control samples of different ethnic origin in order to discard the possibility of the new substitution being a polymorphism. Cleavage of the approximately 195 bp amplified fragment with *FokI* generates three fragments of 13, 50, and 132 bp in size in the absence of the mutation, and in its presence the 132 bp fragment is cleaved into two additional 33 and 99 bp fragments. The mutation was not present in any of the samples. The Cys433Arg mutation was present in five (71%) white patients and two (29%) black patients. Six patients (85%) of those with the mutation had a positive familial history of glaucoma. The mean age of patients harbouring this mutation was 27.00 years (SD 6.02), ranging from 15 to 35 years and the mean IOP was 39.13 mm Hg (SD 12.62). In contrast, JOAG patients without the mutation had a mean age of 24.02 (SD 7.46) and a mean IOP of 25.65 mm Hg (SD 11.68) ($p > 0.05$). In another patient, a previously reported mutation (Pro370Leu) was identified.¹³

One of the patients who showed the Cys433Arg mutation had the family investigated for its presence. Nine subjects were studied and four harboured the Cys433Arg mutation (fig 3). Three of them had glaucoma and one had ocular hypertension without optic nerve or visual field damage. The other members who did not have the disease were not affected with the Cys433Arg mutation.

In order to discriminate between a founder effect and a de novo recurrence, haplotype analysis was performed in the six patients with a positive family history who had the new mutation and in one family using four microsatellite markers, mapped at band 1q21-25, closely linked to the GLC1A locus, DIS210, DIS2790, DIS1619, and NGA19. Polymerase chain reaction (PCR) was carried out following standard procedures and primer sequences were obtained from the Genome Data Bank. For allele scoring, PCR products were size fractionated on a 6% polyacrylamide-urea gel and autoradiographed. The analysis of four microsatellite markers showed that the Cys433Arg mutation is associated with a common haplotype, suggesting that these patients inherited their mutation from a common ancestor. A pedigree of the family analysed can be seen in fig 3, depicting a potential disease haplotype.

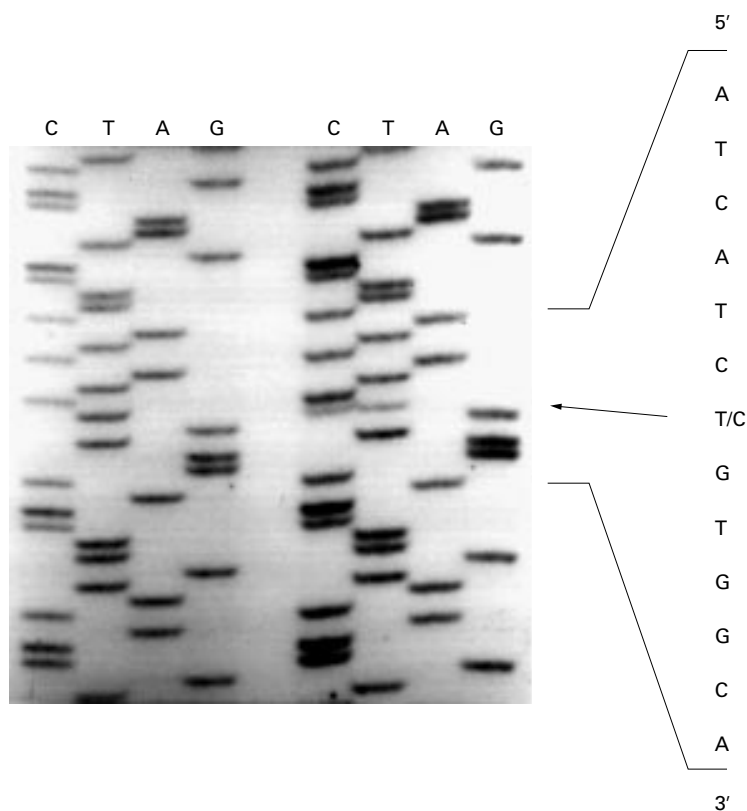


Figure 2 Direct sequencing of the PCR product showing a T-C substitution at codon 433 of the MYOC gene, which changes the amino acid Cys (TGT) to Arg (CGT). The arrow indicates the exact location of the mutation.

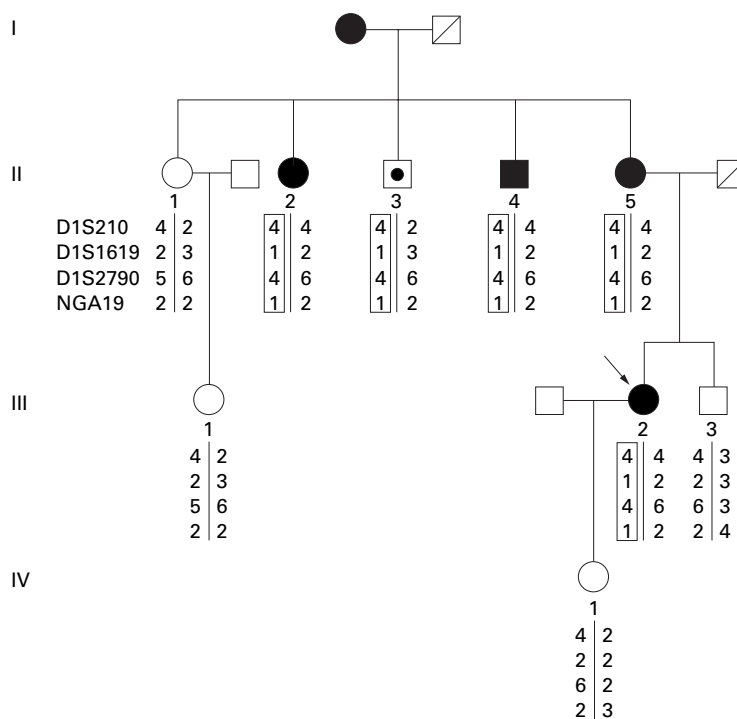


Figure 3 Pedigree of a JOAG patient's family (the proband is indicated with an arrow). Solid symbols indicate affected subjects, all harbouring the Cys433Arg mutation. II.3, indicated with a dotted symbol, has not developed glaucoma, but has very high IOP levels and also shows the Cys433Arg mutation. Four microsatellite markers, located in the vicinity of the GLC1A locus, were used for haplotype analysis. The pedigree shows the genotypes at polymorphic microsatellite loci as well as a potential disease haplotype shown in the boxes.

Since the first description of the *MYOC* gene (then called the *TIGR* gene) by Stone *et al*¹⁰ as one of the genes related to open angle glaucoma at the *GLC1A* locus, several mutations have been described among patients with open angle glaucoma.^{10 11 13 14}

During the screening of exon 3 of the *MYOC* gene in our JOAG patients, we identified a mutation at amino acid 433 (exon 3) which encodes for an arginine instead of a cysteine in 28% of the patients. The mutation is located in a highly conserved amino acid sequence, the olfactomedin (OLFM)-like domain, a region where most of the mutations have been identified.¹² In fact, the cysteine residue 433 is of particular interest, as it is located within the most conserved region between species, from *C elegans* to humans. As in other olfactomedins, it is likely that this cysteine residue is involved in protein oligomerisation by disulphide linked polymer formation.^{15 16} According to Nguyen *et al*,¹⁶ oligomerisation of the *MYOC* protein could be an important feature in the obstruction of the trabecular meshwork. It is possible that *MYOC* dimers or polymers are linked to form a higher molecular mass structure via a cysteine-cysteine formation, similar to that predicted in olfactomedin by Yokoe and Anholt.¹⁵ Therefore, mutations in this domain may alter protein oligomerisation and lead to IOP elevation.¹⁶

Clinically, the Cys433Arg mutation seems to be closely related to glaucoma; it was found in three glaucomatous relatives of one patient and in a relative with ocular hypertension. This change was not found in our control group of 130 unrelated subjects or in any healthy subject studied, indicating that it is a probable disease causing mutation, which, to our knowledge, has not yet been described. Affected patients tend to present with the disease during the third decade, with very high IOPs (high 30s). Hence, the phenotype-genotype correlation is closer to that which has been reported for the Pro370Leu mutation,¹⁷ which also determines a severe disease with an early onset, in contrast with the Gln368Stop mutation, which is associated with later onset of glaucoma.¹⁴

Haplotype analysis showed that the six patients with a positive familial history who harboured the mutation had the same disease associated haplotype, indicating that this mutation has probably arisen from a common ancestor, as shown for the Asn480Lys mutation¹⁷ and for the 1177GACA→T mutation.¹⁹

Although the mechanisms involved in the association between the *MYOC* gene, POAG, and JOAG are not completely understood,¹⁴ it is not unreasonable to expect that the pathophysiology of these diseases will be elucidated, leading to better treatments. Furthermore, it may be used as a screening test to identify susceptible subjects long before the development of optic nerve damage, allowing early treatment and possibly avoiding the disease related visual impairment. Finally, it may be possible to modify the

MYOC gene in order to inhibit phenotypic changes induced by mutations, thereby ultimately halting the development of glaucoma.

The study was supported by FAPESP grant 98/13830-0.

JOSÉ PAULO C VASCONCELLOS*
MÔNICA B MELO†
VITAL P COSTA*
DANIELA M L TSUKUMO†
DANIELA S BASSERES†
SILVANA BORDIN†
SARA T O SAAD†
FERNANDO F COSTA†

*Department of Ophthalmology, School of Medical Sciences, State University of Campinas (UNICAMP), Campinas, SP, Brazil

†Department of Clinical Medicine - Hemocentro, School of Medical Sciences, State University of Campinas (UNICAMP), Campinas, SP, Brazil

Correspondence to: Dr Costa, Hemocentro - UNICAMP, Cidade Universitária Zeferino Vaz S/N, Caixa Postal 6198, CEP 13083-970, Brazil

- 1 Quigley HA. Number of people with glaucoma worldwide. *Br J Ophthalmol* 1996;**80**:389-93.
- 2 Dickens CJ, Hoskins HD. Epidemiology and pathophysiology of congenital glaucoma. In: Ritch R, Shields M, Krupin T, eds. *The glaucomas*. Vol 2. St Louis: Mosby-Year Book Inc, 1996:729-38.
- 3 Johnson AT, Drack AV, Kwitek AE, Cannon RL, Stone EM, Alward WLM. Clinical features and linkage analysis of a family with autosomal dominant juvenile glaucoma. *Ophthalmology* 1993;**100**:525-9.
- 4 Sheffield VC, Stone EM, Alward WLM, *et al*. Genetic linkage of familial open angle glaucoma to chromosome 1q21-q31. *Nat Genet* 1993;**4**:47-50.
- 5 Richards JE, Lichter PR, Boehnke M, *et al*. Mapping of a gene for autosomal dominant juvenile-onset open-angle glaucoma to chromosome 1q. *Am J Hum Genet* 1994;**54**:62-70.
- 6 Wiggs JL, Haines JL, Paglinauan C, Fine A, Sporn C, Lou D. Genetic linkage of autosomal dominant juvenile glaucoma to 1q21-q31 in three affected pedigrees. *Genomics* 1994;**21**:299-303.
- 7 Wiggs JL, Del Bono EA, Schuman JS, Hutchinson BT, Walton DS. Clinical features of five pedigrees genetically linked to the juvenile glaucoma locus on chromosome 1q21-q31. *Ophthalmology* 1995;**102**:1782-9.
- 8 Morissette J, Côté G, Ancil JL, *et al*. A common gene for juvenile and adult-onset primary open-angle glaucomas confined on chromosome 1q. *Am J Hum Genet* 1995;**56**:1431-42.
- 9 Johnson AT, Richards JE, Boehnke M, *et al*. Clinical phenotype of juvenile-onset primary open-angle glaucoma linked to chromosome 1q. *Ophthalmology* 1996;**103**:808-14.
- 10 Stone EM, Fingert JH, Alward WLM, *et al*. Identification of a gene that causes primary open angle glaucoma. *Science* 1997;**275**:668-70.
- 11 Kubota R, Noda S, Wang Y, *et al*. A novel myosin-like protein (myocilin) expressed in the connecting cilium of the photoreceptor: molecular cloning, tissue expression and chromosomal mapping. *Genomics* 1997;**41**:360-9.
- 12 Sarfarazi M. Recent advances in molecular genetics of glaucomas. *Hum Mol Genet* 1997;**6**:1667-77.
- 13 Suzuki Y, Shirato S, Taniguchi F, Ohara K, Nishimaki K, Ohta S. Mutations in the *TIGR* gene in familial primary open-angle glaucoma in Japan. *Am J Hum Genet* 1997;**61**:1202-4.
- 14 Alward WLM, Fingert JH, Coots MA, *et al*. Clinical features associated with mutations in the chromosome 1 open-angle glaucoma gene (*GLC1A*). *N Engl J Med* 1998;**338**:1022-7.
- 15 Yokoe H, Anholt RH. Molecular cloning of olfactomedin, an extracellular matrix protein specific to olfactory neuroepithelium. *Proc Natl Acad Sci USA* 1993;**90**:4655-9.
- 16 Nguyen TD, Chen P, Huang WD, Chen H, Johnson D, Polansky JR. Gene structure and properties of *TIGR*, an olfactomedin-related glycoprotein cloned from glucocorticoid-induced trabecular meshwork cells. *J Biol Chem* 1998;**273**:6341-50.
- 17 Adam MF, Belmouden A, Binisti P, *et al*. Recurrent mutations in a single exon encoding the evolutionary conserved olfactomedin-homology domain of *TIGR* in familial open-angle glaucoma. *Hum Mol Genet* 1997;**6**:2091-7.
- 18 Brézin AP, Adam MF, Belmouden A, *et al*. Founder effect in *GLC1A*-linked familial open-angle glaucoma in northern France. *Am J Med Genet* 1998;**76**:438-45.
- 19 Angius A, De Gioia E, Loi A, *et al*. A novel mutation in the *GLC1A* gene causes juvenile open-angle glaucoma in 4 families from the Italian region of Puglia. *Arch Ophthalmol* 1998;**116**:793-7.

J Med Genet 2000;**37**:303-307

Three novel *SALL1* mutations extend the mutational spectrum in Townes-Brocks syndrome

EDITOR—Townes-Brocks syndrome (TBS, MIM 107480) was first described by Townes and Brocks¹ in 1972 as an association of imperforate anus, supernumerary thumbs, malformed ears, preauricular tags, and sensorineural hearing

loss. Several additional familial as well as isolated cases have been reported.² TBS is caused by mutations of the putative zinc finger transcription factor gene *SALL1*.³ All *SALL1* mutations identified to date in TBS patients are located 5' of the first double zinc finger encoding region.⁴ Three of these are nonsense mutations at two different positions. The mutation 826C>T was found in three unrelated sporadic cases, and at position 1115 one patient carried an adenine (1115C>A) and another a guanine (1115C>G) instead of a cytosine. All seven other reported mutations are short frameshift deletions of 1, 2, 7, or 10 base pairs.⁴

SALL1 encodes four double zinc finger domains which are characteristically distributed over the entire protein.⁵ All known mutations have been predicted, if the mutated transcripts are indeed translated, to result in prematurely truncated proteins lacking all double zinc finger domains presumed to be essential for *SALL1* gene function. Since no mutations were found 3' of the most 5' located double zinc finger encoding region, it was assumed that only those mutations which remove all double zinc fingers could cause TBS,⁴ whereas mutations located further 3' in *SALL1* could result in a different phenotype or no abnormal phenotype at all. Here we describe three novel mutations in three independent families illustrating that truncating mutations positioned further 3' of the previously described hotspot region in *SALL1* also result in TBS.

All subjects available for investigations were examined for *SALL1* mutations after giving informed consent, and all those available for investigations were clinically examined by a clinical geneticist. In all affected subjects chromosomal analysis before DNA studies had shown a normal karyotype.

In the first family (family 1), TBS occurred in a sporadic case. The male patient (patient 1 of this study), aged 44, came to the clinic because of sudden loss of visual acuity owing to optic neuropathy. Townes-Brocks syndrome was diagnosed because he showed bilateral dysplastic ears, bilateral triphalangeal thumbs, and congenital sensorineural deafness. As a child, he had undergone surgery for imperforate anus, and his feet were previously operated on because of toe malposition. X rays showed bilateral partial proximal synostosis of metatarsals IV-V as well as fusion of some tarsal bones (not shown). Unusual features of this patient include acute bilateral optic neuropathy as well as bilateral inguinal hernias and an umbilical hernia. The family history was negative for TBS. His parents were not available for investigation.

In the second family (family 2), TBS was diagnosed in the female index patient (patient 2 of this study) because of a bifid thumb on the left and preaxial polydactyly on the right side, bilateral, small, dysplastic ears, bilateral moderate to severe conductive hearing loss, bilateral renal hypoplasia, acquired hypothyroidism, anteriorly placed and stenotic anus, and hypoplastic third toes with fifth toe clinodactyly. Recently, her mother gave birth to a boy who is also affected. He shows a bifid thumb on the right and complete preaxial polydactyly on the left side. He has bilateral cup shaped microtia with preauricular dimples and is reported not to respond to loud noises. The suspected hearing loss has not yet been fully evaluated. The baby boy has no anal malformation but a prominent midline perineal raphe. Congenital hypothyroidism was also diagnosed. The kidneys were normal on ultrasound. No other abnormalities are reported in these children. Both parents are clinically normal except for an anteriorly placed anus seen in the mother. The mother's family history is unremarkable. Her husband has a great aunt with unilateral preaxial polydactyly whose grandson also has preaxial polydactyly. The aunt's niece had a child with hemifacial microsomia. The parents of the index patient are not consanguineous.

In the third family, at least five persons in three generations are affected (fig 1A). The male index patient (III.2, patient 3) had imperforate anus with a prominent perineal median raphe, bilateral cutaneous syndactyly of the third and fourth toes, bilateral hypoplastic second toes, lop ears, frontal bossing, retrognathia, glandular hypospadias, and bilateral hypoplastic and dysplastic kidneys. Echocardiography showed a secundum type ASD. A mixed hearing loss was diagnosed at 1 year of age, assessed at the age of 2 as 50-60 dB (over the whole tone range). During childhood the boy showed considerable growth retardation (length

and weight <3rd centile), probably secondary to chronic renal insufficiency. At the age of 6 haemodialysis was begun because of severe renal insufficiency. Intelligence is normal.

His grandmother (I.1, patient 4) had late onset hearing loss first noticed at the age of 45. At 70 years of age, she had a hearing loss of 60-65 dB. Clinical examination showed lop ears with downfolded scapha helix and hypoplastic anthelix and insufficient rotation of both thumbs on opposition. Anamnestically, there were no anal abnormalities. She had never had any kidney complaints, but her kidneys were not specifically checked by ultrasound or biochemically. Her daughter (II.2, patient 5) showed sensorineural hearing loss (audiometry aged 37: mild perceptive hearing loss, 35 dB over the whole tone range). Her ears were operated on during adolescence ("bat ears"). Her anus was normal on physical examination, and her kidneys were normal on ultrasound. No further abnormalities were seen in I.1 or II.2. No clinical data are available on the brother of II.2 (II.3). He was reported by his spouse to have "strange ears" but he declined to be examined. However, he has two affected children. His son (III.4) had imperforate anus, "bat ears" with downfolded and hypoplastic margin of the scapha helix, perceptive hearing loss of 20 dB on audiometry at the age of 6, and showed insufficient rotation of the thumbs on opposition. His sister (III.3) had imperforate anus with a prominent perineal raphe, lop ears with downfolded upper margin of the scapha helix, and insufficient rotation of the thumbs on opposition.

Mutation analysis of *SALL1* was performed by PCR amplification of all exons from genomic DNA (prepared from peripheral lymphocytes) followed by direct sequencing of PCR products as described elsewhere.⁴ Permanent lymphoblastoid cell lines were prepared as previously described.⁶ Cells were harvested by centrifugation and total RNA was isolated using Total RNA Reagent (Biomol) according to the manufacturer's instructions. Two µg of total RNA from each stage was reverse transcribed using Ready-To-Go™ You-Prime First Strand Beads (Amersham Pharmacia) and 20 pmol of primer TR5.5 (5'GGCCACCATAGGTTCGCATTC3'), and 1 µl of each first strand reaction was used as a template in a subsequent PCR reaction (conditions: 95°C for four minutes initial denaturation; 35 cycles of 94°C for one minute, 64°C for one minute, 72°C for one minute; 72°C for two minutes final extension) with primers TF4.2 (5'TGGATTTGACATCTAGTCACGC3') and TR5.8 (5'TGAACAGGAATGAATGCTATGTC3'). A nested amplification was carried out using primers TF4.3 (5'GACACCCCCACAGTCACG3') and TR5.7 (5'AGGTGAGCTGTTC-CCACTGC3'). Conditions were: 95°C for four minutes initial denaturation; 35 cycles of 94°C for one minute, 64°C for one minute, 72°C for 45 seconds; 72°C for two minutes final extension. PCRs were performed on Primus 25 thermal cyclers (MWG). Amplification products were visualised on agarose gels, gel extracted, and DNA sequences of amplification products were verified by direct sequencing using primers TF4.3 and TR5.7. PCR products were also subcloned in pGEM-Teasy (Promega) and at least four independent clones were sequenced using vector specific primers.

SALL1 mutation analysis in family 1 (patient 1) showed a heterozygous mutation 840delC which is located 5' of the region encoding the first double zinc finger (fig 2A, fig 3). In family 2, we found a heterozygous nonsense mutation 1509C>A (Y503X) in the affected girl (patient 2, fig 2C, fig 3). This mutation was also detected in her affected newborn brother. However, neither parent showed the mutation in their peripheral lymphocytes. Paternity was confirmed in this family (data not shown). In family 3, molecular analysis was performed on I.1 (patient 4, fig 1A),

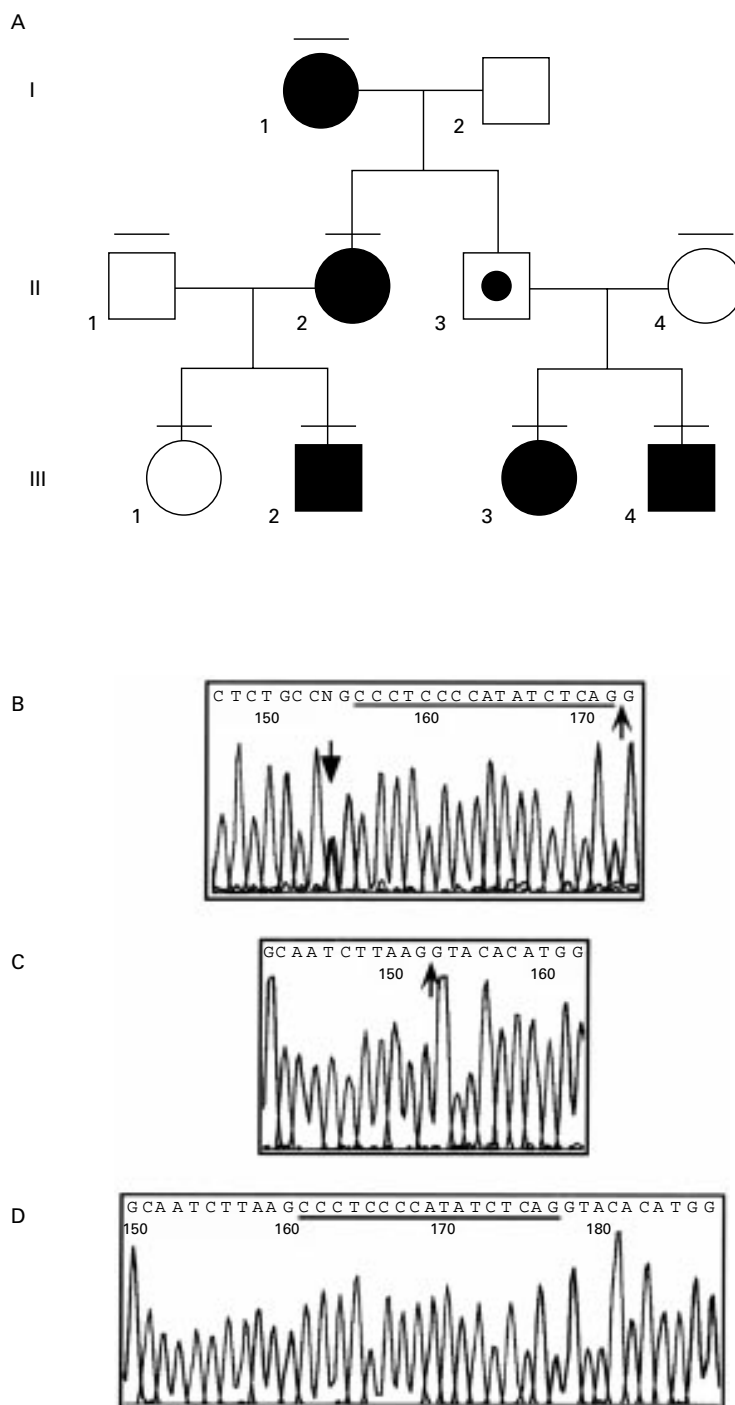


Figure 1 Pedigree and mutation analysis of family 3. (A) Pedigree. Horizontal bars indicate the family members personally examined. The phenotype of II.3 is not known. (B-D) Electrophoretograms of the detected mutations and control. (B) Heterozygous mutation IVS2-19T>A (arrow pointing downwards) detected in all examined affected family members (I.1, II.2, III.2) but not in the unaffected members. The arrow pointing upwards indicates the boundary between intron 2 and exon 3. (C) DNA sequence of the subcloned RT-PCR product of the wild type allele spanning from exon 2 to exon 3 (the arrow indicates the boundary). (D) DNA sequence of the subcloned RT-PCR product of the mutant allele shows an insertion of 17 bp derived from intron 2 (underlined in top and bottom pictures) between exon 2 and exon 3 derived sequences.

II.1, II.2 (patient 5, fig 1A), III.1, and III.2 (patient 3, fig 1A). No mutation was found in the whole *SALL1* coding region. However, within the intron 2 sequence, a heterozygous transition IVS2-19T>A (fig 1B) was found in III.2, and subsequently in I.1 and II.2, but not in the unaffected family members. This mutation was predicted to create an aberrant splice acceptor site. By comparing the surrounding sequences of the aberrant and the normal intron 2 splice acceptor site to consensus sequences,⁷ it was estimated that the aberrant splice site was as likely to be

functional as the normal site. The mutation was excluded in 200 control alleles.

In order to test if the mutation indeed created a functional splice site, lymphoblastoid cell lines of patients II.2 and III.2 were examined by RT-PCR. In both patients, direct sequencing of RT-PCR products showed an identical pattern of two different overlapping sequences indicating that both the mutated and the normal transcript were present in similar amounts. Sequencing of the subcloned RT-PCR fragments showed the wild type allele (fig 1C) and

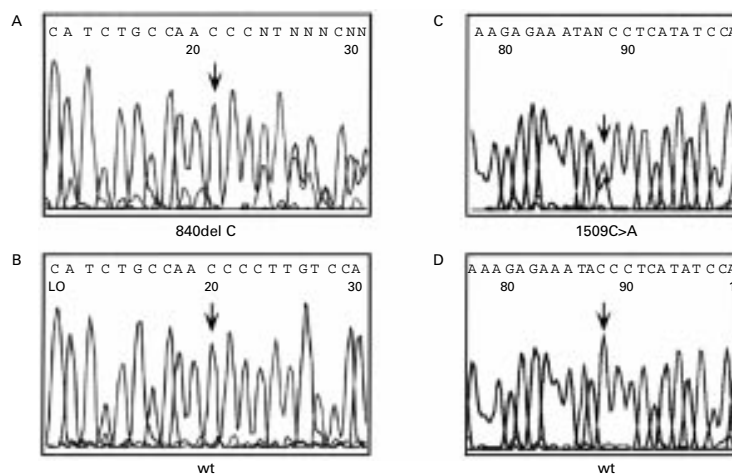


Figure 2 (A, C) Electrophoretograms (direct sequencing) of the heterozygous mutations 840delC (A) detected in family 1 and 1509C>A detected in family 2 (C). Corresponding wild type sequences are shown below (B, D).

a mutated allele (fig 1D) carrying an insertion of 17 bp derived from intron 2 sequence between the aberrant and the normal splice acceptor sites. It is placed within the coding region for the most carboxy-terminal double zinc finger between exon 2 and exon 3 sequences (fig 1B-D fig 3). The frameshift resulting from the insertion is further predicted to cause premature termination of the SALL1 protein (1208 amino acids instead of 1324 in the wild type).

In addition to the mutations reported here, the following polymorphisms were detected in *SALL1*: IVS1+119G>A, IVS1+118C>G, IVS1+36delAC (all intron 1), 2574T>C, 3456C>T (both exon 2), IVS2-31delCT (intron 2), 3872A>G (N1291S), and 3915C>T (exon 3). The intronic polymorphisms occurred in more than 10% of all subjects (affected and unaffected) analysed for *SALL1* mutations by our group. The exonic mutation N1291S is thought to be silent since it was found in two unaffected persons. The other exonic variations do not affect translation and are not segregating with the phenotype. Since the exonic sequence variations have only rarely been found, it is as yet unclear if they represent true polymorphisms or rare sequence variants.

All *SALL1* mutations previously reported in TBS reside in exon 2, 5' of the coding region for the first double zinc finger domain (fig 3), and are predicted to result in *SALL1* haploinsufficiency.⁴ Nonsense mutations seem to occur less frequently than small deletions, and both known nonsense mutations were found independently in two and three families indicating the existence of two hotspots at nucleotides 826 (mutated in three families) and 1115 (mutated in two families). In contrast, *SALL1* small deletions as a group occur more often but they seem to represent private mutations only.⁴

840delC is yet another short deletion located 5' of the coding region for the first double zinc finger domain (fig 3).

The phenotype of the patient carrying this mutation is typical for TBS, that is, he shows anal, ear, and thumb malformations. Interestingly, this man also shows acute optic neuropathy. While this has not been reported so far in TBS, this might represent another rare feature of the syndrome.

The two other mutations described in this report are the first *SALL1* mutations located 3' of the region where all previously known mutations cluster. The 1509C>A mutation is neighbouring the 3' end of the double zinc finger 1 coding region (fig 3). While this mutation could result in a prematurely terminated *SALL1* protein lacking double zinc finger domains 2-4, it is still unclear if the mutated transcript remains stable and the corresponding protein is indeed expressed. Therefore, this mutation could well result in haploinsufficiency if the mutated transcript is readily degraded. This mutation is the third nonsense mutation detected so far in *SALL1*, and it is the first one to be found in a family with dominant transmission since all other nonsense mutations known so far have been detected as de novo mutations in patients with severe features of TBS.⁴ Interestingly, one of the parents carries the mutation in the germline but not in lymphocytes. Yet the parental origin of the mutation needs to be determined in order to explain if the anteriorly placed anus seen in the mother could also reflect the presence of the mutation in other tissues. However, it is clear that the preaxial polydactyly reported in the father's family cannot be related to the mutation which caused TBS in his children.

The most interesting mutation shown here is IVS2-19T>A (fig 1B-D). We were able to show that the predicted transcript resulting from aberrant splicing is indeed expressed. While quantitative PCR has not been performed, direct sequencing of the RT-PCR products indicates that the aberrant transcript is as abundant as the normal one. It seems therefore that splicing of the mutated

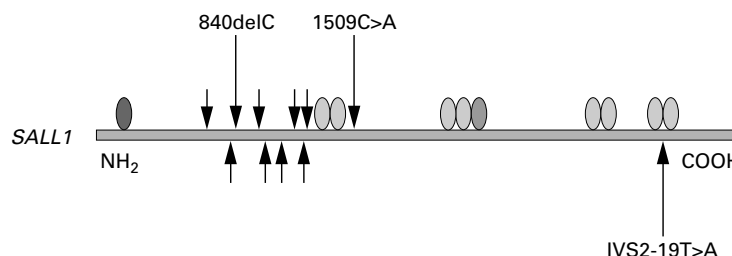


Figure 3 Position of the mutations reported here. 840delC is located within the region where all other mutations reported so far are clustered (small arrows). Note that 1509C>A and IVS2-19T>A are located 3' of this region. IVS2-19T>A leads to an insertion within the region encoding double zinc finger 4. Zinc finger motifs are indicated as oval symbols.

primary transcript occurs preferentially if not completely at the aberrant splice site. The predicted protein encoded by the mutated transcript contains intact coding sequences for all double zinc finger domains except for the double zinc finger 4 in which the carboxy-terminal finger motif is interrupted. How this mutation might lead to the phenotype remains to be elucidated. It has previously been shown in the *Drosophila* transcription factor *Krüppel* that a missense mutation replacing one of the conserved cysteine residues within the second of five tandemly arranged finger motifs results in a null allele.⁸ Therefore, the splice mutation reported here is likely to result in loss of biological function of the most carboxy-terminal double zinc finger domain. It remains unclear if this is sufficient to result in *SALL1* haploinsufficiency causing TBS. The predicted mutant protein is 116 amino acids shorter than the wild type protein and contains different carboxy-terminal amino acids because of the frameshift. An alternative explanation for the effect of the mutation could therefore be that the changed three dimensional structure of the mutated protein results in a non-functional *SALL1* protein which is unstable or not able to bind to its target sequences.

The phenotype of the severely affected family members reported here is not significantly different from other TBS cases in which classical truncating mutations were found. Therefore, we assume that all mutations shown in this report will lead to haploinsufficiency for *SALL1*, as suggested to be the common result of all mutations previously reported.⁴

Data access: GenBank: <http://www.ncbi.nlm.nih.gov/>. Accession numbers: Y18264 (*SALL1* exon 1 and intron 1 genomic sequence (partial)), Y18265 (full *SALL1* coding sequence), X98833 (*SALL1* genomic sequence of intron 1 (partial), exons 2 and 3 and intron 2). Mutation accession numbers (Human Genetics Online Mutation Data Submission): H971415 (840delC), H971417 (IVS2-19T>A). Online Mendelian Inheritance in Man (OMIM): <http://www.ncbi.nlm.nih.gov/OMIM/> (for Townes-Brocks syndrome, OMIM 107480). We thank all the patients and their families participating in this study for their

cooperation and patience. We especially thank Gudrun Essers for EBV transformation, Mareike Hausmann for technical assistance, and Susanne Herlt, Sabine Buth, and René Heise for DNA preparation and sequencing. This work was funded by the Wilhelm Sander-Stiftung (grant No 98.075.1 to JK). The first two authors contributed equally to this work.

CHRISTOPHER BLANCK*
JÜRGEN KOHLHASE*
SASKIA ENGELS*
PETER BURFEIND*
WOLFGANG ENGEL*
ARMAND BOTTANI†
MILLAN S PATEL‡
HESTER Y KROES§
JAN M COBBEN¶

*Institut für Humangenetik, Universität Göttingen, Heinrich-Düker-Weg 12, D-37073 Göttingen, Germany

†Division of Medical Genetics, University of Geneva, Geneva, Switzerland

‡Division of Clinical and Metabolic Genetics, The Hospital for Sick Children, University of Toronto, Toronto, Ontario, Canada

§Department of Medical Genetics, University of Groningen, Groningen, The Netherlands

¶Department of Clinical Genetics, Free University Hospital, Amsterdam, The Netherlands

Correspondence to: Dr Kohlhasse, jkohlha@gwdg.de

- 1 Townes PL, Brocks ER. Hereditary syndrome of imperforate anus with hand, foot and ear anomalies. *J Pediatr* 1972;8:321-6.
- 2 Powell CM, Michaelis RC. Townes-Brocks syndrome. *J Med Genet* 1999;36:89-93.
- 3 Kohlhasse J, Wischermann A, Reichenbach H, Froster U, Engel W. Mutations in the *SALL1* putative transcription factor gene cause Townes-Brocks syndrome. *Nat Genet* 1998;18:81-3.
- 4 Kohlhasse J, Taschner PEM, Burfeind P, et al. Molecular analysis of *SALL1* mutations in Townes-Brocks syndrome. *Am J Hum Genet* 1999;64:435-45.
- 5 Kohlhasse J, Schuh R, Dowe G, et al. Isolation, characterization, and organ-specific expression of two novel human zinc finger genes related to the *Drosophila* gene spalt. *Genomics* 1996;38:291-8.
- 6 Neitzel H. A routine method for the establishment of permanent growing lymphoblastoid cell lines. *Hum Genet* 1986;73:320-6.
- 7 Krawczak M, Reiss J, Cooper DN. The mutational spectrum of single base-pair substitutions in mRNA splice junctions of human genes: causes and consequences. *Hum Genet* 1992;90:41-54.
- 8 Redemann N, Gaul U, Jäckle H. Disruption of a putative Cys-zinc interaction eliminates the biological activity of the *Krüppel* finger protein. *Nature* 1988;332:90-2.

J Med Genet 2000;37:307-309

Genotype-phenotype correlation in three homozygotes and nine compound heterozygotes for the cystic fibrosis mutation 2183AA→G shows a severe phenotype

EDITOR—Cystic fibrosis (CF) is the most common lethal childhood disorder in white populations and occurs at a frequency of about 1/2500 with regional variations. Over 1000 mutations in the CF transmembrane conductance regulator (*CFTR*) gene accounting for the disease have been identified so far and the most common gene mutation is $\Delta F508$.¹ The frameshift mutation 2183AA→G in exon 13 was first described in three Canadian CF patients² and later was shown to have a significant frequency in patients from mid and southern Europe. The frequency among CF patients is 9.3% in north east Italy,³ 2.4% in the Tyrol,⁴ 1-2.1% in Belgium,³ 1.8% in Greece,⁵ 1% in Bavaria, Bulgaria, and France,³ and 0.4% in mid and northern Germany.⁶ We identified three homozygotes among 120 Turkish patients (2.5%), two born to first cousin parents, three compound heterozygotes among 185 Bulgarian patients (0.8%), and seven compound heterozygotes among 650 Spanish patients (0.5%).⁷ The mutation was detected by denaturing gradient gel electrophoresis or sin-

gle strand conformational analysis followed by DNA sequence analysis.

We report here the genotype-phenotype correlation in 12 patients with CF with the mutation 2183AA→G (three homozygous and nine compound heterozygous for 2183AA→G and other mutations). The anamnestic, clinical, and laboratory data are summarised in table 1. Pancreatic insufficiency (PI) was assessed by the fat content of stools and requirement of pancreatic enzyme replacement therapy. Gastrointestinal symptoms (GI) are abdominal cramps and pain and frequent passage of foul and fatty faeces. The presence of pulmonary symptoms was defined as having at least one of the following clinical findings: increased rate of breathing, wheezing, dark coloured/profuse sputum, and recurrent attacks of coughing. Dehydration includes at least one of the following: decreased skin tonus and turgor, decreased output of urine, and sudden weight loss. The presence of bronchiectasis was evaluated by chest x rays and thin section computerised chest tomography.

Patient 1 was homozygous for 2183AA→G. She was admitted to hospital at 2 months of age and died within a week. Clinical findings were clearly of CF with pancreatic insufficiency. The second homozygous patient (patient 2) was examined for CF because all his four sibs had died of the disease before the age of 1 year. He had pulmonary insufficiency at 15 days. He had fatty and foul stools, bronchial hyperactivity, and early *Pseudomonas* colonisation. As a result of medical treatment, he no longer has steatorrhea

Table 1 Anamnesic, clinical, and laboratory data for CF patients carrying the mutation 2183AA→G

Patient No	1	2	3	4	5	6	7	8	9	10	11	12
Nationality	Turkish	Turkish	Turkish	Bulgarian	Spanish	Spanish	Spanish	Spanish	Spanish	Spanish	Bulgarian	Bulgarian
Second CF mutation	2183AA→G	2183AA→G	2183AA→G	ΔF508	ΔF508	ΔF508	ΔF508	ΔF508	G542X	G542X	G1244E	2789+5G→A
Sex	F	M	M	F	M	F	M	M	F	F	F	F
Onset of symptoms	25 d	15 d	2 mth	At birth	3 mth	1 mth	At birth	ND	ND	ND	3 mth	2 mth
Meconium ileus	No	No	No	Yes	No	No	Yes	No	No	No	No	No
Disease progression	Died 2 mth	Severe	Severe	Died 1 mth	Moderate	Moderate	Severe	Moderate	Moderate	Moderate	Died 12 y	Severe
No of affected sibs	0	4	1	0	0	1 (11 y)	0	1 cousin	0	0	0	0
Disease progression for CF sibs	—	All died <1 y	Died 10 mth	—	—	Moderate	—	ND	—	—	—	—
<i>Data at diagnosis</i>												
Age at diagnosis	2 mth	15 d	4 mth	At birth	3 mth	1 mth	2 mth	3 mth	4 y	1 y	3 mth	2 mth
Sweat Cl ⁻ (mEq/l)	ND	99	80	ND	100	100	100	90	93	110	132	130
Pancreatic insufficiency	Yes	Yes	Yes	Yes	Yes	Yes	Yes	Yes	Yes	Yes	Yes	Yes
Failure to thrive	Yes	Yes	Yes	Yes	Yes	Yes	No	Yes	Yes	Yes	Yes	No
Gastrointestinal symp	Yes	Yes	Yes	Yes	Yes	No	Yes	Yes	Yes	Yes	Yes	No
Pulmonary symp	Yes	Yes	Yes	Yes	No	No	Yes	Yes	No	No	Yes	Yes
Dehydration	Yes	No	No	No	No	Yes	Yes	No	No	No	No	No
<i>Data at latest visit</i>												
Age	2 mth	7.5 y	7 y	—	2 y 6 mth	6 y	8 y	14 y	14 y	3 y 6 mth	12 y	7 y
Weight centile	3	25–50	25	—	ND	<3	ND	10–25	ND	ND	10–25	ND
Lung colonisation with bacterial pathogens	—	Pa*	Pa	—	No	No	Pa	Pa	No	No	Pa, Sa	No

*Before medication. ND = not determined. Pa = *Pseudomonas aeruginosa*. Sa = *Staphylococcus aureus*.

or *Pseudomonas* infection. The third homozygous patient (patient 3) was diagnosed early because his brother died of similar clinical findings at the age of 10 months. The clinical symptoms were gastrointestinal and pulmonary; in addition, vitamin deficiency, malnutrition, and severe anaemia (probably resulting from severe vitamin A deficiency) were observed. At present, he has early *Pseudomonas* colonisation, steatorrhoea, recurrent lung problems, and malnutrition.

The remaining nine patients are all compound heterozygotes. Patients 4–8 carry ΔF508 as the other CF allele. Patients 4 and 7 were diagnosed with meconium ileus. Other clinical data available for patient 4 are malnutrition, chronic respiratory insufficiency, and steatorrhoea. Patient 7 also has β thalassaemia. Patient 8 has bronchiectasis. Patients 9 and 10 carry the nonsense mutation G542X⁸ on the other CFTR chromosome. Patient 9 has hepatomegaly, probably resulting from nutritional deficiency. Patient 10 was first diagnosed as having coeliac disease, then CF as well, and also has anorexia. Patient 11 carried the missense mutation G1244E⁹ on the other CFTR chromosome. Pancreatic insufficiency was confirmed by a fat load test, which showed a poor rise in the plasma triglyceride level and an excretion of 60 mmol/day (normal is 20 mmol/day). An ultrasound examination of the liver showed a normal sized liver with markedly increased echogenicity, suggesting hepatic involvement. The enlarged portal vein had a diameter of 12 mm and the spleen and kidneys were normal. A chest radiograph showed widespread peribronchial thickening with interstitial markings, but there were no areas of atelectasis, and in general the changes were not severe. Two years later the chest radiograph showed a quite marked deterioration with much more widespread bronchiectatic changes. Patient 12 has 2789+5G→A, a splice site mutation,¹⁰ on the other CFTR chromosome. She has recurrent respiratory infections.

The mutation 2183AA→G causes premature termination of translation 38 codons downstream on exon 13. The clinical data presented for three patients homozygous for the mutation and eight compound heterozygous patients who carry a severe mutation (ΔF508, G542X, and G1244E) on the other CFTR chromosome indicate that the mutation causes a severe CF phenotype. Severe pancreatic insufficiency is the most common clinical feature, being exhibited by all these 11 patients. Pancreatic insufficiency had also been reported for all three Canadian compound heterozygous patients.² Current moderate progression of the disease in some of these patients is probably the result of treatment with pancreatic enzyme supplements and antibiotics. The disease phenotype is also severe in the compound heterozygote with the mutation 2789+5G→A. It has been shown that this mutation has a mild phenotype which allows synthesis of some normal mRNA.¹⁰

The phenotype of the mutation 2183AA→G was assessed to be severe with pancreatic involvement, failure to thrive, and variable lung involvement (9/12 patients). In 5/10, colonisation with bacterial pathogens was observed. Two patients died too young (1–2 months) for bacterial colonisation to be assessed. Two of the ΔF508/2183AA→G patients had meconium ileus. The mutation may cause various other complications, with two patients exhibiting hepatic involvement and two bronchiectasis. All patients studied were diagnosed very early. Grouping the patients and their sibs together, six homozygotes died within the first year of life and two compound heterozygotes died at the ages of 1 month and 12 years.

In most of our heterozygous patients, the CFTR gene was only partially screened for mutations using either DGGE or SSCP. Thus, it is possible but unlikely that some

of these patients carry a third CF mutation. Spanish and Turkish patients were analysed for the IVS8-6(T) alleles¹¹ and the mutation 2183AA→G was found to be associated with the allele 7T, except in patients 1 and 3, who were homozygous for the allele 9T. Spanish and Turkish patients were also studied for the microsatellite loci IVS8CA, IVS17bTA, and IVS17bCA.¹²⁻¹⁴ While all six Spanish patients shared the same haplotype (16-30-13) for the mutation 2183AA→G, Turkish patients were homozygous for two other haplotypes, 16-31-13 (patients 1 and 3) and 16-32-13 (patient 2). These three haplotypes are among the most common on normal chromosomes¹⁵ and each can be derived from any of the other two. Alternatively, the mutation may have arisen independently in the two populations or even within the Turkish population. Despite the possible heterogeneous genetic background observed, in particular between the homozygous patients, the severity of the disease is similar.

The authors thank the European Community Concerted Action for the Coordination of Cystic Fibrosis Research and Therapy for providing the DGGE and sequencing oligonucleotide primers for the analysis of Spanish and Turkish patients. The work on Spanish patients was supported by FISS 96/2005 and Institut Catala de la Salut. The work on Turkish patients was supported by the Scientific and Technical Research Council of Turkey, The Academy of Sciences of Turkey, and Bogaziçi University Research Fund.

M O KILINÇ*	F ÖZKINAY**
V N NINIS*	E DEMİR**
A TOLUN*	J L SECULI††
X ESTIVILL†	J PENA‡‡
T CASALS†	C BOUSONOS§§
A SAVOV‡	J FERRER-CALVETE¶¶
E DAGLI§	C CALVO***
F KARAKOÇ§	G GLOVER†††
M DEMIRKOL¶	I KREMENSKI‡‡‡
G HÜNER¶¶	

*Department of Molecular Biology and Genetics, Bogaziçi University, Bebek 80815 Istanbul, Turkey

†Genetics Department, IRO, Barcelona, Spain

‡Laboratory of Molecular Pathology, University Obstetrics and Gynecology Hospital, Sofia, Bulgaria

§Pediatrics, Marmara University Hospital, Istanbul, Turkey

¶Nutrition and Metabolic Disorders Division, Istanbul University Medical School, Istanbul, Turkey

**Pediatrics, Aegean University Medical School, Izmir, Turkey

††Cystic Fibrosis Unit, Pediatrics Service, Hospital S Juan Deu, Barcelona, Spain

‡‡Pediatric Service, Hospital General, Santiago Compostela, Spain

§§Pediatric Service, Hospital Central, Oviedo, Spain

¶¶Gastroenterology Service, Hospital La Fe, Valencia, Spain

***Pediatric Service, Hospital Clínico, Valladolid, Spain

†††Centro Bioquímica Espinardo, Murcia, Spain

‡‡‡Laboratory of Molecular Pathology, Medical University, Sofia, Bulgaria

Correspondence to: Dr Tolun, tolun@boun.edu.tr

- Cystic Fibrosis Genetic Analysis Consortium. www.genet.sickkids.on.ca
- Bozon D, Zielenski Z, Rininsland F, Tsui L.C. Identification of four new mutations in the cystic fibrosis transmembrane conductance regulator gene: I148T, L1077P, Y1092X, 2183AA→G. *Hum Mutat* 1994;3:330-2.
- Cystic Fibrosis Genetic Analysis Consortium. Population variations of common cystic fibrosis mutations. *Hum Mutat* 1994;4:167-77.
- Stuhrmann M, Dörk T, Frühwirth M, et al. Detection of the 100% of the CFTR mutations in 63 CF families from Tyrol. *Clin Genet* 1997;52:240-6.
- Tzetis M, Kanavakis E, Antoniadis T, et al. Characterization of more than 85% of cystic fibrosis alleles in the Greek population, including five novel mutations. *Hum Genet* 1997;99:121-5.
- Dörk T, Mekus F, Schmidt K, et al. Detection of more than 50 different CFTR mutations in a large group of German cystic fibrosis patients. *Hum Genet* 1994;94:533-42.
- Casals T, Ramos MD, Gimenez J, et al. High heterogeneity for cystic fibrosis in Spanish families: 75 mutations account for 90% of chromosomes. *Hum Genet* 1997;101:365-70.
- Kerem BS, Zielenski J, Markiewicz D, et al. Identification of mutations in regions corresponding to the two putative nucleotide (ATP)-binding folds of the cystic fibrosis gene. *Proc Natl Acad Sci USA* 1990;87:8447-51.
- Devoto M, Ronchetto P, Fanen P, et al. Screening for non delta508 mutations in 5 exons of the CFTR gene in Italy. *Am J Hum Genet* 1991;48:1127-32.
- Highsmith WE, Lauranell HB, Zhaoqing Z, et al. Identification of a splice site mutation (2789+5G→A) associated with small amounts of normal CFTR mRNA and mild cystic fibrosis. *Hum Mutat* 1997;9:332-8.
- Chu CS, Trapnell BC, Currustin S, et al. Genetic basis of variable exon 9 skipping in cystic fibrosis transmembrane conductance regulator mRNA. *Nat Genet* 1993;3:151-6.
- Morrall N, Nunes V, Casals T, et al. CA/TA microsatellite alleles within the cystic fibrosis transmembrane conductance regulator (CFTR) gene are not generated by unequal crossing over. *Genomics* 1991;10:692-8.
- Morrall N, Girbau E, Zielenski J, et al. Dinucleotide (CA/GT) repeat polymorphism in intron 17B of the cystic fibrosis transmembrane conductance regulator (CFTR) gene. *Hum Genet* 1992;88:356.
- Zielenski J, Rozmahel R, Bozon D, et al. Genomic DNA sequence of the cystic fibrosis transmembrane conductance regulator (CFTR) gene. *Genomics* 1991;10:214-28.
- Morrall N, Nunes V, Casals T, et al. Microsatellite haplotypes for cystic fibrosis: mutation frameworks and evolutionary tracers. *Hum Mol Genet* 1993;2:1015-22.

J Med Genet 2000;37:309-312

Alkaptonuria in Italy: polymorphic haplotype background, mutational profile, and description of four novel mutations in the homogentisate 1,2-dioxygenase gene

EDITOR—Alkaptonuria (AKU, OMIM 203500) is a rare disorder caused by the deficiency of homogentisate 1,2 dioxygenase (HGO, EC 1.13.11.5).¹ HGO catalyses the conversion of homogentisate (HGA) to maleylacetoacetate in the phenylalanine/tyrosine catabolic pathway.² As a consequence, affected subjects excrete HGA in their urine, which becomes dark upon exposure to air. The medical interest in this condition stems from its association with ochronosis, or the deposition of a brownish pigment in connective tissues including cartilage, where its accumulation can produce a debilitating degenerative joint disease.³

AKU occupies a unique place in the history of human genetics because it was the first disorder to be described as a Mendelian recessive trait.⁴⁻⁶ Recent advances in the understanding of the molecular basis of AKU⁷⁻⁹ have verified that loss of function mutations in the HGO gene are

responsible for the disease. A few mutations have been repeatedly detected in patients from different European countries. Since these mutations segregated with specific haplotypes, they should be considered to be old mutations that have spread throughout western Europe with migration. However, allelic heterogeneity is the main feature emerging from the above and other studies.⁷⁻¹² Most HGO mutations were found in just one family and did not involve CpG dinucleotides. Rather, a preferential occurrence in the CCC sequence motif and its inverted complement GGG has recently been reported.¹² Furthermore, some AKU chromosomes escaped mutation detection within the HGO coding region, suggesting the existence of HGO alleles whose defect might be related to gene expression.

To determine the extent of allelic heterogeneity in Italian patients, we started a systematic search of AKU families through announcements at relevant National Congresses. We present here the results leading to the identification of four novel mutations. Our data should facilitate future mutation screening in Italian AKU patients and carrier identification by DNA typing.

Ten affected subjects from five unrelated Italian AKU pedigrees were included in the study. In three families it turned out that the patients' parents were consanguineous. Three patients were diagnosed at birth as having AKU through analysis of homogentisic aciduria. The remaining

Table 1 PCR primers for nested PCR analysis of HGO cDNA from blood lymphocytes

Forward primer		Reverse primer	PCR product (bp)
HTEL	GCAGTGAAGCAGTGGGAACC	HTEP	1556
HS1L	GTGGCTTTATATCCTCTGGG	HS9	258
HS4	CTTGTCACGGAGCACC	HS7	290
HS6	CCTCTGCAATACCTCCATGG	HS3F	278
HS8	GCCAATGGCTTGGCCAATCC	HS12	291
HS11F	TTGACTGTAAAGTCTGTCCG	HS10	288
HS13	ATGACCTGTATGCTGACTGC	HS5	314

cases were diagnosed in adulthood on the basis of clinical and radiological examination. Seventeen normal relatives were also investigated. Both genomic DNA and HGO cDNA were obtained from peripheral blood by standard methods.

RNA was extracted from peripheral blood lymphocytes by the guanidinium thiocyanate-phenol-chloroform method.¹³ cDNA synthesis was performed using both oligo dT and specific primer mapping in the 3'UTR of the HGO gene. From the complete sequence of a human HGO cDNA (AF045167), primers were designed to obtain overlapping amplicons spanning the entire coding sequence of the HGO gene by nested PCR, as described previously.^{14, 15} Primers HTEL and HTEP were used in the first PCR, whereas each of the primer pairs HS1L/HS9, HS4/HS7, HS6/HS3F, HS8/HS12, HS11F/HS10, HS13/HS5 were used in the second PCR. The primer sequences and the expected lengths of the PCR products are shown in table 1.

SSCP analysis was performed according to Orita *et al.*¹⁶ PCR products were heat denatured and subjected to electrophoresis on a non-denaturing 6% polyacrylamide gel and silver stained.¹⁷ All cases were amplified starting from differently obtained cDNA preparations and run independently at least twice with consistent results.

Genomic DNA was used to amplify the exons included in the cDNA regions where abnormal SSCP patterns were found. Moreover, failure to detect mutations in three families necessitated that the genetic lesions were sought at the genomic level by SSCP screening of each exon amplified with intron primers.⁹ PCR products were purified by column filtration and sequenced directly with a dye terminator cycle sequencing kit (ABI PRISM Perkin Elmer, Norwalk, USA) using the ABI 377 automated sequencer (Applied Biosystems, Foster City, USA) and its associated analysis software.

Three intragenic STRs, HGO-1 (D3S4496, intron 4), HGO-2 (D3S4497, intron 13), and HGO-3 (D3S4556, intron 4), have been described previously^{8, 9} and were analysed by PCR with modifications to comply with non-isotopic detection. The PCR products were run on denaturing 6-8% polyacrylamide gels and the alleles were visualised by silver staining. The alleles were numbered consecutively and sized by comparison with known samples. Four SNPs, IVS2+35T/A, IVS5+25T/C, IVS6+46C/A, and c407T/A (exon 4), have also been described⁹ and were studied by SSCP on non-denaturing 8% polyacrylamide gel electrophoresis followed by silver staining. Genotype assignment was made possible by comparison with known

samples. Familial segregation provided unequivocal derivation of the haplotypes present on the AKU chromosomes.

Five additional unrelated AKU families were analysed for mutations and polymorphisms in the HGO gene. The IVS9-56G→A and IVS9-17G→A HGO mutations in one Italian patient have already been described.⁹ Therefore, the mutations found in 12 AKU chromosomes of Italian ancestry are presented here (table 2). Since consanguineous marriage occurred in three families, only nine chromosomes may be considered to be independent in origin. In fact, patients from these families were homozygous for the AKU mutations G152fs (c621insG), G270R (c975G→A), and G360R (c1245G→C), respectively. The AKU patients in another family were compound heterozygotes for K248R (c909A→G) and IVS7+5G→A (c636+5G→A). Finally, in family VRN, the AKU patient is most likely a compound heterozygote for G360R and an as yet unknown HGO mutation. Therefore, as many as eight different HGO mutations were found, four of which were novel. We also anticipate that the AKU mutation that remains to be identified will be novel (table 2) because we know that it is different from all previously characterised AKU mutations. We provisionally denoted this mutation as VRN. Three of the four novel mutations (K248R, G270R, and G360R) are missense mutations that affect HGO amino acid residues that are conserved in different species and are likely to be loss of function mutations. K248R is the consequence of an A to G transition at position c909 in exon 10, G270R results from a G to A transition at position c975 in exon 11, and G360R is caused by a G to C transversion at position c1245 in exon 13. This latter mutation was found twice in two unrelated patients. The other novel AKU mutation (IVS7+5G→A) is a G to A transition in the fifth nucleotide position of the donor (5') splice site sequence of intron 7, which most likely causes aberrant splicing of HGO. None of these four novel AKU mutations were observed, using SSCP screening, in a sample of 100 control chromosomes. Finally, the mutation G152fs originated from a one base insertion at position c621, which determined a frameshift eventually leading to premature arrest of the protein synthesis. This same mutation was described in two Slovak families.¹⁰ Although the loss of function nature of all these HGO mutations was not formally proven, SSCP and sequence analysis of the relevant DNA fragment in family members confirmed in all cases that the pattern of inheritance of AKU was compatible with the segregation of the HGO mutations.

Table 2 HGO mutations and haplotypes identified in Italian AKU patients

Mutation	Type	Nucleotide change*	Associated polymorphisms†	No	Reference
G152fs	Frameshift	c621insG	T T 191 161 T C 187	1	10
IVS7+5G→A	Intron change	c636+5G→A	A T 199 161 T C 187	1	This study
IVS9-56G→A	Intron change	c817-56G→A	A T 195 161 T C 181	1	9
IVS9-17G→A	Intron change	c817-17G→A	A T 189 161 T C 191	1	9
K248R	Missense	c909A→G	A T 197 161 T A 171	1	This study
G270R	Missense	c975G→A	T T 195 161 T C 187	1	This study
G360R	Missense	c1245G→C	A A 193 161 T C 197	2	This study
VRN	Unknown	Unknown	A T 193 163 C A 189	1	This study

*Positions of nucleotide changes are from the transcription start site (AF045167).

†The alphanumerical strings represent the haplotypes formed by the following HGO intragenic markers: IVS2+35T/A, c407T/A, HGO-3, HGO-1, IVS5+25T/C, IVS6+46C/A, HGO-2.

We managed to perform SSCP analysis of cDNA fragments from two families, one where the G360R mutation was segregating and the other where the patients were compound heterozygotes for the K248R and the IVS7+5G→A mutations. It is interesting to note that this latter supposedly splice site mutation did not affect the SSCP pattern of the cDNA amplicon defined by primer pair HS6/HS3F spanning exons 7 to 9. Furthermore, IVS7+5G→A seemed to have no influence on *HGO* mRNA stability, as judged by the presence of both wild type and mutant bands in the cDNA amplicon defined by primer pair HS8/HS12 containing the K248R site.

In the light of the recent report of a preferential occurrence of *HGO* mutations in the CCC/GGG sequence motifs,¹² we analysed the sequence context of the four novel mutations found in the present work. It could not be coincidental that G270R and G360R mutations take place in tri- and penta-G runs, respectively. Moreover, the G152fs mutation previously described in two Slovak families¹⁰ occurs in a tetra-G run. Whether the G152fs mutation we found in an Italian family has an independent origin remains to be determined. Haplotyping of the Slovak pedigrees as well as comparison with the Italian one could provide strong evidence that the CCC/GGG motif is a mutational hot spot in *HGO*.

Table 2 also shows the haplotypes at the *HGO* intragenic markers IVS2+35T/A, c407T/A, HGO-3, HGO-1, IVS5+25T/C, IVS6+46C/A, and HGO-2 which are associated with each AKU chromosome. Analysis of the *HGO* haplotypes harbouring the purported causative AKU mutations showed that the three intronic mutations were found in a common haplotypic background composed of the very same alleles at four SNPs as well as at HGO-1. Beltrán-Valero de Bernabé *et al*⁹ referred to this as haplotype A, the most frequent in European populations. Two other mutations, G152fs and G270R, were detected in a gametic association, haplotype D,⁹ which is derived from haplotype A by variation at the SNP IVS2+35T/A. Closely related to haplotype A is also that segregating with mutation G360R and that harbouring the mutation K248R, haplotype B.⁹ These haplotypes differ from haplotype A at SNPs c407T/A and IVS6+46C/A, respectively. On the other hand, the mutation VRN was probably within the so-called haplotype E.⁹ It has been postulated⁹ that haplotype E has a North African origin, an ethnic component that is known to have contributed to the modern Italian population.¹⁸ Whether the VRN mutation has originated in Italy or has been introduced into this country with the different migrations is at present unknown.

Only two of the AKU mutations found in Italians (G152fs and IVS9-56G→A) have been encountered in patients from other European countries. One of them, as indicated before, is the G152fs mutation that was identified in two Slovak AKU pedigrees.¹⁰ It would be interesting to determine whether the G152fs mutation has an eastern European origin and appeared in Italy by migration. The IVS9-56G→A AKU mutation was also identified earlier in an AKU chromosome of a French patient.⁹ Interestingly the IVS9-56G→A mutation in the Italian and the French patients are associated with the same *HGO* haplotype. In this case, we postulate an Italian origin for this mutation since the French IVS9-56G→A carrier patient has Italian ancestors.

It is important to note that the mutations P230S, V300G, and M368V, which are relatively common mutations,^{7 12 15 19} were absent in our patients. P230S and V300G are typically associated with haplotype E and are thought to be North African in origin.⁹ The M368V

mutation is widely distributed throughout Europe and is associated with haplotype A.⁹ It is also interesting that the mutation G360R was found twice within the same haplotype in two families from different ends of the Italian peninsula; patient VRN was from Calabria (southern Italy), whereas the affected sons of a consanguineous marriage were from South Tyrol, a German speaking region on the Austrian border. Additional *HGO* mutational and polymorphism analyses of AKU patients from many more different countries would be necessary to understand the population genetics of AKU and the migration of the different AKU alleles.

In conclusion, we report here an extensive description of the spectrum of AKU mutations in Italy, including the characterisation of their associated intragenic *HGO* polymorphisms. Four novel mutations were found, which include both missense mutations and subtle intronic changes. The Italian AKU sample confirms the high degree of allelic heterogeneity of the *HGO* gene and illustrates the complications of mutation screening in AKU patients. These data should facilitate the future identification of these AKU alleles in this and other populations.

Note added in proof

The mutation G270R has recently been described by Müller *et al* (*Eur J Hum Genet* 1999;7:645-51).

We thank Pier Luigi Mattiuz and Umberto Serni for encouragement and suggestions. We are also grateful to Alfredo Brusco and to Claudio Castellor for helping us to identify AKU patients and families. This work was supported in part by a grant from the University of Florence, MURST ex 60% funds, by the Fundación Jose Antonio de Castro, the Spanish Comisión Interministerial de Ciencia y Tecnología (SAF96/0055, SAF97/1789E), and the Comunidad de Madrid (08.6/0015/1997). In addition, this study is based on work supported by the Fundación Conchita Rábago de Jiménez Díaz under a grant awarded to DB-VdeB.

BERARDINO PORFIRIO*
ILARIA CHIARELLI*
CLAUDIO GRAZIANO*
ALESSANDRO MANNONI†
AMELIA MORRONE‡
ENRICO ZAMMARCHI‡
DANIEL BELTRÁN-VALERO DE BERNABÉ§
SANTIAGO RODRÍGUEZ DE CÓRDOBA¶

*Dipartimento di Fisiopatologia Clinica, Università degli Studi, Firenze, Italy

†Divisione di Reumatologia, Azienda Sanitaria Locale, Firenze, Italy

‡Dipartimento di Pediatria, Università degli Studi, Firenze, Italy

§Departamento de Inmunología, Centro de Investigaciones Biológicas, Consejo Superior de Investigaciones Científicas, Madrid, Spain

¶Unidad de Patología Molecular, Fundación Jiménez Díaz, Madrid, Spain

Correspondence to: Dr Porfirio, Department of Clinical Physiopathology, Human Genetics Unit, Viale G Pieraccini 6, I-50139 Florence, Italy, n.porfirio@dfc.unifi.it

- 1 La Du BN, Zannoni VG, Laster L, Seegmiller JE. The nature of the defect in tyrosine metabolism in alkaptonuria. *J Biol Chem* 1958;230:251-60.
- 2 Knox WE, Edwards SW. Homogentisate oxidase of liver. *J Biol Chem* 1955; 216:479-87.
- 3 La Du BN. Alkaptonuria. In: Scriver CR, Beaudet AL, Sly W, Valle D eds. *The metabolic and molecular bases of inherited disease*. New York: McGraw-Hill, 1995.
- 4 Garrod AE. The incidence of alkaptonuria: a study in clinical individuality. *Lancet* 1902;ii:1616-20.
- 5 Garrod AE. The Croonian lectures on inborn errors of metabolism. Lecture II. Alkaptonuria. *Lancet* 1908;ii:73-9.
- 6 Bateson W. *Mendel's principles of heredity*. Cambridge: Cambridge University Press, 1902.
- 7 Fernández-Cañón JM, Granadino B, Beltrán-Valero de Bernabé D, *et al*. The molecular basis of alkaptonuria. *Nat Genet* 1996;14:19-24.
- 8 Granadino B, Beltrán-Valero de Bernabé D, Fernández-Cañón JM, Peñalva MA, Rodríguez de Córdoba S. The human homogentisate 1,2-dioxygenase (*HGO*) gene. *Genomics* 1997;43:115-22.
- 9 Beltrán-Valero de Bernabé, Granadino B, Chiarelli I, *et al*. Mutation and polymorphism analysis of the human homogentisate 1,2-dioxygenase gene in alkaptonuria patients. *Am J Hum Genet* 1998;62:776-84.
- 10 Gehrig A, Schmidt SR, Müller CR, Srsen S, Srsnova K, Kress W. Molecular defects in alkaptonuria. *Cytogenet Cell Genet* 1997;76:14-16.
- 11 Higashino K, Liu W, Ohkawa T, *et al*. A novel point mutation associated with alkaptonuria. *Clin Genet* 1998;53:228-9.
- 12 Beltrán-Valero de Bernabé D, Jimenez FJ, Aquaron R, Rodríguez de Córdoba S. Analysis of alkaptonuria (AKU) mutations and polymorphisms reveals that the CCC sequence motif is a mutational hot spot in the homogentisate 1,2-dioxygenase gene (*HGO*). *Am J Hum Genet* 1999;64:1316-22.

- 13 Chomczynski P, Sacchi N. Single-step method of RNA isolation by acid guanidinium thiocyanate-phenol-chloroform extraction. *Anal Biochem* 1987;162:156-9.
- 14 Morrone A, Pegoraro E, Angelini C, Zammarchi E, Marconi G, Hoffmann EP. RNA metabolism in myotonic dystrophy: patient muscle shows decreased insulin receptor RNA and protein consistent with abnormal insulin resistance. *J Clin Invest* 1997;99:1691-8.
- 15 Ramos SM, Hernandez M, Roces A, et al. Molecular diagnosis of alkaptonuria mutation by analysis of homogentisate 1,2 dioxygenase mRNA from urine and blood. *Am J Med Genet* 1998;78:192-4.
- 16 Orita M, Suzuki Y, Sekiya T, Hayashi K. Rapid and sensitive detection of point missense mutations and DNA polymorphisms using the polymerase chain reaction. *Genomics* 1989;5:874-9.
- 17 Budowle B, Chakraborty R, Giusti AM, Eisenberg AJ, Allen RC. Analysis of the VNTR locus D1S80 by the PCR followed by high resolution PAGE. *Am J Hum Genet* 1991;48:137-44.
- 18 Piazza A, Cappello N, Olivetti E, Rendine S. A genetic history of Italy. *Ann Hum Genet* 1988;52:203-13.
- 19 Felber U, Mutsch Y, Grehn F, Müller CR, Kress W. Ocular ochronosis in alkaptonuria patients carrying mutations in the homogentisate 1,2 dioxygenase gene. *Br J Ophthalmol* 1999;83:680-3.

J Med Genet 2000;37:312-314

Rough skin, brittle hair, and photosensitivity: a mild phenotypic variant of trichothiodystrophy

EDITOR—The trichothiodystrophies (TTD) are named primarily for the hair sulphur deficiency which is their most specific feature and which leads to brittleness of the hair. Other ectodermal tissues may be affected and typically the skin is ichthyotic and the nails dystrophic. Additionally, there may be a distinctive facies and physical and developmental retardation of varying degree of severity. Inheritance is autosomal recessive and at least three loci exist, of which two are known, the excision repair/transcription factor genes *XPD/ERCC-2* and *XPB/ERCC-3*. We describe an 8 year old girl in whom the diagnosis of a mild and in some respects atypical form of TTD was made on the synthesis of clinical, pathological, and biochemical data. The genotypic basis of this clinical phenotype has yet to be established.

The patient was the second child of a dizygous twin pregnancy born to unrelated, healthy, white parents by emergency caesarean section at 32 weeks because of pre-eclampsia. The family history was unremarkable and her male co-twin was healthy. Birth weight was 2100 g (90th

centile for this gestation). Birth length and head circumference were 51.5 cm and 32.5 cm respectively. The skin was dry and flaky from birth (but never “collodion”), and in using a towel her mother had to pat her dry, rather than to rub. Thickening of the palms and soles developed in the first year of life. The nails were brittle from birth. Hair growth has always been slow and she has never had a proper haircut, only trims. Desquamated cells from the external auditory canal failed to clear and she has required periodic syringing.

She was referred to our service at 5 years of age because of concerns related to persistent dermatitis, dermal photosensitivity suggested by easy burning in the sun, mild developmental delay, and distinctive facial appearance. We noted the following features: hair that was “wiry” in texture, fragile, and easy to extract; abnormal scalp hair distribution with temporal recession; prominent forehead with sparse eyebrows (fig 1); a generalised dryness of the skin with areas of keratoderma; and brittle, spoon shaped fingernails and toenails. The keratoderma was particularly marked on the soles and palms (fig 2) and at the popliteal and antecubital flexures. Apart from congenital absence of the second premolars, the teeth were normal. Her weight was 27 kg (90th centile), height 128 cm (97th centile), and head circumference 54 cm (98th centile). These measurements are consonant with the parental heights and weights, which were in the 90th-97th centile range. She was attending a normal school and was in the appropriate class for



Figure 1 Patient aged 8 years. The hair is short (has only been trimmed) and stands up irregularly. There is temporal recession.

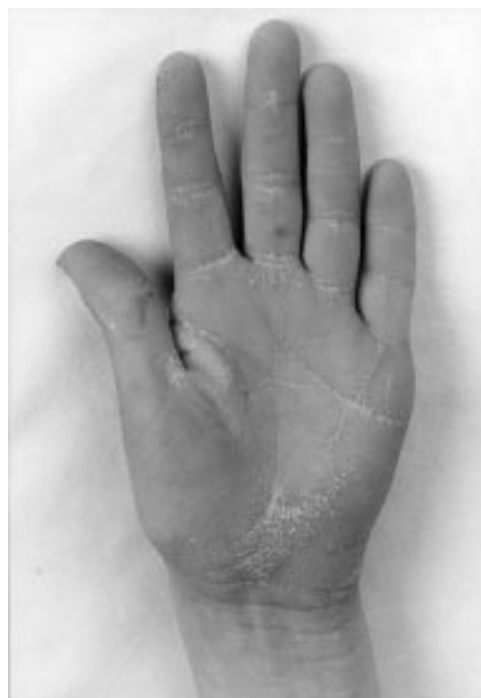

Figure 2 Palmar keratoderma.

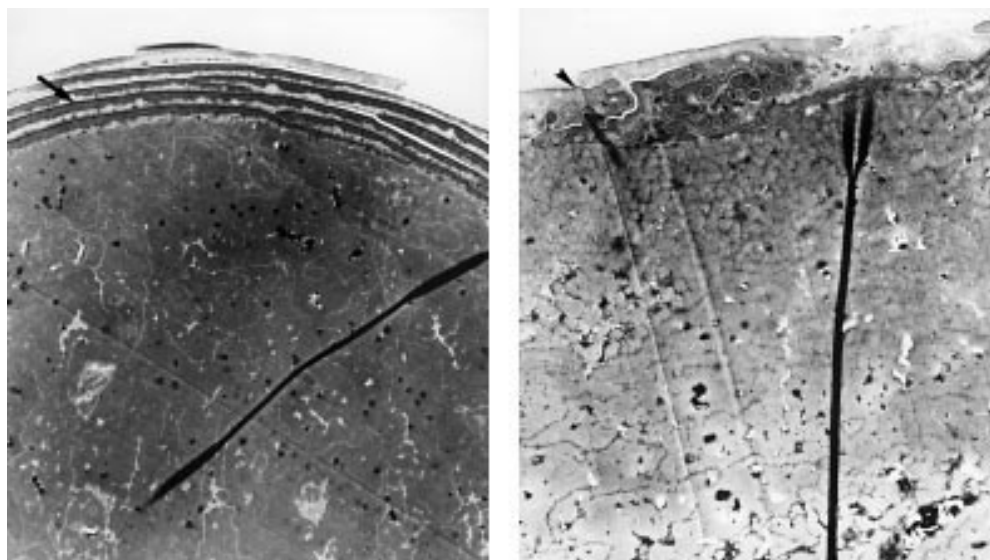


Figure 3 Cross section of hair shaft on transmission electron microscopy. (Left) Normal, showing central cortex and cuticle cell layers peripherally. The cuticle cells are elongated and show a dark continuous band (A layer) on their internal border (arrow). (Right) TTD, present case. The outermost cuticular layers are disrupted and the normal architecture is lost. The A layer (arrowhead) is only intermittently discernible.

Table 1 Hair cysteine analysis results

Sample	Mean cysteine content ($\mu\text{mol/g}$ hair dry weight)
Previously published controls ¹⁴	1407–1512
Control hair (age/sex matched)	1442.6
Patient's hair	1172.8

age, but was receiving remedial help with reading and perceptual motor skills. Her co-twin did not display any of the above features on examination and was reported to be performing satisfactorily at school. On review at the age of 8½ years, her hair was becoming thicker but the growth rate remained very slow. The keratoderma continued to be a problem and was managed by a combination of skin creams. The skin photosensitivity was being dealt with by ultraviolet barrier cream and sun protection. Formal testing with monochromatic light across the ultraviolet A and B spectra did not produce unusual erythema, indicating that the photosensitivity was of mild degree. Eye examination was difficult because of photophobia, but no abnormal retinal pigmentation was observed. She was having private tuition for reading and arithmetic.

Hair examination on polarised light microscopy showed no alternating dark and light band “tiger tail” pattern. On scanning electron microscopy, marked irregularity and flattening of hair shafts was observed. Some areas showed twisting and variation in shaft diameter. Transmission electron microscopy showed a defective A layer in the outermost cuticle cells (fig 3), a characteristic of TTD.¹ The hair cysteine content of the patient and of an age and sex matched control was assessed on hair cuttings scoured as in Church *et al*² and measured according to a modification of the method in Strydom and Cohen.³ All hair shafts showed decreased cysteine content compared to the control specimens and with reference to previously published values (table 1).

Since the patient came from the same city as a previously reported case of TTD (TTD183ME), who was a compound heterozygote at the *XPD/ERCC2* locus, we first tested the mutations identified in that case, these being a null mutation in one allele (c1381C>G, c2146del45) and a causative mutation in the other (c2173G>C).^{4,5} We used this occasion to test the robustness of buccal smears for diagnostic purposes. We had previously used buccal smears successfully for the diagnosis of xeroderma pigmentosum complementation group A (XPA) patients (J E Cleaver, M McDowell,

unpublished data), but we expected that the *XPD* gene, being larger than *XPA* and with more introns, might prove more difficult.⁵ Buccal smears were taken from the patient and her co-twin and sent by express mail from Melbourne to San Francisco. Samples were then solubilised in alkali extraction buffer and subjected to genomic amplification by PCR, using primers that flank those genomic regions in which mutations noted above had previously been identified. The PCR products were subcloned into a cloning vector and individual inserts sequenced. The unaffected co-twin had no causative mutations in the regions investigated, although there were two common neutral polymorphisms (c687G>A, c711C>T). The index case had neither of these polymorphisms and neither was the c1381C>G, c2146del45 null allele identified. We sequenced about 300 nucleotides around the region of the causative mutation (c2173G>C) and found only wild type sequences.

This child presents a mild phenotypic form of trichothiodystrophy (TTD). The scalp hair was abnormal in its texture, strength, and distribution, and the electron microscopic (but not light microscopic) picture was similar to that of the classical form of TTD. Hair cysteine content was reduced and the A layer of the cuticle cells defective, substantiating the diagnosis. Other clinical observations included keratoderma, nail dystrophy, and mild developmental delay. Linear growth was unaffected.

TTD can present with a notably wide clinical range.⁶ In its mildest form, the disorder may be confined clinically to an abnormality of the hair.^{7,8} The “tiger tail” hair sign is typical but not universal,⁶ as indeed our case exemplifies. A further grade of affection is illustrated in our patient, with mild to moderate involvement of the ectoderm and certain of its appendages, as well as (if indeed this is causally related) a minor cognitive component. At the other end of the spectrum, TTD is a seriously disabling disease, with a severe skin affliction and mental defect and growth retardation.

The TTDs comprise one of a group of related disorders resulting from abnormalities in components of the nucleotide excision repair (NER) system, these factors having a second role as subunits of the basal transcription factor TFIIF.^{9,10} Three TTD complementation groups exist, corresponding to the genes *XPB/ERCC-3*, *XPD/ERCC-2*, and an uncloned gene *TTDA*. Xeroderma pigmentosum (XP) and a form of Cockayne syndrome (CS) with XP-like symptoms are also the result of defects

in the NER/TFIIH system, and the three conditions XP, CS, and TTD overlap at a clinical and molecular level. The phenotype in XP includes photosensitivity, pigmentary abnormalities, neurodegeneration, and (unlike TTD) a predisposition to skin cancer; CS is characterised by neurodysmyelination, photosensitivity, and physical and mental retardation.

Mutations in one particular NER/TFIIH subunit, *XPD/ERCC-2*, account for the great majority of photosensitive TTD patients, and are seen in patients with XP complementation group D (XPD), and in patients with combined clinical features of XP and Cockayne syndrome.^{9-11,12} In vitro insertion of *XPD/ERCC-2* in cells of the three conditions corrects the UV induced DNA damage in cells, showing a locus homogeneity with allelic heterogeneity in the three clinical phenotypes. The gene has yet to be identified in a second TTD complementation group, in which the phenotype is severe. Mutations in the gene *XPB/ERCC-3*, which codes for another NER/TFIIH subunit, have recently been identified in the third complementation group of TTD, characterised by a mild phenotype, and so far represented only by two sibs; the Cockayne/XP syndrome has also been associated with this locus.^{9,13} The two reported *XPB/ERCC-3* TTD sibs displayed a dermatological phenotype of "collodion baby", proceeding to a residual mild ichthyosis of the trunk and a mild photosensitivity. Hair microscopy showed a "tiger tail" pattern. They were noted to be of normal intelligence and physical growth, although a "mild learning disability" was recorded in one, and this child also had growth indices at the lower limit of normal (-2 SD).

We have not been able to find an *XPD/ERCC-2* mutation in our patient, although this possibility is by no means excluded. The mildness of the phenotype may suggest an equivalence to the *XPB/ERCC-3* sibs in Weeda *et al.*,⁹ but there is a difference in that she had not presented as a collodion baby, her linear growth is not compromised, her keratoderma is more marked, and light microscopy did not show "tiger tailing". Which, if either, locus underlies her case remains open to question.

We thank Dr Richard McNeill who referred the patient, Dr C W Chow and Professor J P Dowling who performed hair electron microscopy, Dr C Baker who did the skin light testing, and Mr Gary Corino of the Commonwealth Sci-

entific and Industrial Research Organisation, Geelong, Australia, who did the hair sulphur analysis. We thank the patient and her family for their help in the study. JEC acknowledges NIEHS grant number 1R01 8061 and a generous gift from the XP Society.

RAVI SAVARIRAYAN*
R J MCKINLAY GARDNER*
RODNEY D SINCLAIR†
MINDY MCDOWELL‡
JAMES E CLEAVER‡

*Victorian Clinical Genetics Service, Royal Children's Hospital, Melbourne, Victoria 3052, Australia

†Skin and Cancer Foundation, Melbourne, Victoria 3053, Australia

‡UCSF Cancer Center, University of California, San Francisco, CA 94143-0808, USA

Correspondence to: Dr Gardner

- Gummer CL, Dawber RPR. Trichothiodystrophy: an ultrastructural study of the hair follicle. *Br J Dermatol* 1985;113:273-80.
- Church JS, Corino GL, Woodhead AL. The analysis of Merino wool cuticle and cortical cells by Fourier transform and Raman spectroscopy. *Biopolymers* 1997;42:7-17.
- Strydom DJ, Cohen SA. Sensitive analysis of cystine/cysteine using 6-aminoquinolyl-N-hydroxysuccinimidyl carbamate (AQC) derivatives. In: RH Angeletti, ed. *Techniques in protein chemistry IV*. San Diego: Academic Press, 1993:299-306.
- Takayama K, Danks DM, Salazar EP, Cleaver JE, Weber CA. DNA repair characteristics and mutations in the ERCC2 DNA repair and transcription gene in a trichothiodystrophy patient. *Hum Mutat* 1997;9:519-25.
- Cleaver JE, Thompson LH, Richardson AS, States JC. A summary of mutations in the UV-sensitive disorders: xeroderma pigmentosum, Cockayne syndrome and trichothiodystrophy. *Hum Mutat* (in press).
- Tolmie JL, de Berker D, Dawber R, *et al.* Syndromes associated with trichothiodystrophy. *Clin Dysmorphol* 1994;3:1-14.
- Alfandari S, Delaporte E, Van Neste S, Lucidarme-Delespierre E, Piette F, Bergoend H. A new case of isolated trichothiodystrophy. *Dermatology* 1993;186:197-200.
- Peter C, Tomczok J, Hoting E, Behrendt H. Trichothiodystrophy without associated neuroectodermal defects. *Br J Dermatol* 1998;139:137-40.
- Weeda G, Eveno E, Donker I, *et al.* A mutation in the *XPB/ERCC3* DNA repair transcription gene, associated with trichothiodystrophy. *Am J Hum Genet* 1997;60:320-9.
- Drapkin R, Reardon JT, Ansari A, *et al.* Dual role of TFIIH in DNA excision repair and in transcription by RNA polymerase II. *Nature* 1994;368:769-72.
- Stefanini M, Lagomarsini P, Giliani S, *et al.* Genetic heterogeneity of the excision repair defect associated with trichothiodystrophy. *Carcinogenesis* 1993;14:1101-5.
- Takayama K, Salazar EP, Broughton BC, *et al.* Defects in the DNA repair and transcription gene *ERCC2 (XPD)* in trichothiodystrophy. *Am J Hum Genet* 1996;58:263-70.
- Riou L, Zeng L, Chevallier-Lagente O, *et al.* The relative expression of mutated *XPB* genes results in xeroderma pigmentosum/Cockayne's syndrome or trichothiodystrophy cellular phenotypes. *Hum Mol Genet* 1999;8:1125-33.
- Robbins CR. *Chemical and physical behaviour of human hair*. 3rd ed. New York: Springer-Verlag, 1994.

J Med Genet 2000;37:314-315

The first description of lethal pterygium syndrome with facial clefting (Bartsocas-Papas syndrome) in 1600

EDITOR—A recently reviewed 12 page pamphlet dated 1600, housed at the Bodleian Library, Oxford, contains a detailed account of a severely malformed infant born in Herefordshire in January 1600.¹ The child, whose gender was uncertain to the observers, was born to first cousins. "A most strange, and true discourse, of the wonderfull iudgement of God. Of a monstrous deformed infant, begotten by incestuous copulation, betweene the brother's sonne and the sister's daughter, being both vnmarried persons".

Adhering closely to the language of the day the infant is described thus.

Head longer than ordinary children with no hair on the head or eyebrows.

Both eyes standing far out of the head, unequal to each other - right eye very small, like a black sloe sticked half out in the flat face - no eyelid or eyepit - "as it were a bullet sticking in a plain wall"; the left eye was very big and eminent, sticking out like the other but with eyelids which were drawn the upper up and the lower down as if inside out.

Nose depressed flat to face - no nostrils - at lower end a round button of fleshy substance the size of a nut. On either side, higher than the nose the upper lip was slit or hare-thorne from which two slits thro' the pallet or roof of the mouth there passed two hoolow trenches, almost two fingers deep - to the gullet, which seemed to be the passage of the nostrils - the lower part of the mouth on either side of the tongue like a deep trench.

Mouth smaller than usual - no gunms, jawbones or lips. Face more wrinkled than most - grim to behold.

No thumbs or any outward partition of fingers - fingers covered all with one skin, "as with a mitten", but with joints.

Finger of left hand (digitus annularis/ring finger) had nail and was separated towards the end.

Not clear if the child was male or female - had perfect members of neither - urine issued out of a small hole in the proper place - sometimes seemed more male, sometimes more female.

Knees up to the belly, legs fixed to buttocks; the calf of the left leg growing to the buttock, and thigh unto the small of the leg; but the right leg quite down to the heele, within two fingers breadth.

Right foot bowed towards the left and joined to it by a string of flesh at the ends of the big toes - the rest of the toes covered with one skin as were the hands.

The body bigger and longer than other children.

The child died on the third day and was said not to sleep because "it had no eyelids". In summary, the child appears to have had severe facial clefting affecting the lip and palate with a small or absent nose, abnormal eyes and periorbital structures, probable micrognathia, fusion syndactyly of the hands and feet, severe lower limb popliteal pterygia and club foot with a filiform adhesion, and hypoplastic/ambiguous genitalia. The unusually clear and detailed description of the features makes it possible to suggest a diagnosis compatible with consanguinity and autosomal recessive inheritance, namely lethal pterygium syndrome with facial clefting, first described in modern times by Bartsocas and Papas² (MIM 263650). Including a recent report of four affected Arab sibs,³ approximately 20 cases have been described, not all of which have shown early lethality. Most reported cases have originated from the Mediterranean area, adding interest to this historical account from rural England where the first cousin parents were reliably indigenous.

In the 16th-17th century, use of the term "monster" to describe deformity lacked the modern pejorative overtones of that word and such births were regarded as punishment from God. In 1620 Francis Bacon, one of the fathers of modern scientific thinking, suggested that "a compilation, or natural history, must be made of all monsters and pro-

digious births of nature; of everything, in short, which is new, rare, and unusual in nature. This should be done with rigorous selection, so as to be worthy of credit".⁴ This detailed description of 1600 is certainly worthy of credit.

The concept and law relating to incest was very different in 17th century England compared with today. Incest was not a criminal offence but was prohibited by Canon Law and so heard in the Church Courts. Its scope was wide, embracing not only cases of consanguinity (including first cousin unions) but also cases of "affinity", for example, a sexual relationship between a woman and her brother in law (although this could be dispensed with in specific cases if proper approaches were made before marriage). It was not until the late 19th century that marriage with a "deceased wife's sister" was allowed as a matter of course. Seventeenth century Scottish law was different and incest was a criminal offence, leading to a number of executions for sexual relations even in the category of "affinity". Changes and rationalisations in the Law of Incest came about precisely at the time when the science of genetics was born, the publication of Francis Galton's *Natural Inheritance* in 1889 being particularly significant.

PETER D TURNPENNY*
ROBERT HOLE†

*Clinical Genetics, Royal Devon & Exeter Hospital, Barrack Road, Exeter, Devon EX2 8AB, UK

†Faculty of Arts and Education, University of Plymouth, Douglas Avenue, Exmouth, Devon EX8 2AT, UK

Correspondence to: Dr Turnpenny, turnpenn@eurobell.co.uk

- 1 Iones R. *A most strange, and true discourse ...*. Bodleian Library (Oxford) reference: Mal. 640(10). London, 1600.
- 2 Bartsocas CS, Papas CV. Popliteal pterygium syndrome - evidence for a severe autosomal recessive form. *J Med Genet* 1972;9:222-6.
- 3 Massoud AA, Ammaari AM, Khan ASS, Katraman BV, Teebi AS. Bartsocas-Papas syndrome in an Arab family with four affected sibs. *Am J Med Genet* 1998;79:16-21.
- 4 Bacon F. *Novum organum scientiarum*. London, 1620.

J Med Genet 2000;37:315-318

Sex reversal and diaphragmatic hernia in phenotypically female sibs with normal XY chromosomes

EDITOR—True agonadism, characterised by the absence of gonads in both XY and XX patients, is a rare, mostly sporadic, and isolated condition. Its association with diaphragmatic hernia seems to be extremely rare and has always been described associated with multiple congenital malformation (MCA) syndromes of unknown origin. Sex reversal and diaphragmatic hernia have been described once with a heterozygous *WT1* mutation in a sporadic case.¹ The association of normal feminisation, absent gonads, and diaphragmatic hernia in two XY sibs without any other malformation suggested other diagnostic possibilities. Since further investigations did not find any chromosomal or known genetic cause for this familial sex reversal syndrome, we suggest that these cases could represent a new sex reversal syndrome, which could be either autosomal recessive or X linked, and may result from either unreported mutations of *WT1* or anomalies of other developmental genes.

The proband (fig 1, II.4) is the fourth child of non-consanguineous, healthy parents with an unremarkable family history. Their first child (II.1), a girl born at term in 1989, died of severe respiratory distress at 2 days of age after surgery for a left diaphragmatic hernia. She was of normal

size (weight 3200 g, 50th centile) and according to the paediatricians not dysmorphic. No additional malformation was found at necropsy apart from the large left diaphragmatic hernia and a single umbilical artery. Chromosomal analysis was not performed. Two subsequent pregnancies resulted in normal, healthy, male children (II.2, II.3).

At 34 weeks' gestation of the fourth pregnancy, ultrasonography detected dextrocardia owing to a left diaphragmatic hernia involving the stomach, left lobe of the liver, and numerous intestinal loops. Chromosomal analyses were performed on both lymphocytes from fetal blood and fibroblasts from amniotic fluid. They were normal male: 46,XY. Delivery was spontaneous at 37 weeks' gestation. Neonatal measurements were within normal limits (weight 2370 g, 10th centile, OFC 31 cm, 10th centile).

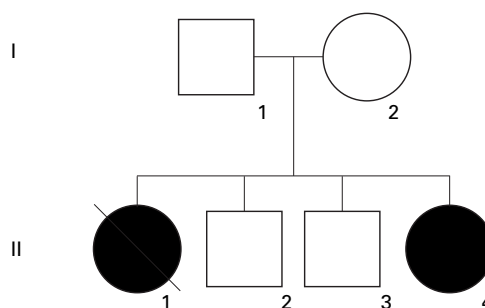


Figure 1 Family pedigree.

Intubation was performed immediately after birth and the infant was transferred to the intensive care unit. HFO and NO treatments were given. Apart from the respiratory distress syndrome, the clinically female infant was normal except for bilateral membranous syndactyly of the second and third toes. This was absent in all three sibs but present to a lesser degree in her father. Cardiac and abdominal ultrasonography were normal. The diaphragmatic hernia was surgically repaired at 2 weeks of age, when an almost total absence of the left diaphragm was noted. This required the fitting of a GoreTex® plate. The subsequent course was favourable and ventilatory support was discontinued at 1 month of age. At 9 months the patient was in good health; weight was 6 kg (-2 SD), height 66 cm (-1 SD), OFC 43 cm (-1 SD), and neuromotor development was normal.

Further investigations were performed in the proband who had completely feminised external genitalia, a normal male karyotype, severe diaphragmatic hernia, and whose sister had died of diaphragmatic hernia. Cholesterol and 7OH cholesterol were normal so that Smith-Lemli-Opitz syndrome (MIM 270400) could be excluded. Skeletal x rays showed somewhat curved clavicles but no anomaly that could indicate campomelic dysplasia (MIM 114290). Hormonal profile in the neonatal period showed very low testosterone (0.21 ng/ml, normal 2-4 ng/ml) and dehydrotestosterone (0.04 ng/ml), with normal FSH (1.8 IU/l) and LH (1.1 IU/l) levels, as seen in both complete XY gonadal dysgenesis and agonadism. Ultrasonography of the visceral organs showed the presence of an apparently normal uterus. Pelvic endoscopy was performed at 6 months of age and confirmed the presence of a normal uterus and fallopian tubes; however, no gonads were found, not even in an ectopic position. High resolution G banding chromosome analysis confirmed the normal male karyotype; in particular no anomalies were observed in the regions of localised or putative sex determining genes, such as Yp11.3 (SRY), Xp21.3 (DSS/DAX-1), 11p13 (WT1), 17q24 (SOX9), 9p,^{2,3} or 10q.⁴ SRY was present and PCR analyses of both the promoter and the unique exon showed that they were present and of normal size. Furthermore, fluorescent in situ hybridisation (FISH) of the Y chromosome performed on paraffin preserved tissue from the dead sib detected retrospectively the presence of a Y chromosome. SRY analyses could not be performed because of the small amount of tissue preserved, and it was not possible to study retrospectively the internal genitalia of this normally feminised infant.

As diaphragmatic hernia has been described in one case of Denys-Drash syndrome (DDS, MIM 194080),¹ renal function was carefully investigated in the proband (whose renal ultrasonography was normal) and was found to be normal. Moreover, renal tissue of the dead sister was re-examined and found to be normal. Finally, in the proband no anomaly was found in exons 7, 8, or 9 of the WT1 gene, which is responsible for DDS and Frasier syndrome (FS, MIM 136680).

Here we report two sibs with a normal male karyotype and diaphragmatic hernia. Clinical and laboratory investigations of sex reversal established the diagnosis of true agonadism, which is a rare, mostly sporadic condition characterised by the absence of gonadal structure. Agonadism has almost always been diagnosed in cases with a normal male (XY) karyotype, female external genitalia, and absence of extragenital anomalies. However, the condition could have been overlooked in karyotypically female patients because of the absence of sex reversal. In XY patients, agonadism has to be differentiated from XY pure gonadal dysgenesis (Swyer syndrome resulting from SRY mutations (MIM 306100)), in which the gonads are

Table 1 Agonadism and multiple malformation with normal karyotype

	13	14	15	16	17	18	19	20/21	22
Consanguinity	-	-	-	-	-	-	-	-	-
Karyotype	XY F	XY F	XX F	XY F	XX F	XY F; large clitoris Blind	XY F	XY F	+ sibs XY F
External genitalia	Blind	Blind	Blind	Blind	Blind	Blind	Blind	Blind	Blind
Vagina		Rudimentary rectovaginal fistula							
Müllerian ducts	Rudimentary	Rudimentary	Hypoplastic	Absent	Absent	Absent	Absent	Rudimentary	Hypoplastic
Gonads	Absent	Absent	Absent	Absent	Absent	Absent	Probably absent	Absent	Absent
Associated anomalies	Severe MR, short stature, unusual facies, hirsutism	CHARGE association	DH; BAV	MR, short stature, unusual facies	NTD, omphalocele	Upper amelia/ peromelia	Bilateral upper amelia, unusual facies	Right DH, ASD, VSD	MR, short stature, obesity, unusual facies, omphalocele, right kidney aplasia

F: female; ASD: atrial septal defect; VSD: ventricular septal defect; HLX: hypoplastic left ventricle; BAV: bicuspid aortic valve; DH: diaphragmatic hernia; CP: cleft palate; MR: mental retardation; NTD: neural tube defect.

reduced to streaks but are present, and both external and internal genitalia are normal female. In XY patients, agonadism was termed embryonic testicular regression syndrome⁵⁻⁶ because, from an embryological point of view, it may be the result of secondary precocious regression rather than true agenesis of the primary undifferentiated gonads. Thus, early testicular tissue action (anti-Müllerian hormone (AMH) and testosterone) could explain the range of virilisation in some agonadal XY patients. Because of the few familial cases of XY embryonic testicular regression syndrome,⁷⁻⁹ genetic determinism has been suggested.

Agonadism has seldom been observed with an XX chromosomal constitution in either sporadic (n=1)¹⁰ (n=2)¹¹ or familial cases (both XY and XX affected sibs of consanguineous parents).¹² External genitalia were normal female in all five patients, but Müllerian ducts were either absent,¹⁰ hypoplastic,¹² or normal,¹¹ whereas no transient testicular anti-Müllerian effect can have acted in these XX patients. Thus, the question is raised of the involvement of autosomal genetic factors maintaining both gonads and Müllerian ducts (the latter independently of AMH action).

On the other hand, agonadism has also been described associated with variable extragenital anomalies in both sporadic¹³⁻¹⁹ and familial cases²⁰⁻²² (table 1), of which one sporadic¹⁵ and one familial²⁰⁻²¹ cases were also associated with diaphragmatic hernia. However, the remaining features in these patients are sufficiently different from those we describe to exclude comparison. In the patient described by Oyer *et al*,¹⁵ Müllerian derivative defects and bicuspid aortic valve were observed. In the sibs born to unrelated parents described by Sorgo *et al*²⁰ and Kennerknecht *et al*,²¹ Müllerian ducts were present although rudimentary, and diaphragmatic hernia was associated with a heart defect in a patient with an XY chromosomal constitution, whose XX sib presented with omphalocele, heart defect, and cleft palate.

Diaphragmatic hernia and sex reversal has been described associated with multiple malformations in three unrelated phenotypic girls with a normal XY karyotype.²³⁻²⁴ However, the multiple associated malformations, cyanotic complex heart defect (n=2),²³ hypoplastic left ventricle, ectopic spleen, and horseshoe kidney (n=1),²⁴ and above all the presence of testis tissue are sufficiently different from our observations to distinguish these conditions.

We also looked for *WT1* mutations (which were first described in patients with Wilms tumour,²⁵⁻²⁶ then in DDS syndrome,²⁶ and more recently in Frasier syndrome²⁷⁻²⁸), because of the description of a *WT1* point mutation (arg 366 his) in a phenotypic girl with a normal male karyotype, a large left posterolateral diaphragmatic hernia, and features of DDS (dysgenetic ovaries, double uterus, double vagina, and severe glomerulopathy), who died at 5 hours of age from respiratory distress.¹ Furthermore, transgenic mice with a homozygous *WT1* deletion consistently have diaphragmatic hernia and heart defects besides their urogenital malformations,²⁹ although no *WT1* mutation has been found in patients with isolated diaphragmatic hernia.³⁰ *WT1* is expressed in abdominal and lung mesothelium and encodes four isoforms of zinc finger transcriptional factors that could regulate several genes involved in the development of the diaphragm as well as those implicated in sex determination and differentiation, such as *SRY*, *AMH*, and the androgen receptor genes.³¹ Our patient did not fit all the diagnostic criteria for either DDS or FS; she had agonadism rather than gonadal dysgenesis, her Müllerian structures were normally developed while they are often hypoplastic or absent in DDS or FS, she has not presented any renal anomalies up to the age of 1 year, and no mutation has

been found in *WT1* exons 7, 8, or 9. However, the absence of identified gonads could be an extreme form of gonadal dysgenesis,³² testicular regression could have been precocious enough to prevent AMH secretion, and renal dysfunction owing to *WT1* mutations could appear later (as seen in FS). Since, to our knowledge, no other familial cases of true agonadism associated with diaphragmatic hernia have been published, and since we did not find *WT1* mutations known to be implicated in DDS and FS syndromes in our patient, we suggest that such cases could represent a new sex reversal syndrome that could be either autosomal recessive or X linked, and result from either unreported mutations of *WT1* or anomalies of other developmental genes.

S MANOUVRIER-HANU*
R BESSON†
L COUSIN*
C JEANPIERRE‡
N KACET§
M CARTIGNY¶
L DEVISME**
L STORME§
B DE MARTINVILLE††
P LEQUIEN§

*Génétique Clinique, Hôpital Jeanne de Flandre, CHRU, Lille, France

†Chirurgie Pédiatrique, Hôpital Jeanne de Flandre, CHRU, Lille, France

‡INSERM U 383, Hôpital Necker-Enfants Malades, Paris, France

§Pédiatrie Néonatale, Hôpital Jeanne de Flandre, CHRU, Lille, France

¶Endocrinologie Pédiatrique, Hôpital Jeanne de Flandre, CHRU, Lille, France

**Laboratoire d'Anatomopathologie, Hôpital Calmette, CHRU, Lille, France

††Laboratoire de Génétique Médicale, Hôpital Jeanne de Flandre, CHRU, Lille, France

Correspondence to: Dr Manouvrier-Hanu, smanouvrier@chru-lille.fr

- Devriendt K, Deloof E, Moerman P, *et al*. Diaphragmatic hernia in Denys-Drash syndrome. *Am J Med Genet* 1995;57:97-101.
- Bennet CP, Docherty Z, Robb SA, Ramani P, Hawkins JR, Grant D. Deletion 9p and sex reversal. *J Med Genet* 1993;30:518-20.
- Fleijter WL, Fergestad J, Gorski J, Varvill T, Chandrasekharappa S. A gene involved in XY sex reversal is located on chromosome 9, distal to marker D9S1779. *Am J Hum Genet* 1998;63:794-802.
- Wilkie AOM, Campbell FM, Daubeney P, *et al*. Complete and partial sex reversal associated with terminal deletion of 10q: report of two cases and literature review. *Am J Med Genet* 1993;46:597-600.
- Josso N, Briard ML. Embryonic testicular regression syndrome: variable phenotypic expression in sibs. *J Pediatr* 1980;97:200-4.
- Parks GA, Dumars KW, Limbeck GA, Quinlivan WL, New MI. "True agonadism": a misnomer? *J Pediatr* 1974;84:375-80.
- Overzier C, Linden H. Echter agonadismus (anorchismus) bei Geschwistern. *Gynaecologia* 1956;142:215-33.
- Park J, Jones HW. Familial male hermaphroditism with ambiguous external genitalia. *Am J Obstet Gynecol* 1970;108:1197-205.
- Nafiah J. Familial testicular regression syndrome. *Bull Acad Natl Med* 1989;173:709-14.
- Levinson G, Zarate A, Guzman-Toledano R, Canales ES, Jimenez M. An XX female with sexual infantilism, absent gonads and lack of Müllerian ducts. *J Med Genet* 1976;13:68-9.
- Medina M, Kofman-Alfaro S, Perez-Palacios G. 46,XX gonadal absence: a variant of the XX pure gonadal dysgenesis? *Acta Endocrinol* 1982;99:585-7.
- Mendonca BB, Barbosa AS, Arnhold IJ, McElreavey K, Fellous M, Moreira-Filho CA. Gonadal agenesis in XX and XY sisters: evidence for the involvement of an autosomal gene. *Am J Med Genet* 1994;52:39-43.
- Maciell-Guerra AT, Farah SB, Garmes HM, *et al*. True agonadism: report of a case analysed with Y-specific DNA probes. *Am J Med Genet* 1991;41:444-5.
- Kusnick T, Wiley JE, Palmer SM. Agonadism in a 46,XY patient with CHARGE association. *Am J Med Genet* 1992;42:96-9.
- Oyer CE, Ramos D, Shoji T, Tantravahi U. 46,XX gonadal agenesis in a neonate with multiple congenital anomalies: case report and review of the literature. *Pediatr Pathol* 1994;14:967-72.
- Sybert VP, Pagon RA, Ramsdell L, Marymee K. Re: true agonadism: report of a case analysed with Y-specific DNA probes. *Am J Med Genet* 1995;55:113.
- Kennerknecht I, Mattfeldt T, Paulus W, *et al*. XX-agonadism in a fetus with multiple dysraphic lesions: a new syndrome. *Am J Med Genet* 1997;70:413-14.
- Temocin AK, Yuksel B, Tuncer R, Ozer G, Zorlutdemir U. *Acta Paediatr Jpn* 1997;39:631-2.
- Ohro Y, Suzuki Y, Tsutsumi Y, Ogata T. Female external genitalia, absent uterus, and probable agonadism in a 46,XY infant with bilateral upper amelia. *Clin Genet* 1998;54:52-5.
- Sorgo W, Gortner L, Bartmann P, *et al*. Gonadal agenesis in a 46,XY female with multiple malformations and positive testing for the sex-determining region of the Y chromosome. *Horm Res* 1991;35:124-31.
- Kennerknecht I, Sorgo W, Oberhoffer R, *et al*. Familial occurrence of agonadism and multiple internal malformations in phenotypically normal girls with 46,XY and 46,XX karyotypes, respectively: a new autosomal recessive syndrome. *Am J Med Genet* 1993;47:1166-70.

- 22 Kennerknecht I, Von Saurma P, Brenner R, *et al.* Agonadism in two sisters with XY gonosomal constitution, mental retardation, short stature, severely retarded bone age, and multiple extragenital malformations: a new autosomal recessive syndrome. *Am J Med Genet* 1995;59:62-7.
- 23 Meacham LR, Winn KJ, Culler FL, Parks JS. Double vagina, cardiac, pulmonary, and other genital malformations with 46,XY karyotype. *Am J Med Genet* 1991;15:478-81.
- 24 Maaswinkel-Mooij PD, Stokvis-Brantsma WH. Phenotypically normal girl with male pseudohermaphroditism, hypoplastic left ventricle, lung aplasia, horseshoe kidney, and diaphragmatic hernia. *Am J Med Genet* 1992;42:647-8.
- 25 Haber DA, Buckler AJ, Glaser T, *et al.* An interstitial deletion within an 11p13 zinc finger protein gene contributes to the development of Wilms' tumor. *Cell* 1990;61:1257-69.
- 26 Pelletier J, Bruening W, Li FP, Haber DA, Glaser T, Housman DE. WT1 mutations contribute to abnormal genital system development and hereditary Wilms' tumour. *Nature* 1991;353:431-4.
- 27 Barbaux S, Niaudet P, Gubler MC, *et al.* Donor splice-site mutations in WT1 are responsible for Frasier syndrome. *Nat Genet* 1997;17:467-70.
- 28 Kikuchi H, Takata A, Akasaka Y, *et al.* Do intronic mutations affecting splicing of WT1 exon 9 cause Frasier syndrome? *J Med Genet* 1998;35:45-8.
- 29 Kreidberg JA, Sariola H, Loring JM, *et al.* WT-1 is required for early kidney development. *Cell* 1993;74:679-91.
- 30 Nordenskjold A, Tapper-Persson M, Anvret M. No evidence of WT1 gene mutations in children with congenital diaphragmatic hernia. *J Pediatr Surg* 1996;31:925-7.
- 31 Shimamura R, Fraizer GC, Trapman J, Lau YFC, Saunders GF. The Wilms' tumor gene WT1 can regulate genes involved in sex determination and differentiation: SRY, Mullerian-inhibiting substance, and the androgen receptor. *Clin Cancer Res* 1997;3:2571-80.
- 32 Marcantonio SM, Fechner PY, Migeon CJ, Perlman EJ, Berkovitz GD. Embryonic testicular regression sequence: a part of the clinical spectrum of 46,XY gonadal dysgenesis. *Am J Med Genet* 1994;49:1-5.

J Med Genet 2000;37:318-320

Clinical variability of Stickler syndrome with a *COL2A1* haploinsufficiency mutation: implications for genetic counselling

EDITOR—Snead and Yates¹ have recently reviewed clinical and molecular findings in Stickler syndrome, the autosomal dominant connective tissue disorder characterised by ocular manifestations, facial abnormalities, cleft palate,

sensorineural hearing loss, and degeneration of epiphyseal and articular cartilage (hereditary progressive arthro-ophthalmopathy).¹⁻⁴ Mutations in the structural genes for collagen II (*COL2A1*) and collagen XI (*COL11A1*, *COL11A2*) have been identified in patients with a Stickler syndrome phenotype.⁵⁻¹³ Based on locus heterogeneity, a subclassification of *COL2A1* associated Stickler syndrome type I, *COL11A1* associated Stickler syndrome type III, and *COL11A2* associated Stickler syndrome type II was established (OMIM 108300, 120280, and 184840). A clinical subclassification based on the presence or absence of an ocular phenotype, and on the

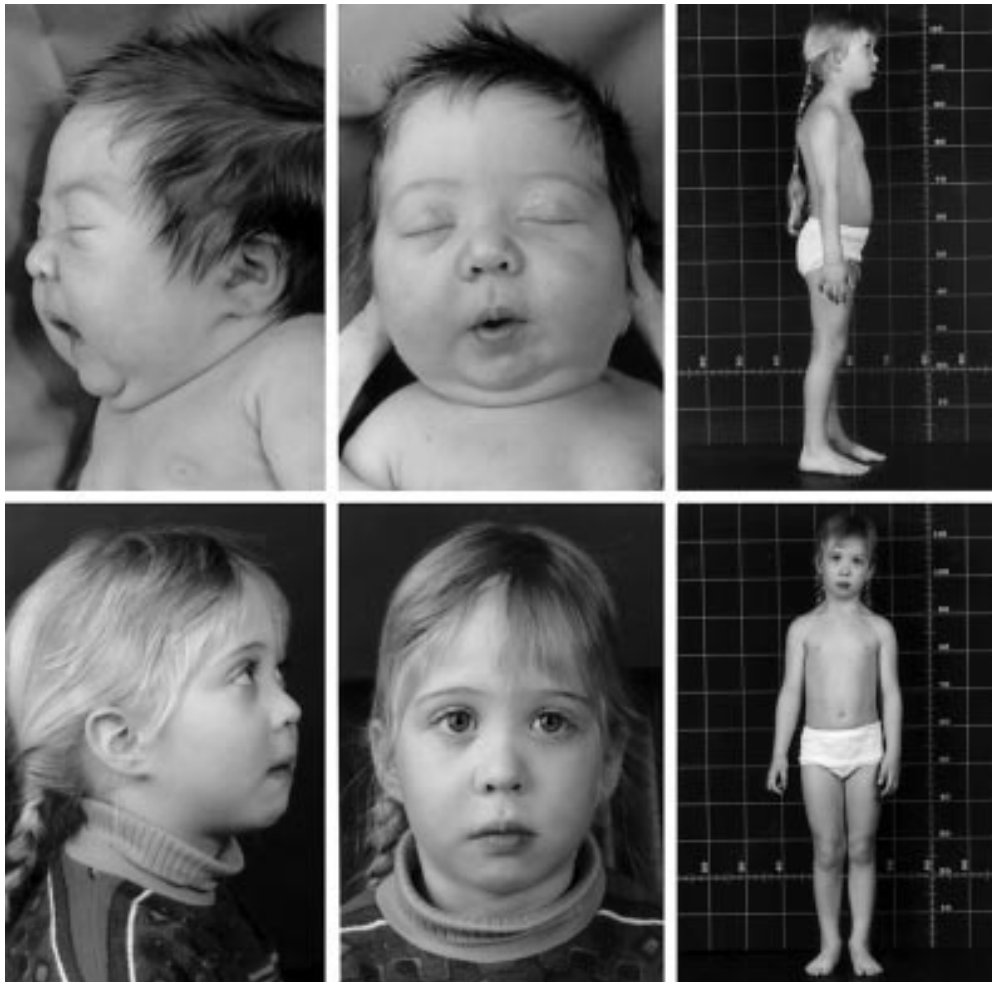

Figure 1 The proband in the newborn period (note midface hypoplasia, micrognathia, apparent exophthalmos, and deep set ears) and at 5 years of age. The face is slightly flat with maxillary hypoplasia and retrognathia. Her height is on the 90th centile; note also mild neck webbing and flat feet. (All photographs reproduced with permission.)

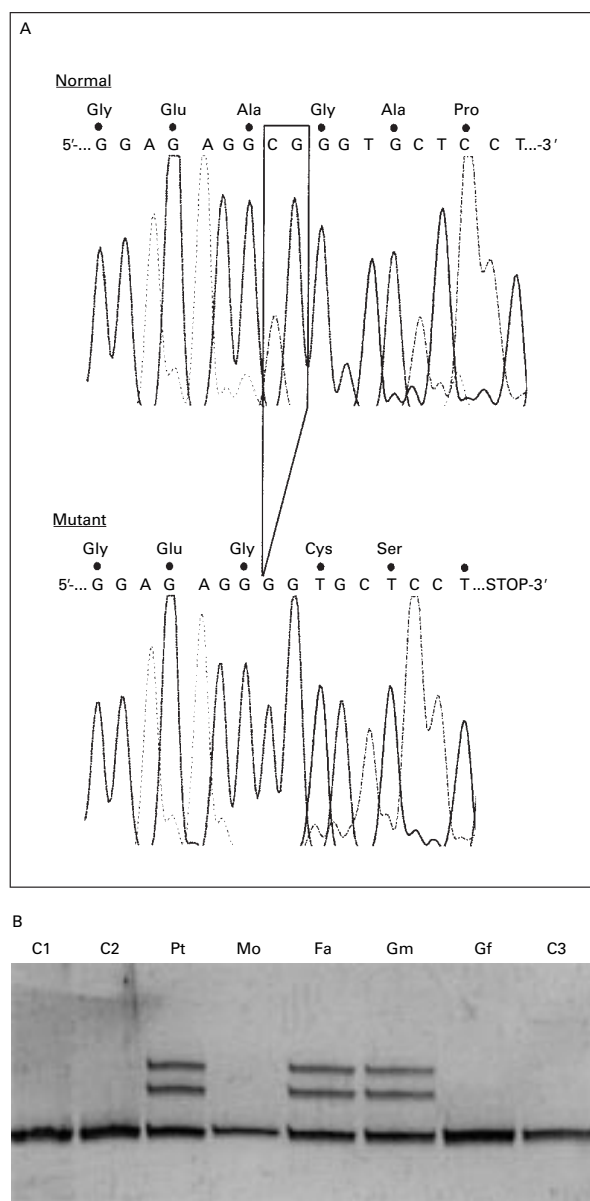


Figure 2 (A) Exon 12 of the *COL2A1* gene was amplified from genomic DNA, subcloned, and sequenced. The mutant clones show a deletion of two nucleotides in exon 12. This leads to a shift in the translational reading frame and the creation of a premature stop codon in exon 13. The corresponding truncated procollagen chains lack the carboxy-terminal domain and cannot participate in procollagen trimer assembly, without exerting other negative effects (haploinsufficiency). (B) Heteroduplex analysis of the exon 12 amplicon in the patient (Pt), her mother (Mo) and father (Fa), the paternal grandmother (Gm) and grandfather (Gf), as well as three controls (C1, C2, C3). Blood leucocyte DNA was used as template. The figure shows the presence of heteroduplex PCR products as two slower migrating bands. Slow migration is caused by the "parachute" effect of the two mismatched bases.

features of the ocular phenotype, correlates reasonably well with the genotype.¹⁹

Clinical variability in Stickler syndrome is well known,^{6 14 15} but correlations with specific mutations are scarce. We report a novel *COL2A1* gene mutation found in a patient with flat face, cleft palate, myopia, and hearing loss (Stickler syndrome) and unexpectedly also in her father and her paternal grandmother who were considered to be healthy. The patient is the first child of healthy, non-consanguineous Swiss parents. The pregnancy was uneventful and she was delivered at term by caesarean section because of breech position. Birth weight was 3890 g (90th centile), birth length 50 cm (50th centile), and head

circumference 37 cm (>97th centile). Macrocephaly and facial dysmorphism were noted in the neonatal period, including a flat midface, deep set ears, exophthalmos, palpebral oedema with telangiectasia, micrognathia, and median clefting of the soft and part of the hard palate (fig 1). No other abnormalities were recognised at that time. At the age of 5 years, midface hypoplasia and micrognathia were still evident. In addition, she presented with mild bilateral hypoacusis, bilateral myopia (4 dioptres), slight webbing of the neck, minimal pectus carinatum, and flat feet (fig 1). Her growth was on the 90th centile. The clinical signs and symptoms as well as radiological findings of mild spondyloepiphyseal dysplasia suggested the diagnosis of Stickler syndrome.

All 54 exons of the *COL2A1* gene, including the flanking splice sites, were amplified and screened by SSCP analysis. Exon 12 gave an abnormal pattern and was subcloned and sequenced, showing a deletion of 2 bp (nt 697-698), for which the patient was heterozygous. The mutation predicts a downstream premature TGA-stop codon in exon 13 (fig 2). The father's DNA gave a similar heteroduplex pattern, and direct sequencing confirmed his heterozygous mutation carrier status. He had been regarded as unaffected, but re-evaluation showed some features consistent with Stickler syndrome including mild bilateral myopia (2 dioptres), a high arched palate, and a partially split uvula. His body habitus showed no distinctive features except for his height of 190 cm (>97th centile) (fig 3); hearing was normal and there was no history of arthropathy. Childhood photographs were reviewed and found to be unremarkable. We subsequently investigated the paternal grandparents and found that the grandmother carried the same *COL2A1* gene mutation in the heterozygous state in her blood leucocytes. She considered herself healthy and declined further investigations. Her physician observed no features of Stickler syndrome. To rule out the presence of a second *COL2A1* mutation in the proband leading to a more severe clinical phenotype, all 54 exons and the flanking intron splice site sequences were analysed by direct sequencing in the proband as well as in her father and grandmother. Except for a few already known common polymorphisms, no additional sequence abnormality was observed.

The 2 bp deletion in exon 12 of the *COL2A1* gene identified in this family leads to a frameshift with a premature stop codon in exon 13. This causes the synthesis of truncated procollagen $\alpha 1(\text{II})$ chains, which are unable to participate in collagen II triple helix formation, without exerting other negative effects, a mechanism referred to as functional haploinsufficiency.^{16 17} To date, at least 10 *COL2A1* gene mutations have been identified in patients with Stickler syndrome type I.^{15 18-24} Except for a 28 bp deletion of exon 12,²⁴ all mutations generate unique premature stop codons leading to functional haploinsufficiency. Findings in our proband provide further evidence that *COL2A1* haploinsufficiency is a common molecular mechanism in patients with Stickler syndrome. However, findings in this family cast some new light on the role of such mutations, as the mutation was detected in two family members who were considered healthy. Apparently, *COL2A1* haploinsufficiency mutations do not necessarily result in the full Stickler phenotype but may cause a mild phenotype or remain below clinical expression.

As briefly mentioned by Snead and Yates,¹ variable clinical expression of Stickler syndrome complicates the genetic counselling scenario. In a child with apparently sporadic Stickler syndrome, caution must be used before assuming a de novo mutation; accurate radiographic and clinical examination of the parents, including formal testing of hearing and vision,¹ is indicated, and a mutation search should be undertaken whenever possible. On the positive




Figure 3 The patient's father at 41 years of age. He is 190 cm tall and thus on the 97th centile for the Swiss population. He has mild myopia (2 dioptres), a compatible but non-specific finding. Little in his physical appearance suggests a collagen disorder; the only telltale finding was a partially bifid uvula.

side, counselling must take into account the possibility that inheritance of such a mutation may have only minimal clinical consequences or remain silent, but it can be difficult for prospective parents to make use of information with this degree of uncertainty.

Some indications for future research may be derived. First, the question might be asked of whether variability is more frequent in *COL2A1* haploinsufficiency mutations than in the other *COL11A1* and *COL11A2* mutations associated with Stickler syndrome. Second, a systematic ascertainment of families segregating such *COL2A1* haploinsufficiency mutations might allow the penetrance of single clinical traits, such as cleft palate or severe myopia, to be determined. It cannot be excluded at present that among carriers of such mutations, subjects with the full blown Stickler phenotype are the exception rather than the rule; this remains to be investigated. Such insight would be helpful for counselling and parental decision making.

We are grateful to our young patient and her parents for cooperation and for permission to publish their photographs; to her grandparents and Dr Z Schneider for clinical information; and to Pia Hermanns, Jutta Busch, and Sabine Fleig for expert technical assistance. Our investigations were supported by a grant from the Swiss National Foundation (32-45401.95 and 32-57272.99) to Andrea Superti-Furga and from the Deutsche Forschungsgemeinschaft to Andreas Winterpacht and Bernhard Zabel.

J FABER*
A WINTERPACHT*
B ZABEL*
W GNOINSKI†
A SCHINZEL‡
B STEINMANN§
A SUPERTI-FURGA§

*Children's Hospital, University of Mainz, Langenbeckstrasse 1, D-55101 Mainz, Germany

†Clinic for Maxillary Orthopaedics and Child Dentistry, University of Zurich, CH-8028 Zurich, Switzerland

‡Institute of Medical Genetics, University of Zurich, CH-8032 Zurich, Switzerland

§Division of Metabolic and Molecular Diseases, Department of Paediatrics, University of Zurich, CH-8032 Zurich, Switzerland.

Correspondence to: Dr Superti-Furga, University Children's Hospital, Steinwiesstrasse 75, CH-8032 Zurich, Switzerland, asupert@access.unizh.ch

- Snead MP, Yates JRW. Clinical and molecular genetics of Stickler syndrome. *J Med Genet* 1999;36:353-9.
- Stickler GB, Belau PG, Farrell FJ, et al. Hereditary progressive arthro-ophthalmopathy. *Mayo Clin Proc* 1965;40:433-55.
- Stickler GB, Pugh DG. Hereditary progressive arthro-ophthalmopathy. II. Additional observations on vertebral abnormalities, a hearing defect, and a report of a similar case. *Mayo Clin Proc* 1967;42:495-500.
- Herrmann J, France TD, Spranger JW, Opitz JM, Wiffler C. The Stickler syndrome (hereditary arthroophthalmopathy). *Birth Defects* 1975;11:76-103.

- Francomano CA, Rowan BG, Liberfarb RM, et al. The Stickler and Wagner syndromes: evidence for genetic heterogeneity. *Am J Hum Genet Suppl* 1988;43:A83.
- Knowlton RG, Weaver EJ, Struyk AF, et al. Genetic linkage analysis of hereditary arthro-ophthalmopathy (Stickler syndrome) and the type II procollagen gene. *Am J Hum Genet* 1989;45:681-8.
- Fryer AE, Upadhyaya M, Littler M, et al. Exclusion of *COL2A1* as a candidate gene in a family with Wagner-Stickler syndrome. *J Med Genet* 1990;27:91-3.
- Bonaventure J, Philippe C, Plessis G, et al. Linkage study in a large pedigree with Stickler syndrome: exclusion of *COL2A1* as the mutant gene. *Hum Genet* 1992;90:164-8.
- Snead MP, Yates JR, Williams R, Payne SJ, Pope FM, Scott JD. Stickler syndrome type II and linkage to the *COL11A1* gene. *Ann NY Acad Sci* 1996;785:331-2.
- Richards AJ, Yates JR, Williams R, et al. A family with Stickler syndrome type 2 has a mutation in the *COL11A1* gene resulting in the substitution of glycine 97 by valine in alpha-1(XI) collagen. *Hum Mol Genet* 1996;5:1339-43.
- Brunner HG, van Beersum SE, Warman ML, Olsen BR, Ropers H, Mariman EC. A Stickler syndrome gene is linked to chromosome 6 near the *COL11A2* gene. *Hum Mol Genet* 1994;3:1561-4.
- Vikkula M, Mariman EC, Lui VC, et al. Autosomal dominant and recessive osteochondrodysplasias associated with the *COL11A2* locus. *Cell* 1995;80:431-7.
- Sirko-Osada DA, Murray MA, Scott JA, Lavery MA, Warman ML, Robin NH. Stickler syndrome without eye involvement is caused by mutations in *COL11A2*, the gene encoding the alpha2(XI) chain of type XI collagen. *J Pediatr* 1998;132:368-71.
- Zlotogora J, Sagi M, Schuper A, Leiba H, Merin S. Variability of Stickler syndrome. *Am J Med Genet* 1992;42:337-9.
- Ritvaniemi P, Hyland J, Ignatius J, Kivirikko KI, Prockop DJ, Ala-Kokko L. A fourth example suggests that premature termination codons in the *COL2A1* gene are a common cause of the Stickler syndrome. Analysis of the *COL2A1* gene by denaturing gradient gel electrophoresis. *Genomics* 1993;17:218-21.
- Prockop DJ, Kivirikko KI. Heritable diseases of collagen. *N Engl J Med* 1984;311:376-86.
- Prockop DJ. Mutations that alter the primary structure of type I collagen: the perils of a system generating large structures by the principle of nucleated growth. *J Biol Chem* 1990;265:15349-52.
- Ahmad NN, Ala Kokko L, Knowlton RG, et al. Stop codon in the procollagen II gene (*COL2A1*) in a family with Stickler syndrome (arthro-ophthalmopathy). *Proc Natl Acad Sci USA* 1991;88:6624-7.
- Ahmad NN, McDonald-McGinn DM, Zakai EH, et al. A second mutation in the type II procollagen gene (*COL2A1*) causing Stickler syndrome (arthro-ophthalmopathy) is also a premature termination codon. *Am J Hum Genet* 1993;52:39-45.
- Ahmad N, Dimascio J, Knowlton RG, Tasman W. Stickler syndrome: a mutation in the nonhelical 3' end of type II procollagen gene. *Arch Ophthalmol* 1995;113:1454-7.
- Brown DM, Nichols BE, Weingeist TA, Sheffield VC, Kimura AE, Stone EM. Procollagen II gene mutation in Stickler syndrome. *Arch Ophthalmol* 1992;110:1589-93.
- Brown DM, Vandenberg K, Kimura AE, Weingeist A, Sheffield VA, Stone EM. Novel frameshift mutations in the procollagen 2 gene (*COL2A1*) associated with Stickler syndrome (hereditary arthro-ophthalmopathy). *Hum Mol Genet* 1995;4:141-2.
- Williams CJ, Ganguly A, Considine E, et al. A-2→G transition at the 3W' acceptor splice site of IVS17 characterizes the *COL2A1* gene mutation in the original Stickler syndrome kindred. *Am J Med Genet* 1996;63:461-7.
- Winterpacht A, Hilbert M, Schwarze U, Mundlos S, Spranger J, Zabel BU. Knies and Stickler dysplasia phenotypes caused by collagen type II gene (*COL2A1*) defect. *Nat Genet* 1993;3:323-6.
- Vintner GM, Temple IK, Middleton-Price HR, Baraitser M, Malcolm S. Genetic and clinical heterogeneity of Stickler syndrome. *Am J Med Genet* 1991;41:44-8.