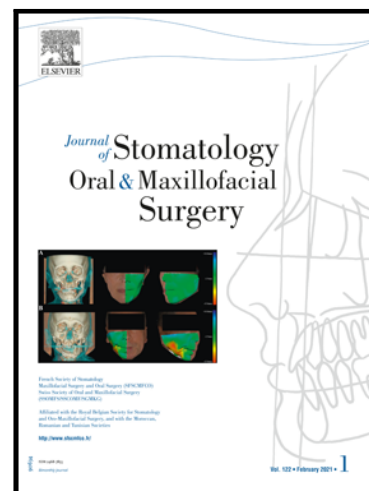


## Journal Pre-proof

Retrospective evaluation of traction time for impacted dilacerated maxillary central incisors in mixed dentition

Betul Sen Yavuz , Ahu Yilmaz , Eda Haznedaroglu ,  
Berkant Sezer , Alev Eda Okutan , Batin Ilgit Sezgin ,  
Mert Ozcelik , Gokce Ildes Sezgin , Faysal Ugurlu , Ali Menten

PII: S2468-7855(23)00107-6  
DOI: <https://doi.org/10.1016/j.jormas.2023.101485>  
Reference: JORMAS 101485



To appear in: *Journal of Stomatology oral and Maxillofacial Surgery*

Received date: 20 February 2023  
Accepted date: 24 April 2023

Please cite this article as: Betul Sen Yavuz , Ahu Yilmaz , Eda Haznedaroglu , Berkant Sezer , Alev Eda Okutan , Batin Ilgit Sezgin , Mert Ozcelik , Gokce Ildes Sezgin , Faysal Ugurlu , Ali Menten , Retrospective evaluation of traction time for impacted dilacerated maxillary central incisors in mixed dentition, *Journal of Stomatology oral and Maxillofacial Surgery* (2023), doi: <https://doi.org/10.1016/j.jormas.2023.101485>

This is a PDF file of an article that has undergone enhancements after acceptance, such as the addition of a cover page and metadata, and formatting for readability, but it is not yet the definitive version of record. This version will undergo additional copyediting, typesetting and review before it is published in its final form, but we are providing this version to give early visibility of the article. Please note that, during the production process, errors may be discovered which could affect the content, and all legal disclaimers that apply to the journal pertain.

© 2023 Elsevier Masson SAS. All rights reserved.

## Retrospective evaluation of traction time for impacted dilacerated maxillary central incisors in mixed dentition

**Running Title:** Traction of impacted dilacerated incisors

Betul Sen Yavuz<sup>a\*</sup>, Ahu Yilmaz<sup>a</sup>, Eda Haznedaroglu<sup>a</sup>, Berkant Sezer<sup>b1</sup>, Alev Eda Okutan<sup>c1</sup>,  
Batin Ilgit Sezgin<sup>d1</sup>, Mert Ozcelik<sup>e1</sup>, Gokce Ildes Sezgin<sup>f1</sup>, Faysal Ugurlu<sup>g</sup>, Ali Mentese<sup>a</sup>

<sup>a</sup> Department of Pediatric Dentistry, School of Dentistry, Marmara University, Istanbul, Turkey

<sup>b</sup> Department of Pediatric Dentistry, School of Dentistry, Çanakkale Onsekiz Mart University, Çanakkale, Turkey

<sup>c</sup> Department of Pediatric Dentistry, School of Dentistry, Istanbul Atlas University, Istanbul, Turkey

<sup>d</sup> Department of Pediatric Dentistry, School of Dentistry, Istanbul Kent University, Istanbul, Turkey

<sup>e</sup> Department of Pediatric Dentistry, School of Dentistry, Istanbul Istinye University, Istanbul, Turkey

<sup>f</sup> Private Practice, Istanbul, Turkey

<sup>g</sup> Department of Oral and Maxillofacial Surgery, School of Dentistry, Marmara University, Istanbul, Turkey

**\* Corresponding Author:** Betül Şen Yavuz

Full Postal Address: Marmara University, School of Dentistry, Basibuyuk yolu 9/3, 34854,  
Basibuyuk, Maltepe / Istanbul, Turkey

Telephone: +90(539)-988-7646

E-mail Addresses: [dtbetulsen@gmail.com](mailto:dtbetulsen@gmail.com)

Betul Sen Yavuz ORCID: 0000-0002-7561-8396 [dtbetulsen@gmail.com](mailto:dtbetulsen@gmail.com)

Ahu Yilmaz ORCID: 0000-0002-0605-1250 [ahu.durhan@marmara.edu.tr](mailto:ahu.durhan@marmara.edu.tr)

Eda Haznedaroglu ORCID: 0000-0003-0792-2465 [ehaznedaroglu@marmara.edu.tr](mailto:ehaznedaroglu@marmara.edu.tr)

Berkant Sezer ORCID: 0000-0001-9731-6156 [dt.berkantsezer@gmail.com](mailto:dt.berkantsezer@gmail.com)

Alev Eda Okutan ORCID: 0000-0001-9399-5761 [eda.okutan@atlas.edu.tr](mailto:eda.okutan@atlas.edu.tr)

Batin Ilgit Sezgin ORCID: 0000-0001-9578-9611 [batinilgit.sezgin@kent.edu.tr](mailto:batinilgit.sezgin@kent.edu.tr)

Mert Ozcelik            ORCID: 0000-0002-3331-5178 [mert.ozcelik@istinye.edu.tr](mailto:mert.ozcelik@istinye.edu.tr)  
Gokce Ildes Sezgin    ORCID: 0000-0002-5728-4476 [gokce.ildes@arident.com.tr](mailto:gokce.ildes@arident.com.tr)  
Faysal Ugurlu         ORCID: 0000-0002-6509-2298 [faysal.ugurlu@marmara.edu.tr](mailto:faysal.ugurlu@marmara.edu.tr)  
Ali Mentés             ORCID: 0000-0002-2778-6803 [amentes@marmara.edu.tr](mailto:amentes@marmara.edu.tr)

Journal Pre-proof

**Author contributions**

All authors have read and agreed to the published version of the manuscript.

**Funding**

This research did not receive any specific grant from funding agencies in the public, commercial, or not-for-profit sectors.

**Ethical approval**

The Clinical Research Ethical Committee of the School of Dentistry, Marmara University assessed and approved the study protocol with approval number 2023-123. The procedures used in this study adhere to the tenets of the Declaration of Helsinki.

**Informed consent**

For this type of study, formal consent is not required.

**Declaration of Competing Interest**

The authors declare that he has no known competing financial interests or personal relationships that could have appeared to influence the work reported in this paper.

**CRedit authorship contribution statement**

All authors contributed to the study conception and design. Material preparation, data collection, and analysis were performed by B.S.Y., A.Y., E.H., B.S., and A.M. The first draft of the manuscript was written by B.S.Y. and A.M. and all authors commented on previous versions of the manuscript. All authors read and approved the final manuscript.

## Abstract

**Purposes:** This study aimed to contribute to understanding the factors affecting the time of traction treatment of impacted dilacerated maxillary central incisors.

**Methods:** This retrospective study included children aged 8 – 11 years with a history of trauma, who applied to the pediatric dentistry clinics of Marmara University, School of Dentistry, between December 2013 and December 2019, and were treated for unilateral impacted dilacerated maxillary upper central incisors. Children's age, sex, digital panoramic radiographs, cone-beam computed tomography, and intraoral photographs were retrieved from electronic dental health records. The effects of children's age, sex, the direction of impacted teeth, distance of the teeth to the top of the alveolar crest, and root dilaceration level on traction time were analyzed by Mann-Whitney U test and Spearman's rank correlation coefficient test.

**Results:** The inverse position of the incisors significantly increased the traction time ( $P = 0.012$ ). However, the traction time did not differ according to the sex of the children ( $P = 0.707$ ) or the level of root dilaceration ( $P = 0.429$ ). No correlation was observed between the traction time and the age of children ( $P = 0.644$ ) or the distance of the incisors from the top of the alveolar crest ( $P = 0.397$ ).

**Conclusions:** In cases of the forced eruption of for the impacted dilacerated maxillary central incisors, the direction of the teeth should be evaluated when deciding on the treatment plan, as it may affect the treatment time.

**Keywords:** *Dilaceration; forced eruption; impacted tooth; incisor; inverse tooth*

## 1. Introduction

Dilaceration is the angulation or bending of the crown or root, with the calcified portion of the permanent tooth germ displaced, forming an angle to the rest of the germ. The most common cause of dilaceration in permanent teeth is primary tooth avulsion or intrusion, especially before the age of five. Other causes other than mechanical trauma are; developmental anomaly of the primary tooth germ, ankylosis of primary tooth, root canal infections, tooth transplantation, extraction of primary teeth; the influence of anatomical structures such as adjacent supernumerary teeth; the effect of the nasal fossa on tooth formation; ectopic development of permanent tooth germ, facial clefts, hypermobility type of Ehlers-Danlos syndrome; orotracheal intubation and laryngoscopy [1-2]. The prevalence of dilaceration in permanent teeth is approximately 3.8%, half of which are impacted whereas for the upper central incisors, the dilaceration ranged between 0.4 - 1.2%, and the impaction incidence ranged between 0.006% - 1.96% [3-5].

Patients with impacted dilacerated maxillary central incisors usually apply to the dentist in early mixed dentition with aesthetic complaints due to the delayed eruption of permanent teeth or unexfoliated primary teeth, therefore pediatric dentists primarily encountered these cases [2,6]. If the contralateral tooth has erupted six months or earlier, it can be considered a delayed eruption, and space loss could be observed as adjacent teeth drift into the space of the impacted tooth [7]. Treatment of the impacted central incisors due to dilaceration is complicated and requires a multidisciplinary approach [3,6]. Many factors are taken into account when deciding on the appropriate treatment of impacted dilaceration incisors for the patient and the treatment time. Social factors such as the cooperation of the children and their parents, as well as conditions determined by intraoral examination, such as the eruption of the contralateral tooth, are some of these. As a result of the evaluation with panoramic radiography and CBCT, the patient's chronological and dental age, the position of the impacted incisor, and the level of root development are also important considerations in the treatment decision [7-10]. The first treatment option in these cases is the orthodontic space creation and traction of the impacted incisor [3,6]. For orthodontic traction of an impacted tooth, preoperative orthodontic treatment is applied to prepare the appropriate space for the impacted tooth, before the attachment is placed with a surgical operation [11]. When other treatments have failed, the extraction of the impacted central incisors is considered as the last treatment option. After the extraction, this space can be restored with a bridge or an implant, or the lateral incisor can be reshaped to simulate the presence of central incisors after the lateral incisor is aligned orthodontically in this space [3,6,11].

Traction treatment of impacted central incisors depends on the following factors: the age of the patient, the presence of root dilaceration, initial crown height, and incisor length [7,8,9]. This may

be related to the increased bone remodeling required as the density and length of the bone through which the incisors must pass [5]. It has also been reported that traction is more successful in incisors with incomplete root development [12]. In addition, the presence of sufficient space for the incisor is a crucial factor [1,6]. Many complications can be seen depending on the time of traction treatment, the surgical technique applied, the traction movements applied, the age of the patient, and the root development status of the incisor [3,6,7,13-15].

This study aimed to contribute to the understanding of the factors affecting the treatment of impacted dilacerated maxillary central incisors from the surgical attachment to the appearance of the tooth in the mouth. The null hypothesis there is no statistically significant difference between horizontal and inverse impacted dilacerated central incisors from the surgical attachment procedure until they were seen in the mouth for the traction time. The following secondary null hypotheses were also addressed: the traction times of impacted dilacerated central incisors from the surgical attachment procedure to their intraoral exposure did not differ according to the level of dilaceration, the sex of the children, the age of the children, and the distance of the incisal edge of the tooth from the alveolar crest.

## **2. Materials and Methods**

### *2.1. Ethical approval and sampling criteria*

The study protocol was assessed and approved by the Clinical Research Ethical Committee of Marmara University Faculty of Dentistry Committee with approval number 2023-123. The procedures used in this study adhere to the tenets of the Declaration of Helsinki.

This retrospective study included children aged eight – 11 years who were admitted to the pediatric dentistry clinics, School of Dentistry, Marmara University between December 2013, and December 2019, who were treated due to unilateral impacted dilacerated maxillary central incisor, who had a history of trauma up to five years of ages, who had an Angle Class I molar relationship, and who were in the mixed dentition at the beginning of the treatment. The children were determined by scanning the electronic dental records of the School of Dentistry, Marmara University. Children with systemic disease, children with incomplete diagnostic and treatment records, including pre-and post-treatment cone-beam computerized tomography (CBCT), or whose radiographs were diagnostically unacceptable, and children in the permanent dentition at the initial were excluded from the study. Age, sex information, the number of impacted dilacerated teeth according to the World Dental Federation notation (FDI), digital panoramic radiographs, CBCT, and intraoral photographs taken during the eruption guidance treatments of children included in the study were obtained from the electronic dental record.

## 2.2. Sample size calculation

The minimum sample size was calculated based on the 0.53% prevalence of root dilaceration in maxillary central incisors reported by study Malcic et al. [16]. The minimum number of samples was calculated with a 95% confidence interval ( $\alpha = 0.05$ ) and 95% test power ( $1-\beta$ ) according to the formula below [17], and the minimum number of samples to be included was nine.

$$n = \frac{t^2 pq}{d^2}$$

$n$ : sample size

$p$ : the prevalence or proportion of event

$q$ :  $1 - p$

$t$ : value in t table according to the degree of freedom and degree of error

$d$ : margin of error with which a researcher wants to measure something

Since the calculation was made according to the 0.05 significance level, 't' was accepted as 1.96 for the two-tailed alternative hypothesis [17].

$$n = (1.96)^2 \cdot (0.0053) (0.9947) / (0.05)^2 = 8.1 \approx 9 \text{ Children}$$

## 2.3. Treatment Protocol

Nance appliance was inserted in all children prior to orthodontic treatment to provide additional anchorage. The alignment process was started with fixed orthodontic appliances. In **Figure 1**, the treatment steps of a 7-year-old male were presented. Brackets (Supertech, Sia Orthodontic Manufacturer, Caserta, Italy) were bonded only on the fully erupted maxillary permanent teeth. Each pediatric dentist treated one child (except for A.Y. who treated two) under the supervision of the study advisor (A.M.).

The leveling and alignment of the permanent teeth were initiated with the correction of the midline. The pre-surgery space was gained with an open coil spring, taking the width of the contralateral permanent central incisor measured using a digital caliper (Mitutoyo Digital Caliper, Japan) as a reference. Then, the space was maintained with plastic sleeves. Since the children were in mixed dentition, new brackets were bonded on the erupting teeth during the treatment period.

The standardized closed eruption technique was used for traction of the impacted central incisor and the surgery was performed by the same dental surgeon (F.U.) assisted with a pediatric dentist. The full-thickness mucoperiosteal buccal flap was surgically raised to expose the tooth. The bone covering the crown of the tooth was removed, a lingual attachment was placed on the palatal

surface of the crown and a light force was applied in order to sublunate for easy traction of the tooth. The attachment was tied to the plastic sleeve of the archwire with a twisted 0.009-in stainless steel ligature wire, the ligature wire was drawn inferiorly and the flap was fully repositioned back to its former place and was securely sutured. The extrusive traction force on the impacted tooth was initiated post-surgically one week later. In only one case, the surgical procedure was performed under general anesthesia.

The children were scheduled once a month, and a light extrusive traction force was inserted by unraveling and shortening the ligature wire in each appointment until the palatal surface of the tooth was exposed. Four teeth were exposed naturally and in five cases, when the teeth became entirely palpable and prominent in the labial gingiva, the labial crowns of the teeth were opened using an 810 nm; 2.5 W diode laser (Gigaa Laser, China) with a 400  $\mu\text{m}$  fiber tip and pulsed mode, and the attachments were debonded and substituted labially to brackets in all cases. After the brackets were bonded, the traction was continued using elastic power chains or ligature wires attached to the plastic sleeves, with/without a 0.012-in Nickel Titanium (NiTi) auxiliary archwire (**Figure 2**).

At the end of treatments, all erupted central incisors were vital on pulp testing and there were no signs and symptoms of pulpal disease clinically and radiographically. Lingual retainers were bonded to the six upper incisors and a fluoride varnish (MI Varnish, GC, America, USA) was applied to each tooth.

#### *2.4. Panoramic Radiographs and Dental Volumetric Tomography*

Digital panoramic radiographs with the Morita device (VeraView IC5, J. Morita MFG. Corporation, Kyoto, Japan) and cone-beam computed tomography (CBCT) with the Planmeca ProMax® 3D Mid unit (Planmeca Oy, Helsinki, Finland) were taken in the oral and maxillofacial radiology clinics of the School of Dentistry, Marmara University. The operating parameters were 7.5 mA, 60–70 kV, 8.8 s for the Morita device, and 5.6 mA, 90 kV, 13.5 s exposure time for the Planmeca device. Twelve radiographs were categorized by consensus by two pediatric dentists (B.S.Y. and A.Y.) according to national guidelines published by the National Radiological Protection Board quality standards. These quality standards state that “at least 70% of all radiographs should be grade 1 (diagnostically excellent), less than 20% should be grade 2 (diagnostically acceptable), and less than 10% should be grade 3 (diagnostically unacceptable)” [18]. Grade 1 and 2 radiographs were included in this study.

Twelve children who met the inclusion criteria of the study were determined. Since two of these children lost all primary teeth before the treatment had started and one had grade 3 panoramic radiography according to the diagnostic criteria were excluded from the study.

### 2.5. Evaluation Procedure

Children were assigned numbers from one to nine for anonymity when data were obtained from electronic dental records. Root dilaceration was defined as a deviation equal to or greater than 90 degrees from the normal tooth axis on pre-treatment CBCT [5]. From these records, the dates when the children started treatment, traction force was applied to the tooth, and other control appointments were recorded. The intraoral exposure time of the tooth was calculated (in months) by subtracting the time when the attachment is surgically bonded and the traction force started, from the time the tooth appeared in the mouth as exposure through the mucosa. By subtracting the dates of birth from the date of initiation of the treatment, the ages at which the children started the treatment were obtained. In the panoramic radiographs, the distance between the top of the maxillary alveolar crest and the incisal edge of the impacted dilacerated central incisor was measured with Image J Version 1.42q (NIH, USA) software, the positions of the impacted teeth (horizontal or inverse) and the level of root dilaceration of the teeth (coronal or apical half) were recorded. All measurements were made by a pediatric dentist (B.S.Y.) with six years of clinical experience under the supervision of the study advisor (A.M.).

### 2.6. Statistical analysis

After the compatibility of numerical variables to normal distribution was tested with the Shapiro-Wilk test and the Mann-Whitney U test was used to compare non-normally distributed variables in two independent groups. Spearman's rank correlation coefficient test was used to analyze (the children's age and distance to the alveolar crest – traction time of teeth). Data analysis was performed using the SPSS Version 26.0 (IBM Corporation, Chicago, Illinois, United States of America) software. The significance levels were set at  $P < 0.05$ .

## 3. Results

When the post-hoc analysis was examined by taking 5 incisors for the reverse impacted group and 4 incisors for the horizontally impacted group, the power of the test was 99.2% ( $1-\beta$ ) with 95% confidence ( $1-\alpha$ ) and an effect size of  $d = 3.445$ .

The mean age ( $\pm$  standard deviation [SD]) of nine children (4 females, 5 males) who met the inclusion criteria of the forced eruption of the impacted dilacerated maxillary central incisor in the six-year period was  $9.78 \pm 1.23$  (ages range from 8 to 11 years). All patients had a record of trauma history to the front upper teeth at ages 2 to 5. Seven out of the nine incisors were #21. Panoramic radiographs showed that five teeth were positioned horizontally, and four were inversed.

Dilaceration level was in the cervical half of the root in three teeth and the apical half in six teeth. All children were in mixed dentition and had an Angle Class I molar relationship.

At the initial, midline shift was detected in six (66.7%) children. The mean time of the pre-surgery treatment to gain adequate space for the impacted teeth ranged between 2 and 5 appointments in nine cases depending on the shift of the adjacent teeth. The mean time ( $\pm$  SD) for teeth to appear in the mouth after the traction was  $9.67 \pm 3.08$  months. The median exposure time of the inverted teeth was statistically higher than the horizontally positioned teeth ( $P = 0.012$ ), but the median exposure time was not statistically different according to the level of root dilaceration ( $P = 0.429$ ) (**Table 1**). Initially, the mean distance from the incisal edge of the central incisors to the top of the alveolar crest was  $8.77$  mm ( $\pm 0.97$ ) but either this gap or the age of the children did not correlate with the exposure time (**Table 2**).

At the end of treatments, the apices of the erupted teeth could be palpated as a bulge in the labial sulcus in two children. In **Figure 3**, the initial position, the traction, and the final position of the tooth apex of the left central incisor were shown in an 8-year-old male. Poor general gingival health but acceptable contours were observed in six children due to inadequate oral hygiene. **Figure 3** also showed white spot lesions in the enamel tissue around the brackets.

#### 4. Discussion

This study aimed to evaluate the effects of the direction of the teeth, the level of root dilaceration, the age of the children, the sex of the children, and the distance of the teeth from the alveolar crest on the traction time of the impacted dilacerated maxillary incisors. While the direction of the tooth increased the traction time, the traction time did not change according to the other factors. Therefore, the primary null hypothesis of the study was rejected, while the secondary null hypotheses were accepted.

It was reported that one-third of children under the age of seven are exposed to at least one primary tooth trauma [19]. Since the root of the primary central incisor is related to the successional permanent central incisor, the tooth is displaced in the socket as a result of the axial trauma force on the primary tooth. Primary tooth intrusion might cause dental anomalies such as permanent tooth hypoplasia, root angulation or dilaceration, crown dilaceration, eruption disturbances, and partial or complete arrest of root formation depending on the age at which the child is traumatized [20]. de Amorim et al. [21] reported that crown dilacerations were more common in children who had trauma before the age of three, and root dilacerations were more common in children who were traumatized between 3 and 5 years of age. This study included children aged 2 to 5 years with root dilacerations due to trauma history. Dilaceration of the incisors is the primary cause of 10-16% of

impacted maxillary incisors [20]. The treatment modalities used for impacted dilacerated maxillary incisors can be listed as follows: orthodontic traction of impacted incisor, orthodontic closure with lateral incisor after extraction of impacted incisor, bridge after extraction of impacted incisor, implant after extraction of impacted incisor, surgical repositioning, and auto transplantation [3,6,8,11,22,23]. Although there are many case reports about orthodontic traction of impacted incisors in the literature [1,3,6,8,9,11], few studies evaluate the factors affecting the traction time of these teeth [4,5,7]. Bhikoo et al. [7] also emphasized that the treatment time of inverse impacted teeth is still uncertain. Therefore, this study was planned to evaluate the factors affecting the orthodontic traction times of inverse and horizontally impacted teeth.

While Asker et al. [24] reported that the incidence of dilaceration was six times higher in males than in females, a study by Jafarzadeh et al. stated that there was no difference between the sexes [2]. In this present study, the distribution of children with impacted dilacerated incisors was equal in both sexes. Unlike this study, Lygidakis et al. [4] reported that 74% of patients with impacted incisors were male, but they also reported that the reason for this bias was supernumerary teeth. In addition, in this study, the traction time of the teeth did not differ according to sex.

Children aged eight to 11 years were treated in the current study, and as an unexpected finding, no correlation was found between the age of the children and the traction time. These results differed from several published studies [5,7,25,26]. These studies reported that impacted incisors erupted orthodontically in a shorter time in younger children and attributed this to younger children having relatively lower bone density [25]. The difference in this study may be due to the limited age range analyzed as solely children in mixed dentition were included. In addition, another advantage of early treatment is that it contributes to a better bone morphology with less alveolar bone loss in the labial of the incisor, thanks to continuous root development [7]. In agreement with these findings, Hu et al. also stated that early treatment provides a better prognosis in the traction treatment of inversely impacted incisors [15]. Dentists tend to expect impacted central incisors to erupt spontaneously, thus early diagnosis of dilaceration is important to provide better bone morphology [5]. Early treatment positively guides the shape of the developing root [27,28].

In addition to two-dimensional panoramic and periapical radiographs, three-dimensional cone beam computed tomography is also used in the planning of the traction of impacted central incisors. However, finite element analysis (FEA), one of the prominent methods today, can be beneficial in estimating bone change, the stress in the bone or periodontal tissues as a result of orthopedic force application, and consequently the direction of force to be applied [13,14]. There are several studies in the literature using the FEA method in the traction of impacted teeth [29,30]. This method may also be used in planning the traction of impacted central incisors.

The importance of sufficient space for the impacted incisor before starting traction has been emphasized in previous studies [4,9]. The mean pre-surgery orthodontic treatment time in Lygidakis et al.'s study [4] was three months, and the researchers stated that space opening treatment would be beneficial for patients to get used to the treatment with orthodontic procedures relatively easier before surgery. In this study, pre-surgery orthodontic treatment was applied to nine children, and it ranged between two and five months. As stated previously [4], this pretreatment might have contributed to the cooperation of the children for the surgical procedure, and thus, general anesthesia might have been required in only one of these younger children.

Previous studies have reported that the closed surgical technique for the traction of impacted teeth is superior to the open [4,15,31,32]. Although gingival overgrowth due to more crestal bone formation is observed in half of the patients after closed surgery, the closed technique provides better aesthetic and periodontal health, bone support, shorter clinical crown length, and shorter traction time [4,31,32]. Asker et al. [24] reported that the second open surgery (apically repositioned flap) performed when the time the incisor is palpable in the labial gingiva resulted in poor periodontal esthetics. In the current study, closed eruption surgery was performed in all children, and a diode laser was applied to five of the erupting incisors before applying brackets, and all of the children had acceptable gingival contours.

Gold chains, magnets, or ligature wires can be used for the traction of impacted teeth. Magnets are no longer preferred due to corrosion in the intra-oral environment, and the decrease in the applied force as the distance between magnets changes. Although gold chains are strong and suitable materials, they are expensive and difficult to apply with closed surgery compared to ligature wires. The chain must be held with locking tweezers to prevent it from slipping inside the flap edges during the suturing period, from bonding to the tooth to attaching the archwire. The stainless steel ligature wires are twisted and loosely suspended until the suture is complete before they are attached to the tooth. It is also inexpensive and widely available. However, both attachments can debond against heavy occlusal forces [33]. In this study, removing the bone covering the crown of incisors before starting traction, subluxation of incisors, bonding the buttons to the easily accessible palatal surface of crowns, and always using light force may have prevented the attachment from debonding. In addition, first the vertical movement of incisors and then the rotation movement was provided.

In the study, the mean traction time from the surgical procedure to the eruption of the incisors was 9.67 months. Although this time is similar to some previous studies [4,5], it is shorter than several studies [7,26]. One of these studies reporting a longer traction time provided traction of inversely impacted incisors using the Guide Rod appliance [7] and another included even impacted

teeth with obstructions in the eruption route [26]. A study evaluating orthodontic traction of incisors with dilacerated roots and incisors with straight roots stated that dilaceration significantly increased the time as they required more bone remodeling but did not affect the total orthodontic treatment time or retention time [5]. Furthermore, it has been reported that a lower crown-root angle (a higher degree of dilaceration) increased the traction time [7,15].

Studies evaluating the effect of impacted tooth direction on treatment time have reported different results. A study reported there was no statistically significant relationship between the traction time and the angle of the long axis of the teeth with delayed eruption due to supernumerary teeth [34]. However, another study reported there was a statistically significant relationship between the total treatment time and the angle of the long axis of the impacted tooth due to several different reasons such as odontoma and dilaceration [4]. Nevertheless, several studies have reported a positive correlation between the distance of the incisal edge of the teeth to the alveolar crest or occlusal plane and the treatment time [4,34]. In line with these studies, the correlation analysis was performed assuming that the exposure time to the mouth would be higher at a thicker alveolar crest distance, but no correlation was found. Moreover, inverse teeth erupted into the mouth statistically longer than teeth in the horizontal position. Bhikoo et al. [7] reported that the longer the crown and the longer the tooth, the greater the traction time. The common reason for the effect of these factors on the traction time might be the bone distance and bone surface which were required for erupting of the tooth. It has been reported that the delay in eruption time and root maturity did not affect the traction time of the teeth [4]. However, Foley et al. reported that the traction of immature teeth was more successful than mature teeth [35]. In the current study, the effect of the dilaceration level has also not been found on traction time. In 2020, in situ rotation surgery, a new approach for inverse impacted central incisors, was presented as a case report [36]. Although it is stated that the treatment time with fixed orthodontic appliance was shortened with this approach, which includes surgical repositioning of the tooth, it has been reported that the total treatment is approximately seven months, with the time of the spontaneous eruption. More clinical studies are needed for preference by practitioners in clinical practice.

The common complications as a result of a forced eruption of impacted incisors with the dilacerated root and inverse or horizontally positioned crown were as follows: ankylosis, attachment loss, external root resorption, pulp necrosis, pulp canal obliteration, crown discoloration, root exposure, unaesthetic gingival margin [2,3,6,7,24]. Factors to affect the success of traction were the degree of dilaceration, the position and direction of the tooth, and the existence of sufficient space for the impacted tooth [1,6]. Furthermore, Shi et al. [5], highlighted that forced eruption at younger ages resulted in less root resorption. In this study, children in mixed dentition

were assessed and adequate space was gained for impacted teeth before the traction. Although dilacerated incisors angled at 90 degrees were included, most of these complications were not observed. The most important complication detected was the palpable roots in the labial gingiva of two children, Becker et al. [27] recommended the amputation of the palpable root apex and the root canal treatment with an orthograde and retrograde approach. In the present study, teeth were only monitored because they were still vital. A systematic review evaluating the status of impacted central incisors after surgical-orthodontic traction indicated that the erupting teeth had less bone thickness and support and shorter root length compared to the control group [37]. Moreover, in the closed eruption surgery technique, negative aesthetic effects such as an increase in crown height, excessive gingival enlargement, and drifting are less common than in the apically positioned flap or open eruption surgery technique [1,31]. In addition, no difference was observed in oral hygiene around the impacted incisors after closed and open eruption surgery [31]. In the present study, acceptable periodontal health and bone support were observed during and after treatment after closed eruption surgery. Although gingival edema was observed around the crown after the central incisor was exposed in the mouth, this may be related to the difficulty of maintaining oral hygiene in that area due to the angle of the crown. There is a need for further studies in the literature on this subject with a larger sample group and clinical long-term evaluation of different methods.

The strengths of this study were performing a standardized surgical technique by a single dental surgeon for the exposure of all teeth and the evaluation of impacted incisors only due to dilaceration. Thus, the effect of differences in surgical technique on traction time was eliminated. However, the small sample size was also a limitation due to the low prevalence of impacted dilacerated incisors. Although the small sample size reduces the statistical significance of the analysis, the findings have clinical significance. However, even though the power of this study is high, further multi-center studies are needed in the literature to reach larger sample sizes and increase statistical significance. Another limitation of the study was investigating the incisors' position as horizontal and inverse. Whereas Lyu et al. [38] reported that the angle of root dilaceration differs in all pairwise comparisons, when they evaluated the position of dilacerated teeth in three directions as palatal, labial, and nasal (inverse).

The traction of impacted dilacerated incisors could cause many complications, and forced eruption of incisors was a long-term treatment that requires the cooperation of the child, parents, and dentist. This treatment modality might require surgical exposure of the teeth and laser excision as in this study. While deciding on the treatment, the cooperation of the child, the capability of the dentist, the management of complications, as well as the treatment time was also a crucial criterion to be considered. We may conclude that the treatment of the impacted dilacerated incisors is not

affected by the level of root dilaceration, the child's sex, the child's age, and the distance of the incisors to the alveolar crest, however, the inverse position of incisors increases the treatment time.

Journal Pre-proof

**References**

- [1] Chew MT, Ong MM. Orthodontic-surgical management of an impacted dilacerated maxillary central incisor: a clinical case report. *Pediatr Dent* 2004;26(4):341–4.
- [2] Jafarzadeh H, Abbott PV. Dilaceration: review of an endodontic challenge. *J Endod* 2007;33(9):1025–30. <https://doi.org/10.1016/j.joen.2007.04.013>
- [3] Kuvvetli SS, Seymen F, Gencay K. Management of an unerupted dilacerated maxillary central incisor: a case report. *Dent Traumatol* 2007;23(4):257–61. <https://doi.org/10.1111/j.1600-9657.2005.00424.x>
- [4] Lygidakis NN, Chatzidimitriou K, Theologie-Lygidakis N, Lygidakis NA. Evaluation of a treatment protocol for unerupted maxillary central incisors: retrospective clinical study of 46 children. *Eur Arch Paediatr Dent* 2015;16(2):153–64. <https://doi.org/10.1007/s40368-014-0150-z>
- [5] Shi X, Sun X, Wang X, Zhang C, Liu Y, Quan J, et al. The effect of the root dilaceration on the treatment duration and prognosis of unilateral impacted immature maxillary central incisors. *Am J Orthod Dentofacial Orthop* 2023;163(1):79–86. <https://doi.org/10.1016/j.ajodo.2021.08.027>
- [6] Uematsu S, Uematsu T, Furusawa K, Deguchi T, Kurihara S. Orthodontic treatment of an impacted dilacerated maxillary central incisor combined with surgical exposure and apicoectomy. *Angle Orthod* 2004;74(1):132–6. doi:10.1043/0003-3219(2004)074<0132:OTOAID>2.0.CO;2
- [7] Bhikoo C, Xu J, Sun H, Jin C, Jiang H, Hu R. Factors affecting treatment duration of labial inversely impacted maxillary central incisors. *Am J Orthod Dentofacial Orthop* 2018;153(5):708–15. <https://doi.org/10.1016/j.ajodo.2017.09.017>
- [8] Singh H, Kapoor P, Sharma P, Dudeja P, Maurya RK, Thakkar S. Interdisciplinary management of an impacted dilacerated maxillary central incisor. *Dental Press J Orthod* 2018;23:37–46. <https://doi.org/10.1590/2177-6709.23.3.037-046.oar>

- [9] Rudnik M, Kaczmarczyk T, Bednarczyk A, Loster BW. Orthodontic and surgical treatment of a patient with an impacted upper central incisor with dilacerations—systematic review of the literature with presentation of a case. *J Stoma* 2018;71(3):288–301. <https://doi.org/10.5114/jos.2018.80642>
- [10] Flores MT, Onetto JE. How does orofacial trauma in children affect the developing dentition? Long-term treatment and associated complications. *J Endod* 2019;45(12):S1–2. <https://doi.org/10.1016/j.joen.2019.05.006>
- [11] Pinho T, Carvalho V. Interceptive orthodontic traction of impacted maxillary incisors: clinical cases. *Rev Port Estomatol Med Dent Cir Maxilofac* 2018;59(2):107–14. <http://doi.org/10.24873/j.rpemd.2018.09.230>
- [12] Lin YT. Treatment of an impacted dilacerated maxillary central incisor. *Am J Orthod Dentofacial Orthop* 1999;115(4):406–9. [https://doi.org/10.1016/S0889-5406\(99\)70260-X](https://doi.org/10.1016/S0889-5406(99)70260-X)
- [13] Ammar HH, Ngan P, Crout RJ, Mucino VH, Mukdadi OM. Three-dimensional modeling and finite element analysis in treatment planning for orthodontic tooth movement. *Am J Orthod Dentofac Orthop* 2011;139(1):e59–71. <https://doi:10.1016/j.ajodo.2010.09.020>
- [14] Yu HS, Baik HS, Sung SJ, Kim KD, Cho YS. Three-dimensional finite-element analysis of maxillary protraction with and without rapid palatal expansion. *Eur J Orthod* 2007;29(2):118–25. <https://doi:10.1093/ejo/cjl057>
- [15] Hu H, Hu R, Jiang H, Cao Z, Sun H, Jin C, et al. Survival of labial inversely impacted maxillary central incisors: a retrospective cone-beam computed tomography 2-year follow-up. *Am J Orthod Dentofacial Orthop* 2017;151:860–8. <https://doi.org/10.1016/j.ajodo.2016.10.029>
- [16] Malcic A, Jukic S, Brzovic V, Miletic I, Pelivan I, Anic I. Prevalence of root dilaceration in adult dental patients in Croatia. *Oral Surg Oral Med Oral Pathol Oral Radiol Endod* 2006;102:104–9. <https://doi.org/10.1016/j.tripleo.2005.08.021>

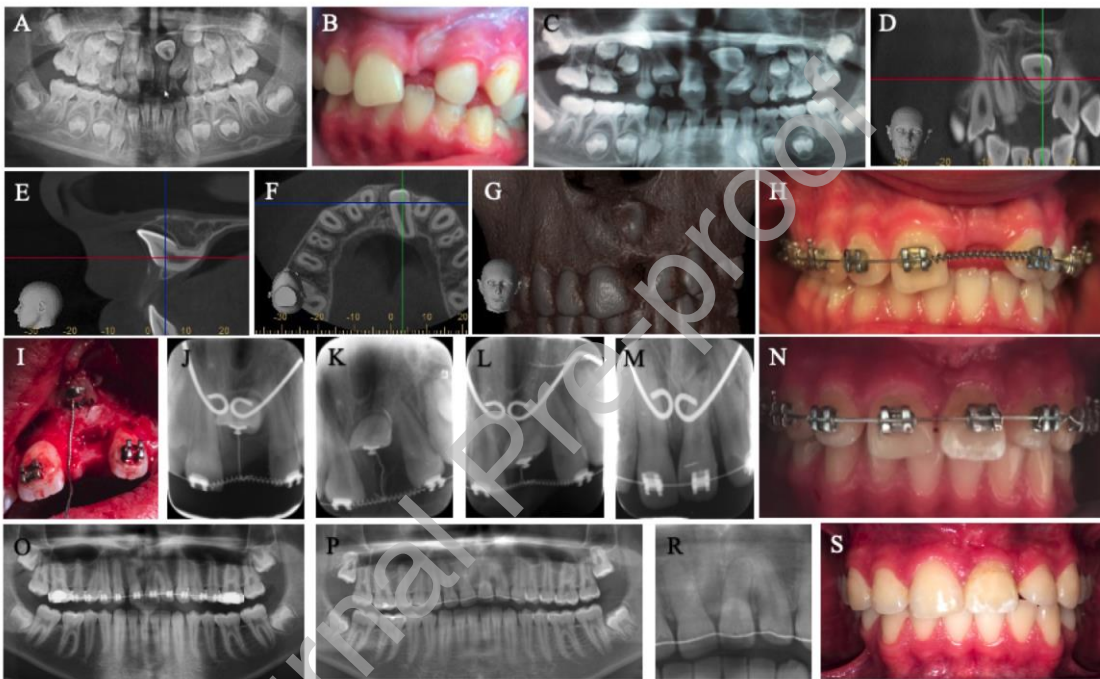
- [17] Suresh KP, Chandrashekara S. Sample size estimation and power analysis for clinical research studies. *J Hum Reprod Sci* 2012;5(1):7. <https://doi.org/10.4103/0974-1208.97779>
- [18] National Radiological Protection Board (NRPB). Guidance notes for dental practitioners on the safe use of X-ray equipment. London, UK: NRPB and Department of Health; 2001.
- [19] Kominami PA, Costa VP, de Lucas Rezende LV, Garcia FC, Almeida JC, Takeshita EM. Traumatic dental injuries in the primary dentition and sequelae in the permanent dentition: a 7-year retrospective study. *Braz Dent Sci* 2022;25(3):e3313. <https://doi.org/10.4322/bds.2022.e3313>
- [20] Altun C, Cehreli ZC, Güven G, Acikel C. Traumatic intrusion of primary teeth and its effects on the permanent successors: a clinical follow-up study. *Oral Surg Oral Med Oral Pathol Oral Radiol Endod* 2009;107(4):493–8. <https://doi.org/10.1016/j.tripleo.2008.10.016>
- [21] de Amorim CS, Americano GC, Moliterno LF, de Marsillac MD, Andrade MR, Campos V. Frequency of crown and root dilaceration of permanent incisors after dental trauma to their predecessor teeth. *Dent Traumatol* 2018;34(6):401–5. <https://doi.org/10.1111/edt.12433>
- [22] Tsai TP. Surgical repositioning of an impacted dilacerated incisor in mixed dentition. *J Am Dent Assoc* 2002;133(1):61–6. <https://doi.org/10.14219/jada.archive.2002.0022>
- [23] Maia RL, Vieira AP. Auto-transplantation of central incisor with root dilaceration. *Int J Oral Maxillofac Surg* 2005;34(1):89–91. <https://doi.org/10.1016/j.ijom.2004.03.009>
- [24] Asker A. Guidelines for orthodontic considerations in impaction of maxillary central incisor with dilaceration. *EC Dent Sci* 2023;22:73–85.
- [25] Ho KH, Liao YF. Predictors of surgical-orthodontic treatment duration of unilateral impacted maxillary central incisors. *Orthod Craniofac Res* 2011;14:175–80. <https://doi.org/10.1111/j.1601-6343.2011.01516.x>
- [26] Chaushu S, Becker T, Becker A. Impacted central incisors: factors affecting prognosis and treatment duration. *Am J Orthod Dentofacial Orthop* 2015;147(3):355–62. <https://doi.org/10.1016/j.ajodo.2014.11.019>

- [27] Becker A. Impacted maxillary central incisors. In: *The orthodontic treatment of impacted teeth*. 4th ed. London: John Wiley & Sons Ltd; 2022, p. 189–267.
- [28] Becker A, Brin I, Ben-Bassat Y, Zilberman Y, Chaushu S. Closed-eruption surgical technique for impacted maxillary incisors: a postorthodontic periodontal evaluation. *Am J Orthod Dentofac Orthop* 2002;122:9–14. <https://doi.org/10.1067/mod.2002.124998>
- [29] Zeno KG, Mustapha S, Ayoub G, Ghafari JG. Effect of force direction and tooth angulation during traction of palatally impacted canines: A finite element analysis. *Am J Orthod Dentofac Orthop* 2020;157(3):377–84. <https://doi.org/10.1016/j.ajodo.2019.04.035>
- [30] Zeno KG, El-Mohtar SJ, Mustapha S, Ghafari JG. Finite element analysis of stresses on adjacent teeth during the traction of palatally impacted canines. *Angle Orthod* 2019;89(3):418–25. <https://doi.org/10.2319/061118-437.1>
- [31] Chaushu S, Dykstein N, Ben-Bassat Y, Becker A. Periodontal status of impacted maxillary incisors uncovered by 2 different surgical techniques. *J Oral Maxillofac Surg* 2009;67(1):120–4. <https://doi.org/10.1016/j.joms.2008.08.012>
- [32] Becker A. Surgical exposure of impacted teeth. In: *The orthodontic treatment of impacted teeth*. 4th ed. London: John Wiley & Sons Ltd; 2022, p. 145–188.
- [33] Becker A. The logistics of orthodontic treatment for impacted teeth. In: *The orthodontic treatment of impacted teeth*. 4th ed. London: John Wiley & Sons Ltd; 2022, p. 54–75.
- [34] Bryan RAE, Cole BOI, Welbury RR. Retrospective analysis of factors influencing the eruption of delayed permanent incisors after supernumerary tooth removal. *Eur J Paediatr Dent* 2005;6(2):84.
- [35] Foley J. Surgical removal of supernumerary teeth and the fate of incisor eruption. *Eur J Paediatr Dent* 2004;5(1):35–40.

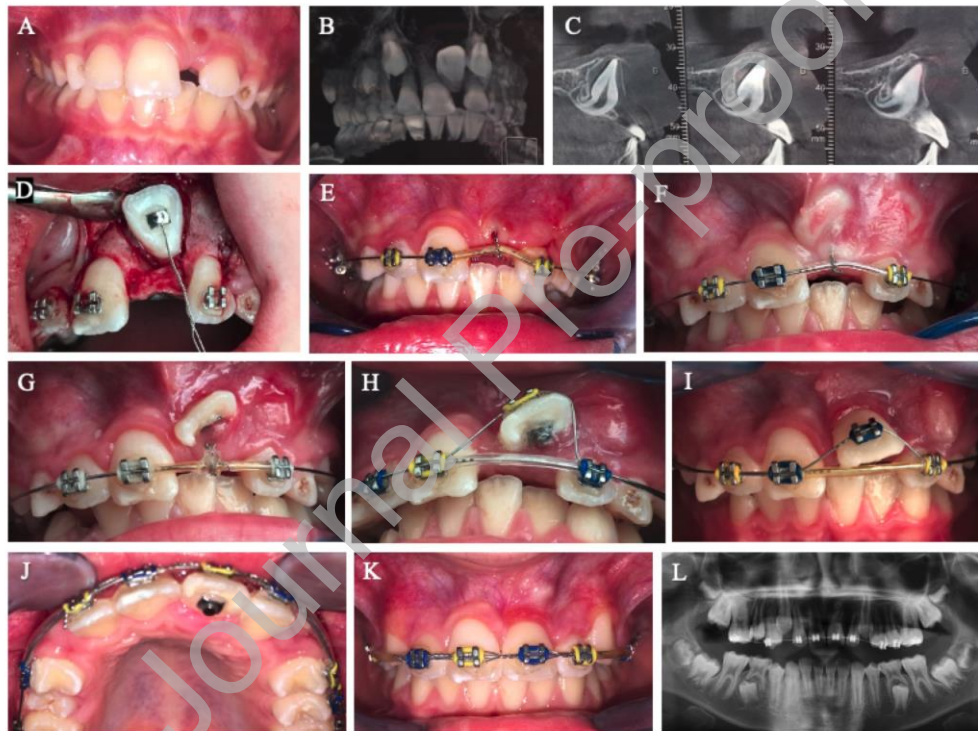
- [36] Shi R, Zhou Z, Li P, Shi L, Sun H, Bai Y. In situ rotation surgery for correction of growing, inversely impacted maxillary central incisors. *Am J Orthod Dentofac Orthop* 2021;159(4):536–44. <https://doi.org/10.1016/j.ajodo.2020.10.023>
- [37] Žaroviėnė A, Grinkeviėienė D, Trakinienė G, Smailienė D. Post-treatment status of impacted maxillary central incisors following surgical-orthodontic treatment: a systematic review. *Medicina* 2021;57(8):783. <https://doi.org/10.3390/medicina57080783>
- [38] Lyu J, Lin Y, Lin H, Zhu P, Xu Y. New clues for early management of maxillary impacted central incisors based on 3-dimensional reconstructed models. *Am J Orthod Dentofac Orthop* 2018;154(3):390–6. <https://doi.org/10.1016/j.ajodo.2017.11.034>

## Figure Captions

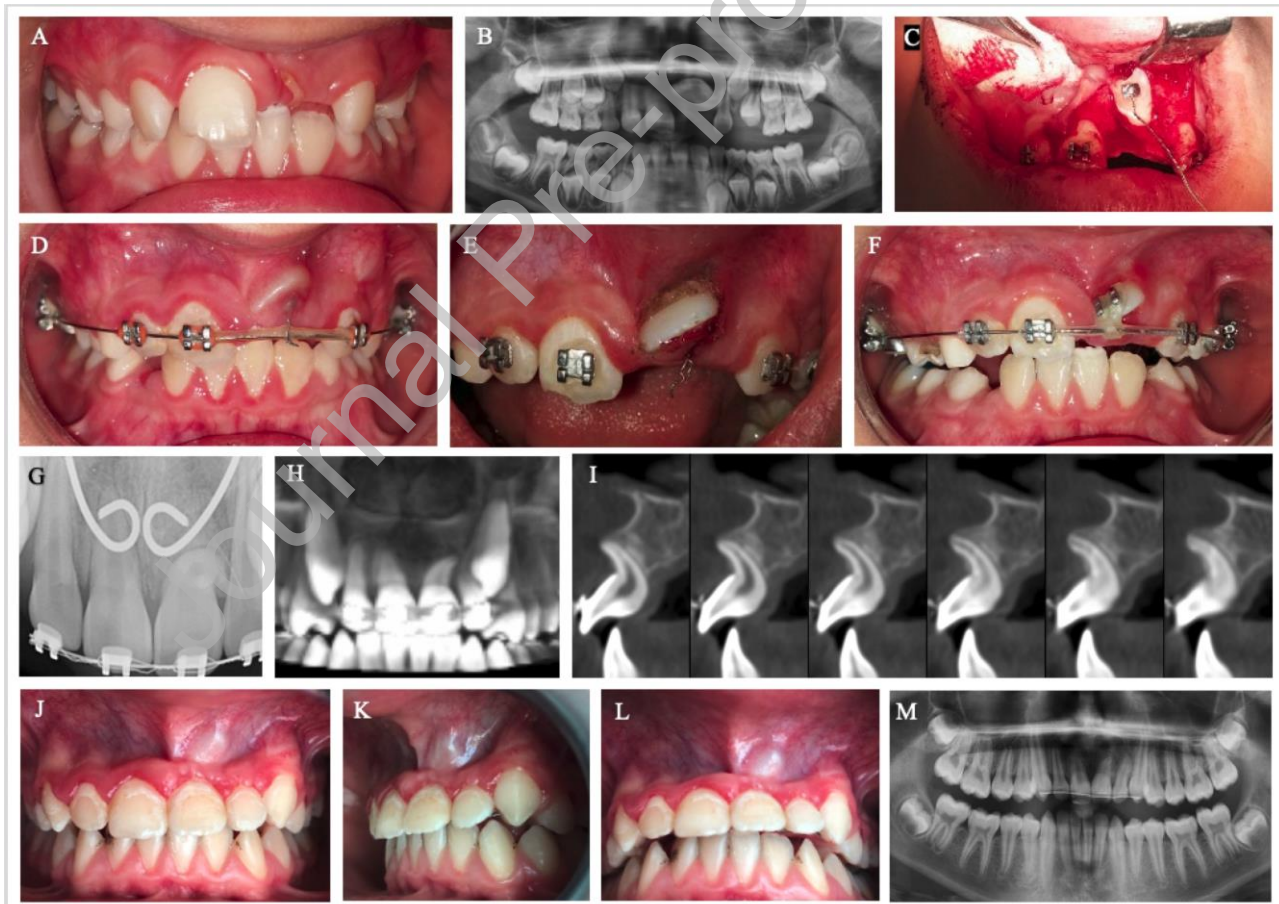
**Figure 1** Treatment progress of the 7-year-old male. A. panoramic radiograph before the eruption of #21, B, C. pretreatment intra-oral photograph and panoramic radiograph, D, E, F, G. the sagittal, axial, coronal views, and 3-dimensional reconstructed images of CBCT, H. after space gaining for the impacted #21 with the open coil spring, I. surgically exposed palatal surface and attachment of the lingual button, J, K, L, M. the steps of closed traction technique, N, O. after orthodontic traction, P, R, S. after a two-year follow-up



**Figure 2** Closed traction technique in an 8-year-old male. A. pretreatment intraoral photograph, B, C. the sagittal and axial CBCT images, D. surgical exposure and attachment of the lingual button to the palatal surface, E, F, G. traction of the impacted tooth with ligature and soft sleeve, and also #21 is seen (F) entirely palpable and prominent in the labial gingiva, H, I. traction with double wire technique, J, K, L. intraoral photographs and panoramic radiography of #21 after alignment. In image K, the root apex of #21 is palpable under the labial gingiva.



**Figure 3** Traction of impacted dilacerated #21 in another 8-year-old male. A, B. pretreatment intraoral photograph and panoramic radiograph, C, D. surgical exposure and traction with ligature, E. diode laser-assisted excision of the labial surface of the tooth, F. continuing traction with vertical power chain, G, H, I. after alignment of teeth, J, K, L, M. posttreatment intraoral photographs, and panoramic radiograph. In images J, K, and L, the root apex of #21 is palpable under the labial gingiva.



**Table 1** The traction time of the impacted tooth in the mouth according to the position of teeth, the level of dilaceration, and sex

	<b>n (%)</b>	<b>Traction time (months)</b> median (min-max) /mean rank	<b>Test value<sup>†</sup></b>	<b>P value</b>
<b>Tooth Position</b>				
<i>Horizontal</i>	5 (55.56%)	8 (7 – 8) / 3	0.000	<b>0.012</b>
<i>Inverted</i>	4 (44.44%)	12 (9 – 16) / 7.5		
<b>The level of root dilaceration</b>				
<i>Cervical half</i>	3 (33.34%)	9 (8 – 13) / 6.0	6.000	0.429
<i>Coronal half</i>	6 (66.67%)	8 (7 – 16) / 4.5		
<b>Sex</b>				
<i>Female</i>	4 (44.44%)	9.5 (7 – 16) / 5.38	8.500	0.707
<i>Male</i>	5 (55.56%)	8 (7 – 13) / 4.7		

n: number, †Mann-Whitney U test, values in bold mean P < 0.05

**Table 2** Correlation between the traction time of teeth and children's age or the distance of the incisal edge of teeth to the alveolar crest

	<b>Traction time (months)</b>	
	<b>Correlation <math>\rho</math>-value<sup>‡</sup> (rho)</b>	<b>P value</b>
<b>Age</b>	- 0.179	0.644
<b>Distance to the crest (mm)</b>	0.323	0.397

<sup>‡</sup> $\rho$ : Spearman's rank correlation coefficients, values in bold mean  $P < 0.05$

Journal Pre-proof