



# Peripheral T-Cell Lymphoma Coexisting with Autoimmune Hemolytic Anemia: Analysis of Clinical Features

Ozlem Candan<sup>1,3</sup> · Narmin Naghizada<sup>2</sup> · Derya Demirtas<sup>1</sup> · Ahmet Mert Yanik<sup>1</sup> · Secil Salim<sup>1</sup> · Meral Ulukoylu Menguc<sup>1</sup> · Fatma Arikan<sup>1</sup> · Asu Fergun Yilmaz<sup>1</sup> · Isik Atagunduz<sup>1</sup> · Ayse Tulin Tuglular<sup>1</sup> · Tayfur Toptas<sup>1</sup>

Received: 15 March 2024 / Accepted: 14 July 2024  
© Indian Society of Hematology and Blood Transfusion 2024

## Introduction

Autoimmune hemolytic anemia (AIHA) is characterized by the production of antibodies targeting red blood cells (RBCs) antigens. The diagnosis is based on the presence of a hemolytic anemia with a positive direct antiglobulin test (or Coombs test) and on the absence of any other hereditary or acquired cause of hemolysis, although direct antiglobulin test-negative cases are not quite uncommon (5% of 308 cases of AIHA recently reported by the Gruppo Italiano Malattie EMatologiche dell'Adulto [GIMEMA]) [1, 2]. AIHA can present in primary and secondary forms. Secondary AIHA generally includes factors such as connective tissue diseases, drugs, infections, and lymphomas [3]. Cases of AIHA accompanied by lymphoma are rare and are typically presented in the literature as case reports. Roughly one-fifth of AIHA patients have lymphoma, while 7–10% of lymphoma patients have co-existing AIHA, indicating a clinicopathological link between both diseases [4–6]. In clinical settings, AIHA is commonly associated with indolent B-cell lymphomas, whereas the combination of AIHA with peripheral T-cell lymphoma (PTCL) is rarely observed [7–11]. This study retrospectively analyzes the clinical data, laboratory characteristics, treatment processes, and prognosis of five patients with the coexistence of PTCL and AIHA who were diagnosed within the last 10 years in our center.

## Materials and Methods

Diagnosis criteria are based on the 2008 World Health Organization (WHO) classification criteria for lymphoid tissue tumors. AIHA diagnosis and treatment efficacy assessment criteria are determined according to the International Autoimmune Hemolytic Anemia Consensus Group (IAIHAC) data. Evaluation of lymphoma treatment efficacy is performed according to the 2014 NHL Lugano standards. The Anti-Human Globulin Tube Agglutination Test (AHG TAT) method was used for the Coombs test. Overall survival time (OS) refers to the period from the diagnosis of lymphoma to the patient's death or the last follow-up date, with the last follow-up date being February 10, 2024. All participants provided informed consent, and the study followed good clinical practice standards and was conducted in accordance with the Helsinki Declaration. Institutional Board approval was obtained from Institutional Ethics Committee (Approval number: 09.2024.131).

## Results

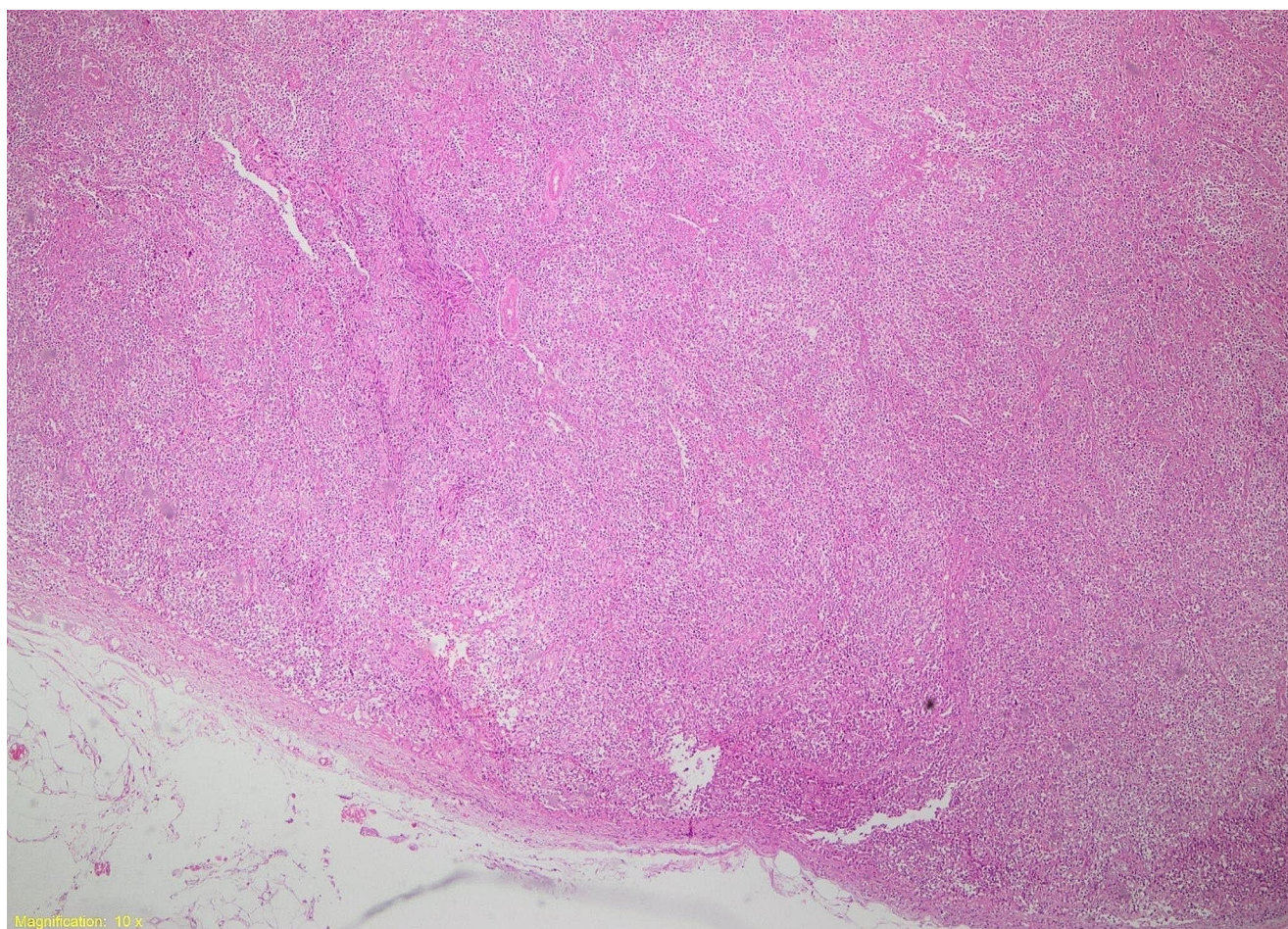
Imaging studies revealed lymph node enlargement in all five patients. Liver and spleen enlargement were observed in two patient, and spleen enlargement alone was identified in three patients. The pathological types of lymphoma were as follows: two cases of angioimmunoblastic T-cell lymphoma (Figs. 1, 2), and three cases of PTCL-not otherwise specified (PTCL-NOS). When all patients were diagnosed with AIHA, the direct Coombs test was positive. In our hospital, the rate of Coombs positivity during AITL in patients is 14.7%. The median hemoglobin was 6.1 (5.2–6.9) g/dL, the median reticulocyte ratio was 5.9% (2.3–7.5%), and the median haptoglobin was 0.16 (0.10–1.55) g/L. The total bilirubin median was 2.06 (0.65–3.6) mg/dL, the direct

✉ Ozlem Candan  
ozlemego@gmail.com

<sup>1</sup> Division of Hematology, Marmara Faculty of Medicine, Marmara University, Istanbul, Turkey

<sup>2</sup> Department of Internal Medicine, Marmara Faculty of Medicine, Marmara University, Istanbul, Turkey

<sup>3</sup> Marmara Universitesi Pendik Egitim ve Arastirma Hastanesi, Doku Tipleme Laboratuvari, Pendik, Istanbul 34899, Turkey



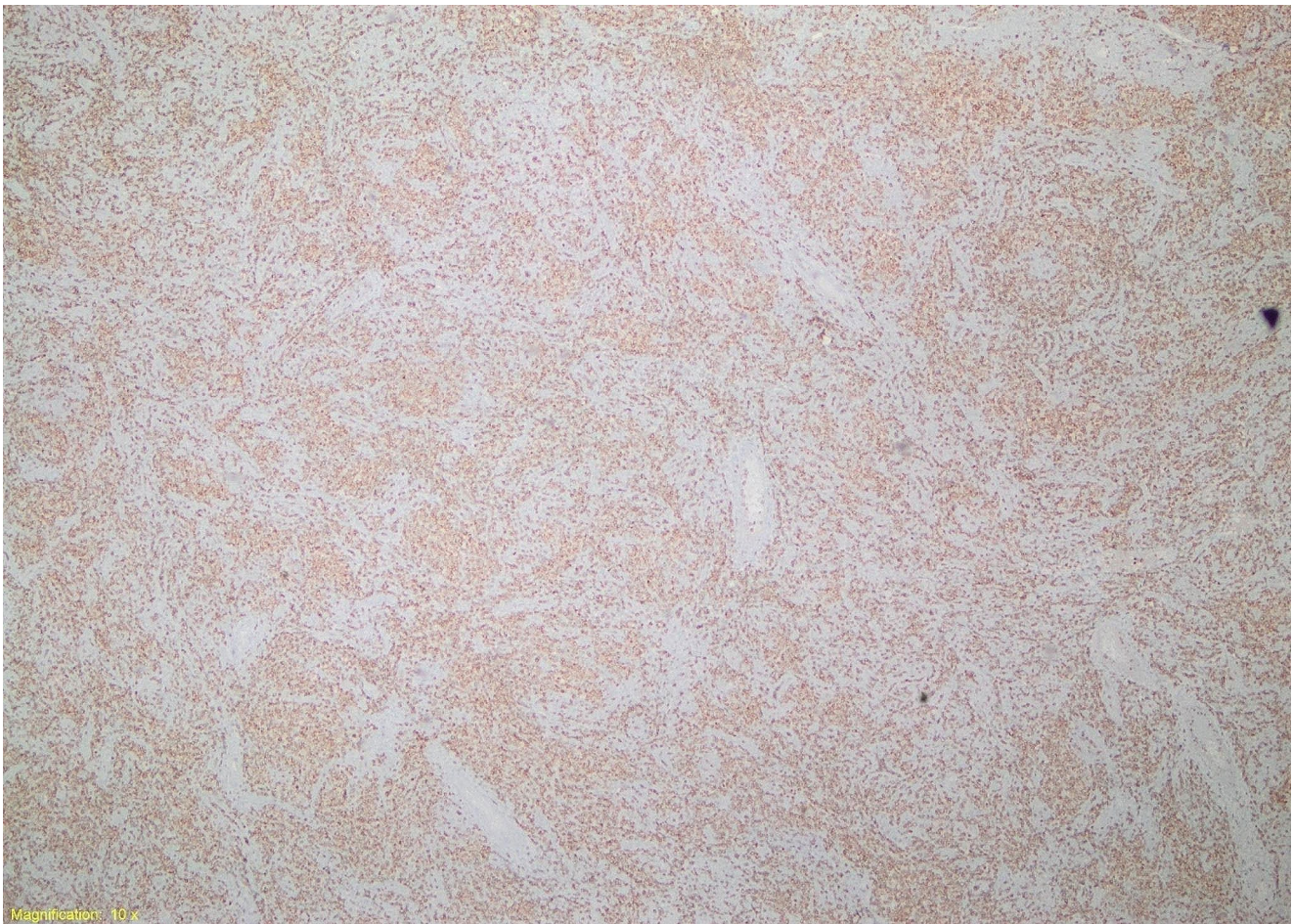
**Fig. 1** The appearance of angioimmunoblastic T-cell lymphoma under hematoxylin and eosin staining: lymph node biopsy view

bilirubin median was 0.55 (0.24–1.98) mg/dL, and the LDH median was 505 (335–895) U/L. Bone marrow involvement was not detected in any of the five patients at the time of diagnosis. Bone marrow involvement was later detected in one patient during follow-up. The characteristics of 5 patients are shown in Table 1. In all five patients, AIHA was initially treated with glucocorticoids as the first-line therapy. Glucocorticoids were incorporated into the chemotherapy regimen and initiated after the completion of chemotherapy. They were used at maximum efficacy and gradually tapered, with the duration of steroid treatment ranging from 3 to 14 months. In the second patient where the response to steroid treatment was inadequate, the disease progressed, and the patient experienced exitus before a new chemotherapy protocol could be initiated. PTCL, NOS diagnosed as the second patient and AITL diagnosed as the third patient experienced two hemolytic anemia attacks during the disease. In the second patient, control of hemolytic anemia could not be achieved with prednisolone (1 mg/kg) and IVIG (1gr/kg) treatment. Despite the presence of cold agglutinin positivity in the third patient, it was interesting that hemolytic

anemia was brought under control with 1 mg/kg of steroids. At the time of diagnosis, concurrent autoimmune hemolytic anemia was observed in four patients. However, in one patient diagnosed with PTCL-NOS (patient 2), an AIHA attack occurred three months before the diagnosis. It was interesting that AIHA occurred before the diagnosis. While all five patients had anemia, 3 patients had decreased platelet counts, and 2 patients had decreased white blood cell counts; therefore, in some patients, immunologic factors may lead to simultaneous immune thrombocytopenia and immune leukopenia. Total bilirubin levels were elevated in 3 patients and normal in the other 2 patients. In our group, one patient had a normal reticulocyte ratio.

## Discussion

The most common subtype of PTCL is PTCL-NOS, accounting for 35% of cases. Autoimmune hemolytic anemia is most frequently observed in the AITL subtype. The international literature reports a Coombs positive rate ranging from 13.0



**Fig. 2** In the patient diagnosed with angioimmunoblastic T-cell lymphoma, widespread staining with CD3 is demonstrated: lymph node biopsy view

to 75.0% throughout the course of AITL [12, 13]. Therefore, routine Coombs testing should be performed to check for the presence of AIHA in patients diagnosed with AITL. The coexistence of PTCL-NOS with AIHA has been reported in the literature as a case report and is considered quite rare. In our study, data from three patients diagnosed with PTCL-NOS are shared. In the literature, prednisolone is commonly used. However, in one case, a combination regimen of chidamide (30 mg, orally, twice a week) and cyclosporine was administered in a patient diagnosed with AITL-associated Evans syndrome, which could not be controlled with prednisolone and intravenous immunoglobulin (IVIg), resulting in complete remission [14]. CD20 antibody did not show a survival advantage in controlling AITL. However, inhibiting the proliferation of B cells may be effective in controlling AIHA, especially in patients with AITL accompanied by AIHA [15]. Additionally, cytarabine currently exhibits a unique effect in the treatment of AITL patients. The use of cytarabine might be considered for patients with AITL accompanied by AIHA [16]. In the literature, it has been

observed that there is limited information regarding treatment options for AIHA in patients with PTCL-NOS. There is a lack of data on cases using a second-line treatment for prednisolone-resistant AIHA. In the literature, cytopenia developed in two patients diagnosed with AITL before the diagnosis. In one of these patients, ITP occurred 2 months before the diagnosis, and in the other, AIHA developed 8 months before the diagnosis. A similar situation has not been reported in patients diagnosed with PTCL-NOS in the literature [17]. Considering the results of our study, when AIHA is associated with lymphoma, the laboratory tests for hemolytic anemia may not exhibit typical patterns. The limitation of this study is that it is a retrospective study conducted at a single center and includes a limited number of cases. In summary, typical laboratory findings of hemolytic anemia may not be detected during this association. When PTCL is treated, AIHA is often brought under control.

**Table 1** Summary of the characteristics of 5 patients with AIHA/PTCL

Item	Patient 1	Patient 2	Patient 3	Patient 4	Patient 5
Sex	Male	Female	Male	Female	Male
Age/year	43	62	73	68	59
Ann Arbor stage	IV	IV	III	III	IV
IPI	3	4	3	3	4
Biopsy site	Inguinal lymph node	Axillary lymph node	Inguinal lymph node	Axillary lymph node	Palatine tonsil
Pathological type	AITL	PTCL, NOS	AITL	PTCL, NOS	PTCL, NOS
WBC ( $\mu$ l)	3400	4500/2100	3100	4500	19,200
Hemoglobin (g/dL)	5.2	6.9 / 5	6.5 / 4.4	6.1	5.5
Hematocrit (%)	15.3	21.3 / 13.4	19 / 11.9	18.4	8.5
MCV (fL)	100.5	109 / 88	94 / 85	100	109
Platelet (per $\mu$ l)	84,000	60,000/210,000	108,000	160,000	94,000
Haptoglobin (g/L)	1.55	0.27 / <0.1	<0.1 / <0.1	0.16	<0.1
Ret/%	2.3	7.5 / 4.4	5.5 / 6.7	5.9	7.2
LDH (U/L)	505	335 / 239	424 / 458	895	827
Total bilirubin (mg/dL)	0.78	0.65 / 0.85	2.13 / 5.11	2.06	3.6
Direct bilirubin (mg/dL)	0.4	0.24 / 0.3	0.78 / 0.99	0.55	1.98
BMB	-	- / +	-	-	-
Coombs test	+	+ / +	+ / +	+	+
AIHA type	W, C3	W, C3 + IgG	C, C3 W, C3 + IgG	W, IgG	C, C3 W, C3 + IgG
Treatment of AIHA	Pred	Pred + IVIG	Pred	Pred	Pred
Response to AIHA	CR	NR / NR	PR/CR	CR	CR
Treatment of PTCL	CHOEP	CHOP	CHOP	CHOP, ICE, OKIT	CHOP
Response to PTCL	CR	NR	CR	CR	CR
OS, month	15	12	14	42	51
Status	Survived	Died	Survived	Died	Survived
Length of spleen (cm)	13 cm	17 cm	19 cm	15 cm	14 cm
EBER	-	-	+	-	+

IPI: International Prognostic Index; AITL: Angioimmunoblastic T-Cell Lymphoma; PTCL-NOS: Peripheral T-Cell Lymphoma-Not Otherwise Specified; WBC: White Blood Cell; MCV: Mean Corpuscular Volume; Ret/%: Reticulocyte Percentage; LDH: Lactate Dehydrogenase; BMB: Bone Marrow Biopsy; AIHA: Autoimmune Hemolytic Anemia; W: Warm; C: Cold; Pred: Prednisone; IVIG: Intravenous Immunoglobulin; CR: Complete Remission; PR: Partial Remission; NR: No Remission; OS: Overall survival; CHOEP: Cyclophosphamide + vincristine + doxorubicin + etoposide + prednisone; CHOP: Cyclophosphamide + vincristine + doxorubicin + prednisone; ICE: ifosfamide + carboplatin + etoposide; EBER: EBV-encoded early RNA

**Supplementary Information** The online version contains supplementary material available at <https://doi.org/10.1007/s12288-024-01822-x>.

## Declarations

**Conflict of Interest** The authors declare that they have no conflicts of interest or sources of funding related to the research process or its outcomes.

**Competing Interests** The authors have no relevant financial or non-financial interests to disclose.

**Ethics Approval** The study was cleared by the institutional ethics committee.

**Informed Consent** All participants provided informed consent, and the study followed good clinical practice standards and was conducted in accordance with the Helsinki Declaration. Institutional Board approval was obtained from Institutional Ethics Committee (Approval number: 09.2024.131).

## References

- Hill QA, Stamps R, Massey E, Grainger JD, Provan D, Hill A, Haematology BS (2017) The diagnosis and management of primary autoimmune haemolytic anaemia. *Br J Haematol* 176:395–411
- Barcellini W, Fattizzo B, Zaninoni A, Radice T, Nichele I, Di Bona E, Lunghi M, Tassinari C, Alfinito F, Ferrari A (2014) Clinical heterogeneity and predictors of outcome in primary autoimmune hemolytic anemia: a GIMEMA study of 308 patients. *Blood J Am Soc Hematol* 124:2930–2936
- Go RS, Winters JL, Kay NE (2017) How I treat autoimmune hemolytic anemia. *Blood J Am Soc Hematol* 129:2971–2979
- Sallah S, Sigounas G, Vos P, Wan J, Nguyen N (2000) Autoimmune hemolytic anemia in patients with Non-hodgkin's lymphoma: characteristics and significance. *Ann Oncol* 11:1571–1577
- Sallah S, Wan JY, Hanrahan LR (2001) Future development of lymphoproliferative disorders in patients with autoimmune hemolytic anemia. *Clin Cancer Res* 7:791–794
- Bauduer F (2001) Correspondence: Rituximab: a very efficient therapy in cold agglutinins and refractory autoimmune haemolytic anaemia associated with CD20-positive, low-grade non-Hodgkin's lymphoma. *Br J Haematol* 112:1085–1086

7. Jiang M, Bennani NN, Feldman AL (2017) Lymphoma classification update: B-cell non-hodgkin lymphomas. *Expert Rev Hematol* 10:405–415
8. Jiang M, Bennani NN, Feldman AL (2017) Lymphoma classification update: T-cell lymphomas, Hodgkin lymphomas, and histiocytic/dendritic cell neoplasms. *Expert Rev Hematol* 10:239–249
9. Cohen M, Vistarop AG, Huaman F, Narbaitz M, Metrebian F, De Matteo E, Preciado MV, Chabay PA (2018) Epstein-Barr virus lytic cycle involvement in diffuse large B cell lymphoma. *Hematol Oncol* 36:98–103
10. Jachiet V, Mekinian A, Carrat F, Grignano E, Retbi A, Boffa J-J, Ronco P, Rondeau E, Sellam J, Berenbaum F (2018) Autoimmune manifestations associated with lymphoma: characteristics and outcome in a multicenter retrospective cohort study. *Leuk Lymphoma* 59:1399–1405
11. Seve P, Philippe P, Dufour J-F, Broussolle C, Michel M (2008) Autoimmune hemolytic anemia: classification and therapeutic approaches. *Expert Rev Hematol* 1:189–204
12. Watatani Y, Sato Y, Miyoshi H, Sakamoto K, Nishida K, Gion Y, Nagata Y, Shiraishi Y, Chiba K, Tanaka H (2019) Molecular heterogeneity in peripheral T-cell lymphoma, not otherwise specified revealed by comprehensive genetic profiling. *Leukemia* 33:2867–2883
13. Maura F, Doderio A, Carniti C, Bolli N, Magni M, Monti V, Cabras A, Leongamornlert D, Abascal F, Diamond B (2021) CDKN2A deletion is a frequent event associated with poor outcome in patients with peripheral T-cell lymphoma not otherwise specified (PTCL-NOS). *Haematologica* 106:2918
14. Zhu F, Li Q, Pan H, Xiao Y, Liu T, Liu X, Li J, Wu G, Zhang L (2020) Successful treatment of Chidamide and Cyclosporine for Refractory/Relapsed Angioimmunoblastic T Cell Lymphoma with Evans Syndrome: a Case Report with Long-Term Follow-Up. *Front Oncol* 10:558677
15. Delfau-Larue M-H, de Leval L, Joly B, Plonquet A, Challine D, Parrens M, Delmer A, Salles G, Morschhauser F, Delarue R (2012) Targeting intratumoral B cells with rituximab in addition to CHOP in angioimmunoblastic T-cell lymphoma. A clinicobiological study of the GELA. *haematologica* 97:1594
16. Shi Y, Dong M, Hong X, Zhang W, Feng J, Zhu J, Yu L, Ke X, Huang H, Shen Z (2015) Results from a multicenter, open-label, pivotal phase II study of chidamide in relapsed or refractory peripheral T-cell lymphoma. *Ann Oncol* 26:1766–1771
17. Crickx E, Poullot E, Moulis G, Goulabchand R, Fieschi C, Galicier L, Meignin V, Coppo P, Delarue R, Casasnovas O (2019) Clinical spectrum, evolution, and management of autoimmune cytopenias associated with angioimmunoblastic T-cell lymphoma. *Eur J Haematol* 103:35–42

**Publisher's Note** Springer Nature remains neutral with regard to jurisdictional claims in published maps and institutional affiliations.