

## Safety of a thermal vessel sealer on main pulmonary vessels<sup>☆,☆☆</sup>

Tunc Lacin<sup>a</sup>, Hasan Fevzi Batirel<sup>a</sup>, Kursat Ozer<sup>b</sup>, Alper Demirutku<sup>b</sup>,  
Rengin Ahiskali<sup>c</sup>, Mustafa Yuksel<sup>a,\*</sup>

<sup>a</sup>Marmara University Hospital, Department of Thoracic Surgery, Istanbul, Turkey

<sup>b</sup>Istanbul University Faculty of Veterinary Medicine, Istanbul, Turkey

<sup>c</sup>Marmara University Faculty of Medicine Department of Pathology, Istanbul, Turkey

Received 4 September 2006; received in revised form 28 October 2006; accepted 7 November 2006; Available online 17 January 2007

### Abstract

**Objective:** LigaSure (Valleylab, Tyco Healthcare, Boulder, CO) is a novel instrument with widespread use in various surgical disciplines for vessel sealing. It uses heat energy to denature collagen and elastin and achieve vessel sealing. We investigated the safety of LigaSure in pulmonary arteries (PA) and veins (PV). **Methods:** Twelve sheep were anesthetized and endotracheally intubated. Six underwent right lower lobectomy (Group 1) and six right upper lobectomy (Group 2). All of the vessels in both groups were divided with LigaSure. Diameters of vessels were measured. Intraoperatively, pulmonary artery pressures (PAP) were monitored in Group 1. Following vascular division, ephedrine was injected to increase PAP in Group 1. In Group 2, animals were followed and euthanized at 7 days. Both immediate and 7 day samples were obtained from divided vessel stumps. Conventional histology was done. Statistical analysis was performed using *t*-test and Fisher's exact test. **Results:** Mean diameter of PAs ( $n = 9$ ) divided in Group 1 was 8.3 mm (3–11) and of PVs ( $n = 8$ ) was 10.4 mm (4–15). Mean PAP increased from 18 (27/9) to 27 (45/18) mmHg after ephedrine injection. Dehiscence rate was 2/6 in PAs and 3/6 in PVs larger than 9 mm in diameter. Mean diameter of PAs ( $n = 8$ ) divided in Group 2 was 5.7 mm (3–7) and of PVs ( $n = 9$ ) was 4.6 mm (4–6). No early or late (7 days) vascular disruption was seen in Group 2. Bleeding incidence was significantly different between groups (Fisher's exact test  $p = 0.015$ ). Overall no dehiscence was observed in vessels less than 7 mm in diameter. Histology of intraoperative samples showed thermal injury and necrosis. Seven day samples showed short segment necrosis limited to the vessel wall, fibrosis, thrombus formation without inflammation, and minimal granulation tissue. **Conclusions:** LigaSure achieves perfect sealing in pulmonary vessels less than 7 mm in diameter in sheep intra- and postoperatively even following a pressure challenge. It can safely be used in segmental branches of PAs and PVs during open or thoracoscopic surgery.

© 2007 European Association for Cardio-Thoracic Surgery. Published by Elsevier B.V. All rights reserved.

**Keywords:** Pulmonary artery; Pulmonary vein; LigaSure; Vascular division

### 1. Introduction

Sutures and staplers have stood the test of time for their safety in major vascular division. However, with the developments in minimally invasive thoracic surgery, suture ligation of pulmonary vessels through thoracoscopic ports have become difficult, leaving thoracic surgeons with the single choice of vascular staplers. On the other hand, clips have not gained popularity for use in division of relatively large pulmonary vasculature due to their unreliability.

Recent advances in cautery technology resulted in invention of thermal vessel sealers. LigaSure is a (Valleylab, Tyco Healthcare, Boulder, CO) bipolar thermal vessel sealer which uses heat energy to denature collagen and elastin and achieve vessel sealing. LigaSure has been used extensively in general surgery and other disciplines especially to divide short gastric vessels, splenic artery, liver tissue and colonic vessels [1–4]. Recently, reports on experimental and clinical use in thoracic surgery for pulmonary wedge resections, bullectomies in adults, and lobectomies in pediatric age groups were published [5–8]. Shigemura et al. [6,5], being the first to publish an initial case about the successful use of LigaSure to perform a thoracoscopic bullectomy in a 39-year-old man, has later updated this report with a series of 12 patients using the same technique for bullectomy and metastasectomy. Albanese et al. [7] published 14 neonates who underwent 13 lobectomies for cystic adenoid malformation and pulmonary sequestration using LigaSure for sealing of lobar pulmonary vessels and parenchymal resections. An experimental study on comparison of burst pressure

<sup>☆</sup> Presented at the joint 20th Annual Meeting of the European Association for Cardio-thoracic Surgery and the 14th Annual Meeting of the European Society of Thoracic Surgeons, Stockholm, Sweden, September 10–13, 2006.

<sup>☆☆</sup> This study was partially funded by Tyco Healthcare International Istanbul Branch. The authors have had full control of the design of the study, methods used, outcome values, analysis data, and production of the written report.

\* Corresponding author. Address: Marmara University Faculty of Medicine, Department of Thoracic Surgery, Tophanelioglu Cad. No: 13-15, Altunizade, Istanbul 34660, Turkey. Tel.: +90 216 325 91 33; fax: +90 216 325 24 26.

E-mail address: myuksel@marmara.edu.tr (M. Yuksel).

measurements after excision of lingula in a swine model with either Endo GIA roticulator stapler or LigaSure showed similar average burst pressures 1 week following division of the lung tissue [8].

The role of LigaSure in division of pulmonary vessels is unclear [9]. Histologic characteristics and size of pulmonary vessels are important concerns during the use of a thermal vessel sealer in these centrally placed high-flow vessels. In this study, we investigated the safety and reliability of LigaSure in dividing major pulmonary vessels.

## 2. Materials and methods

Our study was carried out in 30–40 kg sheep. All animals received humane care in compliance with the European Convention on Animal Care, and our study was approved by Marmara University Faculty of Medicine ethics committee.

Twelve sheep were grouped as Group 1 ( $n = 6$ ) and Group 2 ( $n = 6$ ). The grouping was decided according to the type of pulmonary resection and size of the pulmonary vessels. Animals in Group 1 underwent right lower lobectomy, while in Group 2 right upper lobectomy was performed. Sheep have a small right upper lobe with 1–2 pulmonary arterial and usually a single superior pulmonary vein. The right upper lobe bronchus branches off directly from the lateral wall of the trachea. Right lower lobe is large with major venous and arterial branches. The inferior pulmonary vein and lower lobe pulmonary artery are of the same size as of a human. Lower lobe also has additional arterial and venous branches that supply the medial basal segment which acts like a mediastinal lobe.

All animals had a peripheral intravenous access and cardiac monitorization. Following induction of anesthesia with intramuscular xylazine (10 mg/kg) and ketamine (50 mg/kg), animals were intubated. Anesthesia was continued with inhalation agents.

Surgical approach was a right thoracotomy, usually through 4th intercostal space for a right upper lobectomy and 6th intercostal space for a right lower lobectomy. The pulmonary vessels were dissected and prepared for division with LigaSure.

Ligasure Atlas® 10 mm was used for vascular division (Fig. 1). First, the vessel of concern is prepared and dissected from the surrounding mediastinal and hilar structures. Using a sterile scale, each vessel diameter was measured. During measurements, we did not distort the normal appearance of the vessels avoiding any retraction or compression. Following insertion and closure of the jaws of the LigaSure around the vessel, heat energy was conducted. Care was taken not to distort or retract the vessels while the energy was applied. The appropriate amount of energy applied for the sealing to take place was automatically coordinated by sensors on the jaws of handset and a signal was heard when the seal cycle was complete. Output to the handset was automatically discontinued. This feedback-controlled response system works by diagnosing the tissue type in the instrument jaws and delivers the appropriate amount of energy to effectively seal the vessel. Upon completion of the sealing process, the vessel was either divided with the blade of the probe or cut with surgical scissors. Extreme care was taken during the

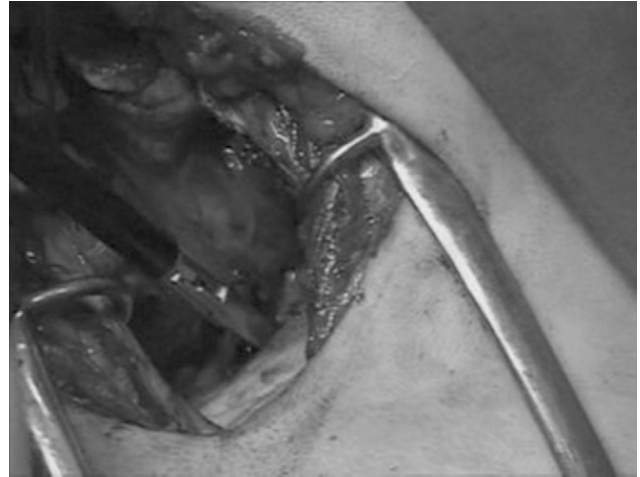


Fig. 1. Intraoperative appearance of vascular division of upper lobe pulmonary artery through a thoracotomy using LigaSure 10 mm probe.

release of the sealed vessel as the jaws could stick to the vessel wall. Any bleeding from the LigaSure divided vessel was accepted as a failure of vascular sealing.

Following vascular division, a purse string suture was placed to the pulmonary artery. At that moment, baseline heart rate and pulmonary artery pressures were measured via direct catheterization through the pulmonary artery. Ephedrine 10 mg was injected directly to the pulmonary artery and the pressure changes in pulmonary artery were monitored. If the heart rate and pulmonary artery pressure did not increase 50% over the baseline, additional dose of ephedrine was injected to the pulmonary artery. In the mean time, the vessel stumps were inspected for bleeding.

Surgical procedure was ended with hemostasis and chest drain placement in Group 2, while the animals in Group 1 were euthanized using intravenous pentothal (100 mg/kg). The animals in Group 2 were followed for a week and euthanized with intravenous pentothal. In the initial design of the study, our aim was to follow the animals in Group 1 (lower lobectomy) for a week as well. However, two sheep in the lower lobectomy group did not tolerate resection of voluminous right lower lobe and went into respiratory arrest shortly after extubation in the postoperative period. That is why we decided to euthanize the animals in Group 1 postoperatively.

The samples were obtained from LigaSure divided vessel stumps in Groups 1 (early samples, postoperative) and 2 (late samples, 1 week) according to their euthanasia timing. The samples were fixed in 10% formalin. Standard hematoxylin–eosin staining was performed to assess necrosis, degree of thermal injury, and spread in early samples. Late samples were assessed for inflammation, thrombus formation, and granulation tissue.

Statistical analysis between two groups was performed using *t*-test and Fisher's exact test.

## 3. Results

The mean diameter of pulmonary arteries ( $n = 9$ ) divided in Group 1 was 8.3 mm (3–11). Pulmonary veins ( $n = 8$ ) were larger with an average diameter of 10.4 mm (4–15).

Hemorrhage occurred in 2/6 of pulmonary arteries and in 3/6 of pulmonary veins larger than 9 mm in diameter. Overall, five of six animals in Group 1 experienced bleeding. Hemorrhages were due to a rupture of either the sealed area or the junction between the sealed and healthy vascular tissue, possibly due to the thermal necrosis of the vessel wall. Bleeding was controlled with vascular clamps and sutures in these animals. Bleeding occurred before ephedrine injection in all of these large vessels, possibly points to the technical inadequacy of LigaSure in pulmonary vasculature larger than 9 mm.

In Group 2, mean diameter of pulmonary arteries ( $n = 8$ ) was 5.7 mm (3–7) and of pulmonary veins ( $n = 9$ ) was 4.6 mm (4–6) (Fig. 2). There was no bleeding from divided pulmonary vessels in Group 2 in the early or late follow-up period.

Mean diameter of pulmonary arteries between the two groups showed statistical significance by Student's unpaired  $t$ -test ( $p = 0.024$ ). Mean diameter of pulmonary veins between the two groups also showed statistical significance by Student's unpaired  $t$ -test ( $p = 0.002$ ). Bleeding incidence was significantly different between groups (Fisher's exact test  $p = 0.015$ ).

Following ephedrine injection, mean pulmonary artery pressures increased from 18 (27/9) to 27 (45/18) mmHg. The increase in mean pulmonary artery pressure was very significant ( $p = 0.004$ , Student's paired  $t$ -test). Heart rate increased from an average of 114 (90–148)–191 (160–230) per minute which was also statistically significant ( $p = 0.001$ , Student's paired  $t$ -test).

In both groups, despite a pressure challenge, no dehiscence was observed in vessels less than 9 mm in diameter.

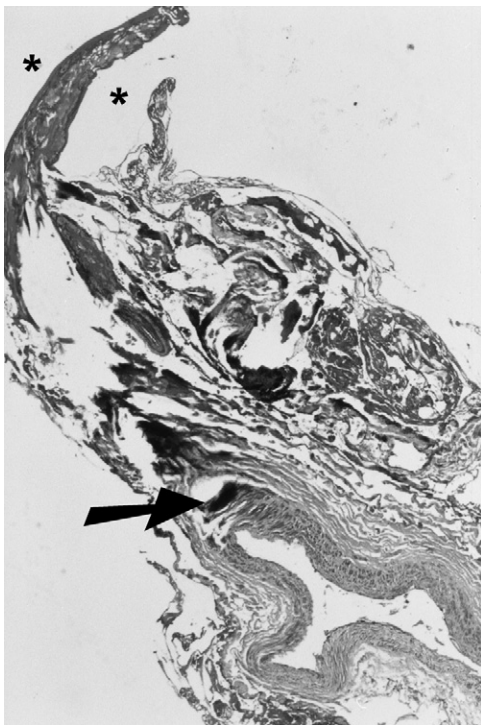


Fig. 2. Microscopic view of a LigaSure divided pulmonary vein at 1 week (40 $\times$ ). The sealed area is between stars. Arrow points to the normal vessel wall.

### 3.1. Histology

Histological analysis of early samples showed thermal injury and necrosis. Seven day samples showed short segment necrosis limited to the vessel wall, thrombus formation without inflammation, and minimal granulation tissue. No thermal effect to the neighboring structures were observed. There was transition to normal vascular tissue within 5 mm from the LigaSure divided stumps (Fig. 2).

### 4. Discussion

The use of a thermal vessel sealer on pulmonary vasculature is in theory against the basic surgical principles of thoracic surgery. The fragile and histologically weak pulmonary artery is different than systemic arteries in character, and lack of an adventitia makes it prone to injury. However, LigaSure has been successfully used in dividing major renal, splenic, and colonic arteries, which have much higher pressures than the pulmonary system [2,4,10,11]. The company guarantees a safe vascular division in vessels less than 7 mm in diameter. Additionally, several studies show that thermal injury is limited to the seal area and is directly correlated with vessel size [12,13]. A study performed in pigs showed a thermal spread of 2.5 mm in vessels 6–7 mm in diameter [12]. In our study, especially in large vessels (>9 mm) we have observed ruptures from the seal-healthy tissue junction which shows that a thermal necrosis occurs in those areas. On the contrary, histologic samples of pulmonary vessels less than 7 mm did not show any thermal necrosis within the neighboring vascular tissue or only a short segment necrosis was observed only limited to the vessel wall (Fig. 2). This high rate of rupture in larger vessels could be due to the low degree of strength provided by the denatured collagen and elastin. Increase in the number or size of sensors on the jaws can achieve greater seal strength.

LigaSure has 5- and 10-mm probes that have a 120° of jaw movement. Both jaws of the instrument are flexible with smooth edges which makes it easier to pass around small vessels. The technology is still in its early ages, thus there are certain disadvantages. The thermal energy frequently causes sticking of the sealed area to the jaws of the instrument. The sealed area can be released from the instrument unharmed with irrigation and careful manipulation. The lack of a scale on the jaws of the probe causes a vessel size determination dilemma. The sensors on the probe need to be clean and dry during each application to correctly sense the vessel size and sealing capability. Some of the studies have reported a failure and bleeding rate of 2–3% in colonic arteries and intrahepatic vessels less than 7 mm in diameter, which is unacceptable for thoracic surgery [4,14]. The thermal vessel sealers are also being used in tissues other than vessels. It has been used for ureteral division, bile duct ligation, and intestinal closure [15–17]. It was successful in the former two. The instrument is not recommended for closure of air-filled organs.

In a recent study by Santini [9], LigaSure was used to seal pulmonary tissue, bronchi, and vessels in pigs and subsequently it was used for pulmonary wedge resections. LigaSure was found successful in division of small bronchi (<2 mm),

pulmonary vessels, and wedge resections in the experimental phase.

Our study design enabled us to evaluate the efficacy and reliability of LigaSure in major pulmonary vessels and mimicked postoperative clinical scenarios of supraventricular arrhythmia and hypertensive attack. Other studies usually evaluate burst pressures as important criteria for successful closure of vessels, while a pulsatile pressure increase and heart rate acceleration similar to clinical situations is more physiologic.

The cost of LigaSure Atlas 10-mm is almost the same as an Endo GIA thoracoscopic linear stapler, and it can be used on several vessels at the same surgical session.

Our study and reports in the literature shows that LigaSure is very successful in pulmonary vascular division, if the size of the vessel is less than 7 mm. The size limit is a disadvantage, as some of the lobar vessels are large. With its round and flexible tip, it can be useful in dividing small segmental branches during thoracoscopic lung resections, typically in dividing left upper lobe branches in the fissure which are sometimes difficult to divide using the cumbersome and rigid 30-mm Endo GIA stapler.

Large experimental series with technical improvements are needed to assess the safety of LigaSure in clinical use. Certain improvements such as, scale placement on the tip and avoidance of sticking are critical for pulmonary vessel division.

In conclusion, LigaSure expands our surgical armament for pulmonary vessel division. The results are successful in pulmonary vessels less than 7 mm in size. After certain improvements, it can safely be used in segmental branches of pulmonary arteries and veins during open or thoracoscopic surgery.

## References

- [1] Lee WJ, Chen TC, Lai IR, Wang W, Huang MT. Randomized clinical trial of Ligasure versus conventional surgery for extended gastric cancer resection. *Br J Surg* 2003;90(12):1493–6.
- [2] Gelmini R, Romano F, Quaranta N, Caprotti R, Tazzioli G, Colombo G, Saviano M, Uggeri F. Sutureless and stapleless laparoscopic splenectomy using radiofrequency: LigaSure device. *Surg Endosc* 2006;20(6):991–4.
- [3] Romano F, Franciosi C, Caprotti R, Uggeri F, Uggeri F. Hepatic surgery using the Ligasure vessel sealing system. *World J Surg* 2005;29(1):110–2.
- [4] Marcello PW, Roberts PL, Rusin LC, Holubkov R, Schoetz DJ. Vascular pedicle ligation techniques during laparoscopic colectomy. A prospective randomized trial. *Surg Endosc* 2006;20(2):263–9.
- [5] Shigemura N, Akashi A, Nakagiri T, Ohta M, Matsuda H. A new tissue-sealing technique using the Ligasure system for nonanatomical pulmonary resection: preliminary results of sutureless and stapleless thoracoscopic surgery. *Ann Thorac Surg* 2004;77(4):1415–9.
- [6] Shigemura N, Akashi A, Nakagiri T. New operative method for a giant bulla: sutureless and stapleless thoracoscopic surgery using the Ligasure system. *Eur J Cardiothorac Surg* 2002;22(4):646–8.
- [7] Albanese CT, Sydorak RM, Tsao K, Lee H. Thoracoscopic lobectomy for prenatally diagnosed lung lesions. *J Pediatr Surg* 2003;38(4):553–5.
- [8] Tirabassi MV, Banever GT, Tashjian DB, Moriarty KP. Quantitation of lung sealing in the survival swine model. *J Pediatr Surg* 2004;39(3):387–90.
- [9] Santini M, Vicidomini G, Baldi A, Gallo G, Laperuta P, Busiello L, Di Marino MP, Pastore V. Use of an electrothermal bipolar tissue sealing system in lung surgery. *Eur J Cardiothorac Surg* 2006;29(2):226–30.

- [10] Constant DL, Florman SS, Mendez F, Thomas R, Slakey DP. Use of the LigaSure vessel sealing device in laparoscopic living-donor nephrectomy. *Transplantation* 2004;78(11):1661–4.
- [11] Yoney E, Hobek A, Keskin M, Yilmaz O, Kamali S, Oktay C, Bender O. Laparoscopic splenectomy and LigaSure. *Surg Laparosc Endosc Percutan Tech* 2005;15(4):212–5.
- [12] Carbonell AM, Joels CS, Kercher KW, Matthews BD, Sing RF, Heniford BT. A comparison of laparoscopic bipolar vessel sealing devices in the hemostasis of small-, medium-, and large-sized arteries. *J Laparoendosc Adv Surg Tech A* 2003;13(6):377–80.
- [13] Matthews BD, Pratt BL, Backus CL, Kercher KW, Mostafa G, Lentzner A, Lipford EH, Sing RF, Heniford BT. Effectiveness of the ultrasonic coagulating shears, LigaSure vessel sealer, and surgical clip application in biliary surgery: a comparative analysis. *Am Surg* 2001;67(9):901–6.
- [14] Saiura A, Yamamoto J, Koga R, Sakamoto Y, Kokudo N, Seki M, Yamaguchi T, Yamaguchi T, Muto T, Makuuchi M. Usefulness of LigaSure for liver resection: analysis by randomized clinical trial. *Am J Surg* 2006;192(1):41–5.
- [15] Goldstein SL, Harold KL, Lentzner A, Matthews BD, Kercher KW, Sing RF, Pratt B, Lipford EH, Heniford BT. Comparison of thermal spread after ureteral ligation with the Laparo-Sonic ultrasonic shears and the Ligasure system. *J Laparoendosc Adv Surg Tech A* 2002;12(1):61–3.
- [16] Schulze S, Kristiansen VB, Fischer Hansen B, Rosenberg J. Sealing of cystic duct with bipolar electrocoagulation. *Surg Endosc* 2002;16(2):342–4.
- [17] Salameh JR, Schwartz JH, Hildebrandt DA. Can LigaSure seal and divide the small bowel? *Am J Surg* 2006;191(6):791–3.

## Appendix A. Conference discussion

**Dr T. Grodzki (Szczecin, Poland):** I would like to congratulate you on an interesting study, but I have more doubts than even before this presentation, because your failure rate, if I am right, was 50%, so it was 3 per 6 vessels.

First I would like to ask you, what is the message of this presentation? Should we continue this study or should we perform a large multicenter study of, let's say, 1000 cases without a single failure, then we can recommend it for common use, otherwise simple ligation will still remain the better option.

**Dr Batirel:** Well, I think that this technology is still in its baby steps and staplers and sutures have stood the test of time. Producing company recommendations and all of the studies show that it is not suitable for vessels over 7 mm in diameter. So you can't divide a major pulmonary artery with LigaSure, not now, but I think it might be useful in tiny upper lobe branches, especially in the fissure where you can't really apply the stapler. During thoracoscopic lobectomy, you have to pass the really large, rigid stapler legs around tiny vessels. So I think a large center study can be started, but, as I said, there are certainly a few technical improvements that have to be done before human use.

**Dr D. Wood (Seattle, Washington, USA):** I'd like to state Dr Grodzki's question another way. The issue is that there is not a black line between <7 mm and >7 mm. Obviously what that represents is a spectrum of failure, and our tolerance of failure in this setting, particularly since we're talking about applying it in a minimally invasive setting, is almost zero. So I think that one would want to see 100% success even in vessels that are larger than 7 mm to feel confident in using it routinely in vessels less than 7 mm.

The other question that I had for you relates to the time of follow-up that you had. You followed them, at most, 7 days, and I also have a concern about late consequences of the adjacent thermal injury to the pulmonary artery, and whether there might be either late disruptions beyond 7 days, which would be obviously catastrophic, or aneurysm formation in the area where you've got a thermal injury to a central pulmonary artery.

**Dr Batirel:** There is transition to normal tissue is within 5 mm of the divided vessel stumps in all of the histologic studies performed in systemic arteries as well as pulmonary vessels. In large vessels more than 7 mm in diameter, we had a similar observation; the thermal injury weakens the proximal. But, as I have stated, it's not recommended for 11 mm vessels. However, within the next decade or years, with the increase in the sensors of the tip, we might be able to divide even larger vessels with absolute safety.

**Dr Wood:** I guess you're implying that 5 mm is a very short distance and I consider it a large distance.