

Ultrastructure of the Natal and Primary Teeth

Esin Çalışkan Ak¹, Serap Arbak², Serap Akyüz³, Burcu Nur Doğan³, Rabia Pişiriciler¹

¹Marmara University, Faculty of Dentistry, Department of Basic Medical Sciences, İstanbul, Turkey
²Acıbadem University School of Medicine, Department of Histology and Embryology, İstanbul, Turkey
³Marmara University, Faculty of Dentistry, Department of Pediatric Dentistry, İstanbul, Turkey

Esin Çalışkan Ak, Phd.
 Serap Arbak, Phd. Prof. Dr.
 Serap Akyüz, Phd. Prof. Dr.
 Burcu Nur Doğan, Phd.
 Rabia Pişiriciler, Phd. Asso. Prof. Dr.

Correspondence:

Phd. Esin Çalışkan Ak
 Marmara University, Faculty of Dentistry,
 Department of Basic Medical Sciences, İstanbul,
 Turkey
 Phone: +90 216 421 16 21 / 1562
 E-mail: esinbir@yahoo.com

Received : December 07, 2015
 Revised : March 18, 2016
 Accepted : March 18, 2016

ABSTRACT

Aim: The teeth present in the oral cavity at birth are known as natal teeth and their etiology is still unknown. In this study, we aimed to compare the morphologic structures of natal and primary teeth at the ultra structural level using transmission electron microscope (TEM).

Material and Methods: We investigated a natal tooth of a fourteen-day-old newborn baby. It was extracted due to the hypermobility with a risk of aspiration. As a control, a healthy primary incisor tooth was extracted from another child due to the physiologic root resorption. Immediately after extraction, both teeth were fixed in 10% formalin solution and decalcified by immersion in ethylenediaminetetraacetic acid (EDTA) solution. Following routine TEM preparation process, teeth were embedded in Epon 812.

Results: Histologically, structures of enamel prism and dentin tubules were different in the natal tooth compared to the primary tooth. Light microscopic (LM) and TEM investigations of the primary tooth showed prominent crystal structures in the enamel prism and regular organization in both enamel and dentin. LM and TEM investigations of the natal tooth revealed an irregular enamel prism in the hypoplastic enamel, vacuolization in the interprismatic enamel and an irregular organization in the dentin tubules.

Conclusion: We conclude that the structural differences of the enamel and dentin in the natal tooth might be a result of incomplete maturation.

Key words: natal tooth, primary tooth, dentin, enamel, transmission electron microscope

NATAL VE SÜT DİŞLERİN İNCE YAPISI

ÖZET

Amaç: Doğumla birlikte ağız içinde görülen dişler natal dişler olarak tanımlanır ve etyolojisi halen bilinmemektedir. Bu çalışmada natal ve süt dişlerin morfolojik yapıları ultrayapısal seviyede geçirimli elektron mikroskobu (TEM) kullanarak karşılaştırmak amaçlandı.

Gereç ve Yöntem: Bu çalışmada 14 günlük yenidoğan bir bebekten aşırı sallanmaya bağlı aspirasyon riski nedeniyle çekilen bir adet natal diş incelendi. Kontrol grubu olarak, fizyolojik kök rezorpsiyonu nedeniyle kliniğimize müracaat eden sağlıklı başka bir çocuktan çekilen süt dişi incelenmiştir. Dişler çekimden hemen sonra %10'luk formol ile fikse edildikten sonra Etilendiaminetetraasetik asit (EDTA) ile dekalsifiye edildi. Dekalsifiye işleminden sonra rutin TEM takip işlemine alınan dişler Epon 812 içerisine gömüldü.

Bulgular: Histolojik olarak natal dişe ait mine prizma ve dentin tubül yapısı süt dişi ile kıyaslandığında düzensiz oldukları tespit edildi. Süt dişi mine prizmalarında belirgin kristal yapılar ve hem mine hem de dentinde ise düzenli yapılanma ışık mikroskobu (IM) ve TEM düzeyinde saptandı. Natal dişin IM ve TEM düzeyindeki incelemeler sonucunda hipoplastik minede düzensiz mine prizmaları, interprizmatik minede vaküolizasyon ve dentin tübüllerinde düzensiz bir dizilim gözlemlendi.

Sonuç: Natal dişte belirlenen mine ve dentin yapısındaki farklılıkların, dişin henüz gelişim aşamalarını tamamlamamış olmasından kaynaklanabileceği kanısına varıldı.

Anahtar sözcükler: natal diş, süt dişi, dentin, mine, geçirimli elektron mikroskop

The normal eruption of primary teeth begins with mandibular incisors at about the age of 6 months (1). Systemic or local disturbances during the development of the teeth can affect the morphology, the structure of dental hard tissues, the number of teeth and also the time of eruption (2). Taking only the time of eruption as a reference, Massler and Savara have defined "natal teeth" as teeth present at birth and "Neonatal teeth" as those that erupt within the first month of life (3). Although this definition has been widely accepted, the terms such as fetal teeth, predeciduous teeth, congenital teeth or dentitia praecox have also been used to describe these teeth (4). The prevalence of natal teeth ranges from 1:2,000 to 1:3,500 births (5). The reports about a significant difference in prevalence between males and females are still controversial. However, a predilection for females was cited by some authors (4,6,7). Natal teeth usually occur in pairs and the most affected teeth are often the lower primary central incisors (85%) (8-10).

The etiology of the natal teeth is still unknown but it is related to several factors such as superficial position of the tooth germ, infection, febrile states, nutritional deficiencies, hormonal stimulation, environmental factors, osteoblastic activity within the area of the tooth germ and heredity (4,8-11). Also some investigators suggest that natal teeth may be associated with some genetic syndromes such as Ellis-van Creveld (Chondroectodermal dysplasia), Cleft Palate and Lip, Hallermann-Streiff, and Down's Syndrome (12-15).

According to the degree of maturity, natal and neonatal teeth are also classified into mature and immature. Mature natal or neonatal teeth are well developed and have relatively good prognosis, whereas the term immature exhibits defective development and poor prognosis (10,16). Clinically, natal teeth may resemble normal primary teeth in size and shape; but in many instances, they are small, conical shape and brown-yellowish / whitish opaque color. They may reveal an immature appearance with hypoplastic enamel and poor or absent root formation (4,9). For the decision of maintaining these teeth in the oral cavity, some factors should be considered such as the degree of mobility, discomfort during suckling, sublingual ulceration, ulceration of the mother's breasts and whether the tooth is a part of normal dentition or is supernumerary (16-19).

In this study, we aimed to compare the morphologic structures of natal and primary teeth at the ultrastructural level using transmission electron microscope (TEM).

Material and methods

A fourteen-day-old newborn baby with a natal tooth admitted to Marmara University, Faculty of Dentistry, Department of Pediatric Dentistry. After consultation with pediatrician, the natal tooth (the lower central incisor) was extracted using local anesthesia because of hypermobility with a risk of aspiration (Figure 1). As a control, a healthy primary tooth (the lower central incisor) from another child was extracted due to the physiologic root resorption. This study protocol was approved by the Local Research Ethics Committee and an informed consent to participate in this study was obtained from the parents of the children.

Light and transmission electron microscopic preparation

Immediately after extraction, the teeth were fixed in 10% formalin and decalcified by immersion in EDTA solution. After decalcification, in preparation for the TEM investigation, the teeth samples were fixed in 2.5% glutaraldehyde and in 0.1 M phosphate buffer saline (PBS, pH, 7.3) for 4 hours at 4°C. They were washed with PBS and post fixed in 1% osmium tetroxide in PBS (0.1 M, pH, 7.3). Samples were dehydrated through ascending grades of ethanol, embedded in Epon 812 (Fluka, Sigma Aldrich, Chemica, Steinheim, Switzerland) and polymerized at 60°C. Ultra-thin and Semi-thin EPON sections were cut using a Leica Ultracut R ultramicrotome (Leica Microsystems, Vienna, Austria). The semi-thin EPON sections (1µm) were stained with toluidine blue. Those were then examined and photographed using an Olympus BX51 photomicroscope (Tokyo, Japan). The ultra-thin EPON sections (60nm) were collected on 200-mesh naked copper grids and contrasted with uranyl acetate and lead citrate. Those sections were then observed using a JEOL 1200 EX II TEM (Tokyo, Japan) at 80 kV accelerating voltage and photographed with a side mounted digital camera (Olympus Morada Soft Imaging System).

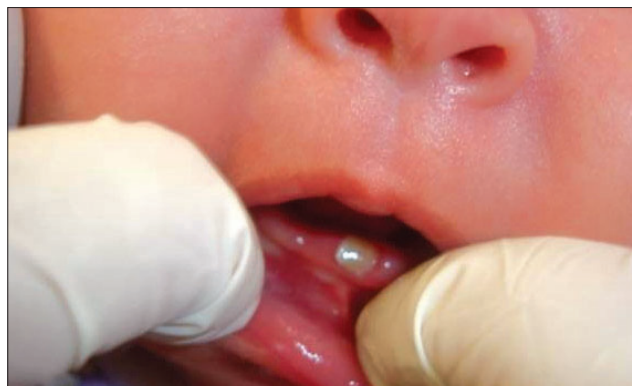


Figure 1. A baby with a natal tooth.

Results

Macroscopic findings

Macroscopically, the natal tooth showed small and conical shape with a poor root formation. The primary tooth was normal in size and had a well developed root formation.

Light and transmission electron microscopic findings

The light microscopic investigation showed regular organization in enamel and dentin of the primary tooth (Figure 2A). The primary tooth was prominent with crystal structures in the enamel prism and showed a regular organization in both enamel and dentin at the TEM investigation (Figure 2B and Figure 2C). The enamel prisms and the structure of dentin tubules were different in the natal tooth compared to the primary tooth. Hypoplastic enamel and irregular organization in dentin tubules were seen in natal tooth at LM investigation (Figure 3A). The TEM assessment showed irregular enamel prisms in the hypoplastic enamel and vacuolization in the interprismatic enamel in the natal tooth. (Figure 3B and Figure 3C). The

dentin of the natal tooth also revealed irregular organization in dentin tubules. (Figure 3B).

Discussion

Macroscopic findings of the natal tooth indicated small, conical shape and a poor root formation as reported in the literature (1,2,8,10). Bigeard et al (20) reported that the maximal enamel thickness was measured as 130 μm in natal tooth while the enamel thickness of the normal primary teeth reaches 1000-1200 μm . According to these findings, they assumed that size reduction of the natal tooth could be due to its smaller enamel thickness. Jasmin and Clergau-Guerithault (21) thought that reduction in enamel thickness associated with hypomineralization could be accepted as normal in a tooth whose crown formation is normally completed three months postnatally.

Previous histological studies have documented that the enamel of natal teeth is usually hypoplastic, hypomineralized and occasionally absent in some regions (4,9,10,19,20).

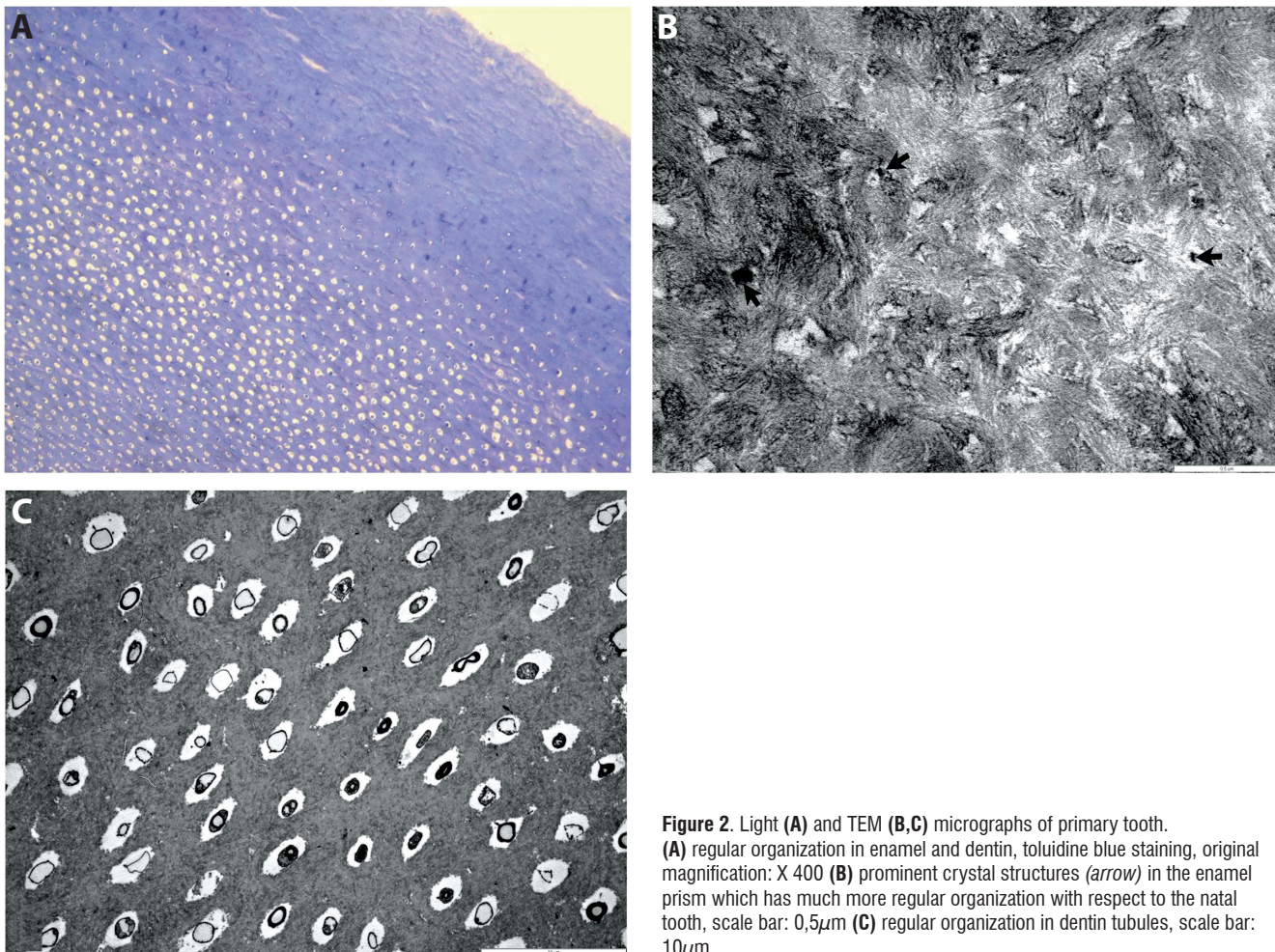


Figure 2. Light (A) and TEM (B,C) micrographs of primary tooth. (A) regular organization in enamel and dentin, toluidine blue staining, original magnification: X 400 (B) prominent crystal structures (arrow) in the enamel prism which has much more regular organization with respect to the natal tooth, scale bar: 0,5 μm (C) regular organization in dentin tubules, scale bar: 10 μm .

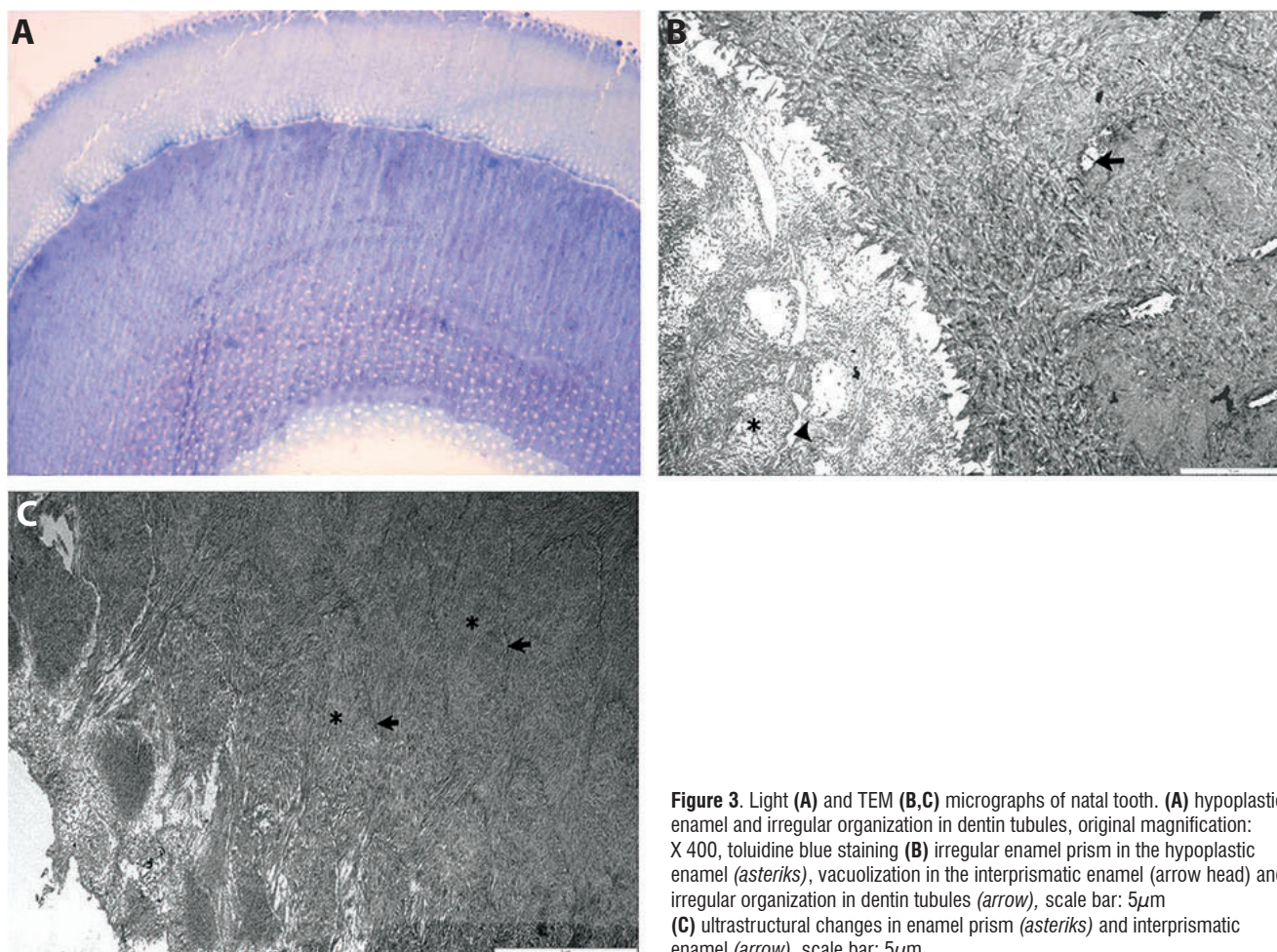


Figure 3. Light (A) and TEM (B,C) micrographs of natal tooth. (A) hypoplastic enamel and irregular organization in dentin tubules, original magnification: X 400, toluidine blue staining (B) irregular enamel prism in the hypoplastic enamel (asterisks), vacuolization in the interprismatic enamel (arrow head) and irregular organization in dentin tubules (arrow), scale bar: 5 μ m (C) ultrastructural changes in enamel prism (asterisks) and interprismatic enamel (arrow), scale bar: 5 μ m.

Uzamiş et al reported that enamel of the natal tooth revealed hypoplastic, depressed areas and the incisal edge of the natal tooth lacked enamel (1). Biegard et al showed that structural disturbance seemed to be limited to the enamel, with the absence of primless zone, Retzius lines and the Hunter-Schreger bands. In this study, they thought that these alterations in the enamel were probably related to early disturbance in amelogenesis (20). The primary teeth start to mineralize in utero and continue to develop and mature during the first year of life (22). Except in the cervical part of the crown, initial mineralization phase of the primary mandibular central incisors is completed before birth while its maturation phase is completed two and half months postnatally (23). Based on our current study, while prominent crystal structures and regular organization in the enamel prism were formed in the primary tooth, irregular enamel prism in the hypoplastic enamel and vacuolization in the interprismatic enamel were detected in the natal tooth. The observed ultrastructural differences in the structure of the enamel prisms might be related to the inadequately calcified enamel.

Several authors have described structural disturbances in the dentin layer of the natal teeth, mostly in the cervical and apical regions (24,25), while others have not observed any alterations (18-20,26). In some studies, natal teeth presented dentinal disturbances including reduced number of dentinal tubules, large diameter dentinal tubules, large interglobular spaces and atubular dentine of osteodentinal character (24,25). Anneroth et al (24) claimed that the number of the dentinal tubules decrease steadily from the coronal to the cervical region. Detection of the atubular osteodentin in the occlusal central fossa suggests that odontoblasts in this region were exposed to oral environment before developing a covering enamel and normal tubular dentin and consequently responding by depositing of the atubular substance (27). In accordance with the literature, we observed irregular organization of the dentin tubules in the natal tooth compared to the primary tooth.

In conclusion, the structural differences of the enamel and dentin in the natal tooth might be the result of incomplete maturation.

References

1. Uzamis M, Olmez S, Ozturk H, Celik H. Clinical and ultrastructural study of natal and neonatal teeth. *J Clin Pediatr Dent*, 1999; 23: 173-7.
2. Seminario AL, Ivancaková R. Natal and neonatal teeth. *Acta Medica (Hradec Kralove)* 2004; 47: 229-33.
3. Massler M, Savara BS. Natal and neonatal teeth: a review of twenty-four cases reported in the literature. *J Pediatr*, 1950; 36: 349-59.
4. Maheswari NU, Kumar BP, Karunakaran, Kumaran ST. "Early baby teeth": Folklore and facts. *J Pharm Bioallied Sci*, 2012; 4: 329-33.
5. Chow MH. Natal and neonatal teeth. *J Am Dent Assoc*, 1980; 100: 215-6.
6. Anegundi RT, Sudha R, Kaveri H, and Sadanand K. Natal and neonatal teeth: a report of four cases, *J Indian Soc Pedod Prev Dent*, 2002; 20: 86-92.
7. Kates GA, Needleman HL, Holmes LB. Natal and neonatal teeth: a clinical study. *JADA*, 1984; 109: 441-3.
8. Leung AK, Rabson WL. Natal teeth. A review. *J Natl Med Assoc*, 2006; 98: 226-8.
9. Mhaske S, Yuwanati MB, Mhaske A, Ragavendra R, Kamath K and Saawarn. Natal and Neonatal Teeth: and overview of the literature. *ISRN Pediatrics* 2013; doi: 10.1155-2013-956269.
10. Rao RS, Mathad SV. Natal teeth: Case report and review of literature. *J Oral Maxillofac Pathol*, 2009; 13: 41-6.
11. Khandelwal V, Nayak UA, Nayak PA, Bafna Y. Management of an infant having natal teeth. *BMJ Case Rep*. 2013; doi:10.1136/bcr-2013-010049.
12. Kadam M, Kadam D, Bhandary S, Hukkeri RY. Natal and neonatal teeth among cleft lip and palate infants. *Natl J Maxillofac Surg*, 2013; 4: 73-6.
13. Shah B, Ashok L, Sujatha GP. Ellis-van Creveld syndrome: a case report. *J Indian Soc Pedod Prev Dent*, 2008; 6: 19-22.
14. Robotta P. and Schafer E. Hallermann-Streiff syndrome: case report and literature review. *Quintessence Int*, 2011; 42: 331-8.
15. Senanayake MP, Karunaratne I. Persistent lingual ulceration (Riga-Fede disease) in an infant with Down syndrome and natal teeth: a case report. *J Med Case Rep*, 2014; 22; 8: 283-5.
16. Cunha RF, Boer FA, Torriani DD, Frossard WT. Natal and neonatal teeth: review of the literature. *Pediatr Dent*, 2001; 23: 158-62.
17. Spouge JD , Feasby WH. Erupted teeth in the newborn. *Oral Surg Oral Med Oral Pathol*, 1966; 22: 198-208.
18. Malki GA, Al-Badawi EA, Dahlan M. Natal teeth: a case report and reappraisal. *A Case Rep Dent* 2015; doi: 10.1155-2015-147580.
19. Ruschel HC, Spiguel MH, Piccinini DD, Ferreira SH, Feldens E. Natal primary molar: clinical and histological aspects. *J Oral Science*, 2010; 52: 313-7.
20. Bigeard L, Hemmerle J, Sommermater JI. Clinical and ultrastructural study of the natal tooth: enamel and dentin assessments. *ASDC J Dent Child*, 1996; 63: 23-31.
21. Jasmin JR, Clergau-Guerithault S. A scanning electron microscopic study of the enamel of neonatal teeth. *J Biol Buccale*, 1991; 19: 309-14.
22. Sabel N, Klinberg G, Nietzsche S, Robertson A, Odelius H, Norén JG. Analysis of some elements in primary enamel during postnatal mineralization. *Swed Dent J*, 2009; 33: 85-95.
23. Lunt RC, Law DB. A review of the chronology of eruption of deciduous teeth. *J Am Dent Assoc*, 1974; 89: 872-9.
24. Anneroth G, Isacson G, Lindwall AM, Linge G. Clinical, histologic and micro-radiographic study of natal, neonatal and pre-erupted teeth. *Scand J Dent Res*, 1978; 86: 58-66.
25. Baumgart M, Lussi A. Natal and und neonatal teeth. *Schweiz Monatsschr Zahnmed*, 2006; 116: 895-903
26. Stamfelj I, Jan J, Cvetko E, Gaspersic D. Size, ultrastructure, and microhardness of natal teeth with agenesis of permanent successors. *Ann Anat*, 2010; 20; 192: 220-6.
27. Sigal MJ, Mock D, Weinberg S. Bilateral mandibular hamartomas and familial natal teeth. *Oral Surg Oral Med Oral Pathol*. 1988; 65: 731-5.