

# Retrospective Analysis of Serology and Radiology Results in Patients with Suspected Cystic Echinococcosis Through 3 Years Period

*Kistik Ekinokokoz Şüphesiyle Serolojik ve Radyolojik Değerlendirme Yapılan Hastaların Üç Yıllık Periyotta Retrospektif Analizi*

✉ Büşra Betül Özmen Çapın<sup>1</sup>, ✉ Barış Can<sup>1</sup>, ✉ Meltem Kurşun<sup>2</sup>, ✉ Canan Cimşit<sup>2</sup>, ✉ Ayşegül Karahaslan<sup>1</sup>

<sup>1</sup>Marmara University Pendik Research and Training Hospital, Department of Medical Microbiology, İstanbul, Türkiye

<sup>2</sup>Marmara University Pendik Research and Training Hospital, Department of Radiology, İstanbul, Türkiye

Cite this article as: Özmen Çapın BB, Can B, Kurşun M, Cimşit C, Karahaslan A. Retrospective Analysis of Serology and Radiology Results in Patients with Suspected Cystic Echinococcosis Through 3 Years Period. Türkiye Parazitoloj Derg 2023;47(2):83-7.

## ABSTRACT

**Objective:** Cystic echinococcosis (CE), caused by the larval stage of *Echinococcus granulosus* sensu lato, is one of the neglected zoonotic infectious diseases and Türkiye is among the endemic countries. This study was designed to analyze serology results for patients who were diagnosed as CE by clinical symptoms and radiological methods over a three-year period.

**Methods:** Sera were analyzed for Anti-*E. granulosus* IgG by a chemiluminescence immunoassay (CLIA) (HYDATIDOSIS VIRCLIA\* IgG MONOTEST, Vircell) using the VIRCLIA\* (CLIA; Vircell, Granada, Spain) and results processed by the dedicated software. Cut-off for a positive test was  $\geq 1.1$  index value. Echinococcal cysts were detected based on ultrasonography, computed tomography, and magnetic resonance imaging.

**Results:** A total of 244 sera were analyzed from 109 patients, during three-year-period from January 2018 to December 2020. Anti-*E. granulosus* IgG was ordered twice in 89 patients, three times in 15 patients, four times in four patients, and five times in one patient. CLIA test was positive among 41 of 109 (37.6%) patients in whom 32 (76%) had only hepatic involvement, whereas in 5 (12%) hepatic and pulmonary involvement were coexisted. The mean age of seropositive patients was 39.8 (6-75 $\pm$ 2.72) and 61.9% of them (n=26) were female. Time intervals between sequential test orders varied from 1 day to 33 months. Eight seropositive patients turned out to be negative, and one of 66 seronegative patients became seropositive. Positive test results were converted to negative in the case of therapy or cyst inactivity.

**Conclusion:** We may conclude that CLIA could be used as a complementary tool for CE patient follow-up.

**Keywords:** Cystic echinococcosis, CLIA, serology, radiology

## ÖZ

**Amaç:** *Echinococcus granulosus* sensu lato'nun larval evresinin neden olduğu kistik ekinokokkoz (CE), ihmal edilen zoonotik enfeksiyon hastalıklarından biridir. Türkiye CE açısından endemik ülkeler arasında yer almaktadır. Bu çalışma, klinik semptomlar ve radyolojik yöntemlerle CE tanısı konan hastaların seroloji sonuçlarını üç yıllık bir süre içinde analiz etmek için tasarlanmıştır.

**Yöntemler:** Serum örnekleri VIRCLIA\* (CLIA; Vircell, Granada, İspanya) kullanılarak bir kemilüminesans immünoanaliz (CLIA) (HYDATIDOSIS VIRCLIA\* IgG MONOTEST, Vircell) yöntemi ile anti-*E. granulosus* IgG için analiz edildi ve sonuçlar özel bir yazılım programı kullanılarak değerlendirildi. Pozitif sonuç için indeks değeri  $\geq 1,1$  olarak belirlendi. Ekinokok kistlerinin tespitinde ultrasonografi, bilgisayarlı tomografi ve manyetik rezonans görüntüleme kullanıldı.

**Bulgular:** Ocak 2018-Aralık 2020 tarihleri arasında 109 hastadan toplam 244 serum analiz edildi. Anti-*E. granulosus* IgG 89 hastada iki kez, 15 hastada üç kez, dört hastada dört kez ve bir hastada beş kez istendi. CLIA testi hastaların 41'inde (37,6) pozitif bulundu ve bu hastaların 32'sinde (%76) sadece karaciğer tutulumu var iken, 5'inde (%12) akciğer ve karaciğer tutulumu birlikte saptandı. Seropozitif hastaların yaş ortalaması 39,8 (6-75 $\pm$ 2,72) olup, %61,4'ü kadındı. Ardışık test istemleri arasındaki zaman aralıkları 1 gün ile 33 ay arasında değişiyordu. İzlem sürecinde 8 seropozitif hasta negatife dönerken 66 seronegatif hastadan biri seropozitif oldu. Pozitif serolojinin tedavi veya kist inaktivasyonu durumunda negatife dönüştüğü belirlendi.

**Sonuç:** CLIA'nın CE hasta takibi için tamamlayıcı bir tanı yöntemi olarak kullanılabilirliği sonucuna varabiliriz.

**Anahtar Kelimeler:** Kistik ekinokokkoz, CLIA, seroloji, radyoloji

Received/Geliş Tarihi: 25.08.2022 Accepted/Kabul Tarihi: 14.02.2023

Address for Correspondence/Yazar Adresi: Ayşegül Karahaslan, Marmara University Pendik Research and Training Hospital, Department of Medical Microbiology, İstanbul, Türkiye

Phone/Tel: +90 532 582 35 82 E-mail/E-Posta: aysegulkarahasan@gmail.com ORCID ID: orcid.org/0000-0002-1560-2624

## INTRODUCTION

Cystic echinococcosis (CE) is a debilitating disease amongst neglected zoonotic infections and caused by the larval stage of the cestode *Echinococcus granulosus* sensu lato. The parasite is transferred from definitive hosts namely domestic dogs to livestock as its intermediate hosts (1). Human, in whom the larval stage occurs as hydatid cysts to a large extent in liver and lungs, acts as dead-end intermediate host (2). This infection has a chronic clinical course, and may cause serious morbidity, and over 1 million cases are reckoned all over the world (3). Several studies conducted among primary school population showed that CE prevalence in Türkiye is around 0.2 to 1.1% and these percentages expected to be increased with age (4-7). According to a cross-sectional, ultrasonography (US)-based, population study from the HERACLES project, the prevalence of abdominal CE was determined to be 0.59% in our country, and the calculated number of people who may be infected with CE was slightly over 100.000 in the rural areas (8).

Abdominal organs were affected in more than 70% of the cases and the diagnosis of CE primarily relies on radiology, namely US which is the reference method for staging of CE cysts. Serological methods including indirect hemagglutination assay, enzyme-linked immunosorbent assay (ELISA), western blot (WB), chemiluminescence immunoassay (CLIA) basically act as complementary tools for spotting antibodies in sera of suspected individuals. These techniques maintain their significance in case imaging results are uncertain or there is no experienced radiologist in the diagnosis of CE (9). Multiple factors (individual-related, test-related, setting-related, and cyst-related components) may affect the result and interpretation of serological tests. Although cross-reactivity arising from other cestode or helminth infections, malignities, hepatic cirrhosis may decrease specificity of the tests, a study which compares nine different sero assays CLIA showed 100% specificity (9,10). Studies from different centers in Türkiye revealed that 15.2-32% of clinically CE-suspected patients were seropositive (11-13).

In this retrospective study, we analysed CLIA results of our patients who were diagnosed as CE by clinical symptoms and radiological methods over three-year-period in order to evaluate the diagnostic value of CLIA for patients' follow-up.

## METHODS

### Study Group

This study was conducted at a tertiary referral center in İstanbul during three-year-period from January 2018 to December 2020. Clinical and radiological features of 109 patients whose repetitive serum samples were sent to microbiology laboratory for serological analysis of CE were analyzed. Data in terms of patients' demographic features (age and sex), administrative information (referral department), and medical history were obtained from hospital database. The study was approved by Local Ethics Committee of Marmara University (approval number: 1.4.2022-09.2022.522).

### Serological Investigation

Sera were analyzed by a CLIA (HYDATIDOSIS VIRCLIA® IgG MONOTEST, Vircell) using the VIRCLIA® (CLIA; Vircell, Granada, Spain) and results were interpreted according to the manufacturer's instructions. Briefly, each assay consists of three

reaction wells and five reagent wells [the conjugate containing anti-human IgG antibodies coupled with peroxidase, the serum dilution solution, the calibrator and two substrate components (peroxidase and luminol)]. The results are expressed as an "antibody index" [=sample relative light unit (RLU)/calibrator RLU], samples with indexes <0.9 are considered negative, while samples >1.1 are considered positive. Samples with an index between both values were considered equivocal and were retested.

### Radiological Features

Echinococcal cysts were classified mainly based on US, computed tomography (CT) and magnetic resonance imaging (MRI) according to the WHO-IWGE classification (14). Cysts were grouped into active (CE1, CE2, CE3a, CE3b) or inactive (CE4, CE5) CE. When  $\geq 2$  CE cysts were present, the patient was grouped according the active cyst, and when more cysts of the same stage were present, the patient was grouped according to the cyst of largest diameter.

### Statistical Analysis

A descriptive data set based on patients' records was prepared. Data were analysed in IBM SPSS Statistics for Windows, Version 23.0 (IBM Corp., Armonk, NY, USA). Descriptive statistics such as frequency, percentage, mean  $\pm$  standard error was used to evaluate the data set.

## RESULTS

A total of 244 sera was send from 109 patients with suspected CE. Majority of the tests (67%) were ordered by clinicians from general surgery, internal medicine, and infectious diseases departments. The mean age of the patients was 43.7 (6-81 $\pm$ 1.8) and 61.4% was female. A total of 47 (43%) patients underwent surgery and PAIR was used in 25 (22%) patients.

Time interval between sequential test orders varied between one day to 33 months. Median time interval between two serological test orders was five months. Anti-*E. granulosus* IgG was ordered twice in 89 patients, three times in 15 patients, four times in four patients, and five times in one patient. CLIA test was positive among 41 of 109 (37.6%) patients (Table 1). Among seropositive patients, 32 (76%) had only hepatic involvement whereas in 5 (12%) hepatic and pulmonary involvement were coexisted. Mean age of seropositive patients was 39.8 (6-75 $\pm$ 2.72) and 61.9% of them (n=26) were female.

During the given period, CLIA results of 11 patients showed a categorical change (Table 1). Eight of 41 seropositive patients turned to be negative and one of 66 seronegative patients became seropositive during follow-up. The patient who became seropositive was a 39-year-old female having multiple hepatic cysts under 5 cm and referred from department of general surgery. Her hydatid cysts were progressed with a dimension increase exceeding 5 cm and the patient turned positive 11 months later then the initial serum sample. Two children who had borderline samples became negative had hepatic cysts smaller than 5 cm. They were treated with drugs and no size change occurred during the follow-up. Among 41 initially seropositive patients, eight patients became seronegative (Table 2). Three patients (patients 1, 4, 5) underwent surgical resection. In 3 patients (patients 3, 7, 8) cysts became inactive during the follow-up although no dimensional change occurred. One patient's (patient 2) cyst size was the same as for both dimensional and activity however

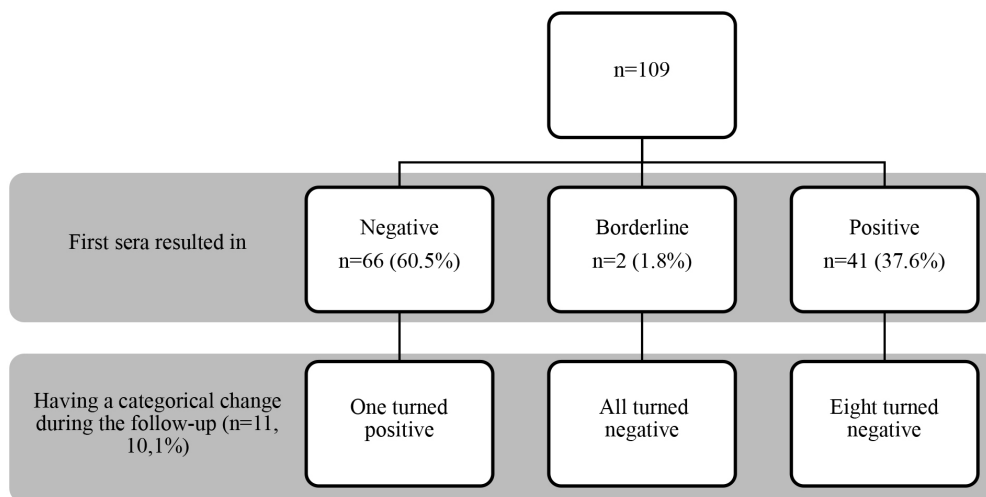
the serum sample turned to be negative. There was no sequential radiological imaging in one patient (patient 6) and the reason for becoming seronegative is not clear.

## DISCUSSION

According to the multicenter database of the European Register of Cystic Echinococcosis, the real burden of human CE remains

elusive, due to the peculiar characteristics of the disease, the heterogeneous and incomplete data recording of clinical cases and incomplete or inefficient official notification systems to compare different treatment outcomes (15). The expert consensus on the diagnosis and treatment of CE in humans underlines that diagnosis relies on clinical findings of patients, findings obtained from imaging tools and results of serological assays (9). Although there are different methods for radiological diagnosis like USG, CT

**Table 1.** Results of serological test of cystic echinococcosis patients during three-year-follow-up period



**Table 2.** Timeline of seropositive patients who become seronegative during the follow-up

Patient no.	Sex, age	Date and index value of serum	Imaging	Date and index value of serum	Imaging	Date and index value of serum	Imaging	Date and index value of serum	Imaging
1	Male, 35	November 2018 3,704	Hepatic CE* right, >10 cm	February 2020 0,858	Resected				
2	Female, 42	February 2018 1,816	Hepatic CE right, <5 cm	October 2018 0,966	Hepatic CE right, <5 cm	March 2019 0,249	Hepatic CE right, <5 cm		
3	Female, 40	December 2018 1,332	Hepatic CE 5-10 cm	September 2019 0,648	Hepatic CE 5-10 cm, inactive				
4	Female, 46	March 2019 7,915	Hepatic CE	August 2019 3,895	Resected	July 2020 0,841	Resected		
5	Male, 55	March 2018 1,949	Hepatic CE surgical treatment	July 2018 1,588	Resected	January 2019 1,152	Resected	January 2020 0,737	Resected
6	Female, 66	January 2019 2,355	Hepatic CL† 5-10 cm	September 2019 0,691	Not performed				
7	Male, 16	April 2018 1,295	Hepatic CE <5 cm	January 2020 0,237	Hepatic CE <5 cm, inactive				
8	Female, 55	October 2019 1,495	Hepatic CE right, 5-10 cm multiple cysts	December 2020 0,888	Hepatic CE right, 5-10 cm multiple cysts, inactive				

\*CE: Cystic echinococcosis, †CL: Cystic lesion

and MRI, USG is the method of choice for the detection of both hepatic and extrahepatic echinococcal cysts and it is also helpful in the follow-up period and sensitivity ranges from 93-98%. CT or MRI can be used in small cysts and if USG is not appropriate in terms of anatomic location (16). Echinococcal cysts were classified mainly based on US in our study according to the WHO-IWGE classification.

The prevalence of CE is reported to be higher in women and in our study, women constitute 59.4% of the cases (17). In CE patients, the liver is the most commonly affected organ and involvement of the right lobe is more common than the left lobe (18). The lung is the next commonly affected organ (19). In our study, among seropositive patients, 32 (76%) had only hepatic involvement whereas in 5 (12%) hepatic and pulmonary involvement were coexisted.

The assessment of serum anti-*Echinococcus granulosus* antibodies is applied as a complementary tool when imaging is not pathognomonic, or radiologists are not experienced enough in CE diagnosis. Performance of serological tests depends on a variety of features related to both the assay and the patients. There is no hundred percent valid algorithm to comply for choosing or interpretation of serological test for the diagnosis of CE. Ideally, two assays, including a test with high sensitivity for the detection of serum antibody followed by confirmation with a high-specific serological test, are recommended. A possible case is defined when a patient is having a clinical or epidemiological characteristic, and radiological findings or seropositivity for CE, whereas a probable case is defined when a patient is having a combination of both clinical and epidemiological history, imaging findings, and seropositivity on two tests. In Türkiye, only one serological assay can be reimbursed to the hospitals as the current "health practice statement" and automated CLIA test was used as a single assay for detection *E. granulosus* IgG antibody.

CE is frequently diagnosed clinically and radiologically in Türkiye and sero epidemiological field studies are limited. Serum samples (n=2.390) of suspected Echinococcosis patients sent to the National Parasitology Reference Laboratories of the General Directorate of Public Health were investigated for the presence of antibodies and 388 (16.2%) samples were found to be positive (20). In this study, it is not clear if samples are unique or there were repetitive samples. We have detected seropositivity by CLIA test among 41 of 109 (37.6%) patients in our study. When nine commercial assays including five ELISA, two WB, one CLIA, and one immunochromatographic test (ICT), for 135 hepatic CE patients were compared, only CLIA Vircell reached to 100%, specificity (10). False negative antibody results were reported due to cyst stage, cyst size, localization, and even due to the medical treatment of CE with albendazole and rupture of cysts (21-24).

Treatment options for CE are surgery, percutaneous procedures, drug treatment and observation (watch and wait) (9). Although surgery is mainly indicated in the treatment of hydatid disease, less invasive methods may be preferred more because of their successful results (17). In our study, a total of 47 (43%) patients underwent surgery and PAIR was used in 25 (22%) patients. As a limitation of the retrospective structure of the study, we could not exactly say the number of patients who received different kinds of treatment in between repetitive sampling, since detailed anamnesis of all patients were not accessible. Patients were on follow-up because of either their laboratory results or radiological findings regarding CE or previously diagnosed-CE.

There are limited studies that analyse the sero reactivity survey among repeated patient samples. Among 41 initially seropositive patients, eight patients became seronegative in our group. Three patients underwent surgical resection, and three patients' cysts became inactive during the follow-up although no dimensional change occurred. Two children who had borderline samples were treated with drugs and although no size change occurred during the follow-up, the serum samples turned to be negative. One patient become seropositive and her hydatid cysts were progressed with a dimensional increase exceeding 5 cm, as a previous study implies that there is a positive correlation between serological response and increased cyst size among active cysts (22). Seroconversion of CE patients is suggested as an indicator of therapeutic success (23). Although it may depend on the serological assay used, a follow-up study showed that serological method fails to detect recurrence (25). Studies illustrated that stage-specific approach is crucial and serological methods have an additional role to imaging tools for CE follow-up (26).

## CONCLUSION

Even though considerable progress has been made, uncertainties remain in the diagnosis and treatment of CE. Imaging techniques may not recognize early-stage cysts. Therefore new serodiagnostic tests that can be widely used and has high sensitivity and specificity should be defined. Serological methods can guide clinicians in the diagnosis of CE, although we have a small number of patients, we also suggest that CLIA could be used as a complementary tool for CE patients' follow-up.

### \* Ethics

**Ethics Committee Approval:** The study was approved by Local Ethics Committee of Marmara University (approval number: 1.4.2022-09.2022.522).

**Informed Consent:** Retrospective study.

**Peer-review:** Internally and externally peer-reviewed.

### \* Authorship Contributions

Surgical and Medical Practices: B.B.Ö.Ç., B.Ç., A.K., Concept: B.C., A.K., Design: B.B.Ö.Ç., B.C., A.K., Data Collection or Processing: B.B.Ö.Ç., B.C., M.K., C.C., A.K., Analysis or Interpretation: B.B.Ö.Ç., B.C., M.K., C.C., A.K., Literature Search: B.B.Ö.Ç., A.K., Writing: A.K.

**Conflict of Interest:** No conflict of interest was declared by the authors.

**Financial Disclosure:** The authors declared that this study received no financial support.

## REFERENCES

- Romig T, Deplazes P, Jenkins D, Giraudoux P, Massolo A, Craig PS, et al. Ecology and Life Cycle Patterns of Echinococcus Species. *Adv Parasitol* 2017; 95: 213-314.
- Kern P, Menezes da Silva A, Akhan O, Müllhaupt B, Vizcaychipi KA, Budke C, et al. The Echinococcoses: Diagnosis, Clinical Management and Burden of Disease. *Adv Parasitol* 2017; 96: 259-369.
- World Health Organization (WHO) [Internet]. Echinococcosis. [cited 2022 June 10] Available from: <https://www.who.int/news-room/fact-sheets/detail/echinococcosis>.
- Bakal U, Kazez A, Akyol M, Kocakoc E, Simsek S. A portable ultrasound based screening study on the prevalence and risk factors of cystic

- echinococcosis in primary school children in East Turkey. *Acta Trop* 2012; 123: 91-5.
5. Kilimcioglu AA, Ozkol M, Bayindir P, Girginkardeşler N, Ostan I, Ok UZ. The value of ultrasonography alone in screening surveys of cystic echinococcosis in children in Turkey. *Parasitol Int* 2006; 55: 273-5.
  6. Ok UZ, Ozkol M, Kilimcioglu AA, Dinç G, Bayindir P, Ostan I, et al. A province-based study using sampling method to investigate the prevalence of cystic echinococcosis among primary school children in Manisa, Turkey. *Acta Trop* 2007; 103: 116-22.
  7. Ozkol M, Kilimcioglu AA, Girginkardeşler N, Balcioglu IC, Sakru N, Korkmaz M, et al. A discrepancy between cystic echinococcosis confirmed by ultrasound and seropositivity in Turkish children. *Acta Trop* 2005; 93: 213-6.
  8. Tamarozzi F, Akhan O, Cretu CM, Vutova K, Akinci D, Chipeva R, et al. Prevalence of abdominal cystic echinococcosis in rural Bulgaria, Romania, and Turkey: a cross-sectional, ultrasound-based, population study from the HERACLES project. *Lancet Infect Dis* 2018; 18: 769-78.
  9. Brunetti E, Kern P, Vuitton DA; Writing Panel for the WHO-IWGE. Expert consensus for the diagnosis and treatment of cystic and alveolar echinococcosis in humans. *Acta Trop* 2010; 114: 1-16.
  10. Tamarozzi F, Longoni SS, Vola A, Degani M, Tais S, Rizzi E, et al. Evaluation of Nine Commercial Serological Tests for the Diagnosis of Human Hepatic Cyst Echinococcosis and the Differential Diagnosis with Other Focal Liver Lesions: A Diagnostic Accuracy Study. *Diagnostics (Basel)* 2021; 11: 167.
  11. Esenkaya Taşbent F, Yağcı B, Kadiyoran C, İyisoy MS. Comparative Evaluation of the Efficacy of Indirect Hemagglutination Test and Radiological Methods in the Pre-diagnosis of Cystic Echinococcosis. *Türkiye Parazitoloj Derg* 2021; 45: 22-7.
  12. Samancı Aktar G, Ayaydın Z, Rahmanlı Onur A, Uzala Mızraklı A, Tekay F. Retrospective Evaluation of Cases with the Pre-diagnosis of Cystic Echinococcosis Admitted to the Microbiology Laboratory of Diyarbakır Health Sciences Gazi Yaşargil Training and Research Hospital Between 2014 and 2017. *Türkiye Parazitoloj Derg* 2020; 44: 207-10.
  13. Ertabaklar H, Yıldız İ, Malatyalı E, Tileklioglu E, Çalışkan SÖ, Ertuğ S. Retrospective Analysis of Cystic Echinococcosis Results in Aydın Adnan Menderes University Training and Research Hospital Parasitology Laboratory Between 2005 and 2017. *Türkiye Parazitoloj Derg* 2019; 43: 118-22.
  14. WHO Informal Working Group. International classification of ultrasound images in cystic echinococcosis for application in clinical and field epidemiological settings. *Acta Trop* 2003; 85: 253-61.
  15. Rossi P, Tamarozzi F, Galati F, Akhan O, Cretu CM, Vutova K, et al. The European Register of Cystic Echinococcosis, ERCE: state-of-the-art five years after its launch. *Parasit Vectors* 2020; 13: 236.
  16. Mandal S, Mandal MD. Human cystic echinococcosis: epidemiologic, zoonotic, clinical, diagnostic and therapeutic aspects. *Asian Pac J Trop Med* 2012; 5: 253-60.
  17. Pakala T, Molina M, Wu GY. Hepatic Echinococcal Cysts: A Review. *J Clin Transl Hepatol* 2016; 4: 39-46.
  18. Budke CM, Carabin H, Ndimubanzi PC, Nguyen H, Rainwater E, Dickey M, et al. A systematic review of the literature on cystic echinococcosis frequency worldwide and its associated clinical manifestations. *Am J Trop Med Hyg* 2013; 88: 1011-27.
  19. Wen H, Vuitton L, Tuxun T, Li J, Vuitton DA, Zhang W, et al. Echinococcosis: Advances in the 21st Century. *Clin Microbiol Rev* 2019; 32: e00075-18.
  20. Yücesan B, Babür C, Kılıç S, Dikmen AU. Evaluation of Echinococcosis Pre-Diagnosis Patients Admitted to the National Parasitology Reference Laboratory of Turkey from 2014-2019. *Iran J Parasitol* 2022; 17: 250-8.
  21. Li T, Ito A, Pengcun R, Sako Y, Chen X, Qiu D, et al. Post-treatment follow-up study of abdominal cystic echinococcosis in tibetan communities of northwest Sichuan Province, China. *PLoS Negl Trop Dis* 2011; 5: e1364.
  22. Lissandrini R, Tamarozzi F, Piccoli L, Tinelli C, De Silvestri A, Mariconti M, et al. Factors Influencing the Serological Response in Hepatic Echinococcus granulosus Infection. *Am J Trop Med Hyg* 2016; 94: 166-71.
  23. Sarink MJ, van Genderen PJJ, Tielens AGM, van Hellemond JJ. Ruptured Echinococcus granulosus cysts in migrants: Is excessive antigen release causing false negative serology? *Travel Med Infect Dis* 2020; 35: 101412.
  24. Tamarozzi F, Silva R, Fittipaldo VA, Buonfrate D, Gottstein B, Siles-Lucas M. Serology for the diagnosis of human hepatic cystic echinococcosis and its relation with cyst staging: A systematic review of the literature with meta-analysis. *PLoS Negl Trop Dis* 2021; 15: e0009370.
  25. Stojkovic M, Adt HM, Rosenberger K, Boubaker G, Hernandez-Gonzalez A, Junghanss T, et al. Follow-up of surgically treated patients with cystic echinococcosis: can novel recombinant antigens compete with imaging? Analysis of a patient cohort. *Trop Med Int Health* 2017; 22: 614-21.
  26. Piccoli L, Tamarozzi F, Cattaneo F, Mariconti M, Filice C, Bruno A, et al. Long-term sonographic and serological follow-up of inactive echinococcal cysts of the liver: hints for a "watch-and-wait" approach. *PLoS Negl Trop Dis* 2014; 8: e3057.