

## LETTERS

## Weight loss with purpura and pain at the distal femora

K F Haegele, N J Buechner, C A Stueckle, L C Rump, S M Weiner

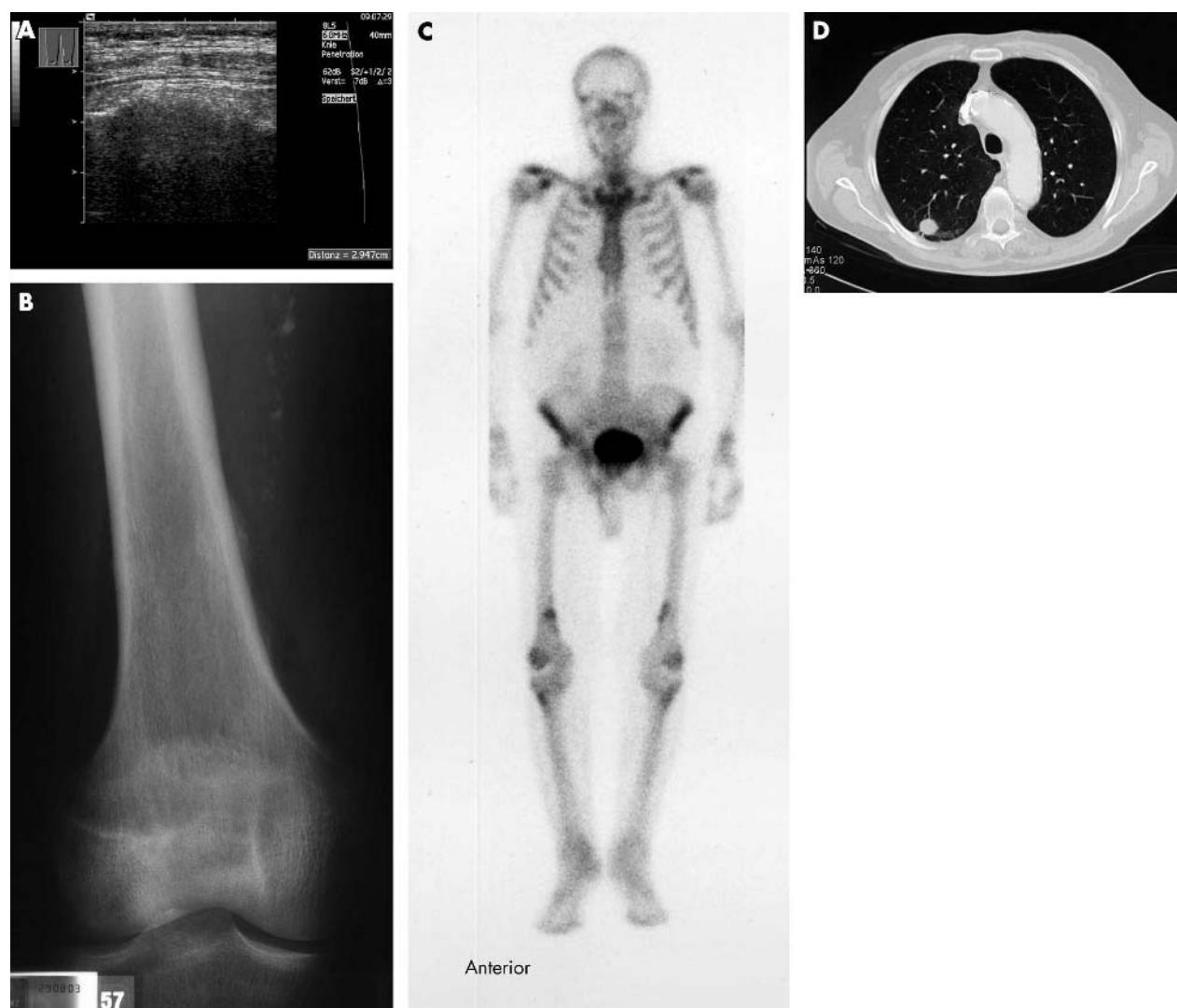
*Ann Rheum Dis* 2005;64:1373–1374. doi: 10.1136/ard.2004.023325

Paraneoplastic syndromes may occur as the first clinical symptom at an early stage of malignant diseases in about 7–10% of cases.<sup>1</sup> As presented here, intensive investigations may be necessary to uncover an early curable tumour.

## CASE REPORT

A 72 year old man presented with multiple purpuric and necrotising skin eruptions (sized 2–20 mm) covering mainly the extremities and, to a lesser extent, the trunk. He had noticed a weight loss of 12 kg in the past 2 months. There

was a history of smoking with chronic obstructive pulmonary disease and partial colectomy because of a benign adenoma. Laboratory investigations showed a normal erythrocyte sedimentation rate (9 mm/1st h), but C reactive protein was raised (43 mg/l). Serological markers, such as anti-nuclear antibodies, antineutrophil cytoplasmic antibodies, cryoglobulins, and hepatitis B and hepatitis C were excluded. A diagnostic procedure was performed to exclude a neoplasm, but, chest radiography, abdominal ultrasonography, gastroscopy, and colonoscopy were normal. Prednisone was



**Figure 1** (A) Musculoskeletal ultrasound demonstrated an echogenic irregular focus above the surface of the distal femoral bone with distal acoustic shadowing (longitudinal scan). (B) Plain radiography of the right femur disclosed smooth, lamellated periosteal new bone formation, consistent with hypertrophic osteoarthropathy. (C) A bone scan showed irregular increased uptake involving the distal femur bilaterally. (D) Computed tomography of the chest showed a small mass at the right lung.

**Table 1** Differential diagnosis of periostitis

Diseases associated with periostitis	Predominant location of periostitis
Hypertrophic osteoarthropathy	Distal diaphysis of long bones and metacarpal joints
Psoriatic onycho-pachydermo periostitis	Terminal phalanx
Psoriatic arthritis	Phalanges of fingers and toes
Reiter's syndrome	Phalanges of fingers and toes
Athletic overuse (running, jumping)	Upper and lower extremities
Ossifying fasciitis	Variable
Periostitis ossificans	Variable
Polyarteritis nodosa	Lower extremities
Systemic lupus erythematosus	Variable
Facial infections	Mandibule, orbita
Florid reactive periostitis	Phalanges of hands and feet
Osteoblastoma	Variable
Bizarre parosteal osteochondromatous proliferation (Nora's tumour)	Bones of the hands and feet
Chondrosarcoma	Variable
Treatment with interleukin 11	Clavicle, long bones
Osteomyelitis	Variable
Chronic leg ulcers	Tibia
SAPHO syndrome	Variable

given at a dose of 1 mg/kg body weight, with gradual improvement of the cutaneous vasculitis.

During the residential period the patient complained of pain in the region of the distal femur and the ankle bilaterally. Musculoskeletal ultrasound of the knee joints showed an effusion of 6 ml from the right and 3 ml from the left, without signs of synovitis, but discrete osteophytes. However, at the surface of the distal femoral bone echogenic irregular foci bilaterally with distal acoustic shadowing were seen, suggesting periosteal calcifications (fig 1A). An x ray examination confirmed symmetric periosteal reactions of the femora of both sides (fig 1B), compatible with periostitis. Inflammatory activity was shown by a significant enhancement in both distal femora in a three phase bone scan with technetium-99m DPD (fig 1C).

Even though there was no sign of a tumour on the standard chest radiographs a computed tomographic scan of the lung was performed. A suspect lesion of 1.9 cm in diameter in the right lung was seen (fig 1D). A transthoracic puncture showed a highly differentiated adenocarcinoma of the lung. No metastasis was seen. The patient was referred to a thoracic surgeon and the tumour was excised. Re-evaluation 6 months after excision of the tumour showed complete remission of bone pain and vasculitis without immunosuppressive treatment.

## DISCUSSION

Our patient presented with two paraneoplastic syndromes: hypertrophic osteoarthropathy and cutaneous vasculitis.

Hypertrophic osteoarthropathy is most commonly seen in Pierre-Marie-Bamberger's syndrome. This syndrome is characterised by the concurrence of clubbed fingers, arthralgia, and painful periostitis of the extremities, and occurs in pulmonary, cardiac, hepatic, or intestinal diseases.<sup>2</sup> Rarely,

periostitis may be the only manifestation of Pierre-Marie-Bamberger's syndrome<sup>3</sup> as in our patient. The periostitis is the result of subperiosteal bone formation, occurring mainly on the distal diaphysis of the long bones. Effusions into the large joints with little inflammatory cell exudation are a frequent finding. The diagnosis of periostitis is usually made by radiography and by bone scan. As we showed, musculoskeletal ultrasound may also visualise periostitis, but it is needed especially to look for periosteal lesions far from the adjacent joints. Table 1 presents other conditions associated with periostitis.

Non-small lung cell cancer is the most common malignancy associated with both Pierre-Marie-Bamberger's syndrome and cutaneous vasculitis.<sup>4-5</sup> However, hypertrophic osteoarthropathy is more common (4.9% in one study) than paraneoplastic vasculitis in patients with lung cancer.<sup>6-7</sup> Differential diagnosis includes polyarteritis nodosa and systemic lupus erythematosus; both have been associated with periosteal reactions and vasculitis in anecdotal reports.<sup>8-10</sup> However, as demonstrated by our case, computed tomography of the lung should be performed in the presence of unexplained vasculitis or periostitis, or both, even if standard chest radiography of the lung shows no pathological findings.

## Authors' affiliations

**K F Haegele, N J Buechner, L C Rump, S M Weiner**, Medizinische Klinik I, Marienhospital, Klinikum der Ruhr-Universität Bochum, Herne, Germany

**C A Stueckle**, Radiologie, Marienhospital, Klinikum der Ruhr-Universität Bochum, Herne, Germany

Correspondence to: Dr S M Weiner, Medizinische Klinik I, Marienhospital, Klinikum der Ruhr-Universität Bochum, Hölkeskampring 40, 44625 Herne, Germany; stefan.weiner@ruhr-uni-bochum.de

Accepted 7 February 2005

## REFERENCES

- Abu-Shakra M**, Buskila D, Ehrenfeld M, Conrad K, Shoenfeld Y. Cancer and autoimmunity: autoimmune and rheumatic features in patients with malignancies. *Ann Rheum Dis* 2001;**60**:433-40.
- Martinez-Lavin M**. Hypertrophic osteoarthropathy. *Curr Opin Rheumatol* 1997;**9**:83-6.
- Clarke S**, Barnsley L, Peters M, Morgan L, Van der Wall H. Hypertrophic pulmonary osteoarthropathy without clubbing of the digits. *Skeletal Radiol* 2001;**30**:652-5.
- Pankow W**, Neumann K, von Wichert P. Bronchial carcinoma associated with pulmonary osteoarthropathy (Marie-Bamberger disease). *Pneumologie* 1990;**44**:1306-11.
- Kurzrock R**, Cohen PR, Markowitz A. Clinical manifestations of vasculitis in patients with solid tumors. A case report and review of the literature. *Arch Intern Med* 1994;**14**:334-40.
- Suteanu S**, Rohan C, Gherasim E, Stoica V. Hypertrophic osteoarthropathy secondary to bronchopulmonary cancer (our experience). *Rom J Intern Med* 1992;**30**:281-4.
- Greer JM**, Longley S, Edwards L, Effenbein GJ, Panush RS. Vasculitis associated with malignancy. Experience with 13 patients and literature review of literature. *Medicine (Baltimore)* 1988;**67**:220-30.
- Astudillo LM**, Rigal F, Couret B, Arlet-Suau E. Localized polyarteritis nodosa with periostitis. *J Rheumatol* 2001;**28**:2758-9.
- Aries PM**, Reuter M, Lamprecht P, Gross WL. Periostitis as the initial manifestation of systemic vasculitis. *Ann Rheum Dis* 2005;**64**:329-30.
- Glickstein M**, Neustadter L, Dalinka M, Kricun M. Periosteal reaction in systemic lupus erythematosus. *Skeletal Radiol* 1986;**15**:610-12.

# Long term infliximab treatment for severe psoriatic arthritis: evidence of sustained clinical and radiographic response

F Rinaldi, G Provenzano, A Termini, M Spinello, F La Seta

*Ann Rheum Dis* 2005;64:1375–1376. doi: 10.1136/ard.2004.033233

Psoriatic arthritis (PsA) affects about 30% of patients with psoriasis and is a chronic inflammatory rheumatic disease, with the development of erosive and deforming arthritis in about 40% of patients.<sup>1</sup> Tumour necrosis factor  $\alpha$  (TNF $\alpha$ ) has an established role in the pathogenesis of PsA, and the TNF $\alpha$  receptor blocker etanercept has been approved for its treatment.<sup>2</sup>

There are also encouraging data about the efficacy of infliximab,<sup>3–5</sup> but its long term efficacy and safety in PsA have been questioned.<sup>6</sup>

## METHODS AND RESULTS

We evaluated in an open label, 2 year study the safety and efficacy of infliximab in association with methotrexate for patients with severe PsA. This study was an extension protocol of an initial 6 month study.<sup>7</sup>

Four men and eight women with PsA and active disease despite treatment with methotrexate + steroid + non-steroidal anti-inflammatory drugs had been enrolled and treated with five infusions of infliximab (Remicade, Centocor) at a dose of 5 mg/kg at weeks 0, 2, 6, 14, and 22. Thereafter the patients continued treatment with 5 mg/kg every 6 or 8 weeks for up to 2 years.

The patients had a mean (SD) age of 48.4 (13.6) years and a mean duration of articular symptoms of 8.6 (5.6) years. Eleven of the 12 patients had a polyarticular pattern of disease with predominantly peripheral arthritis. Two patients had been withdrawn from the study before the fifth infusion owing to the occurrence of severe diseases and another patient had to stop infliximab after the seventh infusion owing to a lymphadenitis due to cytomegalovirus. Nine patients continued infliximab treatment for up to 2 years.

The following outcome measures were evaluated: patient evaluation of global health status (100 mm visual analogue scale (VAS)); patient global assessment of disease activity (100 mm VAS); patient assessment of pain (100 mm VAS); Health Assessment Questionnaire (HAQ) scores; physician global assessment of disease activity (100 mm VAS); tender joint count; swollen joint count; erythrocyte sedimentation rate

(ESR); C reactive protein level (CRP); Psoriasis Area and Severity Index (PASI).

The American College of Rheumatology (ACR) improvement criteria for rheumatoid arthritis with 20%, 50%, and 70% improvement were also assessed.

Radiographs of the hands and wrists were obtained at baseline and at 2 years for the patients with peripheral polyarthritis completing 2 years of infliximab treatment and were scored according to the modified Sharp's method.<sup>8</sup>

At week 26 a significant decrease ( $p \leq 0.05$ , by *t* test for paired data) had been seen for all variables, with the exception of ESR. At 1 and 2 years a significant decrease was maintained for all the outcome measures, with the persisting exception of ESR (table 1). Seven patients had received infliximab every 8 weeks, two of them every 6 weeks owing to a partial loss of efficacy.

At 1 year, 8/9 (89%) patients met the ACR20 and 6/9 (67%) patients the ACR70. At 2 years 9/9 (100%) patients met the ACR20 and 5/9 (56%) patients the ACR70.

Eight of nine patients completing 2 years of infliximab treatment had a predominantly peripheral polyarthritis. In these eight patients we did not observe a significant increase of radiographic Sharp's score from baseline (table 2). In 5/8 (63%) patients we did not see any increase in Sharp's score at the end of 2 years of infliximab treatment.

## DISCUSSION

Our data suggest that long term treatment with infliximab may be highly effective for patients with severe PsA. These results are in partial contrast with those from another observational study,<sup>6</sup> but similar to other recent observations.<sup>9</sup> TNF $\alpha$  neutralising agents are being used by an increasing number of patients with PsA and the Italian Society of Rheumatology has recently published specific guidelines for their appropriate use.<sup>10</sup>

PsA is a heterogeneous disease and we need larger studies and more data to better select patients with PsA who may benefit from anti-TNF $\alpha$  treatment.

**Table 1** Outcome measures at baseline, week 26, years 1 and 2. Values are given as mean (SD)

Outcome measure	Baseline (12 patients)	Week 26 (10 patients)	Year 1 (9 patients)	Year 2 (9 patients)
Patient health status	28.3 (22.1)	63.0 (23.6)*	77.2 (10.9)*	77.8 (13.9)*
Patient pain	84.2 (17.3)	33.0 (27.1)*	33.3 (29.6)*	26.7 (20.6)*
Patient disease activity	82.5 (18.6)	28.0 (16.2)*	27.8 (27.7)*	25.5 (16.7)*
HAQ score	2.0 (0.6)	0.9 (1.1)*	0.6 (0.6)*	0.6 (0.8)*
Physician disease activity	74.2 (14.4)	27.0 (17.0)*	22.2 (19.9)*	23.3 (15)*
Tender joint count	31.7 (22.9)	9.6 (12.7)*	10.1 (12.0)*	3.7 (4.4)*
Swollen joint count	9.9 (6.8)	2.3 (4.6)*	1.9 (4.3)*	0.5 (1.1)*
PASI	12.1 (10.3)	1.1 (2.7)*	2.2 (4.5)*	0.4 (0.4)*
ESR (mm/1st h)	21.6 (15.5)	20.2 (20.4)	14.3 (10.8)	21.1 (16.9)
CRP (mg/l)	0.9 (0.9)	0.2 (0.4)*	0.2 (0.5)*	0.3 (0.5)*

\* $p \leq 0.05$  as compared with baseline (determined by *t* test for paired data).

**Table 2** Evaluation of radiographic progression of joint damage according to modified Sharp's score (eight patients)

	Baseline	After 2 years of infliximab
Global Sharp's score	65.4 (43.5)	66 (43.2)
Erosions	33.9 (24.2)	34.5 (23.9)
Joint space narrowing	31.5 (19.9)	31.5 (19.9)

p non-significant as determined by *t* test for paired data. Values are given as mean (SD).

#### Authors' affiliations

**F Rinaldi, A Termini, M Spinello**, Division of Internal Medicine II, AO "V. Cervello", Palermo, Italy

**G Provenzano**, Department of Medicine, Division of Respiratory Diseases, Section of Systemic Autoimmune Diseases, AO "Villa Sofia-CTO", Palermo, Italy

**F La Seta**, Service of Radiology, AO "V. Cervello"; Palermo, Italy

Correspondence to: Dr G Provenzano, Department of Medicine, Division of Respiratory Diseases, Section of Systemic Autoimmune Diseases, Azienda Ospedaliera "Villa Sofia-CTO", Via Ingegneros No 33, 90100 Palermo, Italy; giuseppe.provenzano5@tin.it

Accepted 7 February 2005

## Topical tacrolimus treatment in a patient with dermatomyositis

**C E Lampropoulos, D P D' Cruz**

#### REFERENCES

- 1 Gladman DD. Psoriatic arthritis. *Rheum Dis Clin North Am* 1998;**24**:829-44.
- 2 Mease PJ, Kivitz AJ, Burch FX, Siegel EL, Cohen SB, Ory P, et al. Etanercept treatment of psoriatic arthritis. Safety, efficacy and effect on disease progression. *Arthritis Rheum* 2004;**50**:2264-72.
- 3 Van den Bosch F, Kruihof E, Baeten D, Herrensens A, de Keyser F, Mielans H, et al. Randomized double-blind comparison of chimeric monoclonal antibody to tumour necrosis factor- $\alpha$  infliximab versus placebo in active spondyloarthritis. *Arthritis Rheum*, 2002;**46**:755-65.
- 4 Antoni C, Dechant C, Hanns-Martin Lorenz PD, Wendler J, Ogilvie A, Lueftl M, et al. Open label study of infliximab treatment for psoriatic arthritis: clinical and magnetic resonance imaging measurements of reduction of inflammation. *Arthritis Rheum* 2002;**47**:506-12.
- 5 Salvarani C, Cantini F, Olivieri I, Macchioni P, Padula A, Niccoli L, et al. Efficacy of infliximab in resistant psoriatic arthritis. *Arthritis Rheum* 2003;**49**:541-5.
- 6 Feletar M, Brockbank JE, Schentag CT, Lapp V, Gladman DD. Treatment of refractory psoriatic arthritis with infliximab: a 12 month observational study of 16 patients. *Ann Rheum Dis* 2004;**63**:156-61.
- 7 Provenzano G, Termini A, Le Mali C, Rinaldi F. Efficacy of infliximab in psoriatic arthritis resistant to therapy with disease modifying antirheumatic drugs: an open pilot study. *Ann Rheum Dis* 2003;**62**:680-1.
- 8 Sharp JT, Ypung DY, Bluhm JB, Brook A, Brower AC, Corbett M, et al. How many joints in the hands and wrists should be included in a score of radiologic abnormalities used to assess rheumatoid arthritis? *Arthritis Rheum* 1985;**28**:1326-35.
- 9 Yazdani-Biuki B, Wohlfart K, Mulabecirovic A, Mueller T, Hermann J, Graninger WB, et al. Long term treatment of psoriatic arthritis with infliximab. *Ann Rheum Dis* 2004;**63**:1531-2.
- 10 Salvarani C, Olivieri I, Cantini F, Marchesoni A, Punzi L, Scarpa R, et al. Recommendations for the appropriate use of anti-TNF $\alpha$  therapy in patients with psoriatic arthritis. *Reumatismo* 2004;**56**:133-8.

*Ann Rheum Dis* 2005;**64**:1376-1377. doi: 10.1136/ard.2004.032714

**D**ermatomyositis is an idiopathic inflammatory process manifested by proximal muscle weakness and cutaneous lesions such as Gottron's sign, heliotrope rash, erythematous photosensitive rash, or periungual erythema. Other unusual cutaneous manifestations are ichthyosis, panniculitis, erythroderma, lichen planus, vesicle and bullae formation, follicular hyperkeratosis, malacoplakia, and papular mucinosis.<sup>1</sup> Administration of systemic agents such as corticosteroids, methotrexate (MTX), hydroxychloroquine (HCQ), mycophenolate mofetil, intravenous immunoglobulins, and/or azathioprine for the underlying systemic disease leads in many cases to remission of the cutaneous lesions. Nevertheless, many patients have resistant cutaneous lesions despite treatment. On the other hand, cutaneous lesions may be the major manifestation of the disease, making it difficult to justify systemic agents because of their side effects.

#### CASE REPORT

A 61 year old woman with dermatomyositis and cutaneous lesions, refractory to previous treatment, with good response to tacrolimus ointment is described. Her cutaneous lesions comprised a photosensitive rash over her face, neck and hands, heliotrope rash, and Gottron's sign.

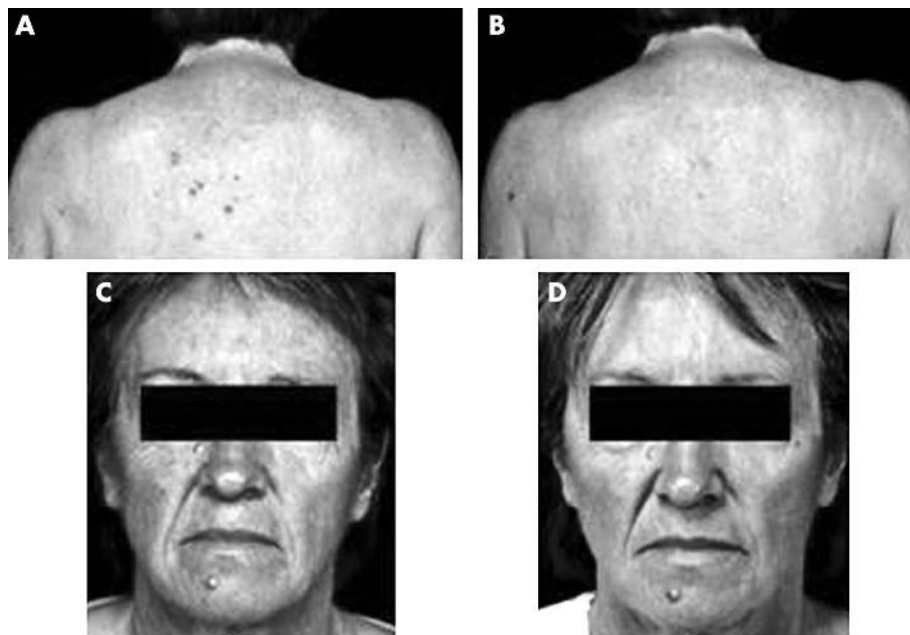
Treatment was started with MTX (10 mg/week intramuscularly). Two months later, the muscle weakness was markedly improved, but the cutaneous lesions were still active with accompanying pain and pruritus. MTX was increased to 15 mg/week and HCQ was added (200 mg/day with gradual increase to 400 mg/day), but after 1 year there

was no response and HCQ was discontinued. The extensive cutaneous lesions were temporarily relieved with oral prednisolone. The photosensitive rash worsened after exposure to fluorescent lamps, and monochromator light testing showed a marked papular reaction and sensitivity to the emissions of the lamps. In 2002, MTX was discontinued as it had had no efficacy on the skin lesions.

One year later she had a severe flare of her skin disease over the face, arms, and upper chest without any proximal weakness. Tacrolimus ointment 0.1% was suggested as an alternative treatment and with her informed consent she started applying it twice a day over the affected areas. Four weeks later there was a good response of the skin rashes, especially of the upper chest (fig 1). Tacrolimus ointment was discontinued, but after 1 month the patient had another flare of the skin rash. Tacrolimus ointment was restarted and the lesions improved. To date, her cutaneous lesions remain in remission with continuous use of the ointment.

#### DISCUSSION

Tacrolimus—isolated in 1984 from the fungus *Streptomyces tsukubaensis*—is a macrolide immunomodulator FK506, which acts on T lymphocytes and inhibits interleukin 2 transcription as well as other cytokines.<sup>2</sup> Since 1989 it has been widely used in preventing graft rejection after transplantation (liver, kidneys, lungs).<sup>3</sup> In 2000<sup>4</sup> tacrolimus ointment was approved for the treatment of atopic dermatitis.<sup>5</sup> Efficacy is similar or even better than corticosteroids (especially in children or for facial lesions, where only weak steroids can be used), without



**Figure 1** (A, C) Photosensitive rash on face and back upper chest before treatment. (B, D) Improvement of the cutaneous lesions 4 weeks later. A colour version of the figure can be seen at <http://www.annrheumdis.com/supplemental>. Reproduced with the patient's permission.

the adverse effects of skin atrophy (no impairment of collagen synthesis) and serious systemic absorption.<sup>6</sup> Common side effects are burning sensations, itching, or erythema, which usually decline as treatment is continued owing to improvement of the skin's condition.<sup>7</sup> Tacrolimus also seems to be effective in resistant cutaneous lesions of other diseases such as psoriasis, localised scleroderma, chronic actinic dermatitis, pyoderma gangrenosum, Behçet's disease, lichen planus, rheumatoid ulcers, and steroid rosacea.

To date, there are a few case reports and a pilot study suggesting good therapeutic efficacy of tacrolimus ointment in connective tissue diseases like dermatomyositis.<sup>8-10</sup> Our patient's cutaneous lesions, which had been refractory to any previous treatment, seemed to respond well. These results suggest that tacrolimus ointment could be considered as an alternative treatment for resistant cutaneous lesions in dermatomyositis.



A colour version of fig 1 can be found at <http://www.annrheumdis.com/supplemental>

#### Authors' affiliations

**C E Lampropoulos, D P D' Cruz**, Lupus Research Unit, The Rayne Institute, St Thomas' Hospital, London, UK

Competing interest statement: Neither of the authors have any competing interests.

Correspondence to: Dr D P D' Cruz, The Lupus Research Unit, The Rayne Institute, St Thomas' Hospital, 4, Lambeth Palace Road, London SE1 7EH, UK; [david.d'cruz@kcl.ac.uk](mailto:david.d'cruz@kcl.ac.uk)

Accepted 14 January 2005

#### REFERENCES

- 1 Kovacs SO, Kovacs SC. Dermatomyositis. *J Am Acad Dermatol* 1998;**39**:899-920.
- 2 Sawada S, Suzuki G, Kawase Y, Takaku F. Novel immunosuppressive agent, FK506. In vitro effects on the cloned T cell activation. *J Immunol* 1987;**139**:1797-803.
- 3 Starzl TE, Todo S, Fung J. FK506 for liver, kidney and pancreas transplantation. *Lancet* 1989;**8670**:1000-4.
- 4 US FDA. US FDA Advisory Committee recommends approval for tacrolimus ointment. *Skin Therapy Letter* 2000;**6**:5.
- 5 Kang S, Lucky AW, Pariser D, Lawrence I, Hanifin JM. Long-term safety and efficacy of tacrolimus ointment for the treatment of atopic dermatitis in children. *J Am Acad Dermatol* 2001;**44**(suppl 1):S58-64.
- 6 Bos JD. Non-steroidal topical immunomodulators provide skin-selective and self-limiting treatment in atopic dermatitis. *Eur J Dermatol* 2003;**13**:455-61.
- 7 Soter NA, Fleischer AB, Webster OF. Tacrolimus ointment for the treatment of atopic dermatitis in adult patients: part II, safety. *J Am Acad Dermatol*, 2001;**44**(suppl 1):S39-46.
- 8 Lampropoulos CE, Sangle S, Harrison P, Hughes GRV, D' Cruz DP. Topical tacrolimus therapy of resistant cutaneous lesions in lupus erythematosus: a possible alternative. *Rheumatology (Oxford)* 2004;**20**:54-7.
- 9 Hollar CB, Jorizzo JL. Topical tacrolimus 0.1% ointment for refractory skin disease in dermatomyositis: a pilot study. *J Dermatolog Treat* 2004;**15**:35-9.
- 10 Yoshimatsu T, Ohtani T, Sakamoto T, Oshima A, Furukawa F. Topical FK506 (tacrolimus) therapy for facial erythematous lesions of cutaneous lupus erythematosus and dermatomyositis. *Eur J Dermatol* 2002;**12**:50-2.

# Surgery in patients receiving anti-tumour necrosis factor $\alpha$ treatment in rheumatoid arthritis: an observational study on 50 surgical procedures

D Wendling, J-C Balblanc, A Brousse, A Lohse, G Lehuède, P Garbuio, E Toussiro, B Auge, D Jacques

*Ann Rheum Dis* 2005;64:1378–1379. doi: 10.1136/ard.2005.037762

Currently, little information is available about the interaction between anti-tumour necrosis factor (TNF) treatment and surgery.<sup>1</sup>

In an attempt to evaluate the relative safety of anti-TNF and its impact on the course of disease in patients with rheumatoid arthritis (RA) undergoing surgery, we included in a retrospective study all such patients followed up in a regional network. The network allows close follow up as the patients regularly renew their prescription at the hospital. Surgical outcomes focused on infection and other complications together with the postoperative impact on RA disease activity. A flare of RA was defined as an increase in the joint count and global assessment of >20%.

Fifty surgical procedures were recorded in 30 patients with RA (25 women), with a mean age of 54.6 years, a mean disease duration of 12.3 years, and a mean of 3.7 previous disease modifying antirheumatic drugs. In 38 cases, anti-TNF was associated with a disease modifying antirheumatic drug (methotrexate 33 cases) and with general steroid treatment in 41/50 patients receiving a mean of 8.2 mg/day of prednisone. The TNF blocker at the time of surgery was infliximab (n = 26), etanercept (n = 13), adalimumab (n = 11), with a mean exposure to an anti-TNF agent of 12.1 months (range 1–42). Discontinuation of the anti-TNF agent occurred before surgery in 18/50 patients, and for the rest, surgery was performed between two anti-TNF injections.

Table 1 summarises the type of surgery; the mean follow up after surgery was 14 months (range 1–42). No major complications, especially infections, occurred in either group whether the anti-TNF agent was discontinued or not. Three cases (6%) of minor postoperative side effects were recorded (delay of wound healing of 1–2 weeks). Six cases (12%) of moderate short lasting RA flares were reported occurring with each TNF blocker, in orthopaedic surgery, and significantly associated with anti-TNF interruption before surgery (5 interruptions/6 cases of flare versus 13 interruptions/44 surgical procedures without flare; Fisher's exact p value = 0.02).

In this group of patients with classic RA receiving an anti-TNF agent, the main result was the absence of a major complication after surgery, particularly pyogenic infection.<sup>2,3</sup> Methotrexate does not seem to have deleterious impact upon surgical outcome in RA.<sup>4</sup>

In Crohn's disease, Marchal *et al* found no significant differences in postoperative early minor or major complications or in duration of hospitalisation between infliximab exposed and infliximab naïve patients.<sup>5</sup> In RA, Bibbo and Goldberg found similar rates of complications in both groups (16 patients receiving an anti-TNF agent compared with 15 matched anti-TNF naïve patients) in foot and ankle surgery.<sup>6</sup>

In our study the overall rate of complication is lower than reported in large studies of anti-TNF $\alpha$  treatment, irrespective

**Table 1** Type of surgery in patients with RA receiving an anti-TNF agent

Type of surgery	No of patients
<i>Orthopaedic</i>	39
Foot and ankle	13
Hand and wrist	11
Total joint replacement	12
Hip	4
Shoulder	3
Knee	2
Elbow	1
Finger	2
Miscellaneous	3
<i>Non-orthopaedic</i>	11
Head and neck	5
Abdomen	6

of surgery. For example the percentage of patients developing severe infection is 2% in the ATTRACT study<sup>7</sup> (infliximab in RA), 4% in the ACCENT study in Crohn's disease,<sup>8</sup> and up to 18% in some RA cohort studies.<sup>9</sup> The retrospective design, the size of our population, the absence of comorbidities and of a control group may represent bias in the present study. Recently, Giles *et al* reported an increased risk of infection (odds ratio = 5.3) during orthopaedic surgery for patients receiving an anti-TNF agent.<sup>10</sup>

Our observational study did not find an increased frequency of adverse events related to uninterrupted use of anti-TNF treatment in patients with RA undergoing surgery.

## Authors' affiliations

D Wendling, J-C Balblanc, A Brousse, A Lohse, G Lehuède, P Garbuio, E Toussiro, B Auge, D Jacques, Regional Rheumatologic Network for Biotherapies, Department of Rheumatology, University Teaching Hospital, F-25030 Besançon, France

Correspondence to: Professor D Wendling, daniel.wendling@ufc-chu.univ-fcomte.fr

Accepted 6 March 2005

## REFERENCES

- Jain A, Maini R, Nanchahal J. Disease modifying treatment and elective surgery in rheumatoid arthritis: the need for more data. *Ann Rheum Dis* 2004;63:602–3.
- Ellerin T, Rubin RH, Weinblatt ME. Infections and anti-tumor necrosis factor alpha therapy. *Arthritis Rheum* 2003;48:3013–22.
- Rosandich PA, Kelley JT, Conn DL. Perioperative management of patients with rheumatoid arthritis in the era of biologic response modifiers. *Curr Opin Rheumatol* 2004;16:192–8.

- 4 Sany J, Anaya JM, Canovas F, Combe B, Jorgensen C, Saker S, et al. Influence of methotrexate on the frequency of postoperative infectious complications in patients with rheumatoid arthritis. *J Rheumatol* 1993;20:1129–32.
- 5 Marchal L, D'Haens G, Van Assche G, Vermeire S, Noman M, Ferrante M, et al. The risk of post-operative complications associated with infliximab therapy for Crohn's disease: a controlled cohort study. *Aliment Pharmacol Ther* 2004;19:749–54.
- 6 Bibbo C, Goldberg JW. Infectious and healing complications after elective orthopaedic foot and ankle surgery during tumor necrosis factor-alpha inhibition therapy. *Foot Ankle Int* 2004;25:331–5.
- 7 Lipsky PE, Van der Heijde DM, St Clair EW, Furst DE, Breedveld FC, Kalden JR, et al. Infliximab and methotrexate in the treatment of rheumatoid arthritis. Anti-tumor necrosis factor trial in rheumatoid arthritis with concomitant study group. *N Engl J Med* 2000;343:1594–602.
- 8 Hanauer SB, Feagan BG, Lichtenstein GR, Mayer LF, Schreiber S, Colombel JF, et al. Maintenance infliximab for Crohn's disease: the ACCENT 1 randomised trial. *Lancet* 2002;359:1541–9.
- 9 Kroesen S, Widmer AF, Tyndall A, Hasler P. Serious bacterial infections in patients with rheumatoid arthritis under anti-TNF-alpha therapy. *Rheumatology (Oxford)* 2003;42:617–21.
- 10 Giles JT, Gelber AC, Nanda S, Bartlett SJ, Bathon JM. TNF inhibitor therapy increases the risk of post operative orthopaedic infection in patients with rheumatoid arthritis [abstract]. *Arthritis Rheum* 2004;50(suppl):S660.

## Increase in methotrexate dose in patients with rheumatoid arthritis who have an inadequate response to infliximab

P Ornetti, E Solau, P Gaudin, J Sibilia, J-M Berthelot, X Puechal, C Tavernier, J F Maillefert, on behalf of the "Club Rhumatismes et Inflammation", from the French Society of Rheumatology

*Ann Rheum Dis* 2005;64:1379–1380. doi: 10.1136/ard.2004.035030

The strategy needed for patients with inadequate response to treatment with infliximab and methotrexate (MTX) is not well defined. It has been suggested that an increase in the infliximab dosage, a shortening of the intervals between infusions, or a switch to another anti-tumour necrosis factor  $\alpha$  agent might provide clinical benefit.<sup>1–4</sup> Another, less expensive, strategy might be to increase the MTX weekly dose in patients not co-treated with MTX at the maximal dose. This study aimed at evaluating the efficacy of increasing the MTX dose in patients with rheumatoid arthritis (RA) with active disease despite treatment with infliximab and MTX.

### METHODS AND RESULTS

Data were obtained from six rheumatology departments that measure the 28 joint count Disease Activity Score (DAS28) before each infliximab infusion. All patients with RA with active disease (DAS28  $\geq 3.2$ ), despite treatment with a stable regimen of infliximab (3 mg/kg at 0, 2, 6 weeks, thereafter every 8 weeks) and MTX, in whom the MTX weekly dose was increased in order to obtain a better disease control, were included. The exclusion criteria were a change in corticosteroid daily dose or in infliximab regimen at the time of the change of MTX dose, or during the 16 weeks following. The DAS28 scores obtained at the first and second infusion after the change in MTX dose were compared with those obtained before the change (Wilcoxon paired test), and the percentages of responders (EULAR criteria) at the first and second infliximab infusion after the adjustment in MTX dosage were obtained.

A total of 22 patients with RA were included (15 female and 7 male, mean (SD) age 47 (9.1) years, mean (SD) disease duration 7.3 (3.9) years). At the time of adjustment of MTX dosage, patients had been treated with MTX and infliximab for a mean (SD) of 7.6 (6.4) months. The mean (SD) MTX weekly dose was increased from 9.9 (3.9) mg to a mean of 15 (4.3) mg because of primary (n = 8), or secondary infliximab treatment failure (n = 7) or because the response was judged to be insufficient (n = 7). The change was tolerated well in all patients. The DAS28 scores decreased significantly after the MTX dose adjustment (table 1). Five (23%) patients were considered as responders at 8 weeks (four moderate and one good response) and eight (36%) at 16 weeks (seven moderate

and one good response) (fig 1). However, according to the EULAR criteria, 21 (95%) of the patients presented with active disease (DAS28  $\geq 3.2$ ) 16 weeks after the adjustment, and a disease remission (DAS28  $\leq 2.6$ ) was never observed.

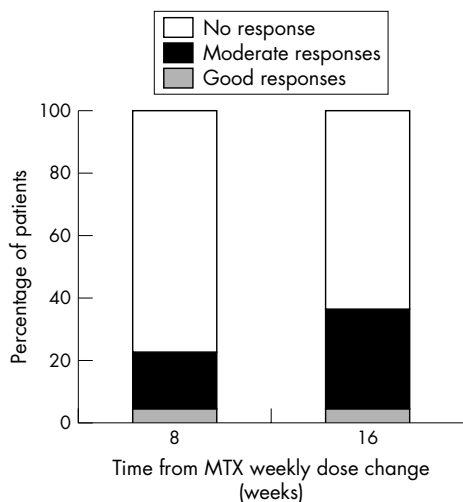
### DISCUSSION

These results might be regarded as disappointing: the mean disease activity showed only modest improvements, and the disease remained active in most patients. However, a response was observed in more than a third of the patients, a percentage which cannot be considered as anecdotal. This study was an observational cohort study, so it cannot be claimed that an increase in MTX dose is useful in patients with active disease despite infliximab treatment, because two main hypotheses can be put forward for explanation: (a) the increase in the MTX dose induces a clinical response in a relevant number of patients; (b) the observed results are due to a regression to the mean effect; adjustment in the MTX dose is likely to be proposed when disease activity increases, so the observed improvement in disease activity might have occurred without a change in the MTX dose. Such a hypothesis was recently proposed to explain the improvement observed after infliximab dose escalation.<sup>5</sup>

**Table 1** Disease activity before, and at the first (8 weeks) and second (16 weeks) infliximab infusion after MTX dose adjustment

	Before adjustment	After adjustment	
		First infliximab infusion	Second infliximab infusion
MTX dose (mg/weekly)	9.9 (3.9)	15 (4.3)	15 (4.3)
DAS28	5.2 (0.8)	4.7 (1.1)*	4.5 (0.9)**
Tender joint count (/28)	10.2 (7)	7.7 (7)*	7.4 (7)*
Swollen joint count (/28)	5.2 (4)	4.8 (4)	3.7 (4)
ESR (mm/ 1st h)	32.1 (21)	28.9 (17)	27.2 (17)
Patient global assessment (/100)	52.2 (17)	44 (23)	42 (18)*

Results are shown as mean (SD).  
\*p<0.05; \*\*p<0.01.



**Figure 1** percentage of patients with good and moderate response (EULAR criteria) 8 and 16 weeks after an increase in the MTX weekly dose.

Further prospective studies are needed to determine the precise strategy to be used in patients with active RA despite infliximab treatment. While waiting for these, an increase in the MTX dose might be an inexpensive but well tolerated strategy which might be used as a first therapeutic option, or in combination with other changes in treatment for patients not treated with MTX at a maximal dose.

#### Authors' affiliations

**P Ornetti, C Tavernier, J F Maillefert**, Department of Rheumatology, Dijon University Hospital, Dijon, France  
**E Solau**, Department of Rheumatology, Lille University Hospital, Lille, France  
**P Gaudin**, Department of Rheumatology, Grenoble University Hospital, Grenoble, France  
**J Sibilis**, Department of Rheumatology, Strasbourg University Hospital, Strasbourg, France  
**J-M Berthelot**, Department of Rheumatology, Nantes University Hospital, Nantes, France  
**X Puechal**, Department of Rheumatology, le Mans Hospital, le Mans, France

Correspondence to: Dr J F Maillefert, Department of Rheumatology, Hôpital Général, 3 rue du Faubourg Raines, 21000 Dijon, France; jean-francis.maillefert@chu-dijon.fr

Accepted 2 January 2005

#### REFERENCES

- Sidiropoulos P**, Bertias G, Kritikos HD, Kouroumalis H, Voudouris K, Boumpas DT. Infliximab treatment for rheumatoid arthritis, with dose titration based on the Disease Activity Score: dose adjustments are common but not always sufficient to assure sustained benefit. *Ann Rheum Dis* 2004;**63**:144–8.
- Haraoui B**. Is there a rationale for switching from one anti-tumor necrosis factor agent to another? *J Rheumatol* 2004;**31**:1021–2.
- Favalli EG**, Arreghini M, Arnoldi C, Panni B, Marchesoni A, Tosi S, *et al*. Anti-tumor necrosis factor alpha switching in rheumatoid arthritis and juvenile chronic arthritis. *Arthritis Rheum* 2004;**51**:301–2.
- Stern R**, Wolfe F. Infliximab dose and clinical status: results of 2 studies in 1642 patients with rheumatoid arthritis. *J Rheumatol* 2004;**31**:1538–45.
- Van Vollenhoven RF**, Brannemark S, Klareskog L. Dose escalation of infliximab in clinical practice: improvements seen may be explained by a regression-like effect. *Ann Rheum Dis* 2004;**63**:426–30.

## The T348M mutated form of cryopyrin is associated with defective lipopolysaccharide-induced interleukin 10 production in CINCA syndrome

T Bihl, E Vassina, M K Boettger, R Goldbach-Mansky, M Seitz, P M Villiger, H U Simon

*Ann Rheum Dis* 2005;**64**:1380–1381. doi: 10.1136/ard.2004.031179

The term autoinflammatory disease has been proposed to describe a group of disorders characterised by attacks of seemingly unprovoked inflammation without increased levels of autoantibodies or increased numbers of autoreactive T cells. Such inflammatory conditions are often associated with mutations of genes of the pyrin superfamily. For instance, mutations in cryopyrin (CIAS1, NALP3, PYPAF1) have been found in about 50% of patients with CINCA syndrome.<sup>1</sup> These patients are characterised by neonatal onset of cutaneous symptoms, chronic meningitis, and joint manifestations with recurrent fever and inflammation. Despite the description of several mutations within the cryopyrin gene,<sup>1, 2</sup> it remains unclear how the resulting amino acid changes modify the function of this protein and why inflammation develops under these conditions. A recent study demonstrated increased spontaneous interleukin (IL) 1 production by macrophages expressing the R260W mutated form of cryopyrin.<sup>3</sup>

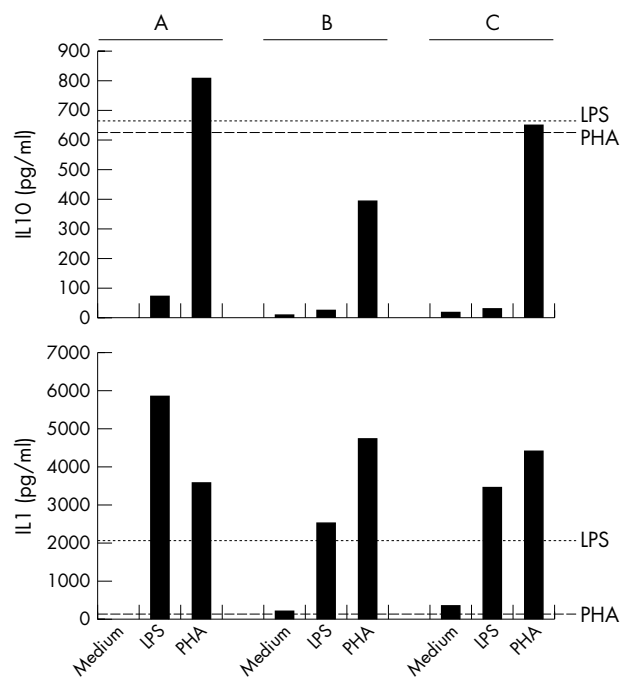
#### METHODS AND RESULTS

We identified a patient with CINCA syndrome who had a T348M mutation of the cryopyrin gene using genomic DNA

extracted from whole blood, as described previously.<sup>1</sup> Because cryopyrin is largely expressed in monocytes and neutrophils, we performed functional in vitro tests using blood leucocytes of this patient (table 1) at three time points: A. medium inflammatory activity ( $9.59 \times 10^9$  blood neutrophils/l); B. high inflammatory activity ( $14.950 \times 10^9$ /l); and C. low

**Table 1** Patient characteristics

41 year old man
Periodic fever and a generalised maculopapular itching erythematous rash since the age of about 8 months
Arthralgia and arthritis with transient swelling beginning in the first year of life
Perceptive deafness beginning after about 30 years
Suffering from abdominal pain and persistent haemorrhagic diarrhoea with increasing age
No increased levels of autoimmune antibodies
Skin histology: cellular infiltrate mainly containing neutrophils
Cranial MRI: internal hydrocephalus and empty sella
Lumbar puncture: sterile chronic meningitis
No growth or mental retardation



**Figure 1** T348M cryopyrin-expressing PBMCs generated IL1 but not IL10 upon LPS stimulation. The same cells, however, produced IL10 after PHA stimulation (for culture conditions, see text). The lack of IL10 production after LPS stimulation did not appear to be dependent on the inflammatory condition of the patient (time points A, B, and C, see text). T348M cryopyrin-expressing PBMCs, but not normal PBMCs, generate large amounts of IL1 upon PHA stimulation. The horizontal dashed lines represent the mean cytokine levels generated by normal PBMCs after stimulation with LPS and PHA ( $n=4$ ; means (SEM) were as follows: LPS-induced IL10: 666 (142) pg/ml; PHA-induced IL10: 621 (157) pg/ml; LPS-induced IL1: 2108 (521) pg/ml; PHA-induced IL1: 40 (29) pg/ml).

inflammatory activity ( $5.47 \times 10^9/l$ ). The patient did not receive immunosuppressive drug treatment except at time point C (300 mg infliximab).

Earlier work suggested a defect in apoptosis mechanisms associated with mutations of the cryopyrin gene.<sup>1</sup> We excluded an intrinsic defect of spontaneous neutrophil apoptosis associated with the T348M mutation using methods previously described (data not shown).<sup>4,5</sup> We then tested the production of cytokines of peripheral blood mononuclear cells (PBMCs,  $1 \times 10^6/ml$ ) after phytohemagglutinin (PHA, 10  $\mu g/ml$ ) and lipopolysaccharide (LPS, 10 ng/ml) stimulation (24 hour cultures, 96 well plates, triplicate cultures).<sup>6</sup> Cytokines were measured in the PBMC culture supernatants using a Cytometric Bead Array Assay (BD Biosciences), according to the manufacturer's instructions. In normal PBMCs both stimuli induced high levels of IL10 (fig 1). In contrast, only PHA but not LPS induced significant levels of IL10 in T348M cryopyrin-expressing PBMC. The defect in LPS-induced IL10 production was not dependent on the inflammatory condition of the patient. Taken together, these data suggest that LPS-mediated but not PHA-mediated IL10 production requires functionally active cryopyrin.

The defect in LPS-induced IL10 production was associated with a particularly high susceptibility to generate IL1 after PHA activation (fig 1). Normal PBMCs did not generate significant amounts of IL1 in this system. Moreover, and in contrast with R260W macrophages,<sup>3</sup> T348M PBMCs

demonstrated no, or only marginal, IL1 production in the absence of stimulation. Thus, it is likely that increased IL1 generation particularly occurs after T cell activation, which may result from defective tolerance mechanisms due to decreased IL10 generation upon exposure to microbial antigens, in our patient. Based on these data, we successfully treated our patient with an IL1 receptor antagonist (data not shown). Similarly, IL1 antagonism proved to be useful in two patients with the R260W cryopyrin variant.<sup>7</sup>

## DISCUSSION

As far as we know, this is the first study providing direct evidence that microbial antigens may trigger an abnormal inflammatory response in an autoinflammatory disease. In contrast, a primary defect of apoptosis, which has been suggested in earlier studies, was, at least in T348M cryopyrin-expressing neutrophils, not seen. Additional investigations should be performed that examine the functional consequences of other known mutations in the genes of the pyrin superfamily. Moreover, further work is required to define the exact hierarchy of signalling events after LPS stimulation to define the place of cryopyrin in this pathway, including its distal molecular targets.

## ACKNOWLEDGEMENTS

We are indebted to the participating patient and to Evelyne Kozłowski (Department of Pharmacology, University of Bern), who provided excellent technical support. This work was supported by grants from the Swiss National Science Foundation (grant No 310000-107526) and the OPO-Foundation, Zurich, Switzerland.

## Authors' affiliations

**T Bihl, M K Boettger, M Seitz, P M Villiger**, Department of Rheumatology/Clinical Immunology/Allergy, Inselspital, University of Bern, Bern, Switzerland  
**E Vassina, H U Simon**, Department of Pharmacology, University of Bern, Bern, Switzerland  
**R Goldbach-Mansky**, National Institute of Arthritis and Musculoskeletal and Skin Diseases, NIH, Bethesda, MD, USA

Correspondence to: Professor H U Simon, Department of Pharmacology, University of Bern, Friedbuehlstrasse 49, CH-3010 Bern, Switzerland; hus@pki.unibe.ch

Accepted 30 January 2005

## REFERENCES

- Aksentijevich I**, Nowak M, Mallah M, Chae JJ, Waiford WT, Hofmann SR, *et al*. De novo CIAS1 mutations, cytokine activation, and evidence for genetic heterogeneity in patients with neonatal-onset multisystem inflammatory disease (NOMID). *Arthritis Rheum* 2002;**46**:3340–8.
- Neven B**, Callebaut I, Prieur AM, Feldmann J, Bodemer C, Lepore L, *et al*. Molecular basis of the spectral expression of CIAS1 mutations associated with phagocytic cell-mediated autoinflammatory disorders CINCA/NOMID. *Blood* 2004;**103**:2809–15.
- Agostini L**, Martinon F, Burns K, McDermott MF, Hawkins PN, Tschopp J. NALP3 forms an IL-1 $\beta$ -processing inflammasome with increased activity in Muckle-Wells autoinflammatory disorder. *Immunity* 2004;**20**:319–25.
- Altzner F**, Conus S, Cavalli A, Folkers G, Simon HU. Calpain-1 regulates Bax and subsequent Smac-dependent caspase-3 activation in neutrophil apoptosis. *J Biol Chem* 2004;**279**:5947–57.
- Altzner F**, Martinelli S, Yousefi S, Thürig C, Schmid I, Conway EM, *et al*. Inflammation-associated cell cycle-independent block of apoptosis by survivin in terminally differentiated neutrophils. *J Exp Med* 2004;**199**:1343–54.
- Plötz SG**, Simon HU, Darsow U, Simon D, Vassina E, Yousefi S, *et al*. Use of an anti-interleukin-5 antibody in the hypereosinophilic syndrome with eosinophilic dermatitis. *N Engl J Med* 2003;**349**:2334–9.
- Hawkins PN**, Lachmann HJ, McDermott MF. Interleukin-1-receptor antagonist in the Muckle-Wells syndrome. *N Engl J Med* 2003;**348**:2583–4.

# Churg-Strauss vasculitis syndrome and leukotriene receptor antagonists

J Ng, R Savage, F McQueen

*Ann Rheum Dis* 2005;64:1382. doi: 10.1136/ard.2004.034272

A 28 year old Middle Eastern woman presented to hospital with shortness of breath and new onset numbness of her foot. Five years previously, in Iraq, she had been diagnosed with severe brittle asthma and sinusitis. After 2 years of management with oral (up to 15 mg prednisone) and inhaled steroid, zafirlukast, a leukotriene receptor antagonist (LRA) was added to her treatment regimen. Despite this, her asthma remained poorly controlled and zafirlukast was stopped after 12 months. Subsequent clinical improvement allowed the prednisone dose to be tapered and then stabilised at 7.5 mg/day. By the time she migrated to New Zealand she had been receiving that dose for 1 year.

At presentation to Auckland City Hospital she was clinically in left ventricular failure with a raised jugular venous pressure. Neurological examination disclosed features of a common peroneal nerve palsy, presumed to be a manifestation of mononeuritis multiplex. Investigations showed a leucocytosis with extreme eosinophilia (white cell count  $28.3 \times 10^9/l$ , eosinophils  $13.3 \times 10^9/l$ ) and erythrocyte sedimentation rate of 40 mm/1st h. Renal function and liver function were normal. Troponin T was raised at 0.64 µg/l (normal <0.03 µg/l), indicating myocyte injury. She was antineutrophil cytoplasmic antibody and antinuclear antibody negative. There was moderate left ventricular impairment on echocardiogram, with an ejection fraction of 45% and a small pericardial effusion. Chest radiography showed cardiomegaly and a fine nodular pattern at the lung bases, which resolved after starting treatment. Attempts to confirm vasculitis on sural nerve and muscle biopsies were unsuccessful.

This patient fulfilled American College of Rheumatology criteria for a diagnosis of Churg-Strauss syndrome (CSS).<sup>1</sup> As there was evidence of cardiac injury, she scored 1 on the five factors score.<sup>2</sup>

She was treated with prednisone initially at 1 mg/kg (later tapered to 15 mg/day) and given monthly pulse cyclophosphamide at 0.5 mg/m<sup>2</sup>, to continue for 12 months according to the protocol proposed by Guillevin and Pagnoux.<sup>3</sup> She has responded well symptomatically with normalisation of the eosinophil count and erythrocyte sedimentation rate. On echocardiography, the ejection fraction remains unchanged but the pericardial effusion has resolved.

## DISCUSSION

Our patient's experience raises several interesting points. To our knowledge, this is the first case reported in Australasia of CSS occurring in a patient who had received LRA treatment. A possible causal association between the use of zafirlukast and CSS was first suggested in 1998.<sup>4</sup> The New Zealand Intensive Medicines Monitoring Programme has prospectively monitored adverse events in 1535 patients who received prescriptions for montelukast from 1999 to the present.<sup>5</sup> Forty three adverse events were considered associated with montelukast, but these did not include CSS or

related features. The annual incidence of CSS in patients with asthma has been estimated at 64.4 per million patients.<sup>6</sup> Thus, any link between montelukast and CSS may not have been detected owing to the small size of the cohort as LRA have not been widely used in New Zealand.

In most reports of CSS occurring in patients receiving LRA, extrapulmonary vasculitic features have developed after steroid reduction.<sup>7,8</sup> It has been proposed that this may be because vasculitis has been "unmasked" by reduction of previously suppressive doses of steroid.<sup>7</sup> This would not apply in our patient as she developed features of CSS after receiving a stable dose of 7.5 mg of prednisone for 12 months.

Other explanations for the association between treatment with an LRA and CSS in this patient include the possibility that zafirlukast has an immunomodulatory role in promoting the development of vasculitis directly (albeit some time later), as has been suggested by Guilpain *et al.*<sup>9</sup> Alternatively, the association may have been purely coincidental, and the fact that zafirlukast was stopped 18 months before presentation with CSS makes it harder to implicate the drug in disease pathogenesis in this case.

## Authors' affiliations

J Ng, R Savage, F McQueen, Department of Rheumatology, Auckland District Health Board, Auckland, New Zealand and the Centre for Pharmacovigilance, Dunedin School of Medicine, University of Otago, New Zealand

Correspondence to: Dr F McQueen, Department of Rheumatology, Building 7, Auckland Hospital, Private Bag 92024, Auckland, New Zealand; f.mcqueen@auckland.ac.nz

Accepted 17 February 2005

## REFERENCES

- Masi AT, Hunder GG, Lie JT, Michel BA, Bloch DA, Arend WP, *et al.* The American Rheumatology criteria 1990 for the classification of Churg-Strauss syndrome. *Arthritis Rheum* 1990;33:1094.
- Guillevin L, Lhote F, Gayraud M, Cohen P, Jarrousse B, Lortholary O, *et al.* Prognostic factors in polyarteritis nodosa and Churg-Strauss syndrome: a prospective study in 342 patients. *Medicine (Baltimore)* 1996;75:17-28.
- Guillevin L, Pagnoux C. When should immunosuppressants be prescribed to treat systemic vasculitides? *Intern Med* 2003;42:313-17.
- Wechsler ME, Garpestad E, Flier SR, Kacher O, Weiland DA, Polito AJ, *et al.* Pulmonary infiltrates, eosinophilia, and cardiomyopathy following corticosteroid withdrawal in patients with asthma receiving zafirlukast. *JAMA* 1998;279:455-7.
- Coulter D. Pro-active safety surveillance. *Pharmacoepidemiol Drug Safety*. 2000; 9:273-80).
- Noth I, Strek ME, Leff AR. Churg Strauss syndrome. *Seminars. Lancet* 2003;361:587-94.
- Wechsler ME, Finn D, Gunawardena D, Westlake R, Barker A, Haranath SP, *et al.* Churg Strauss syndrome in patients receiving montelukast as treatment for asthma. *Chest* 2000;117:708-13.
- Weller PF, Plant M, Taggart V, Trentell A. The relationship of asthma therapy and Churg-Strauss Syndrome: NIH workshop summary report. *J Allergy Clin Immunol* 2001;108:175-83.
- Guilpain P, Viillard JF, Lagarde P, Cohen P, Kambouchner M, Pellegrin JL, *et al.* Churg-Strauss syndrome in two patients receiving montelukast. *Rheumatology (Oxford)* 2002;41:535-9.

# A major subset of patients with ankylosing spondylitis followed up in tertiary clinical care require anti-tumour necrosis factor $\alpha$ biological treatments according to the current guidelines

M Temel, P Atagündüz, H Direskeneli

*Ann Rheum Dis* 2005;64:1383–1384. doi: 10.1136/ard.2004.028423

**T**herapeutic options for severe ankylosing spondylitis (AS) have been limited to non-steroidal anti-inflammatory drugs (NSAIDs), corticosteroids, and to some traditional disease modifying drugs (DMARDs) such as sulfasalazine and methotrexate. In view of open label and controlled trials of treatment with a monoclonal chimeric tumour necrosis factor (TNF)  $\alpha$  antibody (infliximab), and with recombinant human TNF receptor (etanercept), the need for more effective second line treatments in AS seems to be met.<sup>1–4</sup>

In this study we aimed at determining the proportion of patients with active AS, despite treatment with NSAIDs and second line treatments (sulfasalazine, methotrexate), using current guidelines for anti-TNF treatment in a tertiary clinical care.

## METHODS AND RESULTS

Study patients were selected according to the Modified New York criteria. ASAS and SPARTAN guidelines for biological treatments of AS were used.<sup>5–6</sup> Ninety three patients with AS (M/F = 46/47, mean (SD) age 39.5 (11.5) years, mean (SD) disease duration 13.7 (10.5) years) were screened. The University of Marmara Institutional review board approved the study and informed consent was given by the study patients.

Eighty patients (86%) were receiving NSAIDs: 67/93 (72%) sulfasalazine and 32/93 (34%) methotrexate. Disease duration, age, disease activity defined by the Bath AS Disease Activity Index (BASDAI), and drugs used did not differ significantly between male and female patients. Of the 93 patients, 32 (34%; M/F = 17/15) and 37 patients (40%; M/F = 18/19) were defined as having active AS according to SPARTAN and ASAS guidelines, respectively.

Although high mean C reactive protein (CRP) values are considered critical in defining active AS, the higher mean CRP values detected in the male patients (male *v* female mean CRP, 259 *v* 69 mg/l, *p* = 0.054) did not correlate with the ratio of men and women considered to have active AS (ASAS = 18M/19F, SPARTAN = 17M/15F). Higher CRP values in this group correlated negatively with the use of sulfasalazine (*r* = -0.764, *p* = 0.05).

## DISCUSSION

Our study showed that a significant number of patients had active AS (34–40%) in our patient tertiary care clinic. A recent study reflects the same need for effective treatment in AS, though that study had a higher proportion of patients with active AS (65%).<sup>7</sup> In that study, NSAIDs were used as the first line treatment option and use of sulfasalazine and methotrexate was limited. We used combined methotrexate with sulfasalazine for persistent peripheral arthritis, which might have had modifying effects on disease activity in our study group, despite a lack of evidence that conventional DMARDs

alter the course of established axial disease, and might explain the differences between the two studies.

According to current diagnostic criteria, patients with AS must have *x* ray changes for the diagnosis, which take months to years to establish. Two separate studies from Europe emphasise that a substantial period of active disease was already present before the diagnosis.<sup>8–9</sup> As we now know, treatment with biological agents improves the signs and symptoms of axial disease in AS where traditional DMARDs fail.<sup>1–4</sup> Starting DMARDs at an earlier stage of AS after the diagnosis might provide a chance to assess the effect of conventional treatment in patients with shorter disease duration and enable use of anti-TNF treatment for patients with refractory disease before the radiographic signs of established disease occur.

In a similar study of rheumatoid arthritis<sup>10</sup> the eligibility of patients receiving routine care to receive treatment with TNF $\alpha$  agents, according to the inclusion criteria of the studies for biological agents, was also low (prevalence of 8%). However, current criteria for defining patients with active AS eligible for anti-TNF treatment, and patient selection criteria of major clinical trials with biological agents, do parallel each other, suggesting that current guidelines for selecting patients with active AS are suitable for routine clinical care.

In conclusion, a significant subset of the patients with AS followed up in our tertiary care clinic require more effective treatment according to current guidelines despite intensive conventional second line treatment.

## Authors' affiliations

M Temel, P Atagündüz, H Direskeneli, Department of Rheumatology, Marmara University Medical Faculty, Istanbul, Turkey

Correspondence to: Dr H Direskeneli, Division of Rheumatology, Marmara Medical School Hospital, Tophanelioglu Cad. 13/15, 81190, Altunizade, Istanbul, Turkey; direskeneli@superonline.com

Accepted 30 January 2005

## REFERENCES

- Braun J, Brandt J, Listing J, Zink A, Alten R, Burmester G, *et al*. Long-term efficacy and safety of infliximab in the treatment of ankylosing spondylitis: an open, observational, extension study of a three-month, randomized, placebo-controlled trial. *Arthritis Rheum* 2003;48:2224–33.
- Braun J, Brandt J, Listing J, Zink A, Alten R, Golder W, *et al*. Treatment of active ankylosing spondylitis with infliximab: a randomized controlled multicenter trial. *Lancet* 2002;359:1187–93.
- Van der Heijde D, Dijkmans B, Geusens P, Sieper J, DeWoody K, Williamson P, *et al*. Ankylosing Spondylitis Study for the Evaluation of Recombinant Infliximab Therapy Study Group. Efficacy and safety of a Infliximab in patients with ankylosing spondylitis: results of randomized, placebo controlled trial (ASSERT). *Arthritis Rheum* 2005;52:582–91.
- Davis JC, van der Heijde D, Braun J, Dougados M, Cush J, Clegg DO, *et al*. Recombinant human tumor necrosis factor receptor (etanercept) for treating ankylosing spondylitis. *Arthritis Rheum* 2003;48:3230–6.

- 5 Braun J, Pham T, Sieper J, Davis J, van der Linden S, Dougados M, *et al*. ASAS consensus statement for the use of anti-tumor necrosis factor agents in patients with ankylosing spondylitis. *Ann Rheum Dis* 2003;**62**:817–24.
- 6 [http://www.spondylitis.org/physician\\_resources/guidelines.aspx](http://www.spondylitis.org/physician_resources/guidelines.aspx), accessed 3 July 2005.
- 7 Barkham N, Kong KO, Fraser A, Tennant A, Emery P. The unmet need for effective therapy in ankylosing spondylitis. *Arthritis Rheum*. 2003;**48**: S175, abstr 360, (suppl).
- 8 Zink A, Listing J, Klindworth C, Zeidler H. German Collaborative Arthritis Centres. The national database of the German Collaborative Arthritis Centres: Structure, aims, and patients. *Ann Rheum Dis* 2001;**60**:199–206.
- 9 Boonen A, van der Heijde D, Landewe R, Spoorenberg A, Schouten H, Rutten-van Molken M, *et al*. Work status and productivity costs due to ankylosing spondylitis: comparison of three European countries. *Ann Rheum Dis* 2002;**61**:429–37.
- 10 Sokka T, Pincus T. Eligibility of patients in routine care for major clinical trials of anti-tumor necrosis factor- $\alpha$  agents in rheumatoid arthritis. *Arthritis Rheum* 2003;**48**:313–18.

## Colchicine responsive periodic fever syndrome associated with pyrin I591T

B A C Fisher, H J Lachmann, D Rowczenio, H J B Goodman, S Bhalara, P N Hawkins

*Ann Rheum Dis* 2005;**64**:1384–1385. doi: 10.1136/ard.2004.030379

Familial Mediterranean fever (FMF) is a recessively inherited disorder characterised by recurrent attacks of fever and serositis that usually begin in childhood, last for fewer than 3 days, and which can largely be prevented by colchicine prophylaxis. Identification of the gene associated with FMF, *MEFV*, has facilitated genotype:phenotype studies, and we report here on a patient with a little described exon 9 mutation associated with an atypical inflammatory syndrome.

### CASE REPORT

A 56 year old white French woman presented with normochromic anaemia, haemoglobin 61 g/l, and recent onset fatigue and headaches. Extensive investigations including upper and lower gastrointestinal endoscopy, autoantibody screens, bone marrow examination, and whole body computed tomography proved normal. There was no family history of note or consanguinity.

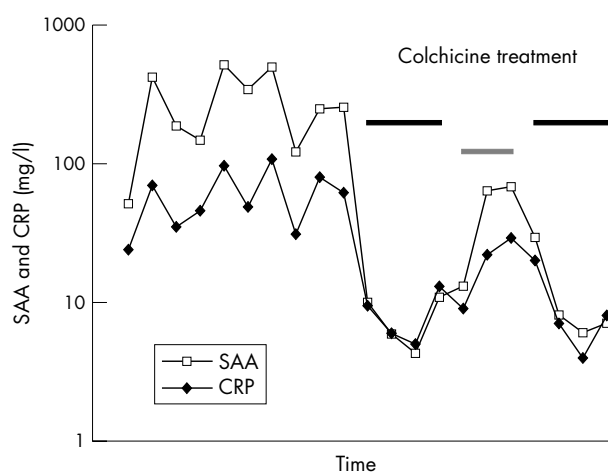
Over the following 9 years her symptoms—comprising pyrexia, headache, and drenching night sweats—intensified, occurring about every fourth day and lasting for 24 hours. She required intermittent blood transfusions and her erythrocyte sedimentation rate remained markedly raised. Repeat bone marrow, echocardiogram, radiolabelled white cell scan, and computed tomographic imaging were normal. An investigation for infectious disease was non-diagnostic and a trial of prednisolone ineffective.

The possibility of atypical FMF was considered and was supported by complete resolution of symptoms after the introduction of colchicine 1 mg daily. Before treatment, her median serum amyloid A protein was 338 mg/l and C reactive protein 56 mg/l. Both markers were in the healthy range of <10 mg/l with colchicine (fig 1).

Sequencing of *MEFV* showed a single exon 9 mutation, encoding pyrin I591T; no mutations were found in exons 2, 3, 5, or 10. The *TNFRSF1A* gene, associated with TRAPS (tumour necrosis factor receptor associated periodic fever syndrome) was wild type. A reduction in colchicine to 0.5 mg/day led to recurrence of symptoms and acute phase response, which resolved when the dose was increased. She remains well and has a normal haemoglobin at 12 months' follow up.

### DISCUSSION

FMF is an inherited inflammatory disorder predominantly affecting people of the Mediterranean littoral, but which has been described in many populations.<sup>1</sup> The gene associated with FMF, *MEFV*, was cloned in 1997 and comprises 10 exons.<sup>1</sup> Forty eight mutations associated with FMF have been reported, just



**Figure 1** Our patient's acute phase response, plotted on a logarithmic scale, and the effect of colchicine treatment. Her chronic inflammatory activity responded to colchicine 1 mg/day, partially relapsed with 0.5 mg/day, and subsided again when the dose was increased again to 1 mg/day.

five of which are associated with 70–80% of cases.<sup>2</sup> Although finding a mutation in each *MEFV* allele corroborates a diagnosis of FMF, the sensitivity and specificity of DNA analysis are hampered by reduced penetrance, and by the fact that only a single mutation can be identified in up to 20% of patients with classical FMF.<sup>3–5</sup> This suggests that certain people may be especially susceptible to a single *MEFV* mutation, or that other as yet unidentified genes can contribute to the pathogenesis of the disease. The diagnosis of FMF therefore remains clinical, and the Tel Hashomer criteria are well validated for this purpose.<sup>6–7</sup>

Pyrin I591T was first reported in 2001 with no accompanying clinical data.<sup>8</sup> A Spanish kindred was subsequently described, in which three siblings were compound heterozygotes for pyrin I591T and M694I, the latter a recognised variant causing FMF.<sup>9</sup> Only one subject was symptomatic, and the contribution from I591T was therefore unclear. However, a pathogenic role for pyrin I591T in our patient is supported because she fulfilled diagnostic criteria for probable FMF, had attacks of characteristically short duration which responded to colchicine, and we only identified this mutation in one other case among our large referral practice, in a patient with classical FMF who had a second *MEFV* mutation, M694V. Furthermore, the absence of serositis and a late onset of symptoms have all been described in FMF.<sup>10</sup>

This case illustrates the usefulness of a therapeutic trial of colchicine monitored objectively by frequent acute phase protein measurements in patients with undiagnosed periodic fever syndromes. It also raises the possibility that a low threshold for analysing the FMF gene might disclose a wider spectrum of associated disease.

#### Authors' affiliations

**B A C Fisher, S Bhalara**, Department of Rheumatology, Watford General Hospital, Vicarage Road, Watford, Herts WD18 0HB, UK

**H J Lachmann, D Rowczenio, H J B Goodman, P N Hawkins**, National Amyloidosis Centre, Department of Medicine, Royal Free and University College Medical School, Rowland Hill Street, London NW3 2PF, UK

Correspondence to: Dr B Fisher, Department of Rheumatology, Charing Cross Hospital, Fulham Palace Road, London W6 8RF, UK; bacfisher@yahoo.com

Accepted 30 January 2005

#### REFERENCES

- 1 Drenth JPH, Van der Meer JWM. Hereditary periodic fever. *N Engl J Med* 2001;**345**:1748–57.

- 2 Shinar Y, Livneh A, Langevitz P, Zaks N, Aksentjevich I, Koziol DE, et al. Genotype-phenotype assessment of common genotypes among patients with familial Mediterranean fever. *J Rheumatol* 2000;**27**:1703–7.
- 3 Paut K, Dubuc M, Sportouch J, Minodier P, Garnier JM, Toutou I. Phenotype-genotype correlation in 91 patients with familial Mediterranean fever reveals a high frequency of cutaneous mucous features. *Rheumatology (Oxford)* 2000;**39**:1275–9.
- 4 Aksentjevich I, Torosyan Y, Samuels J, Centola M, Pras E, Chae JJ, et al. Mutation and haplotype studies in of familial Mediterranean fever reveal new ancestral relationships and evidence for high carrier frequency with reduced penetrance in the Ashkenazi Jewish population. *Am J Hum Genet* 1999;**64**:949–62.
- 5 Yilmaz E, Ozen S, Balci B, Duzova A, Topaloglu R, Besbas N, et al. Mutation frequency of familial Mediterranean fever and evidence for a high carrier rate in the Turkish population. *Eur J Hum Genet* 2001;**9**:553–5.
- 6 Livneh A, Langevitz P. Diagnostic and treatment concerns in familial Mediterranean fever. *Baillieres Best Pract Res Clin Rheumatol* 2000;**14**:477–98.
- 7 Grateau G, Pêcheux C, Cazeneuve C, Cattan D, Derichian M, Goossens M, et al. Clinical versus genetic diagnosis of familial Mediterranean fever. *Q J Med* 2000;**93**:223–9.
- 8 Toutou I. The spectrum of familial Mediterranean fever (FMF) mutations. *Eur J Hum Genet* 2001;**9**:473–83.
- 9 Aldea A, Casademont J, Aróstegui JJ, Rius J, Masó M, Vives J, et al. 1591T MEFV mutation in a Spanish kindred: is it a mild mutation or a variant influenced by another modifier? *Hum Mutat* 2002;**20**:148–50.
- 10 Nir-Paz R, Ben-Chetrit E, Pikarsky E, Hassin D, Hasin Y, Chajek-Shaul T. Unusual presentation of familial Mediterranean fever: role of genetic diagnosis. *Ann Rheum Dis* 2000;**59**:836–8.

## Whale of a tale

**B Rothschild, V Naples**

*Ann Rheum Dis* 2005;**64**:1385–1386. doi: 10.1136/ard.2004.033423

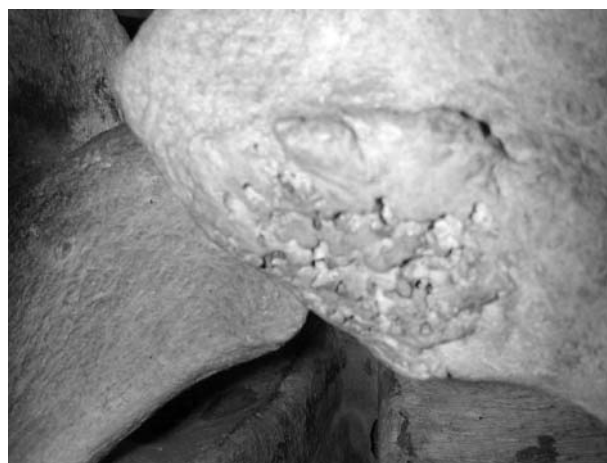Spondyloarthropathy is the term applied to a form of arthritis with sentinel alteration of the spine, in the form of syndesmophytes and zygapophyseal joint erosions.<sup>1–3</sup> Although a single zygapophyseal joint can be damaged by pyogenic or rarely by a granulomatous infection, the only known cause of multiple zygapophyseal joint erosions is spondyloarthropathy,<sup>1,2</sup> as previously documented in the sauropod dinosaur *Camarasaurus*.<sup>4</sup> Species susceptibility to spondyloarthropathy of the reactive arthritis variety has been clearly documented in non-human primates, identical in character, infectious agent involvement, and response to treatment to that found in humans.<sup>5</sup>

Observation of syndesmophytes and zygapophyseal joint fusion in cetacea (for example, dolphins)<sup>6</sup> stimulated a systematic survey of cetacean collections for evidence of spondyloarthropathy. That survey exposed a blue whale (*Balenoptera musculus*) at the American National Museum of Natural History (Washington, DC) (USNM 124326) with erosions of zygapophyseal joints of vertebrae 11–14 (fig 1). This specimen, collected in Newfoundland, Canada by F Leucas, contrasts with another sign of spondyloarthropathy,<sup>1,2,7</sup> sacroiliac joint fusion, present in the mouse-like marsupial *Antechinomys laniger* (common name, kultarr) at the Center for Biodiversity, Illinois Natural History Survey (Champaign, IL) (UIMMH 39301).

The phylogenetic spectrum of spondyloarthropathy is now extended from the largest mammal (weighing up to 190 000 kg) that ever lived to one of the smallest, the latter weighing in at less than a twentieth of a kilogram. With apologies to Walt Disney, A whale of a tale and its all true.

#### ACKNOWLEDGEMENT

Appreciation is expressed for facilitation of collection access by Charles Potter and Jeff Saunders.



**Figure 1** En face view of *Balenoptera musculus* USNM 124326 13th thoracic vertebra before and after zygapophysysis. Photograph taken by VN, a member of the Smithsonian staff, with the assistance of Charles Potter, curator in charge, who provided permission for the study and photography.

#### Authors' affiliations

**B M Rothschild**, Arthritis Center of Northeast Ohio, Youngstown, Ohio 44512, USA; Northeastern Ohio Universities College of Medicine, Rootstown, OH 44527, USA; Carnegie Museum of Natural History, Pittsburgh, PA 15213, USA; University of Kansas Museum of Natural History, Lawrence, KS 66045, USA

**V Naples**, Division of Vertebrate Zoology, USNM, Smithsonian Institution, Washington, DC 20506, USA; Department of Biological Sciences, Northern Illinois University, DeKalb, Illinois 60115, USA

Correspondence to: Professor B Rothschild, Arthritis Center of Northeast Ohio, 5500 Market, Youngstown, OH 44512, USA; bmr@neoucom.edu

Accepted 17 February 2005

## REFERENCES

- 1 Resnick D. *Diagnosis of bone and joint disorders*. Philadelphia: Saunders, 2002.
- 2 Rothschild BM, Martin LD. *Paleopathology: disease in the fossil record*. London: CRC Press, 1993.

- 3 San Zhang C, Rothschild BM. Zygapophyseal and costovertebral/costovertebral joints: an anatomic assessment of arthritis impact. *Br J Rheumatol* 1993;**32**:1066–71.
- 4 Rothschild BM, Helbling M II, Miles C. Origin of spondyloarthritis in the Jurassic. *Lancet* 2002;**360**:1454.
- 5 Neiffer DL, Rothschild BM, Marks SK, Urvater JA, Watkins DI. Management of reactive arthritis in a juvenile gorilla (*Gorilla gorilla gorilla*) with long-term sulfasalazine therapy. *J Zoo Wildlife Med* 2000;**31**:539–51.
- 6 Kompanje EO. Vertebral osteophytosis in cetacea: spondylosis or spondylitis. *Z Säugetierkunde* 1993;**58**:316–18.
- 7 Rothschild BM, Woods RJ. Spondyloarthritis: erosive arthritis in representative defleshed bones. *Amer J Phys Anthropol* 1991;**85**:125–34.

# Paget's hydrocephalus treated with zoledronate

A Morton

*Ann Rheum Dis* 2005;**64**:1386. doi: 10.1136/ard.2004.031302

A case is described of severe untreated polyostotic Paget's disease with severe skull involvement causing hydrocephalus, and its response to treatment with intravenous bisphosphonates is presented.

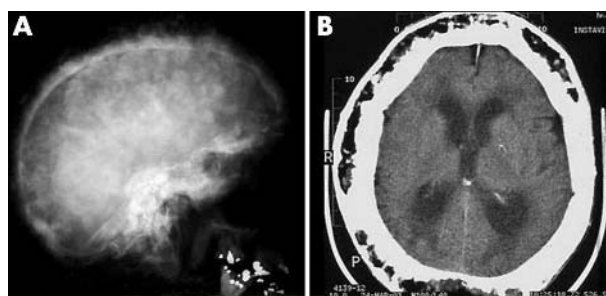
## CASE REPORT

An 86 year old woman presented with a femoral neck fracture as result of a fall. Her daughter gave a 20 year history of progressive deafness and a 6 month history of confusion, ataxia, and urine incontinence in the setting of untreated Paget's disease. Examination disclosed a profoundly deaf woman with whom communication was only possible by writing, typical bony changes of the skull and both tibiae, but no papilloedema or angioid streaks on fundoscopy. A modified mini-mental state examination was 21/30. Serum alkaline phosphatase (AP) was 1477 U/l (normal 30–120). Plain radiography showed severe pagetic changes affecting both hemipelves, femora (including the site of fracture), tibiae, and the skull. Computed tomography scanning of the head showed moderate enlargement of both lateral ventricles and the third ventricle, with the fourth ventricle remaining decompressed, consistent with obstructive hydrocephalus (fig 1).

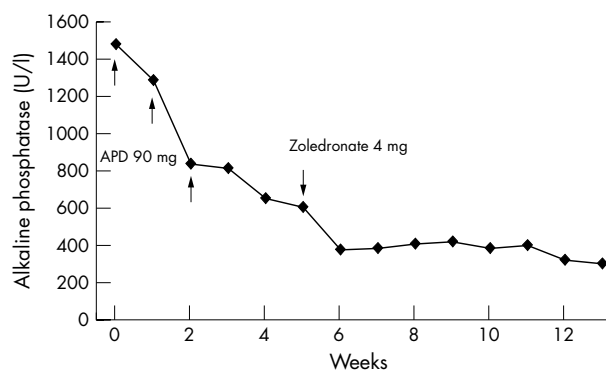
The patient declined orthopaedic intervention, magnetic resonance imaging of the brain, or neurosurgical consultation. In view of the neurological involvement her Paget's disease was treated aggressively with three infusions of 90 mg pamidronate given weekly, and her serum AP fell to 650 U/l 4 weeks after presentation. When the effect of this seemed to be plateauing she was then given 4 mg of zoledronate intravenously (fig 2). Her serum AP fell further to 290 U/l over the next 2 months. Her daughter felt there was improvement in her hearing, but this was not documented objectively with audiometry. Unfortunately, the patient developed sudden respiratory problems and died 4 months after presentation.

## DISCUSSION

Reports of about 20 cases of hydrocephalus complicating Paget's disease have been published. Affected patients presented with ataxia, confusion, urine incontinence, and parkinsonian syndromes, and had relief of their neurological symptoms with ventricular shunting. The use of zoledronate in this case was prompted by the article by Chung and Keen, who reported an excellent response of polyostotic Paget's disease to this drug after variable responses to various bisphosphonates and subsequent resistance to intravenous



**Figure 1** (A) x Ray findings and (B) computed tomography scan of the head.



**Figure 2** Biochemical response to bisphosphonates. APD, pamidronate.

pamidronate.<sup>1</sup> Randomised trials are underway comparing response rates between zoledronate and other bisphosphonates.

No competing interest.

Correspondence to: Dr A Morton, Mater Hospital, Raymond Tce, South Brisbane 4101, Australia; Amorton@mater.org.au

Accepted 7 February 2005

## REFERENCE

- 1 Chung G, Keen RW. Zoledronate treatment in active Paget's disease. *Ann Rheum Dis* 2003;**62**:275–6.

# Oral sildenafil for the treatment of Raynaud's phenomenon and digital ulcers secondary to systemic sclerosis

J Gore, R Silver

*Ann Rheum Dis* 2005;64:1387. doi: 10.1136/ard.2004.034488

Raynaud's phenomenon (RP) with or without digital ulcer formation is a significant cause of morbidity for patients with systemic sclerosis (SSc, scleroderma). Lichtenstein reported oral sildenafil as a treatment of RP for patients with SSc, systemic lupus erythematosus, and idiopathic RP.<sup>1</sup> His report included 10 patients from his community office practice given sildenafil, 50 mg once orally at bedtime.

## METHODS AND RESULTS

We performed a retrospective chart review of 10 patients with SSc seen at a tertiary care referral centre who were offered sildenafil after standard treatments (calcium channel blockers,  $\alpha$  blockers, angiotensin converting enzyme (ACE) inhibitors, aspirin, dipyridamole, pentoxifylline, and/or topical nitrates) had failed. Of the 10 patients, four had limited disease and six had diffuse disease. The mean (SD) age of the patients was 49.9 (9.9) years, and the mean (SD) duration of SSc was 9.5 (6.5) years. The mean (SD) duration of RP was 9.5 (7.5) years. Seven were female and three were male. Eight were white, one was African-American, and one was Hispanic. The starting dose of sildenafil varied among the patients, ranging from 12.5 mg/day to 100 mg/day, in single or divided doses.

Eight of the ten patients treated with sildenafil had a response within a few weeks, with significant reduction in the frequency and severity of RP. Of the eight patients who had digital ulcers refractory to conventional treatment, six experienced complete healing of the ulcers.

One patient, who had recently had a normal coronary arteriogram, did have some chest discomfort after taking the sildenafil. She had taken sildenafil for four months previously without any complaints. Nevertheless, the medicine was discontinued and her chest discomfort resolved. Otherwise, the medicine was well tolerated.

## DISCUSSION

Sildenafil is a phosphodiesterase V inhibitor that allows accumulation of cyclic guanosine monophosphate (cGMP). cGMP causes a decrease in intracellular calcium, and the result is vascular smooth muscle relaxation and dilatation.<sup>2</sup> Perhaps in those patients whose digital ulcers failed to heal while they were receiving sildenafil, the failures were the result of fibrosis and/or occlusion of vessels that did not allow further vasodilatation.

The dose prescribed was limited by the availability of the drug. Four patients were allowed only eight tablets a month and so were prescribed 100 mg tablets that were divided into quarters. This allowed the patients to take the medicine daily, albeit in small doses. We present this experience with patients with SSc with RP and digital ulcers in the hopes that further studies will be carried out to examine this new and potentially effective treatment. Clearly, traditional medical and surgical treatments for severe RP and digital ulceration are not adequate for all patients with SSc.

## Authors' affiliations

J Gore, R Silver, Medical University of South Carolina, Division of Rheumatology, Charleston, South Carolina, USA

Correspondence to: Dr J Gore, Medical University of South Carolina, Division of Rheumatology, 96 Jonathon Lucas Street, Suite 912, PO Box 250623, Charleston, SC 29425, USA; gorej@muscc.edu

Accepted 30 January 2005

## REFERENCES

- 1 Lichtenstein JR. Use of sildenafil citrate in Raynaud's phenomenon: *Arthritis Rheum* 2003;48:282-3.
- 2 Rybalkin S, Yan C, Bornfeldt K, Beavo J. Cyclic GMP phosphodiesterases and regulation of smooth muscle function. *Circ Res* 2003;93:280-91.