



# Diagnostic Value of Diffusion-weighted Imaging and Apparent Diffusion Coefficient Values in the Differentiation of Breast Lesions, Histopathologic Subgroups and Correlation with Prognostic Factors using 3.0 Tesla MR

Yasin Akın<sup>1</sup>, M. Ümit Uğurlu<sup>2</sup>, Handan Kaya<sup>3</sup>, Erkin Arıbal<sup>1</sup>

<sup>1</sup>Department of Radiology, Marmara University School of Medicine, İstanbul, Turkey

<sup>2</sup>Department of General Surgery, Marmara University School of Medicine, İstanbul, Turkey

<sup>3</sup>Department of Pathology, Marmara University School of Medicine, İstanbul, Turkey

## ABSTRACT

**Objective:** The aim of this study was to evaluate the effect of the apparent diffusion coefficient (ADC) and diffusion-weighted imaging in differentiating benign from malignant breast lesions, histopathologic subtypes of breast tumors, and to find a correlation with prognostic factors using 3T MR.

**Materials and Methods:** A total of 165 patients aged between 16 and 78 years with 181 histopathologically-verified breast lesions were enrolled in this study. A 3T MR system and bilateral phased array breast coil was used. Diffusion-weighted imaging was performed with spin echo "echo planar" with "b" values: 50, 400, and 800 seconds/mm<sup>2</sup>. ADC values were calculated for normal fibroglandular tissue and breast lesions. ADC values of independent groups were compared using Student's t-test. ROC analysis was used to find a threshold ADC value in the differentiation of lesions.

**Results:** The mean ADC values were  $1.35 \pm 0.16 \times 10^{-3}$  mm<sup>2</sup>/s for normal fibroglandular tissue,  $1.41 \pm 0.24 \times 10^{-3}$  mm<sup>2</sup>/s for benign breast lesions and  $0.83 \pm 0.19 \times 10^{-3}$  mm<sup>2</sup>/s for malignant breast lesions. The AUC with ROC analysis was 0.945 and the threshold for ADC was  $1.08 \times 10^{-3}$  mm<sup>2</sup>/s with a sensitivity and specificity of 92% and 92%, respectively. The threshold value for ADC ratio was 0.9 with 96% sensitivity and 89% specificity. The mean ADC of malignant breast lesions was statistically lower for benign lesions ( $p < 0.01$ ). We found no correlation between the mean ADC values and ER-PR receptor, Her2, and Ki-67 values.

**Conclusion:** Diffusion-weighted imaging has high diagnostic value with high sensitivity and specificity in differentiating malignant and benign breast lesions.

**Keywords:** Diffusion-weighted imaging, ADC, breast cancer, invasive ductal carcinoma, Ki-67, Her 2 expression

## Introduction

Magnetic resonance imaging (MRI) as a method for breast exams has been used increasingly frequently during the last decade. In particular, it is preferred for selected cases as a diagnostic and problem-solving method for its high contrast resolution, multiplanar capability of examination, lack of ionizing radiation, and capacity to obtain dynamic contrast images (1, 2). Conventional MRI has disadvantages such as time-consuming screening and requirement of high-value contrast agents (3). Despite the fact that dynamic contrast-enhanced MRI is an efficient diagnostic exam with high sensitivity, but its limited specificity creates a need for new techniques (1-7). Therefore, additional sequences are sought that would increase image quality, reduce imaging time and enable differential diagnosis for lesions (4). Diffusion-weighted imaging (DWI) is one of these fast MRI sequences. By recording the free movement of water molecules in the extracellular space, DWI creates different signals in images as a result of the inhibition of this movement and therefore diffusion restriction, which occurs due to an increase in cell frequency in the presence of a malignant mass. The apparent diffusion coefficient (ADC) is a quantitative measure of the diffusion of water molecules within tissue. Using the data in various b-values obtained from DWI in MRI, ADC maps are created and ADC values of lesions can be calculated (8, 9). Recent studies showed that DWI and ADC measurements had high rates of accuracy and specificity in the differential diagnosis of malignant and benign breast lesions (10-13).

Breast cancer is a heterogeneous disease, and its natural course after diagnosis varies among patients. In the follow-up of patients with tumors of the same diameter, some experience tumor recurrence after a very short time, whereas others continue living a healthy life. Therefore, prognostic factors and molecular subgroups are used in order to determine differences between clinical and biologic behaviors of patients with breast cancer and establish the high-risk group, which demonstrates a quick disease progression (14-17). Although some of these factors (tumor diameter, axillary involvement, histologic characteristics of tumor, hormone receptors) have a well-known role in determining prognosis, there is ongoing intensive research regarding hormone receptors, tumor proliferation rate, and molecular prog-

nostic factors. The prognostic importance of estrogen receptor (ER) and progesterone receptors (PR) was established in a group of neoplastic diseases, breast, and endometrial carcinoma in particular. ER and PR positive tumors respond to hormone therapy and provide a better prognosis (18). There are subcategories that include the prognostic values of tumor proliferation rate. Prognostic factors exist such as mitotic index, immunohistochemical proliferation markers (Cyclin A, Ki-67), S-phase reaction, thymidine labeling index, and bromodeoxyuridine (BrDu) labeling index. There are still extensive studies regarding most of these factors today (19). C-erbB-2 (Her2) oncoprotein shows protein-tyrosine kinase activity, which is structurally associated with epidermal growth factor receptor. Previous studies have shown that Her2 oncogene is a significant mediator of cell proliferation and differentiation (20). This gene is located on chromosome 17. Her2 positivity is encountered in breast cancers with high histologic grade, negative ER and PR, positive lymph node, and high proliferation rate (20, 21).

The aim of this study was to evaluate the diagnostic significance of ADC value and DWI in the differentiation of benign and malignant breast lesions and to investigate their correlation with histopathologic subtypes of breast tumors and prognostic factors such as ER, PR, Her2, and Ki-67 using 3T MR.

## Materials and Methods

The subjects in our retrospective study were chosen from patients who had undergone a preoperative MRI and were scheduled for a breast biopsy procedure in our clinic between November 2012 and November 2014. Informed consent forms were obtained from the patients as well as approval from the local ethics committee for this study.

Histopathologically diagnosed, 312 patients who had undergone ultrasound-guided tru-cut, mammography-guided stereotactic vacuum-assisted biopsy and routine breast screening were enrolled into the study. Of these patients, 56 patients with lesions smaller than 1cm and 91 patients with diagnostically inadequate quality of DWI-MRI sequences were excluded from the study. The remaining 165 patients with 181 lesions were included in the study. The patients' ages ranged between 16 and 78 years (mean age:  $46.7 \pm 12.01$  years), and all patients were female.

### MR Imaging

All MR images were obtained using a special 16-channel 3.0 Tesla coil (Magnetom Siemens Verio, Germany) with the breast in the prone position. All the patients had routine breast MRI examinations with conventional sequences. The sequences used in the conventional MRI were as follows: TRIM axial T2-weighted (TI:230ms, TR:4000ms, TE:72 ms, 3 mm section thickness, FOV:300-340 mm) images were obtained before T1 axial IV contrast-enhanced axial dynamic 3D (TR:5.04 ms, TE:1.91 ms,  $f_{3d1}/10$ , 1 mm section thickness, FOV:280-300 mm Matrix 420x400) examination; 1 pre-contrast sequence and 6 post-contrast sequences were performed, and the temporal resolution was 82 seconds. Subtraction images were acquired by subtracting the post-contrast images from the first images. For the contrast images, a dose of 0.1-0.2 mmol/kg of gadolinium-containing gadobutrol and gadoterate meglumine were injected via IV with an automatic injection device over 20 seconds.

As the primary subject of our study, DWI was performed before the contrast-enhanced examination. The diffusion-weighted sequences (TR/TE: 8300/93, flip angle: 80 degrees, 4 mm section thickness, FOV:300-320, Matrix 192x192 Nex:4) were performed with single-

shot spin-echo echo-planar in the axial plane with 3 different b values (b=50, 500, 800). The ADC values were automatically measured at the workstation, and ADC (b=800-b=50) map images were prepared.

### Lesion Evaluation

The lesions were evaluated by a single radiologist (YA) who has one-year experience of breast radiology; the radiologist was blinded the histopathologic diagnoses. A total of 165 patients with 181 lesions were evaluated by analyzing the conventional MRI and DWI to determine whether there were breast lesions with abnormal contrast enhancement. The DWI was examined for the presence of diffusion restriction on the breast tissues connected to the lesions, and the measurement values on the ADC map were taken into account. The equivalent of the most contrasted part in the masses detected in the conventional MRI examination was found in the DWI. A standard round region of interest (ROI) with a 5 mm diameter was placed on the image of this area in the ADC map. During the measurement, the cystic and necrotic component of the lesion was left out of the measuring range. Additionally, the ADC values of normal breast tissues on the lesion-free breast were measured in every patient, and the ADC rates of lesion-normal breast tissues were calculated.

The sizes of the 181 lesions included in the study ranged between 10 mm and 64 mm (mean  $18.3 \pm 8.9$  mm). Small lesions sized less than 1.5 cm were measured with one ROI, and large lesions were measured with 3 different ROIs. The lowest value of three measurements was taken into account. Furthermore, the ADC value of the mass in each patient was divided by the ADC value of the opposite normal breast for a proportion measurement.

Biopsy was performed on all lesions through either ultrasound-guided tru-cut (152 cases) or stereotactic vacuum-assisted biopsy (29 cases). The histopathologic diagnoses were considered as the referral diagnosis. The postoperative histopathologic findings of the malignant cases were accepted as a reference. Surgical excision was performed on 9 patients who had been diagnosed as having atypical ductal hyperplasia after which the diagnoses for 3 of these patients were changed to ductal carcinoma in situ (DCIS).

Hormonal prognostic factors were evaluated in 3 subgroups when both ER and PR were negative, both were positive, and when only one was positive. In total, hormone receptors were analyzed in 80 of 89 malignant lesions. Hormone receptors were not analyzed in 8 cases of DCIS and 1 well-differentiated liposarcoma. The postoperative histopathologic findings were investigated for the malignant lesions.

Ki-67 value was taken into consideration while evaluating tumor proliferation. Not including 8 DCIS and 1 well-differentiated liposarcoma malignant lesions, the Ki-67 values of 80 malignant lesions were analyzed. Pearson's correlation test was used for the correlation between the Ki-67 values and ADC.

Of molecular prognostic factors, Her2 was used as a base. Excluding 8 DCIS and 1 well-differentiated liposarcoma case from 89 patients with a malignant diagnosis, 80 lesions were rated with one positive (+), two positives (++) , three positives (+++) and 'no immunoeexpression.' Three positives (+++) was considered a positive result, whereas results with no immunoeexpression and + were considered negative. Fluorescence in situ hybridization (FISH) was used in 8 patients with two positives (++) . As a result of the FISH test, 4 lesions that had no amplification were considered negative, the remaining 4 lesions, which had positive amplification, were considered positive.

### Statistical analysis

The ADC values were reported with  $\text{min} \pm \text{standard deviation}$  using SPSS version 15 (SPSS, Inc.; Chicago, Illinois, USA) in the statistical analysis of our study. The mean min ADC values between the independent groups were compared using Student's t-test. A p value of  $<0.05$  was considered statistically significant. The threshold ADC values used to differentiate between benign and malignant lesions were determined using receiver operating characteristic (ROC) analysis. A post-hoc Tukey test was performed to evaluate the diagnostic difference in different subgroups. The Kruskal-Wallis H test was used to determine whether there was a statistically significant difference between the malignant and benign subgroups after which the Mann-Whitney U test was performed to determine which group had caused the difference. Pearson's correlation test was conducted for the correlation between the Ki-67 values and ADC.

### Result

Ninety-two of the 181 lesions involved in the study were diagnosed as benign and 89 were malignant. The histopathologic distribution of lesions is shown in Table 1.

The ADC values in the measurements determined from normal breast parenchyma ranged between  $0.96 \times 10^{-3} \text{ mm}^2/\text{sec}$  and  $1.94 \times 10^{-3} \text{ mm}^2/\text{sec}$  (mean  $1.35 \pm 0.16 \times 10^{-3} \text{ mm}^2/\text{sec}$ ).

In the ADC measurements of the lesions, the lowest ADC lesion value was  $0.51 \times 10^{-3} \text{ mm}^2/\text{sec}$  with invasive ductal carcinoma, and the highest ADC lesion value was  $1.79 \times 10^{-3} \text{ mm}^2/\text{sec}$  with fibroadenoma. The lowest lesion/normal breast tissue ADC rate was (0.40) in an invasive ductal carcinoma case, whereas the highest was (1.36) in a case of fibroadenoma.

The mean size of the 92 benign lesions was  $15.5 \pm 6.4 \text{ mm}$ . The mean min ADC value was found to be  $1.41 \pm 0.24 \times 10^{-3} \text{ mm}^2/\text{sec}$  for all the benign lesions. Among the benign lesions, the lowest ADC value belonged to an abscess with  $0.57 \times 10^{-3} \text{ mm}^2/\text{sec}$  and the highest ADC value was  $1.79 \times 10^{-3} \text{ mm}^2/\text{sec}$  in a fibroadenoma. The mean lesion/normal breast tissue ADC rate was  $1.07 \pm 0.17$  in these lesions. The lowest rate among all the benign lesions was 0.4 in an abscess and the highest rate was 1.36 in a fibroadenoma.

The mean size of malignant 89 lesions was measured  $20.9 \pm 9.9 \text{ mm}$ . The mean min ADC value was  $0.83 \pm 0.19 \times 10^{-3} \text{ mm}^2/\text{sec}$  for all the malignant lesions. Among the malignant lesions, the lowest ADC value was  $0.51 \times 10^{-3} \text{ mm}^2/\text{sec}$  in an invasive ductal carcinoma, and the highest ADC value was  $1.50 \times 10^{-3} \text{ mm}^2/\text{sec}$  in an invasive mucinous carcinoma. The mean lesion/normal breast tissue ADC rate was  $0.61 \pm 0.14$  in these lesions. The lowest rate was 0.4 in an invasive ductal carcinoma and the highest rate was 1.15 in an invasive mucinous carcinoma among all the malignant lesions.

The difference between the mean ADC values of the malignant lesions and benign lesions was statistically significant ( $p=0.001$ ). The difference between the lesion/normal breast tissue ADC values of the malignant lesions and benign lesions was statistically significant ( $p=0.001$ ) (Table 2).

When the threshold value for the mean min ADC value of the lesions was considered  $1.08 \times 10^{-3} \text{ mm}^2/\text{sec}$ , in the ROC analysis the AUC was 0.95 and the sensitivity and specificity of detecting malignant lesions were 92.1% and 92.4%, respectively (Figure 1) (Table 3). With a 0.9 threshold value for the lesion/normal breast tissue ADC rates, the

Table 1. The distribution of histopathologic diagnoses

	n	%
<b>Benign Lesions</b>	<b>92</b>	<b>50.8</b>
Fibroadenoma	37	40.2
Columnar Cell Hyperplasia	10	10.8
Fibrosis	11	11.9
Apocrine Metaplasia	7	7.6
Sclerosing Adenosis	6	6.5
Fibrocystic Changes	2	2.2
Postoperative Granulation Tissue	1	1.0
Atypia	6	6.5
Abscess	8	8.2
Intraductal Papilloma	4	4.1
Total	92	100
<b>Malignant Lesions</b>	<b>89</b>	<b>49.2</b>
Ductal carcinoma in situ	8	9
Invasive ductal carcinoma	63	70.8
Invasive lobular carcinoma	6	6.7
Invasive mucinous carcinoma	4	4.5
Invasive mixed carcinoma	5	5.6
Invasive medullary carcinoma	1	1.1
Invasive apocrine carcinoma	1	1.1
Well-differentiated liposarcoma	1	1.1
Total	89	100.0
<b>Total</b>	<b>181</b>	<b>100.0</b>

Table 2. The distribution of ADC levels and lesion/ADC rates by histopathologic result

	Benign (n=92)		Malignant (n=89)		t	p
	Mn	Sd	Mn	Sd		
Lesion ADC	1.414	2.388	0.826	0.187	18.418	<0.001
Lesion/ADC	1.074	0.171	0.607	0.136	20.328	<0.001

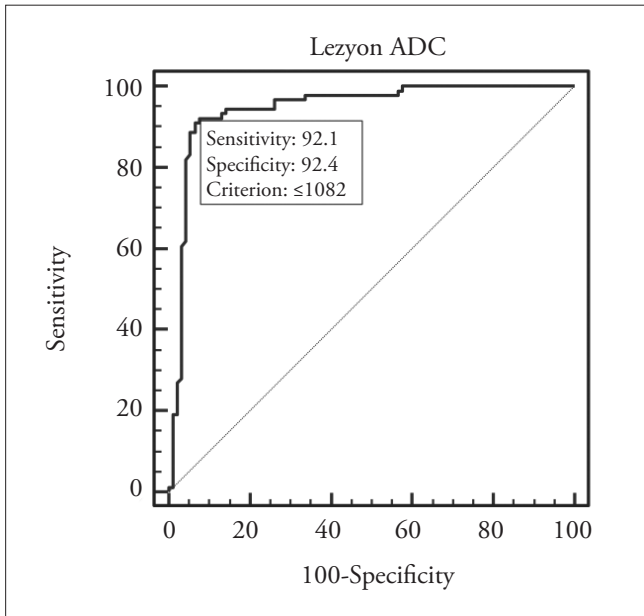
ADC: Apparent Diffusion Coefficient; Mn: mean; Sd: standard deviation; t: t value; p: p value

AUC was 0.956, and the sensitivity and specificity of the differentiation capability for benign and malignant breast lesions were 96.6% and 89.1%, respectively (Figure 2).

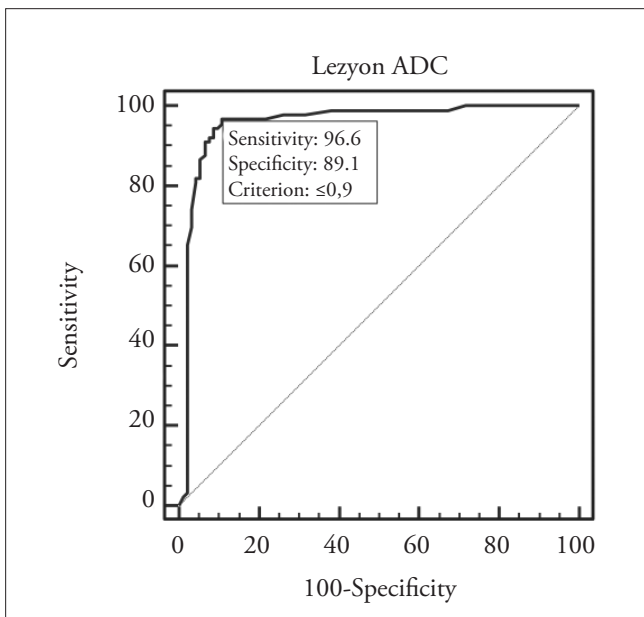
Table 3. ADC limit values in differentiation of benign and malignant breast lesions, sensitivity and specificity levels found in different threshold values in the ROC analysis

Threshold value	Sensitivity	95% CI	Specificity	95% CI	PPV	95% CI	NPV	95% CI
≤908	79.78	69.9 - 87.6	95.65	89.2 - 98.8	94.7	86.9 - 98.5	83.0	74.5 - 89.6
≤914	80.90	71.2 - 88.5	95.65	89.2 - 98.8	94.7	87.1 - 98.5	83.8	75.3 - 90.3
≤920	82.02	72.5 - 89.4	95.65	89.2 - 98.8	94.8	87.2 - 98.6	84.6	76.2 - 90.9
≤926	83.15	73.7 - 90.2	94.57	87.8 - 98.2	93.7	85.8 - 97.9	85.3	76.9 - 91.5
≤948	84.27	75.0 - 91.1	94.57	87.8 - 98.2	93.7	86.0 - 97.9	86.1	77.8 - 92.2
≤979	85.39	76.3 - 92.0	94.57	87.8 - 98.2	93.8	86.2 - 98.0	87.0	78.8 - 92.9
≤1000	86.52	77.6 - 92.8	94.57	87.8 - 98.2	93.9	86.3 - 98.0	87.9	79.8 - 93.6
≤1026	87.64	79.0 - 93.7	94.57	87.8 - 98.2	94.0	86.5 - 98.0	88.8	80.8 - 94.3
≤1033	88.76	80.3 - 94.5	94.57	87.8 - 98.2	94.0	86.7 - 98.0	89.7	81.9 - 94.9
≤1036	88.76	80.3 - 94.5	93.48	86.3 - 97.6	92.9	85.3 - 97.4	89.6	81.7 - 94.9
≤1047	89.89	81.7 - 95.3	93.48	86.3 - 97.6	93.0	85.4 - 97.4	90.5	82.8 - 95.6
≤1065	91.01	83.1 - 96.0	93.48	86.3 - 97.6	93.1	85.6 - 97.4	91.5	83.9 - 96.3
≤1079	91.01	83.1 - 96.0	92.39	84.9 - 96.9	92.0	84.3 - 96.7	91.4	83.8 - 96.2
≤1082	92.13	84.5 - 96.8	92.39	84.9 - 96.9	92.1	84.5 - 96.8	92.4	84.9 - 96.9
≤1083	92.13	84.5 - 96.8	91.30	83.6 - 96.2	91.1	83.2 - 96.1	92.3	84.8 - 96.9
≤1089	92.13	84.5 - 96.8	90.22	82.2 - 95.4	90.1	82.1 - 95.4	92.2	84.6 - 96.8
≤1103	92.13	84.5 - 96.8	89.13	80.9 - 94.7	89.1	80.9 - 94.7	92.1	84.5 - 96.8
≤1138	92.13	84.5 - 96.8	88.04	79.6 - 93.9	88.2	79.8 - 93.9	92.0	84.3 - 96.7
≤1143	92.13	84.5 - 96.8	86.96	78.3 - 93.1	87.2	78.8 - 93.2	92.0	84.1 - 96.7
≤1146	93.26	85.9 - 97.5	86.96	78.3 - 93.1	87.4	79.0 - 93.3	93.0	85.4 - 97.4
≤1160	93.26	85.9 - 97.5	85.87	77.0 - 92.3	86.5	78.0 - 92.6	92.9	85.3 - 97.4
≤1163	94.38	87.4 - 98.2	85.87	77.0 - 92.3	86.6	78.2 - 92.7	94.0	86.7 - 98.0
≤1203	94.38	87.4 - 98.2	84.78	75.8 - 91.4	85.7	77.2 - 92.0	94.0	86.5 - 98.0
≤1213	94.38	87.4 - 98.2	83.70	74.5 - 90.6	84.8	76.2 - 91.3	93.9	86.3 - 98.0
≤1216	94.38	87.4 - 98.2	82.61	73.3 - 89.7	84.0	75.3 - 90.6	93.8	86.2 - 98.0
≤1242	94.38	87.4 - 98.2	81.52	72.1 - 88.9	83.2	74.4 - 89.9	93.7	86.0 - 97.9
≤1244	94.38	87.4 - 98.2	80.43	70.9 - 88.0	82.4	73.6 - 89.2	93.7	85.8 - 97.9
≤1246	94.38	87.4 - 98.2	79.35	69.6 - 87.1	81.6	72.7 - 88.5	93.6	85.7 - 97.9
≤1255	94.38	87.4 - 98.2	78.26	68.4 - 86.2	80.8	71.9 - 87.8	93.5	85.5 - 97.9
≤1266	94.38	87.4 - 98.2	77.17	67.2 - 85.3	80.0	71.1 - 87.2	93.4	85.3 - 97.8
≤1290	94.38	87.4 - 98.2	76.09	66.1 - 84.4	79.2	70.3 - 86.5	93.3	85.1 - 97.8
≤1292	94.38	87.4 - 98.2	75.00	64.9 - 83.4	78.5	69.5 - 85.9	93.2	84.9 - 97.8
≤1294	94.38	87.4 - 98.2	73.91	63.7 - 82.5	77.8	68.8 - 85.2	93.2	84.7 - 97.7
≤1299	95.51	88.9 - 98.8	73.91	63.7 - 82.5	78.0	69.0 - 85.4	94.4	86.4 - 98.5
≤1301	96.63	90.5 - 99.3	73.91	63.7 - 82.5	78.2	69.3 - 85.5	95.8	88.1 - 99.1
≤1305	96.63	90.5 - 99.3	72.83	62.6 - 81.6	77.5	68.6 - 84.9	95.7	88.0 - 99.1

NPD: negative predictive value; PPV: positive predictive value; CI: confidence interval



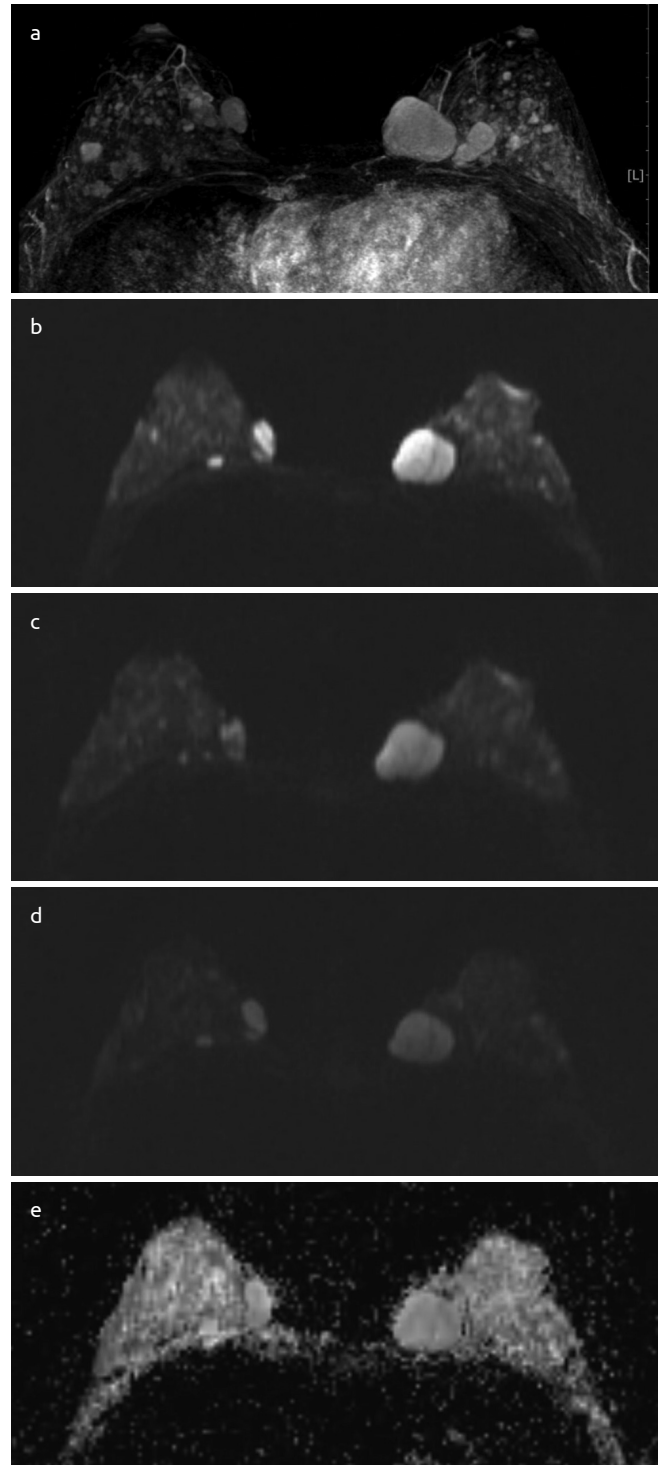
**Figure 1.** The differentiation curve of malignant-benign lesions for the ADC values based on the ROC analysis AUC=0.945



**Figure 2.** The differentiation curve of malignant-benign lesions for ADC lesion/normal breast tissue rates based on the ROC analysis AUC= 0.945

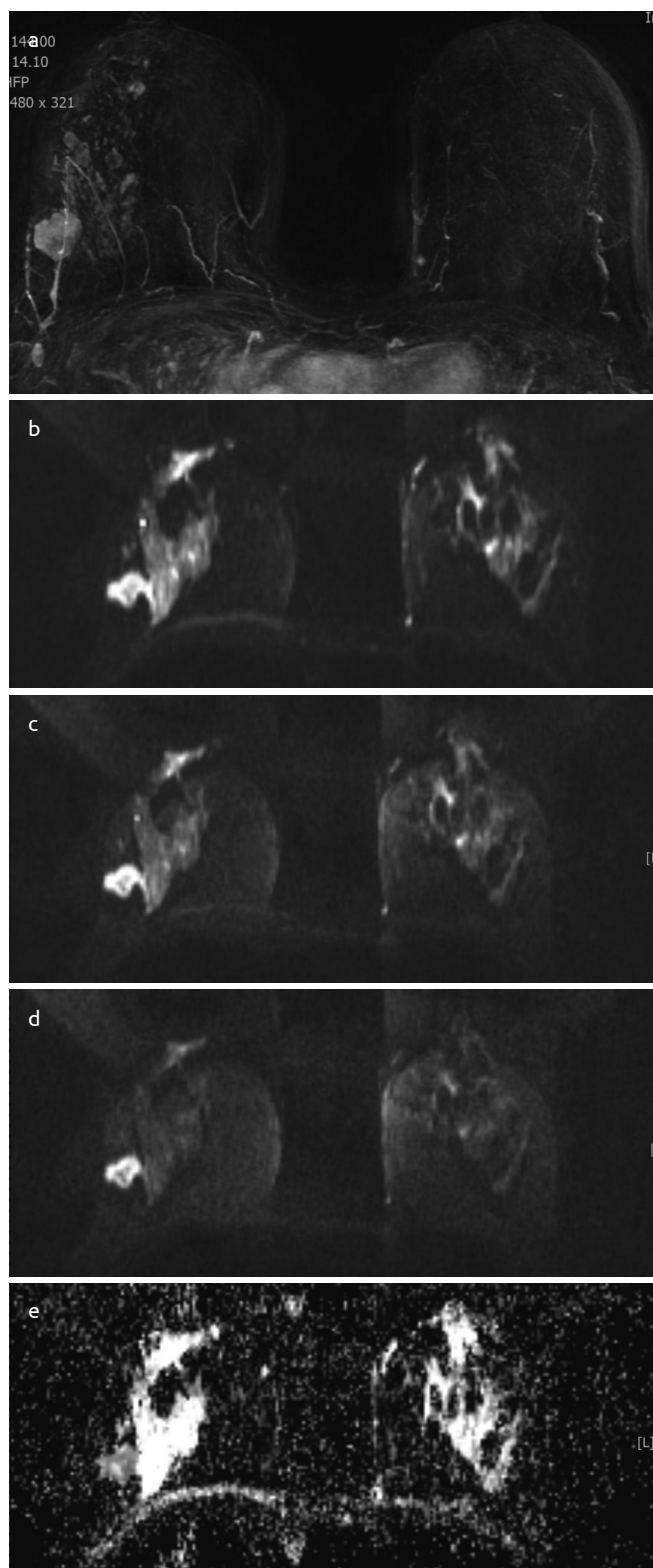
Of the benign lesions, 7 (7.6%) had lower ADC values than the determined threshold value  $1.08 \times 10^{-3} \text{ mm}^2/\text{sec}$ . Of these 7, 1 was fibroadenoma (Figure 3), 2 were atypical ductal hyperplasia, 3 were abscesses, and 1 was intraductal papilloma. Of the malignant lesions, 8 (9%) had higher ADC values than the determined threshold value  $1.08 \times 10^{-3}$ . Of these 8, 3 were DCIS, 1 was invasive lobular carcinoma, 3 were invasive mucinous carcinoma, and 1 was well-differentiated liposarcoma.

Of the 89 malignant lesions, 63 (71%) were diagnosed as invasive ductal carcinoma. The mean min ADC value of the lesions diagnosed as invasive ductal carcinoma was  $0.76 \pm 0.09 \times 10^{-3} \text{ mm}^2/\text{sec}$  (Figure 4). The mean min ADC value of 6 lesions (6%) diagnosed as invasive



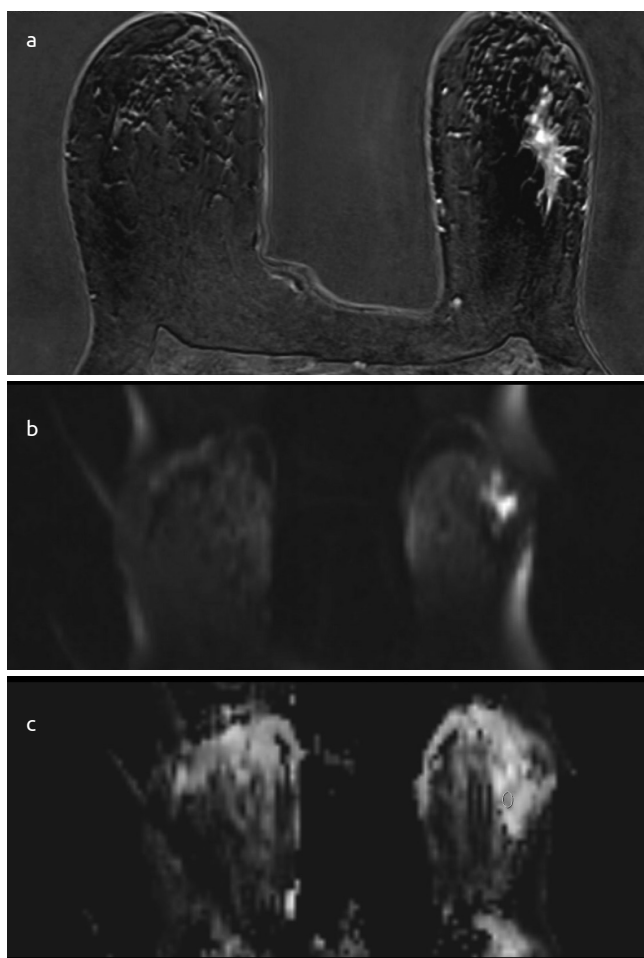
**Figure 3. a-e.** A woman aged 22 years. A large number of fibroadenomas were monitored in both breasts, the largest of which was located in the upper inner quadrant of the left breast with a 33 mm diameter. (a) Contrast-enhanced T1-weighted imaging (b) Diffusion-weighted Imaging (DWI) ( $b=50 \text{ mm}^2/\text{sec}$ ) (c) DWI ( $b=400 \text{ mm}^2/\text{sec}$ ) (d) DWI ( $b=800 \text{ mm}^2/\text{sec}$ ) (e) ADC value:  $1587 \times 10^{-6} \text{ mm}^2/\text{sec}$

lobular carcinoma was  $0.94 \pm 0.14 \times 10^{-3} \text{ mm}^2/\text{sec}$ . The mean min ADC value of 4 patients (4%) who were diagnosed as having invasive mucinous carcinoma was  $1.21 \pm 0.15 \times 10^{-3} \text{ mm}^2/\text{sec}$ . The mean min ADC value of 5 patients (5%) diagnosed as having invasive mixed carcinoma was  $0.73 \pm 0.10 \times 10^{-3} \text{ mm}^2/\text{sec}$ . The mean min ADC value of 8 (8%) DCIS lesions was  $1.06 \pm 24 \times 10^{-3} \text{ mm}^2/\text{sec}$  (Figure 5). The mean



**Figure 4. a-e.** A woman aged 32 years. A lesion diagnosed as invasive ductal carcinoma with a 23 mm diameter located in the upper outer quadrant of the right breast. (a) Contrast-enhanced T1-weighted imaging (b) Diffusion-weighted Imaging (DWI) ( $b=50 \text{ mm}^2/\text{sec}$ ) (c) DWI ( $b=400 \text{ mm}^2/\text{sec}$ ) (d) DWI ( $b=800 \text{ mm}^2/\text{sec}$ ) (e) ADC value:  $809 \times 10^{-6} \text{ mm}^2/\text{sec}$

min ADC values within the malignant groups were found significantly different in terms of the histopathologic result variable ( $p<0.05$ ). The mean min ADC values of DCIS, invasive lobular carcinoma and in-



**Figure 5. a-c.** A woman aged 51 years. An irregular spiculated mass 28 mm in diameter with contour in the contrast-enhanced images located in the upper outer quadrant of the left breast. Histopathologic result: DCIS. (a) Contrast-enhanced T1-weighted imaging (b) Diffusion-weighted Imaging (DWI) ( $b=800 \text{ mm}^2/\text{sec}$ ) (c) ADC value:  $1299 \times 10^{-6} \text{ mm}^2/\text{s}$

vasive mucinous carcinoma were significantly higher than the mean min ADC values of invasive ductal carcinoma and invasive mixed carcinoma ( $p<0.05$ ). The group with the highest mean min ADC value of the malignant lesions was invasive mucinous carcinoma. Among the benign lesions, the mean min ADC value of 37 fibroadenoma lesions was  $1.54 \pm 0.13 \times 10^{-3} \text{ mm}^2/\text{sec}$ , and the mean min ADC value of 4 intraductal papilloma lesions was  $1.17 \pm 0.31 \times 10^{-3} \text{ mm}^2/\text{sec}$ . The mean min ADC value of the fibroadenoma lesions was significantly higher than that of the intraductal papilloma lesions ( $p<0.05$ ). When the fibroadenoma and mucinous tumors were compared, the difference between the mean min ADC values of the invasive mucinous carcinoma and fibroadenoma lesions was statistically significant ( $p<0.05$ ) (Table 4).

The mean min ADC value of 15 malignant lesions with negative ER and PR molecular prognostic factors was  $0.77 \pm 0.11 \times 10^{-3} \text{ mm}^2/\text{sec}$ , whereas the mean min ADC value of 7 malignant lesions with one positive ER or PR was  $0.76 \pm 0.07 \times 10^{-3} \text{ mm}^2/\text{sec}$ , and the mean min ADC value of 58 patients with positive ER and PR was  $0.80 \pm 0.16 \times 10^{-3} \text{ mm}^2/\text{sec}$ . Based on these results, the group with negative ER and PR had a lower mean min ADC value than the group with positive ER and PR. However, this difference was not statistically significant ( $p=0.684$ ) (Table 5).

Table 4. The mean values of ADC levels by histopathologic subgroups

	N	Mean ADC	SD	Minimum	Maximum
<b>Benign</b>					
Apocrine metaplasia and columnar cell hyperplasia	37	1.469	0.176	1.187	1.783
Fibroadenoma	37	1.543	0.133	0.926	1.791
Atypia	6	1.194	0.270	0.720	1.448
Abscess	8	1.188	0.397	0.570	1.597
Intraductal Papilloma	4	1.172	0.314	0.818	1.573
<b>Malignant</b>					
Ductal Carcinoma In Situ	8	1.056	0.242	0.747	1.356
Invasive Ductal Carcinoma	63	0.758	0.093	0.508	1.065
Invasive Lobular Carcinoma	6	0.944	0.144	0.785	1.163
Invasive Mucinous Carcinoma	4	1.210	0.153	1.026	1.504
Invasive Mixed Carcinoma	5	0.727	0.104	0.617	0.875
Invasive Medullary Carcinoma	1	0.898	-	0.898	0.898
Well-Differentiated Liposarcoma	1	1.499	-	1.499	1.499
Invasive Apocrine Carcinoma	1	0.775	-	0.775	0.775
Total	181	1.125	364.30	0.508	1.791

ADC: apparent diffusion coefficient; SD: standard deviation; N: number

Table 5. Lesion ADC levels by ER/PR

	ER and PR-(15)		ER or PR-(7)		ER and PR +(58)		F	p
	Mn	Sd	Mn	Sd	Mn	Sd		
Lesion ADC	0.771	0.114	0.762	0.065	0.803	0.160	0.382	0.684

ER: estrogen receptor; PR: progesterone receptor; ADC: apparent diffusion coefficient

Table 6. Lesion ADC levels by C-erbB-2

	c-erbB-2(-) (n=56)		c-erbB-2(+) (n=24)		t	p
	Mn	Sd	Mn	Sd		
Lesion ADC	0.807	0.164	0.766	0.089	1.43	0.157

C-erbB-2: Her2 immunoeexpression  
ADC: apparent diffusion coefficient; SD: standard deviation; Mn: mean value

The mean min ADC value of 56 lesions with a negative, 1+ and 2+ Her2, a molecular prognostic factor, and no amplification found in FISH was  $0.81 \pm 0.16 \times 10^{-3} \text{ mm}^2/\text{sec}$ , and the mean min ADC value of 24 lesions with 3+ and 2+ Her2 and amplification found in FISH was  $0.77 \pm 0.09 \times 10^{-3} \text{ mm}^2/\text{sec}$ . Based on these findings, the mean min ADC value of the group with Her2-positive lesions was lower compared with the mean min ADC value of the group with Her2-neg-

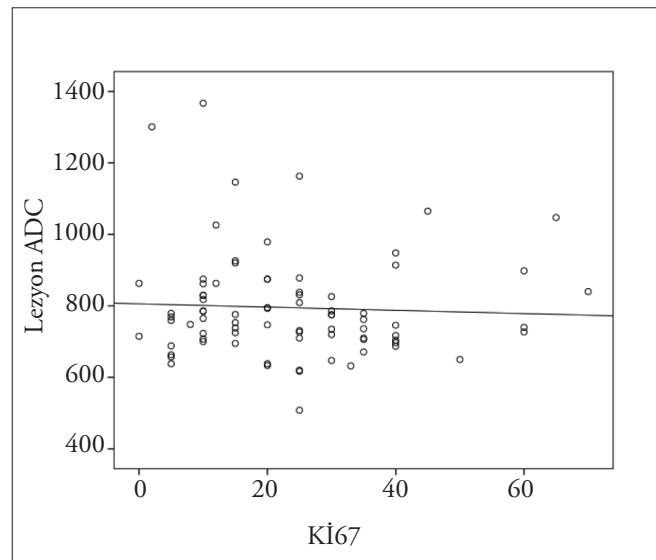


Figure 6. Pearson's correlation was performed for the correlation of the Ki-67 values and ADC values,  $p=0.669$

ative lesions. However, the difference was not statistically significant ( $p=0.157$ ) (Table 6).

When the correlation between the tumor proliferation rate indicators Ki-67 and ADC values was analyzed, there was no correlation found between the values ( $p= 0.669$ ) (Figure 6).

**Discussion and Conclusion**

There was a statistically significant difference between the ADC values of the malignant breast lesions and benign breast lesions in our

study ( $p < 0.01$ ), and the diagnostic value of the test showed a very high AUC value (0.945) in the ROC analysis. This difference was caused by the decrease in the extracellular volume content of the tumors due to the increased cellular density and the fall in the ADC value due to restricted water diffusion (10). The dynamic contrast-enhanced examinations are directly related to the vascularity of the tumors and unrelated to tumor cellularity (5). In our study, fairly high sensitivity (92%) and specificity (92%) were acquired in evaluating the breast lesions with DWI. The dynamic contrast-enhanced breast MRI had a high sensitivity in detecting malignant lesions but a low specificity, which imposed limitations. There are studies stating that this specificity can be improved with DWI (22-24). However, different threshold values were reported in studies with DWI based on the station and magnetic field of the device. The reported values range between 1.02 and  $1.43 \times 10^{-3} \text{ mm}^2/\text{sec}$ , and differed from each other. According to the ROC curve in our study, the best threshold value was  $1.08 \times 10^{-3} \text{ mm}^2/\text{sec}$ . This value fell between the reported values in the literature; however, it was closer to the low values. The fact that the values differ greatly amongst studies raises difficulties in using DWI as a standard method. Baltzer et al. (25) determined a threshold ADC value of 1.4 in the evaluation algorithm they proposed, and created an evaluation chart accordingly. According to this chart, biopsy should not be recommended for lesions with an ADC higher than 1.4 even if the other criteria of the lesions indicate biopsy. Ours is the highest threshold value reported in the literature, and the sensitivity was 96.6% for this threshold value. However, there were cases with invasive mucinous carcinoma that did not comply with this criterion and had an ADC value higher than 1.4. The mean min ADC value of 4 lesions diagnosed as invasive mucinous carcinoma was  $1.21 \pm 0.15 \times 10^{-3} \text{ mm}^2/\text{sec}$ , and there was a significant difference between this type of cancer and other types of cancer ( $p < 0.05$ ). Similarly, high values were reported in the literature for mucinous carcinoma between  $1.6 \times 10^{-3}$  and  $2.1 \times 10^{-3} \text{ mm}^2/\text{sec}$ , but the mean value in our study was below these values (26-28). The most typical feature of mucinous carcinoma is the mucin content observed in the extracellular area. The mucin content makes diffusion of liquids easier, and there is less restriction compared with other malignant lesions (26-28). Mucinous carcinomas are sharply-bordered like fibroadenomas in morphologic analyses, and are seen as lesions that contain black septa in T2-weighted and contrast-enhanced examinations, and therefore may cause diagnostic errors. We found a distinctive difference between the fibroadenoma ADC values and mucinous carcinoma ADC values in our evaluation ( $p < 0.05$ ).

When we assessed the lesion/breast tissue ADC rates and the lesions, we found a higher AUC, going up to 0.956 from 0.945, according to the ROC analysis. When we determined a threshold value as 0.9, the sensitivity went up 96% and the specificity was 89%. Similar studies in the literature reported that measuring the ratio of ADC values for healthy breast tissues and lesions helped diagnostic accuracy, whereas an increase in sensitivity caused a decrease in specificity in our study (23, 29).

There was a significant difference between the mean ADC values of invasive ductal carcinomas and ductal carcinoma in situ in our study ( $p < 0.005$ ) when we evaluated the ADC values of cancers in different histopathologic groups. The ADC values of DCIS were significantly high. In a study by Choi et al. (30) with 276 cases of invasive ductal carcinoma and 59 cases of DCIS, the mean ADC value of invasive ductal carcinoma was  $0.907 \times 10^{-3} \text{ mm}^2/\text{sec}$ , and the mean ADC value of DCIS was  $1.113 \times 10^{-3} \text{ mm}^2/\text{sec}$ . Bickel et al. (31) reported in their study 155 patients with invasive ductal carcinoma and 21 patients with

DCIS that the mean ADC value of invasive ductal carcinoma lesions was  $0.900 \times 10^{-3} \text{ mm}^2/\text{sec}$  and the mean ADC value of DCIS was  $1.240 \times 10^{-3} \text{ mm}^2/\text{sec}$ . In a study by Qiu Lang Hua et al. (26) the authors used two different b values, the mean ADC value of 48 invasive ductal carcinoma lesions was  $1.099 \times 10^{-3} \text{ mm}^2/\text{sec}$  and the mean ADC value of 6 DCIS lesions was  $1.305 \times 10^{-3} \text{ mm}^2/\text{sec}$  when the b value was 1000. The reasons for this difference were that invasive ductal carcinoma is a type of cancer that is heavier with cells and it restricts water diffusion more compared with DCIS (32, 33).

Various studies have investigated the relationship between tumor prognostic factors and DWI (30-41). Some studies concluded that there was a relationship between tumor grade and ADC values. In these studies, it was argued that high-grade tumors had more diffusion restriction than low-grade tumors due to cell morphology and differences in extracellular matrix (33, 35). Therefore, we compared the ADC values particularly in terms of molecular markers that determine the prognosis of tumor. However, we found no relationship especially between the ADC values and Ki-67 values that inform about the tumor's mitotic activity. Similarly, we could not demonstrate a relationship between ER and Her2. Jeh et al. (40) reported a relationship between ER positivity and Her2 negativity and low ADC. However, they did not report a relationship between other prognostic factors, and especially Ki-67. In the study by Choi et al. (30) of 335 patients with invasive ductal carcinoma, the ADC value of ER(+) and PR(+) tumors was significantly lower than the ADC value of ER(-) and PR(-) tumors ( $p = 0.003$  and  $p = 0.032$ ). Aglietta et al. (41) reported a slight but significant relationship between ER and ADC. On the other hand, Park et al. (39) could not demonstrate a relationship between ER, PR, and Ki-67 in their study on 190 malignant lesions. Similarly, Kim et al. (35) could not report a distinctive relationship with ER and PR in their study. Contrary to these studies, the mean ADC values were higher with positive ER and PR in our study; however, we did not find a statistically significant result.

Her2 expression with cell proliferation occurs in more invasive tumors with poor prognosis. Therefore, a decrease in ADC values is expected after cell growth in Her2 expression. However, studies have shown low ADC values in cases with no Her2 expression (39, 41). Park et al. (39) claimed that increased angiogenesis and increased perfusion secondary to neovascularization in patients with Her2-positive suppressed the diffusion restriction the tumor creates. The effect of perfusion becomes more suppressed as the determined b value increases. However, although Park et al. (39) used a b1000 value that would effectively suppress the effect of perfusion, they included the strong perfusion that could have occurred due to Her2-positivity in their report but did not explain why the high b value did not suppress the perfusion. Additionally, regardless of the number of the statistical differences found in this study, the difference between the ADC values of Her2 0 and Her2 +++ cases was between 0.88 and 0.92 with a very small gap of 0.4. Despite the fact that the gap was similarly 0.4 units between the 0.81 mean ADC value of the Her2-negative cases and the 0.77 mean ADC value of the Her2-positive cases, there was no statistical significance found in our study. Choi et al. (30) did not report a correlation between the Her2 and ADC values in their study with 335 patients with invasive ductal carcinoma. Similarly, Kamitani et al. (36) did not report a correlation between the Her2 and ADC values in their study with 81 patients with invasive breast cancer. Although we found no statistical significance in terms of ER and PR values and Her2 values compared with the literature, the mean ADC values were much lower in patients with negative ER, PR and Her2 than in the patients with

positive ER, PR and Her2. Park et al. (39) found low ADC values in both ER-positive and PR-negative patients in their study. However, although there was a difference between the PR-positive and PR-negative patients, they did not find a statistical significance. The results of the studies reported in the literature are inconsistent. The mean ADC values with very small differences were significant in some studies but not significant in others (31-41). Therefore, we believe large series with the participation of more patients are needed in this regard.

In our study, there was no correlation between the Ki-67 and ADC values. In the study by Choi et al. (31), the threshold value for the Ki-67 value was considered as 20, when values over 20 were categorized as Ki-67(+) and values under 20 were (-), the ADC values of the tumors with high Ki-67 were significantly low. In a study by De Felice et al. (37) of 75 patients with invasive ductal carcinoma, the threshold value for Ki-67 was 30. Accordingly, there was no significant correlation found between the Ki-67 values and ADC values. There was no significant correlation found between prognostic factors such as ER-PR, Her2 and Ki-67, and ADC value in the study by Cipolla et al. (38) of 96 patients with invasive ductal carcinoma, or in the study by Kim et al. (39) in 67 patients with invasive breast cancer.

One of the limitations in our study is that it was a retrospective study and a large number of examinations were excluded because of technical errors. Therefore, objectivity may have been damaged with regard to lesions. Another limitation is the possibility of mismeasurement due to mis-locating a region of interest (ROI) (42). The ADC levels of malignant lesions with necrotic centers are expected to increase in localization of necrosis (42). In lesions with thin peripherally-enhanced tumor tissues, an adjacent necrotic part, adjacent normal fibroglandular tissue and adipose tissues may enter inside the region of interest, and this may cause incorrect positive or negative results. Another limitation was that invasive ductal carcinoma was dominant in the histopathologic subgroup distribution of malignant lesions, and the number of other lesions was small in comparison. A similar inequality is present in some of the molecular subgroups (ER, PR, and Her2). Another limitation of the study was that the performance of DWI alone was analyzed without including its contribution to dynamic contrast-enhanced examination.

Consequently, DWI is a method with high sensitivity and specificity that demonstrates a high diagnostic performance in the differentiation of benign and malignant breast lesions. However, it was not deemed adequate for evaluating prognostic molecular markers such as ER, PR, Her2 and Ki-67.

**Ethics Committee Approval:** Ethics committee approval was received for this study.

**Informed Consent:** Informed consent was obtained from patients who participated in this study.

**Peer-review:** Externally peer-reviewed.

**Author Contributions:** Concept - E.A.; Design - E.A., Y.A.; Supervision - E.A.; Funding - E.A., Y.A.; Materials - M.Ü.U.; Data Collection and/or Processing - Y.A.; Analysis and/or Interpretation - H.K., Y.A., E.A.; Literature Review - Y.A., E.A.; Writing - Y.A.; Critical Review - E.A.

**Conflict of Interest:** No conflict of interest was declared by the authors.

**Financial Disclosure:** The authors declared that this study has received no financial support.

## References

- Rankin SC. MRI of the breast. *Br J Radiol* 2000; 73:806-818. (PMID: 11026854) [[CrossRef](#)]
- Szabo BK, Aspelin P, Wiberg MK, Bone B. Dynamic MR imaging of the breast analysis of kinetic and morphologic diagnostic criteria. *Acta Radiol* 2003; 44:379-386. (PMID: 12846687)
- Morris EA. Diagnostic breast MR imaging: current status and future directions. *Radiol Clin North Am* 2007; 45:863-880. (PMID: 17888774) [[CrossRef](#)]
- Baltzer PA, Benndorf M, Dietzel M, Gajda M, Camara O, Kaiser WA. Sensitivity and specificity of unenhanced MR mammography (DWI combined with T2-weighted TSE imaging, uMIRM) for the differentiation of mass lesions. *Eur Radiol* 2010; 20:1101-1110. (PMID: 19936758) [[CrossRef](#)]
- Kuhl CK, Mielcareck P, Klaschik S, Leutner C, Wardelmann E, Gieseke J, Schild H. Dynamic breast MR imaging: are signal intensity time course data useful for differential diagnosis of enhancing lesions. *Radiology* 1999; 211:101-110. (PMID: 10189459) [[CrossRef](#)]
- Wenkel W, Geppert C, Uder M, Kiefer B, Bautz W, Janka R. Diffusion-Weighted Imaging in Breast MRI-An Easy Way to Improve Specificity. *Clinical Woman's Health* 2007; 3:28-32. (PMID: 17707315)
- Reimer P, Parizel PM, Stichnoth FA. A practical approach clinical MR imaging. IN: Khul C, ed. *Magnetic resonance of breast*. Springer, 1999. p. 397-414.
- Sener RN. Diffusion MRI: Apparent diffusion coefficient (ADC) values in the normal brain and a classification of brain disorders based on ADC values. *Comput Med Imaging Graph* 2001; 25:299-326. (PMID: 11356324) [[CrossRef](#)]
- El Kady RM, Choudhary AK, Tappouni R. Accuracy of apparent diffusion coefficient value measurement on PACS workstation: A comparative analysis. *AJR Am J Roentgenol* 2011; 196:280-284. (PMID: 21343475) [[CrossRef](#)]
- Sinha S, Lucas-Quesada FA, Sinha U, DeBruhl N, Bassett LW. In Vivo DiffusionWeighted MRI of the Breast: Potential for Lesion Characterization. *J Magn Reson Imaging* 2002 15:693-704. (PMID: 12112520) [[CrossRef](#)]
- Provenzale JM, Sorensen AG. Diffusion-Weighted MR Imaging in Acute Stroke: Theoretic Considerations and Clinical Applications. *AJR* 1999; 173:1459-1467. (PMID: 10584783) [[CrossRef](#)]
- Le Bihan D, Breton E, Lallemand D, Aubin M-L, Vignaud J, Laval-Jeantet M. Separation of diffusion and perfusion in intra-voxel incoherent motion imaging. *Radiology* 1988; 168:497-505. (PMID: 3393671) [[CrossRef](#)]
- Petralia G, Bonello L, Summers P, Preda L, Malasevski A, Raimondi S, Di Filippi R, Locatelli M, Curigliano G, Renne G, Bellomi M. Intraobserver and interobserver variability in the calculation of apparent diffusion coefficient (ADC) from diffusion-weighted magnetic resonance imaging (DW-MRI) of breast tumours. *Radiol Med* 2011; 116:466-476. (PMID: 21225368) [[CrossRef](#)]
- Crowe JR, JP Gordon NH, Shenk RR, Zolliger Jr. RM, Brumberg DJ, Shuck JM. Primary tumor size. Relevance to Breast Cancer Survival. *Arch Surg* 1992; 127:910-915. (PMID: 1642535) [[CrossRef](#)]
- Clauser P, Marcon M, Maieron M, Zuiani C, Bazzocchi M, Baltzer PA. Is there a systematic bias of apparent diffusion coefficient (ADC) measurements of the breast if measured on different workstations? An inter- and intra-reader agreement study. *Eur Radiol* 2016; 26:2291-2296. (PMID: 26443604) [[CrossRef](#)]
- Fisher B, Slack NH. Number of lymph nodes examined and prognosis of breast carcinoma. *Surg Gynecol Obstet* 1970; 131:79-88. (PMID: 5419966)
- International Histological Classifications of tumours. In: *World Health Organization. Histological Typing of Breast Tumors*, 2nd ed. Geneva: World Health Organizations 1982:19.
- Chen XS, Ma CD, Wu JY, Yang WT, Lu HF, Wu J, Lu JS, Shao ZM, Shen ZZ, Shen KW. Molecular subtype approximated by quantitative estrogen receptor, progesterone receptor and Her2 can predict the prognosis of breast cancer. *Tumori* 2010; 96:103-110. (PMID: 20437866)

19. Amadori D, Silverstrini R. Prognostic and predictive value of thymidine labeling index in breast cancer. *Breast Cancer Res Treat* 1998; 51:267-281. (PMID: 10068084) [\[CrossRef\]](#)
20. Slamon DJ, Godolphin W, James CA, Holt JA, Wong SG, Keith DE, Levin WJ, Stuart SG, Udove J, Ullrich A. Studies of the Her-2/neu proto-oncogene in human breast and ovarian cancer. *Science* 1989; 244:707-712. (PMID: 2470152) [\[CrossRef\]](#)
21. Paik S, Byant J, Park C, Fisher B, Tan-Chiu E, Hyams D, Fisher ER, Lippman ME, Wickerham DL, Wolmark N. Erb B-2 and response to doxorubicin in patients with axillary lymph node-positive, hormone receptor-negative breast cancer. *J Cancer Inst* 1998; 90:1361-1370. (PMID: 9747867) [\[CrossRef\]](#)
22. El Khouli RH, Jacobs MA, Mezban SD, Huang P, Kamel IR, Macura KJ, Bluemke DA. Diffusion-weighted imaging improves the diagnostic accuracy of conventional 3.0-T breast MR imaging. *Radiology* 2010; 256:64-73. (PMID: 20574085) [\[CrossRef\]](#)
23. Yabuuchi H, Matsuo Y, Kamitani T, Setoguchi T, Okafuji T, Soeda H, Sakai S, Hatakenaka M, Kubo M, Tokunaga E, Yamamoto H, Honda H. Non-mass-like enhancement on contrast-enhanced breast MR imaging: lesion characterization using combination of dynamic contrast-enhanced and diffusion-weighted MR images. *Eur J Radiol* 2010; 75:e126-132. (PMID: 19796900) [\[CrossRef\]](#)
24. Kul S, Cansu A, Alhan E, Dinc H, Gunes G, Reis A. Contribution of diffusion-weighted imaging to dynamic contrast-enhanced MRI in the characterization of breast tumors. *AJR Am J Roentgenol* 2011; 196:210-217. (PMID: 21178069) [\[CrossRef\]](#)
25. Baltzer A, Dietzel M, Kaiser CG, Baltzer PA. Combined reading of Contrast Enhanced and Diffusion Weighted Magnetic Resonance Imaging by using a simple sum score. *Eur Radiol* 2016; 26:884-891. (PMID: 26115653) [\[CrossRef\]](#)
26. Long-Hua Q, Qin X, Wen-Tao Y, Feng T, Kun-Wei S, Bin W, Ya-Jia G. Diffusion-Weighted MRI evaluations of breast cancer extension. *Clinical Imaging* 2010; 34:89-96. (PMID: 20189070) [\[CrossRef\]](#)
27. Hatakenaka M, Soeda H, Yabuuchi H, Matsuo Y, Kamitani T, Oda Y, Tsuneyoshi M, Honda H. Apperent Diffusion Coefficient of Breast Tumor: Clinical Application. *Magn Reson Med* 2009; 7:23-29. (PMID: 18460845) [\[CrossRef\]](#)
28. Woodhams R, Kakita S, Hata H, Iwabuchi K, Umeoka S, Mountford CE, Hatabu H. Diffusion-weighted imaging of mucinous carcinoma of the breast: evaluation of apparent diffusion coefficient and signal intensity in correlation with histologic findings. *AJR Am J Roentgenol* 2009; 193:260-266. (PMID: 19542422) [\[CrossRef\]](#)
29. Sahin C, Aribal E. The Role of Apperent Coefficient Values in the differential diagnosis of breast lesions in diffusion-weighted MRI. *Diag Interv Radiol* 2013; 19:457-462. (PMID: 24004972)
30. Choi SY, Chang YW, Park HJ, Kim HJ. Correlation of the apparent diffusion coefficient values on diffusion-weighted imaging with prognostic factors for breast cancer. *Br J Radiol* 2012 85:e474-e479. (PMID: 22128125) [\[CrossRef\]](#)
31. Bickel H, Pinker-Domenig K, Bogner W, Spick C, Bagó-Horváth Z, Weber M, Helbich T, Baltzer P. Quantitative Apperent Diffusion Coefficient as a Noninvasive Imaging of the Differentiation of Invasive Breast Cancer and Ductal Carcinoma In Situ. *Invest Radiol* 2015; 50:95-100. (PMID: 25333308) [\[CrossRef\]](#)
32. Costantini M, Belli P, Rinaldi P, Bufi E, Giardina G, Franceschini G, Petrone G, Bonomo L. Diffusion-Weighted imaging in breast cancer: relationship between apperent diffusion coefficient and tumor aggressiveness. *Clin Radiol* 2010; 65:1005-1012. (PMID: 21070905) [\[CrossRef\]](#)
33. Yoshikawa M, Ohumi S, Sugata S. Comparison of breast cancer detection by diffusion-weighted magnetic resonance imaging and mammography. *Radiat Med* 2007 25:218-223. (PMID: 17581710) [\[CrossRef\]](#)
34. Belli P, Costantini M, Bufi E, Giardina GG, Rinaldi P, Franceschini G, Bonomo L. Diffusion magnetic resonance imaging in breast cancer characterisation: correlations between the apparent diffusion coefficient and major prognostic factors. *Radiol Med* 2015; 120:268-276. (PMID: 25096888) [\[CrossRef\]](#)
35. Kim SH, Cha ES, Kim HS, Kang BJ, Choi JJ, Jung JH, Park YG, Suh YJ. Diffusion-Weighted imaging of breast cancer: correlation of the apperent diffusion coefficient value with prognostic factors. *J Magn Reson Imaging* 2009; 30:615-620. (PMID: 19711411) [\[CrossRef\]](#)
36. Kamitani T, Matsuo Y, Yabuuchi H, Fujita N, Nagao M, Jinnouchi M, Yonezawa M, Yamasaki Y, Tokunaga E, Kubo M, Yamamoto H, Yoshiura T, Honda H. Correlations Between Apperent Diffusion Coefficient Values and Prognostic Factors of Breast Cancer. *Magn Reson Med Sci* 2013; 12:193-199. (PMID: 23857151) [\[CrossRef\]](#)
37. De Felice C, Cipolla V, Guerrieri D, Santucci D, Musella A, Porfiri LM, Meggiorini ML. Apperent Diffusion Coefficient on 3.0 Tesla Magnetic Resonance imaging and prognostic factors in breast cancer. *Eur J Gynecol Oncol* 2014; 35:408-414. (PMID: 25118482)
38. Cipolla V, Santucci D, Guerrieri D, Drudi FM, Meggiorini ML, de Felice C. Correlation between 3T apperent diffusion coefficient values and grading of invasive breast carcinoma. *Eur J Radiol* 2014; 83:2144-2150. (PMID: 25305145) [\[CrossRef\]](#)
39. Park SH, Choi HY, Hahn SY. Correlations between apparent diffusion coefficient values of invasive ductal carcinoma and pathologic factors on diffusion-weighted MRI at 3.0 Tesla. *J Magn Reson Imaging* 2015; 41:175-182. (PMID: 24353241) [\[CrossRef\]](#)
40. Jeh SK, Kim SH, Kim HS, Kang BJ, Jeong SH, Yim HW, Song BJ. Correlation of the apparent diffusion coefficient value and dynamic magnetic resonance imaging findings with prognostic factors in invasive ductal carcinoma. *J Magn Reson Imaging* 2011; 33:102-109. (PMID: 21182127) [\[CrossRef\]](#)
41. Aglietta M, Regge D, Montemurro F. Correlations between diffusion-weighted imaging and breast cancer biomarkers. *Eur Radiol* 2012; 22:1519-1528. (PMID: 22411304) [\[CrossRef\]](#)
42. Charles-Edwards EM, DeSouza NM. Diffusion Weighted Magnetic Resonance Imaging and Its Application to Cancer. *Cancer Imaging* 2006; 6:135-143. (PMID: 17015238) [\[CrossRef\]](#)