



Should we continue to administer blind shoulder injections?

Kör omuz enjeksiyonu yapmaya devam etmeli miyiz?

Mehmet Ağırman, MD.,¹ Merve Akdeniz Leblebicier, MD.,² Oğuz Durmuş, MD.,¹
İlknur Saral, MD.,¹ Osman Hakan Gündüz, MD.²

¹Department of Physical Medicine and Rehabilitation, Medical Faculty of İstanbul Medipol University, İstanbul, Turkey

²Department of Physical Medicine and Rehabilitation, Medical Faculty of Marmara University, İstanbul, Turkey

ABSTRACT

Objectives: This study aims to investigate the accuracy and effectiveness of blind and fluoroscopic-guided intra-articular shoulder injections in patients with shoulder pain.

Patients and methods: The study included 17 patients (6 males, 11 females; mean age 52.6±9.9 years; range 36 to 66 years) with shoulder pain more than three months. First intra-articular joint injections were performed with anterior approach blindly. Following the injection and after confirming that the needle tip was intra-articular with fluoroscopy and contrast distribution, the procedure was completed using 3 mL of local anesthetic (prilocaine and bupivacaine) and 1 mL of steroid (40 mg methylprednisolone). When the contrast distribution was observed to be extra-articular at the first administration, a second injection was continued under fluoroscopy guidance. All of the injections were intra-articular with the continuation of the procedure. Pain intensity was measured with visual analog scale (VAS).

Results: According to the contrast distribution viewed with fluoroscopy, first blind injections were intra-articular in 11 of the 17 shoulders (64.7%). Mean of initial VAS score was 7.11. Improved pain was observed in the clinical follow-ups at the first hour (mean VAS: 2.35), third day (mean VAS: 2.64), and at the end of the first month (mean VAS: 2.23). The mean durations for blind and fluoroscopic-guided procedures excluding patients' preparation time were 0.8 minutes and 4.2 minutes, respectively.

Conclusion: Although blind intra-articular shoulder injections are inexpensive and easily applicable, injections should be performed under fluoroscopy or another guide to ensure that the needle is intra-articular, not peri-articular.

Keywords: Injection; intra-articular; pain; shoulder.

ÖZ

Amaç: Bu çalışmada omuz ağrısı olan hastalarda kör ve floroskopi rehberli eklem içi omuz enjeksiyonlarının doğruluğu ve etkinliği araştırıldı.

Hastalar ve yöntemler: Çalışmaya üç aydan uzun süredir omuz ağrısı olan 17 hasta (6 erkek, 11 kadın; ort. yaş 52.6±9.9 yıl; dağılım 36-66 yıl) dahil edildi. İlk eklem içi enjeksiyonlar ön yaklaşım ile kör olarak uygulandı. Enjeksiyon sonrası iğne ucunun eklem içerisinde olduğu floroskopi ve kontrast dağılımı ile doğrulandıktan sonra işlem 3 mL lokal anestetik (prilokain ve bupivakain) ve 1 mL steroid (40 mg metilprednizolon) ile tamamlandı. İlk uygulamada kontrast dağılımının eklem dışı olduğu gözlemlendiğinde, ikinci enjeksiyona floroskopi eşliğinde devam edildi. İşlemin devam ettirilmesi ile tüm enjeksiyonlar eklem içi oldu. Ağrı yoğunluğu görsel analog ölçeği (GAÖ) ile ölçüldü.

Bulgular: Floroskopi ile bakılan kontrast dağılımına göre, 17 omuzun 11'inde (%64.7) birinci kör enjeksiyonlar eklem içi idi. Başlangıç GAÖ skoru ortalaması 7.11 idi. Klinik takiplerde birinci saatte (ortalama GAÖ: 2.35), üçüncü günde (ortalama GAÖ: 2.64) ve birinci ayın sonunda (ortalama GAÖ: 2.23) ağrı iyileşme gözlemlendi. Kör ve floroskopi rehberli uygulama için hasta hazırlanma süresi dışındaki ortalama süre sırasıyla 0.8 dakika ve 4.2 dakika idi.

Sonuç: Kör eklem içi omuz enjeksiyonları ucuz ve kolay uygulanabilir olsa da iğnenin eklem çevresinde değil eklem içinde olduğundan emin olmak için enjeksiyonlar floroskopi ya da başka bir rehber eşliğinde yapılmalıdır.

Anahtar sözcükler: Enjeksiyon; eklem içi; ağrı; omuz.

Shoulder pain is a common complaint with many causes including adhesive capsulitis, impingement syndrome, rotator cuff diseases, osteoarthritis, and bicipital tendinitis. The most important clinical sign of adhesive capsulitis is pain and a limited range of motion in the shoulder joint. Pain management includes non-steroidal anti-inflammatory drugs, physical therapy, and intra-articular injections.^[1] Intra-articular injections are widely used to treat shoulder pain and can be administered blindly using anatomical or imaging guidance techniques such as ultrasound (US) or fluoroscopy (FL).^[2,3] In daily practice, most of the intra-articular injections have been performed blindly for many years. However, performing the injections to the wrong place may reduce the effectiveness of treatment. Previous studies have demonstrated that injections under guidance are more effective.^[4,5] Blind injections are usually well-tolerated, inexpensive, and do not involve radiation or require special equipment. On the other hand, the needle position in the joint is not known during blind injections, which represents a significant disadvantage. In this study, we aimed to investigate the accuracy and effectiveness of blind and FL-guided intra-articular shoulder injections in patients with shoulder pain.

PATIENTS AND METHODS

Seventeen patients (6 males, 11 females; mean age was 52.6 ± 9.9 years; range 36 to 66 years) with shoulder pain more than three months were included in the study between January 2014 and July 2014. All patients signed written informed consent forms to participate in the study, which was approved by the local Ethics Committee of Marmara University, Faculty of Medicine. The study was conducted in accordance with the principles of the Declaration of Helsinki. The exclusion criteria were previous shoulder trauma or surgery, pregnancy, intra-articular injection for last three months, history of allergies to steroids, local anesthetics or contrast agents, and infection. Intra-articular joint injections were performed using an anterior approach by a single, highly trained specialist. Patients were seated on a table with their shoulder slightly externally rotated.^[6] The needle was placed to the lateral edge of coracoid and directed posteriorly towards the glenohumeral joint. Injections were performed using a 21 gauge (0.8x38 mm) needle without a stylet (Figure 1). The tip of the needle was checked with 1 mL contrast agent (iohexol) at the end of the procedure, at which time FL images were taken. Following confirmation that the needle tip was intra-articular (Figure 2), the procedure was completed using 3 mL of local anesthetic (prilocaine

and bupivacaine) and 1 mL of steroid (40 mg methylprednisolone). If the contrast distribution was observed to be extra-articular, a second injection was administered under FL guidance, followed by local anesthetic and steroid. Calculation of procedure durations was started after the preparation of patients and drugs, and finished when the intra-articular contrast distribution was seen. Pain intensity was measured with visual analog scale (VAS) (0 to 10) at the beginning of the study, at the first hour, on third day, and at the end of the first month.

RESULTS

Eight patients (47%) (6 females and 2 males) had adhesive capsulitis while nine patients (53%) (5 females and 4 males) had impingement syndrome (Table I). In 11 of the 17 shoulders (64.7%), the blind injection was intra-articular at first application as confirmed by the fluoroscopic contrast distribution. Four of the six shoulders (66.6%) subjected to FL-guided injections were intra-articular on the first attempt. One of the injections was achieved at second attempt and the other was successful at third attempt. The average VAS score was 7.11 before the injections. In the clinical follow-ups, improved pain was observed at the first hour (mean VAS score: 2.35), third day (mean VAS score: 2.64), and at the end of the first month (mean VAS score: 2.23) in all patients except

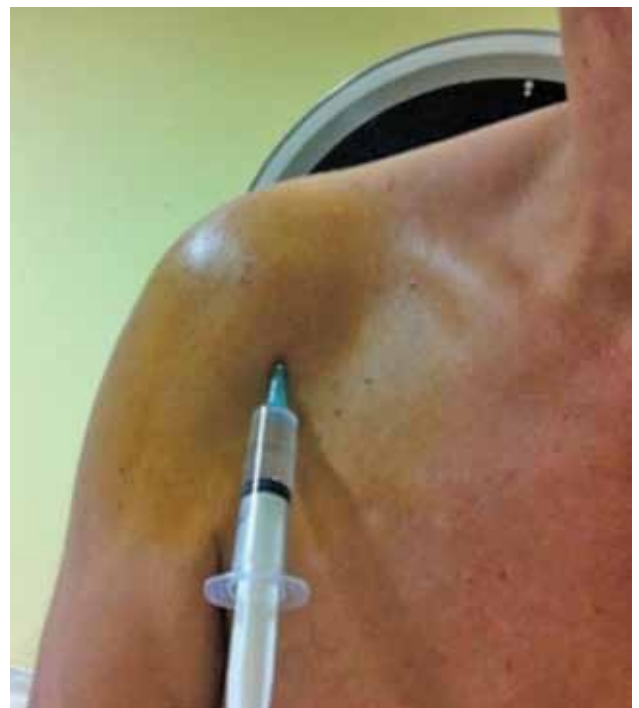

Figure 1. Intra-articular shoulder injection. Injections were performed with anterior approach.

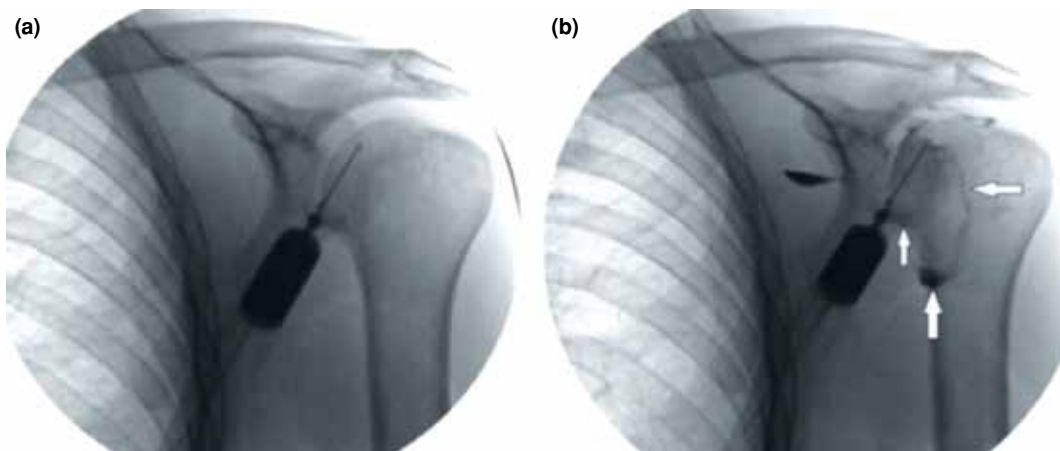


Figure 2. (a) Fluoroscopic image shows shoulder specimen and needle before injection of contrast material. (b) A fluoroscopic image after contrast injection. Distribution of contrast agent in joint capsule confirms an accurate injection (white arrows).

one (Table II). The mean durations of procedures for blind and FL-guided injections were 0.8 minutes and 4.2 minutes, respectively. No complications were observed during or after the procedures.

DISCUSSION

The main goal in the treatment of shoulder disorders is to reduce pain and increase range of motion. Non-operative treatment of adhesive capsulitis and impingement syndrome comprises anti-inflammatory drugs, exercise, physical therapy, and intra-articular injections.^[7,8] Injections are recommended via the

anterior, posterior or supraclavicular approach.^[9] Tong et al.^[10] investigated anterior and posterior approach to penetrate the glenohumeral joint with a standard 21-gauge needle. They showed that the mean joint depth was 43.5 mm at posterior and 27.1 mm at anterior side. Therefore, access into the joint is more likely through an anterior procedure. Also, Tobola et al.^[6] argue that the anterior approach was the most accurate, independently of the level of experience of the clinician. Blind intra-articular injections are accurate in 26 to 97% of occasions according to previous reports.^[11,12] In the present study, the accuracy of blind injection at first attempt was similar with the studies in the literature. In one-third of blind applications, the needle was extra-articular. Therefore, FL or US-guided injections are recommended for accurate intra-articular access. In a cadaver study, 92.5% of US-guided injections and 72.5% of blind injections accurately reached to glenohumeral joint.^[13] In another study, Uuncu et al.^[5] compared US with landmark-guided injection in a randomized study and demonstrated significantly improved pain intensity in US group compared with blind group six weeks after injection (mean VAS score decrease: 4.0 ± 1.7 for US vs. 2.2 ± 0.9 for blind). Rutten et al.^[14] compared FL with US-guided intra-articular shoulder injections and reported 76% accuracy in FL and 96% in US on the first attempt using an anterior approach.

However, to our knowledge, no previous study has compared blind and FL-guided injections in shoulder pain. Accuracy of the FL-guided injections was 66.6% at first attempt and 100% at second attempt in our study. Furthermore, no difference was detected at first entry in fluoroscopic injection

TABLE I

Patients' characteristics and diagnoses

	Diagnosis	Age/gender	Side
1	Impingement syndrome	63/F	Right
2	Impingement syndrome	66/M	Left
3	Impingement syndrome	50/F	Left
4	Impingement syndrome	58/F	Right
5	Impingement syndrome	37/M	Left
6	Adhesive capsulitis	54/F	Left
7	Adhesive capsulitis	62/F	Left
8	Adhesive capsulitis	56/E	Right
9	Adhesive capsulitis	47/F	Right
10	Adhesive capsulitis	40/F	Left
11	Adhesive capsulitis	42/F	Right
12	Impingement syndrome	61/M	Right
13	Impingement syndrome	66/F	Right
14	Impingement syndrome	36/M	Right
15	Impingement syndrome	47/F	Right
16	Adhesive capsulitis	63/F	Right
17	Adhesive capsulitis	47/M	Right

TABLE II
Accuracy of injections and outcomes

	Without fluoroscopy	After fluoroscopic imaging	VAS before injection	VAS after 1 hour	VAS after 3 day	VAS after 1 month
1	Done	–	8	3	2	3
2	Done	–	7	0	0	0
3	Done	–	6	0	3	3
4	Done	–	5	0	0	0
5	Done	–	7	1	0	1
6	Done	–	9	0	1	1
7	Done	–	5	0	5	3
8	Done	–	5	0	0	0
9	Done	–	9	5	3	3
10	Done	–	5	2	4	2
11	Done	–	7	1	0	1
12	None	First attempt	7	7	4	3
13	None	Third attempt	8	0	4	2
14	None	First attempt	8	8	9	8
15	None	Second attempt	8	3	3	4
16	None	First attempt	7	4	0	0
17	None	First attempt	10	10	7	4

VAS: Visual analog scale.

compared with the blind. However, with continued procedure, all of the injections were successful with the fluoroscopic guide, suggesting that procedures should be accompanied by a guide.

Many studies indicate that superior and earlier improvement in shoulder pain and increased range of motion in the shoulder joint are possible with US-guided injections compared to blind injections.^[2,5,14] In our study, clinically improved pain was observed in all patients except one. Decrease in VAS scores continued for one month. According to our opinion, reduced pain supports the accuracy of fluoroscopic injections. There were no complications during the study. However, theoretically, the most serious complication is septic arthritis. Furthermore; skin atrophy, tendon rupture, post-injection flare, and effects of systemic absorption may occur after intra-articular steroid injections. Analysis of durations for both injections demonstrated that guided applications were more time consuming than blind applications. One may gain time in blind injections since there is no requirement to check the needle during the procedure. However, if the needle is not in the right place, the procedure may not achieve its purpose.

In this study, we assessed the accuracy of blind injection and we confirmed the results with fluoroscopic imaging. Also, we associated 'achieved injections' with decreased pain intensity. Despite the

study's limitations including small sample size and absence of functional evaluation of the shoulder, these results have clinical importance. Exposure to ionizing radiation is the most important disadvantage of FL. Additionally; fluoroscopic injections require more equipment by contrast with blind injections. Our study may provide contribution for future studies with larger number of patients.

In conclusion, although blind injections are inexpensive and easily applicable, FL or other guided injections should be considered to ensure that the needle is intra-articular, not peri-articular.

Declaration of conflicting interests

The authors declared no conflicts of interest with respect to the authorship and/or publication of this article.

Funding

The authors received no financial support for the research and/or authorship of this article.

REFERENCES

1. Çift H, Özkan FÜ, Tolu S, Şeker A, Mahiroğulları M. Comparison of subacromial tenoxicam and steroid injections in the treatment of impingement syndrome. *Eklem Hastalık Cerrahisi* 2015;26:16-20.
2. Soh E, Li W, Ong KO, Chen W, Bautista D. Image-guided versus blind corticosteroid injections in adults with shoulder pain: a systematic review. *BMC Musculoskeletal Disord* 2011;12:137.

3. Speed CA. Injection therapies for soft-tissue lesions. *Best Pract Res Clin Rheumatol* 2007;21:333-47.
4. Gruson KI, Ruchelsman DE, Zuckerman JD. Subacromial corticosteroid injections. *J Shoulder Elbow Surg* 2008;17:118-130.
5. Ucuncu F, Capkin E, Karkucak M, Ozden G, Cakirbay H, Tosun M, et al. A comparison of the effectiveness of landmark-guided injections and ultrasonography guided injections for shoulder pain. *Clin J Pain* 2009;25:786-9.
6. Tobola A, Cook C, Cassas KJ, Hawkins RJ, Wienke JR, Tolan S, et al. Accuracy of glenohumeral joint injections: comparing approach and experience of provider. *J Shoulder Elbow Surg* 2011;20:1147-54.
7. Başar S, Kanatlı U, Cıtaker S, Bölükbaşı S. Does presence of anterior greater tuberosity cysts change the function in patients with chronic rotator cuff tear? *Eklemler Hastalıkları Cerrahisi* 2014;25:141-7.
8. Esenyel CZ, Esenyel M, Yeşiltepe R, Ayanoğlu S, Bülbül M, Sirvanci M, et al. The correlation between the accuracy of steroid injections and subsequent shoulder pain and function in subacromial impingement syndrome. [Article in Turkish] *Acta Orthop Traumatol Turc* 2003;37:41-5.
9. Sidon E, Velkes S, Shemesh S, Levy J, Glaser E, Kosashvili Y. Accuracy of non assisted glenohumeral joint injection in the office setting. *Eur J Radiol* 2013;82:829-31.
10. Tong A, Harding R, Graham G. Glenohumeral joint penetration with a 21-gauge standard needle. *J Shoulder Elbow Surg* 2012;21:1-3.
11. Sibbitt WL Jr, Peisajovich A, Michael AA, Park KS, Sibbitt RR, Band PA, et al. Does sonographic needle guidance affect the clinical outcome of intraarticular injections? *J Rheumatol* 2009;36:1892-902.
12. Arroll B, Goodyear-Smith F. Corticosteroid injections for painful shoulder: a meta-analysis. *Br J Gen Pract* 2005;55:224-8.
13. Patel DN, Nayyar S, Hasan S, Khatib O, Sidash S, Jazrawi LM. Comparison of ultrasound-guided versus blind glenohumeral injections: a cadaveric study. *J Shoulder Elbow Surg* 2012;21:1664-8.
14. Rutten MJ, Collins JM, Maresch BJ, Smeets JH, Janssen CM, Kiemeny LA, et al. Glenohumeral joint injection: a comparative study of ultrasound and fluoroscopically guided techniques before MR arthrography. *Eur Radiol* 2009;19:722-30.