



# THE PREVENTION EFFECT OF N-ACETYLCYSTEINE ON EPIDURAL FIBROSIS IN THE POST-LAMINECTOMY RAT MODEL

Yahya GÜVENÇ<sup>1</sup>,  
Mesut Emre YAMAN<sup>2</sup>,  
Yaşar ÖZTÜRK<sup>3</sup>,  
Gülüşan ERGÜL<sup>4</sup>,  
Fatma Kübra ERBAY<sup>5</sup>,  
Tolga TOLUNAY<sup>6</sup>,  
Güner MENEKŞE<sup>7</sup>,  
Abdullah ÖZCAN<sup>8</sup>,  
Erkan KAPTANOĞLU<sup>1</sup>

<sup>1</sup>Marmara University, School of Medicine, Department of Neurosurgery, İstanbul, Turkey.

<sup>2</sup>Gazi University, School of Medicine, Department of Neurosurgery, Ankara, Turkey.

<sup>3</sup>Yenimahalle Training and Education Hospital, Department of Neurosurgery, Ankara, Turkey.

<sup>4</sup>Yenimahalle Training and Education Hospital, Department of Pathology, Ankara, Turkey.

<sup>5</sup>TOBB University of Economics and Technology, Department of Micro and Nanotechnology, Ankara, Turkey.

<sup>6</sup>Yenimahalle Training and Education Hospital, Department of Orthopaedics, Ankara, Turkey.

<sup>7</sup>Ankara Training and Education Hospital, Department of Neurosurgery, Ankara, Turkey.

<sup>8</sup>Marmara University, Neuroscience Institute, Department of Anesthesiology, İstanbul, Turkey.

## ORCID Numbers:

Yahya GUVENC: 0000-0002-4813-0854  
Mesut Emre YAMAN: 0000-0003-0049-1316  
Yaşar ÖZTÜRK: 0000-0003-0923-5941  
Gulusan ERGUL: 0000-0002-6631-6118  
Fatma Kubra ERBAY: 0000-0002-4117-1098  
Tolga TOLUNAY: 0000-0003-1998-3695  
Guner MENEKSE: 0000-0002-5912-6949  
Abdullah OZCAN: 0000-0002-2625-6325  
Erkan KAPTANOĞLU: 0000-0002-9945-8817

**Address:** Yahya Güvenç,  
Marmara University, School of Medicine,  
Department of Neurosurgery, Basıbüyük  
Health Campus, Maltepe, İstanbul, Turkey.

**Phone:** +90 505 899 46 39

**E-Mail:** dr.yahyaguvenc@gmail.com

**Received:** 24<sup>th</sup> January, 2018.

**Accepted:** 16<sup>th</sup> May, 2018.

## ABSTRACT

**Aim:** The development of epidural fibrosis after laminectomy lead to postoperative morbidities, persistent radicular pain and failed back syndrome. Various materials or drugs have been used to inhibit formation of epidural fibrosis and reduce the compressive effect on neural structures. Nevertheless, the effects are not satisfied. NAC has mucolytic, antioxidant and anti-inflammatory effect. The aim of this study was to evaluate the effect of NAC on spinal epidural fibrosis in the post-laminectomy rat model.

**Methods:** Twenty-four albino rats were divided randomly into three equal groups: control, spongostan and Local NAC. Each animal underwent a laminectomy. Local NAC group (n=8): 100mg/kg was locally applied with a spongostan soaked with 0,5 ml of the solution and was left on the dura mater. At 4 weeks post surgery, the animals euthanized and their tissue samples at the laminectomy site were assessed histological evaluation for dura thickness, epidural fibrosis grading, inflammatory response grading and presence of arachnoidal involvement. All data were evaluated by statistically.

**Results:** Epidural fibrosis were observed significant lower in the NAC group when compared with control group (p= 0.001) . Inflammatory cell density was significant lower in the NAC group when compared with control and spongostan group (p=0.001 and p=0.015, respectively). Arachnoidal involvement was not observed in NAC group. The differences between all groups weren't statistically significant for dura thickness and fibroblastic density (p=0.162 and p=0.056, respectively, Kruskal Wallis test)

**Conclusion:** The results of our study suggested that NAC has anti-fibrotic effects on epidural fibrosis in the post-laminectomy rat model.

**Keywords:** NAC, Laminectomy, Epidural fibrosis, Histopathology

**Level of Evidence:** Experimental animal study, Level II

## INTRODUCTION

Laminectomy is widespread treatment for spinal disorders. The development of epidural fibrosis after laminectomy lead to postoperative morbidities, persistent radicular pain and failed back syndrome<sup>(16)</sup>. Fibrosis is taking the place of epidural fat with fibrotic tissue, which binds the dura mater and the nerve roots to the anterior and posterior of vertebral structures<sup>(5)</sup>. Epidural fibrosis leads to difficulties in revision surgery because of that iatrogenic nerve root injury or dura mater tear may seen highyl in revision surgeries. Various biological

or nonbiological materials were used to prevent epidural fibrosis but satisfactory results havent achived, yet. Because of that preventing, the occurrence of Epidural fibrosis is still a great problem for surgeons and patients.

N-Acetylcysteine (NAC) is a thiol-containing radical scavenger and glutathione precursor. NAC has mucolytic, antioxidant and anti-inflammatory effect<sup>(3,14)</sup>.

Some previous studies have indicated that NAC has beneficial effects in clinical conditions which free radicals

are involved, and it has been reported to attenuate pulmonary fibrosis, liver fibrosis and skin fibrosis in experimental studies<sup>(4,10,21-22)</sup>.

The aim of this study was to evaluate the effect of NAC on spinal epidural fibrosis in the post-laminectomy rat model.

## MATERIAL AND METHODS

### Animals

Adult, male, 24 Wistar Albino rats weighing 250-350g were used for this study. The experimental part of the study was conducted at the Ankara Training and Research Hospital laboratory after obtaining consent from the Ankara Training and Research Hospital Animal Experiments Local Ethics Committee. All subjects were kept under stable and standard environmental conditions during the experiment and were fed on standard animal food and water.

### Operative procedure

Each animal underwent a laminectomy. Surgery was conducted with the animals under general anesthesia using xylazine (10 mg/kg, Rompun, Bayer, and Turkey) and ketamine hydrochloride (50 mg/kg, Ketalar, Parke Davis, Turkey) administered intraperitoneally. The rats were placed in the prone position. The lumbar area of the rat was shaved then prepared in a sterile manner using povidone-iodine solution. All of the operative procedures were performed using a surgical microscope (Zeiss OPMI- Carl Zeiss Meditec Company, Oberkochen, Germany) by the same surgeon (YG). A longitudinal mid-line skin incision was made over the L1-L3 levels and carried down to the spinous process.

At the L1-L3 level total laminectomy was performed. The ligamentum flavum and epidural fat were removed. The dura mater was fully exposed and the hemostasis was obtained by using cotton sheet. After the application of the topical agents, the wounds were closed in anatomical layers using the same 4-0 Prolene polypropylene sutures (Ethicon; Ethicon Endo-Surgery, Inc., Cincinnati, OH, USA). There were no complications, wound infections or any adverse effects observed relevant to NAC. The animals were euthanized on the 4 weeks postoperative day using a lethal dose of pentobarbital (60 mg/kg, IE. Ulagay, Istanbul, Turkey).

**Experimental Groups:** All rats were randomly divided into three groups.

**Control group (n=8):** only laminectomy was performed without treatment;

**Spongostan group (n=8):** a spongostan (Ethicon Endo-Surgery, Inc.) soaked with 2cc/kg saline solution and was left on the dura mater after laminectomy.

**Local Nac group (n=8):** 100mg/kg was locally applied with a spongostan soaked with 0,5 ml of the solution and was left on the dura mater.

### Histopathological Evaluation

Vertebral columns were fixed 10% buffered formalin for 1 week, and then were decalcified for 5 days in Biocal C solution. The laminectomy site was identified and four 2-mm-thick sections were obtained. Sections were embedded in paraffin and serial sections (5µm) were cut with microtome and stained with Hematoxylin Eosin (HE) and Masson Trichrome (MT). A pathologist under the Nikon Eclipse 80i light microscope as regards dural thickness and epidural fibrosis evaluated all laminectomized spine sections in a blinded manner. Quantitative morphometric analysis was performed on sections using the Nikon Nis Elements D 3.1 Digital Analyzing System. Epidural fibrosis was evaluated as described by He and colleagues<sup>(6)</sup> (Table-1). Fibroblast cell density was evaluated as described by Sen and colleagues<sup>(15)</sup> (Table-2).

**Table-1.** Epidural fibrosis grading table. (He et al.)

Grade	Explanation
0	Dura mater was free of scar tissue
1	Only thin fibrosis bands between the scar tissues and the dura mater were observed.
2	Continuous adhesion was observed but made up less than two-thirds of the laminectomy defect
3	Scar adhesion was large and involved more than two-thirds of the laminectomy defect, and/or extended to the nerve roots.

**Table-2.** Fibroblast cell density scoring system.

Grade	Cell density
Grade 1	<100 cells in each area at x400
Grade 2	100-150 cells in each area at x400
Grade 3	>150 cells in each area at x400

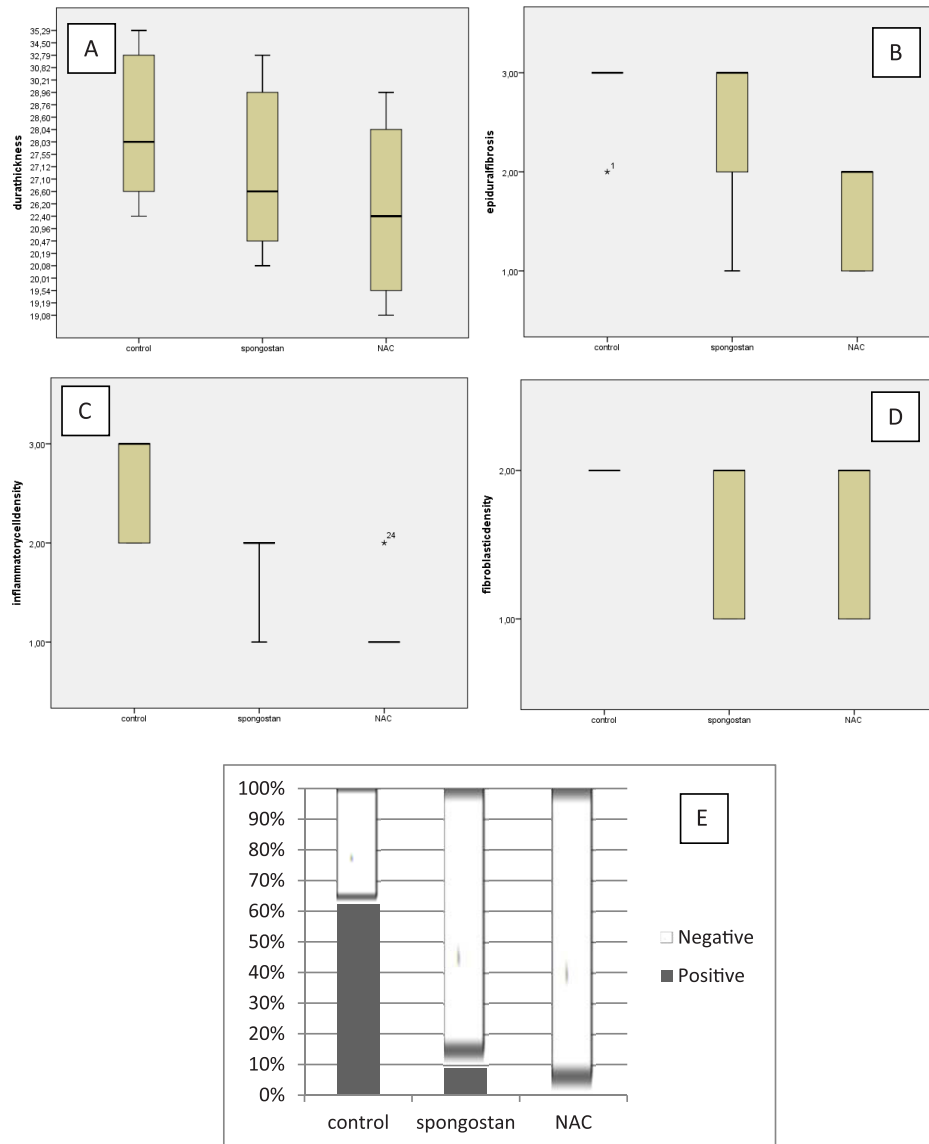
### Statistical analysis

All data were analyzed using SPSS for Windows version 11.5 (SPSS, Inc., Chicago, IL, USA). The Shapiro Wilk test was used to determine if the distributions of continuous variables were normal. The nonparametric Kruskal Wallis test was used to compare differences in groups, the Mann Whitney U Test was used to determine the differences between subgroups. The presence of arachnoidal involvement was analyzed using a likelihood ratio test. A p value less than 0.05 was considered statistically significant.

## RESULTS

There was not seen any rat mortality related to study. There was no case with neurologic deficits or cerebrospinal leak in any of the rats. All animals were ambulatory during the study.

The mean thickness of dura were 0,024 mm in NAC group, 0,025 mm in spongostan group and 0,028 mm in control group. The differences between all groups weren't statistically significant for dura thickness and fibroblastic density ( $p=0.162$  and  $p=0.056$ , respectively, Kruskal Wallis test) (Figure.1-A, 1-C, Table-3).



**Figure-1. (A)** Comparison of dural thickness among groups. The horizontal lines in the middle of each box indicate the median, whereas the top and bottom borders of the box mark the 25th and 75th percentiles, respectively. The whiskers above and below the box mark the maximum and minimum dural thickness. **(B)** Comparison of epidural fibrosis grades among groups. The horizontal lines in the middle of each box indicate the median, whereas the top and bottom borders of the box mark the 25th and 75th percentiles, respectively. The whiskers above and below the box mark the maximum and minimum epidural fibrosis grades. Asterisks represent extreme cases. **(C)** Comparison of fibroblastic density grades among groups. The horizontal lines in the middle of each box indicate the median, whereas the top and bottom borders of the box mark the 25th and 75th percentiles, respectively. The whiskers above and below the box mark the maximum and minimum fibroblastic density grades. **(D)** Comparison of inflammatory cell density grades among groups. The horizontal lines in the middle of each box indicate the median, whereas the top and bottom borders of the box mark the 25th and 75th percentiles, respectively. The whiskers above and below the box mark the maximum and minimum inflammatory cell density grades. Asterisks represent extreme cases. **(E)** Comparison of arachnoidal involvement among groups. The light bars indicate the ratio of arachnoidal involvement negative within each group, the prevalence of arachnoidal involvement positive was shown as solid bars.

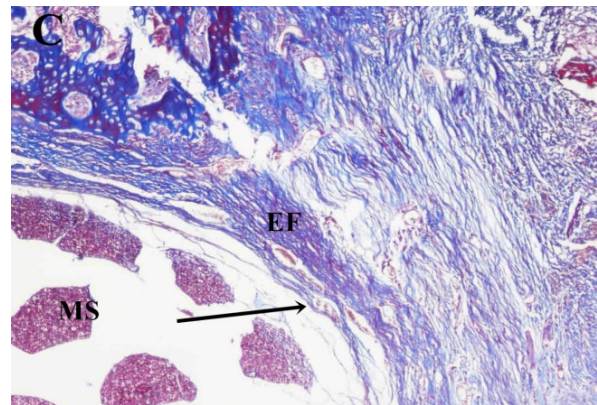
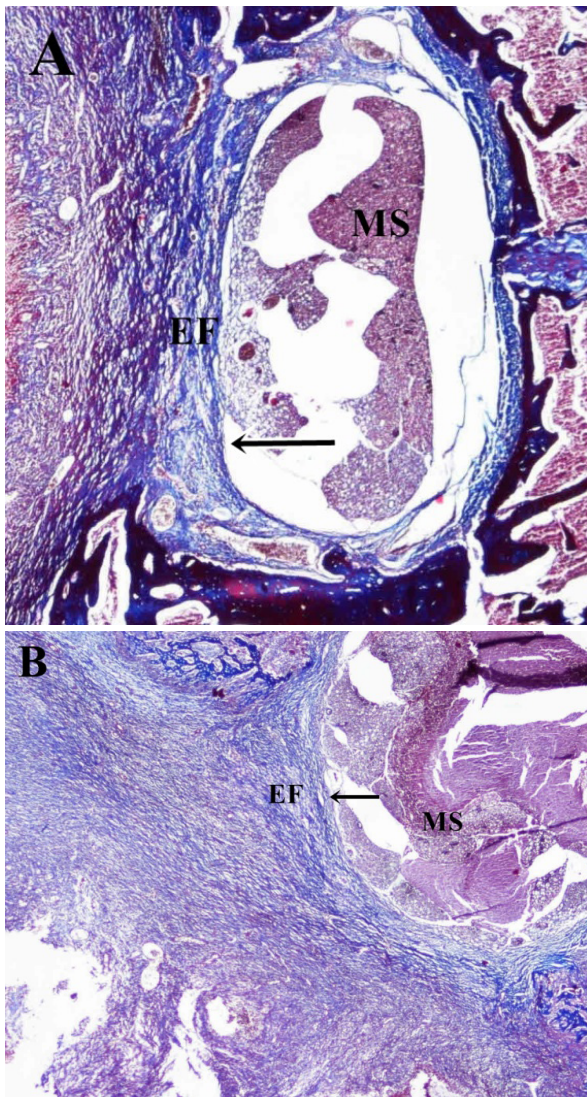
In NAC group, Grade-1 and Grade-2 epidural fibrosis were observed in equal rate (% 50). In spongostan group, Grade-1, Grade-2 and Grade-3 epidural fibrosis were found in % 25, % 25 and % 50 of the rats, respectively. Grade-2 and Grade-3 epidural fibrosis were observed in % 12.5 and % 87.5 of the rats, respectively in the control group.

The difference between the spongostan and both the NAC and control group wasn't statistically significant ( $p=0.74$  and  $p=0.095$ , respectively). Statistically significant difference was determined between the NAC and control group ( $p= 0.001$ ) (Figure-1.B, Table-3).

In NAC group, Grade-1 and Grade-2 inflammatory cell density were observed in % 12.5 and %87.5 of the rats, respectively. Grade-1 and Grade-2 were observed in % 25 and % 75 of the rats, respectively in spongostan group.

In control group, Grade 2 and Grade 3 inflammatory cell density was detected in equal rate (% 50). When the grade of the control group was compared with NAC and spongostan groups, the differences were statistically significant ( $p=0.001$  and  $p=0.015$ , respectively). The difference between the NAC and spongostan group was also statistically significant ( $p=0.015$ ) (Figure-1.D, Table-3).

Arachnoidal involvement was not observed in NAC group. A few rats in the spongostan group (% 50) and control group (% 62.5) demonstrated arachnoidal involvement. The differences between the NAC and both control and spongostan group was statistically significant ( $p=0.009$  and  $p=0.025$ ). There was not statistically difference between the spongostan and the control group up ( $p=0.626$ ) (Figure-1E, Table-3).



**Figure-2.** Photomicrographs of the study (Masson's Trichrome, x40 objective) **(A)** Grade-3 epidural fibrosis (EF) from Control group. EF covered the whole laminectomy defect and adhered to the underlying Dura mater (black arrow). Grade 3 fibrosis is observed in most of the specimens in Control group. **(B)** Grade-2 epidural fibrosis specimen from Spongostan group. Epidural fibrosis adhered the underlying Dura (black arrow) and covered less than two-thirds of the laminectomy defect. **(C)** In the NAC group Grade-1 fibrosis is adherent to the underlying Dura (black arrow) without direct contact to the medulla spinalis (MS).

<b>Table-3. Result of Statistical analysis</b>				
Variables	Control	Spongostan	NAC	P value <sup>1</sup>
Dural thickness	28.03 (22.40-35.29)	26.60 (20.08-32.79)	22.40 (19.08-28.96)	0.162
Epidural fibrosis	3 (2-3) <sup>b</sup>	3 (1-3)	2 (1-2) <sup>b</sup>	0.003
Fibroblastic density	2	2 (1-2)	2 (1-2)	0.056
Inflammatory cell density	3 (2-3) <sup>b,c</sup>	2 (1-2) <sup>a,c</sup>	1 (1-2) <sup>a,b</sup>	0.001
Arachnoid involvement	5/3 <sup>b</sup>	4/4 <sup>a</sup>	0/8 <sup>a,b</sup>	0.028

Data were represented as median (25-75 percentile).

<sup>1</sup> Kruskal-Wallis test

<sup>a</sup> NAC group versus the spongostan group (p<0.05)

<sup>b</sup> NAC group versus the control group (p<0.01)

<sup>c</sup> Spongostan group versus the control group (p=0.015)

## DISCUSSION

Postoperative fibrosis is a expected outcome of surgical wound healing and it arise from the disrupted intervertebral disc and muscles in the surgical wound<sup>(8,20)</sup>. This fibrotic tissue may extend to epidural space when laminectomy performed. The development of epidural fibrosis after laminectomy lead to postoperative morbidities, persistent radicular pain and failed back syndrome<sup>(16)</sup>. Radicular pain is caused by leading compression or tethering the nerve roots and movement of vertebral column increased stretch so the pain is intensified<sup>(1,19)</sup>. The best solution to this problem is preventing EF formation.

Some mechanisms have been aimed to explain the presence of post-laminectomy EF. LaRocca and colleagues have suggested that fibrosis originates from the posterior invasion of fibroblasts, extending from the erector spinae muscle to the dura and then growing into the haematoma<sup>(9)</sup>. Holtz at all. have suggested that the fibrosis formation and separation of fibrin are prevented by a physical barrier and inhibition of fibroblast proliferation<sup>(7)</sup>.

A lot of drugs and agents have been studied to prevent EF, but experiments showed that they still have some limitations before clinical use.

NAC has mucolytic, antioxidant and anti-inflammatory effect. NAC acts as a cysteine precursor for the synthesis of glutathione (GSH), it changes intracellular GSH levels and increasing the antioxidant protection of the cells<sup>(12)</sup>. Reactive oxygen species (ROS) include the superoxide anion (O<sub>2</sub><sup>-</sup>), hydrogen peroxide (H<sub>2</sub>O<sub>2</sub>), and hydroxyl radicals (OH). The high ROS levels induce oxidative stress and inflict cell damage. NAC inhibit ROS production trough anjiotensin-2 blocage and increasing the antioxidant protection of the cells. It may help reduce the inflammation process. NAC *suppresses* the EF through antioxidant and antiinflamatur effect<sup>(18)</sup>.

We have hypothesized that NAC may have preventive effects on epidural fibrosis via anti-inflammatory and antioxidant effects. We have showed that epidural

fibrosis was significantly lower in the NAC group when we compare with the Control group. Inflammatory cell density and arachnoidal involvement were lower in the NAC group when we compared with the control and Spongostan group. These are important evidence for our hypothesis.

There are some studies in the litrature which explain NAC attenuate fibrosis in different experimental study. NAC decrease interstitial fibrosis, indicating that ROS elimination effectively slowed the progression of renal fibrosis in mice<sup>(18)</sup>. Administration of oral NAC increased intracellular and extracellular glutathione levels so NAC therapy may be delay idiopatic pulmoner fibrosis progression<sup>(13)</sup>. Liu at all. have showed that NAC blocked hyperglycemia promoted induced cardiac fibroblast proliferation and myofibroblast differentiation on mice. (Cong Liu) Several studies have shown that NAC could be used for the treatment of pulmonary fibrosis, liver fibrosis, and skin fibrosis<sup>(4,10,21-22)</sup>.

As a results of a macroscopic scoring system, histological evaluation showed that NAC suppressed the EF in rats. Our finding first demonstrated the beneficial effect of topical application of NAC in laminectomy models. Nevertheless, the efficacy of this agent should be further explored in additional experimental and clinical studies.

## Conflict of interest

The authors have no conflicts of interest.

## REFERENCES

1. Andrychowski J, Frontczak-Baniewicz M, Sulejczak D, Kowalczyk T, Chmielewski T, Czernicki Z, Kowalewski TA. Nanofiber nets in prevention of cicatrization in spinal procedures. Experimental study. *Folia Neuropathol* 2013; 51: 147-157.
2. Atkuri KR, Mantovani JJ, Herzenberg LA. N-Acetylcysteine—a safe antidote for cysteine/glutathione deficiency. *Curr Opin Pharmacol* 2007; 7: 355–359.

3. Cazzola M, Calzetta L, Facciolo F, Rogliani P, Matera MG. Pharmacological investigation on the anti-oxidant and anti-inflammatory activity of N-acetylcysteine in an ex vivo model of COPD exacerbation. *Respir Res* 2017; 18: 26.
4. Demiroren K, Dogan Y, Kocamaz H, Ozercan IH, Ilhan S, Ustundag B, Bahcecioglu IH. Protective effects of L-carnitine, N-acetylcysteine and genistein in an experimental model of liver fibrosis. *Clin Res Hepatol Gastroenterol* 2014; 38: 63–72.
5. de Tribolet N, Porchet F, Lutz TW, Gratzl O, Brotchi J, van Alphen HA, van Acker RE, Benini A, Strommer KN, Bernays RL, Goffin J, Beuls EA, Ross JS. Clinical assessment of a novel antiadhesion barrier gel: prospective, randomized, multicenter, clinical trial of ADCON-L to inhibit postoperative peridural fibrosis and related symptoms after lumbar discectomy. *Am J Orthop* 1998; 27: 111-120.
6. He Y, Revel M, Loty B. A quantitative model of post-laminectomy scar formation: effects of a nonsteroidal anti-inflammatory drug. *Spine* 1995; 20: 557-563.
7. Holtz G. Prevention of postoperative adhesions. *J Reprod Med* 1980; 24: 141-146
8. Key JA, Ford LT. Experimental intervertebral-disc lesions. *J Bone Joint Surg* 1948; 30-A: 621-630.
9. LaRocca H, MacNab I. The laminectomy membrane: studies in its evaluation, characteristics, effects and prophylaxis in dogs. *J Bone Joint Surg* 1947; 56-B: 545-550.
10. Lee JS, McLaughlin S, Collard HR. Comprehensive care of the patient with idiopathic pulmonary fibrosis. *Curr Opin Pulm Med* 2011; 17: 348–354.
11. Liu C, Lu XZ, Shen MZ, Xing CY, Jing M, Yun YD, Yuan LJ. N-Acetyl Cysteine improves the diabetic cardiac function: possible role of fibrosis inhibition. *BMC Cardiovascular Disord* 2015; 15: 84.
12. Matera MG, Calzetta L, Cazzola M. Oxidation pathway and exacerbations in COPD: the role of NAC. *Expert Rev Respir Med* 2016; 10: 89–97.
13. Muramatsu Y, Sugino K, Ishida F, Tatebe J, Morita T, Homma S. Effect of inhaled N-acetylcysteine monotherapy on lung function and redox balance in idiopathic pulmonary fibrosis. *Respir Investig* 2016; 54(3): 170-178.
14. Sadowska AM, Verbraecken J, Darquennes K, DeBacker WA. Role of N-acetylcysteine in the management of COPD. *Int J Chronic Obstr Pulm Dis* 2006; 1: 425–434.
15. Sen O, Kizilkilic O, Aydin MV, Yalcin O, Erdogan B, Cekinmez M, Caner H, Altinors N. The role of closed suction drainage in preventing epidural fibrosis and its correlation with a new grading system of epidural fibrosis based on MRI. *Eur Spine J* 2005; 14: 409-414.
16. Songer MN, Rauschnig W, Carson EW, Pandit SM. Analysis of peridural scar formation and its prevention after lumbar laminotomy and discectomy in dogs. *Spine* 1995; 20: 71-80.
17. Sun Y, Wang L, Sun S, Liu B, Wu N, Cao X. The effect of 10-hydroxycamptothecin in preventing fibroblast proliferation and epidural scar adhesion after laminectomy in rats. *Eur J Pharmacol* 2008; 593: 44-48.
18. Yang S, Miao L, Xu JL, Gan XX, Xu D, Zhou L, Xue H, Zhang W, Lu LM. N-acetylcysteine alleviates angiotensin II-mediated renal fibrosis in mouse obstructed kidneys. *Acta Pharmacol Sinica* 2016; 37: 637–644.
19. Yang J, Ni B, Liu J, Zhu L, Zhou W. Application of liposome-encapsulated hydroxycamptothecin in the prevention of epidural scar formation in New Zealand white rabbits. *Spine J* 2011; 11: 218-223.
20. Yang L, Tang J, Chen H, Ge D, Sui T, Que J, Cao X, Ge Y. Taurine reduced epidural fibrosis in rat models after laminectomy via downregulating EGR1. *Cell Physiol Biochem* 2016; 38: 2261-2271.
21. Zhang L, He YL, Li QZ, Hao XH, Zhang ZF, Yuan JX, Bai YP, Jin YL, Liu N, Chen G. N-acetylcysteine alleviated silica-induced lung fibrosis in rats by down-regulation of ROS and mitochondrial apoptosis signaling. *Toxicol Mech Methods* 2014; 24: 212–219.
22. Zhou CF, Yu JF, Zhang JX, Jiang T, Xu SH, Yu QY, Zhu QX. N-acetylcysteine attenuates subcutaneous administration of bleomycin-induced skin fibrosis and oxidative stress in a mouse model of scleroderma. *Clin Exp Dermatol* 2013; 38: 403–409.