

## Endeavour to gain basic function in a nonsensory stiff hand injured with electrical burn

Mehmet Bekir Unal<sup>1</sup>, Evrim Sirin<sup>2</sup>, Ali Seker<sup>3</sup>, Eren Cansu<sup>4</sup>

### ABSTRACT

Electrical thermal injuries usually result from industrial accidents and have a mortality rate of 3-5%. They might cause functional impairment, loss of extremity and even death. Psychologic impacts can be observed also. A 34 year-old male patient admitted to our institute with an amputated upper extremity on one side and a nonfunctional hand on the contralateral side one year after an electrical injury. He had total sensorial loss on his hand. A two staged operation was planned in order to gain grip function. The first stage was composed of release of contractures of 1st web space and MP joints of 2nd, 3rd, 4th and 5th fingers and restoration of opposition of thumb with opponensplasty. The second stage was composed of restoration of flexion of fingers with tendon grafts and restoration of pinch with adductorplasty. At the end, the patient had a partially functioning hand; at least he was able to hold a pen between his thumb and index finger. Restoration of function and especially tendon transfer in a nonsensory extremity has only very limited indications. However psychological conditions sometimes should be taken into consideration and attempt could be made to gain a basic function.

**Key words:** *Electrical burn; reconstruction; tendon transfer*

### Introduction

Electrical burns are usually work related injuries and they cause thermal harm to the body [1]. The other risk group is children playing near electrical equipments [2,3]. There is a point of entrance and an exit of the current and it results in deep muscle necrosis which might lead to whole extremity burn and even death of the patient. There are approximately 1000 deaths per year due to electrical injuries in the United States [4]. The actual mortality rate is between 3-5%. Following resuscitation, viability of the muscles must be evaluated. At the operation room extended fasciotomies

and even amputation of a whole extremity might be required [4,5]. At the end, the patient might get an irreversibly disabled extremity and repetitive operations and a lifelong psychological impact may be the faith of the patient [6]. We aimed to present a patient who was operated for hand reconstruction after electrical burn.

### Case Report

A 34 year-old male patient was presented to our institute with sequelae in his extremities one year after burn injury due to high voltage electric current contact. The patient's both feet soles were skin grafted and had slight flexion contracture at his right ankle. His domi-

**Author affiliations** : Department of Orthopaedics and Traumatology <sup>1</sup>Bahcesehir University, <sup>2</sup>Fatih Sultan Mehmet Training and Research Hospital, <sup>3</sup>Istanbul Medipol University, <sup>4</sup>Marmara University Pendik Training and Research Hospital, Istanbul, Turkey

**Correspondence** : Ali Seker, MD, Department of Orthopaedics and Traumatology, Istanbul Medipol University, Istanbul, Turkey. e-mail: aliseker@doctor.com

**Received / Accepted** : March 03, 2016 / April 16, 2016

nant right hand was amputated at the level of the proximal forearm because of necrosis and the patient was wearing a uniaxial motorized prosthetic arm for grip function. In his left upper extremity, the shoulder and elbow had full active range of motion. The wrist had an active flexion of 10°, extension of 15° and rotation of 90°. The metacarpophalangeal (MP) joints of 2<sup>nd</sup>, 3<sup>rd</sup>, 4<sup>th</sup> and 5<sup>th</sup> fingers were stiff in extension. Proximal interphalangeal (PIP) and distal interphalangeal (DIP) joints had 90° and 40° passive flexion ranges and full passive extension respectively. The thumb was stiff in adduction and had slight flexion contracture. There was no active motion in carpometacarpal (CMC), MP and interphalangeal (IP) joints. Patient's extensor muscle bellies had substantial tonus and active contracture with no sign of atrophy. Common finger extensor tendons, wrist extensors and extensor pollicis longus tendon (EPL) had adequate tension with voluntary contraction.

Following serial debridements, the musculotendinous junction was covered with pedicled groin flap according to the medical reports of patient. Although flexor muscle bellies at the forearm had active contraction, there was no active flexion at any joint of any finger. All ulnar and median nerve innervated intrinsic muscles at web spaces and palm were wasted. Palmar skin was contracted because of fibrotic scars. Neurologic examination of ulnar and median nerves revealed almost complete sensory loss.

The patient was psychologically depressed. When using the prosthesis, he was unable to wear his shirt or pants by his own. He was completely non-functional without his arm prosthesis and seeking for any improvement in his left hand's function.

In the treatment of patient, a two staged operation was planned in order to gain grip function of the hand. The first stage was composed of release of contractures of 1st web space and MP joints of 2<sup>nd</sup>, 3<sup>rd</sup>, 4<sup>th</sup> and 5<sup>th</sup> fingers and restoration of opposition of thumb with opponensplasty. The second stage was composed of restoration of flexion of fingers with tendon grafts and restoration of pinch with adductorplasty. The patient was informed about the possible complications of the operation and an informed consent was obtained.

The first operation was performed under general

anesthesia. A pneumatic tourniquet was placed at the level of the arm. The first web space contracture was approached with Z-plasty skin incision (Figure 1). The atrophied fibrotic adductor muscle group was transected until achieving adequate web space. Following contracture release the 1st metacarp was fixed to 2<sup>nd</sup> metacarpal with a provisional K wire. To release the joint contractures of each MP joints, we approached through separate longitudinal dorsal incisions (Figure 2). The extensor tendons were split longitudinally and reflected radially and ulnarly to expose the joint capsules (Figure 3). T-shaped incisions were made in the dorsal capsules and the collateral ligaments were transected with scissor. The joints were then passively flexed and provisional K-wire fixations in 90° flexed position of MP joints were applied to maintain flexion (Figure 4). Opponensplasty procedure started with the incision made over the fifth finger MP joint, and

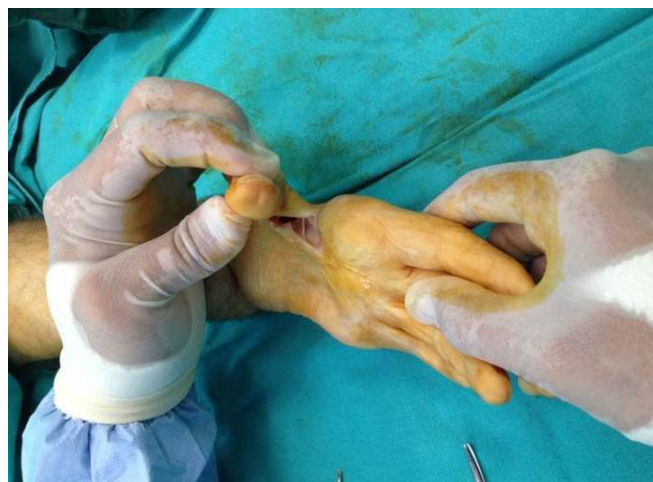


Figure 1. Release of first web space.

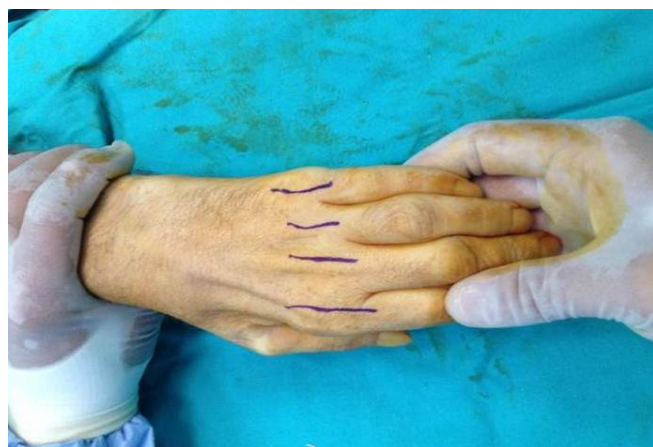
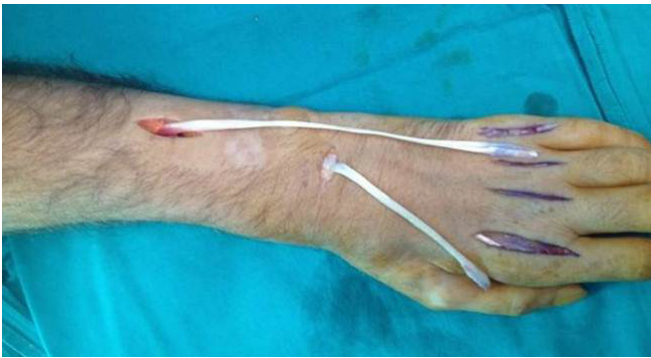
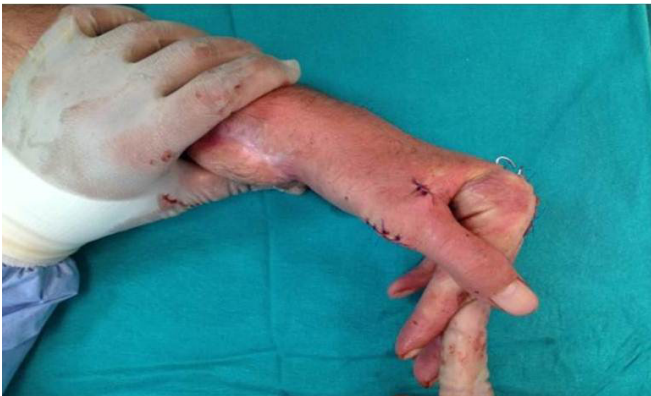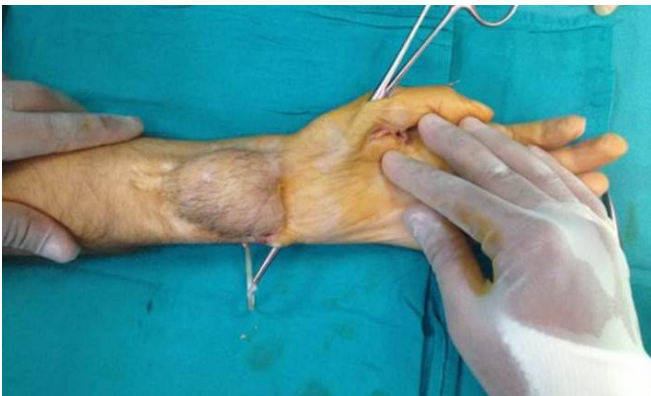Figure 2. 2<sup>nd</sup>, 3<sup>rd</sup>, 4<sup>th</sup> and 5<sup>th</sup> MP joint capsules were released using dorsal approach.



**Figure 3.** Preparing extensor tendons for flexor transfer.



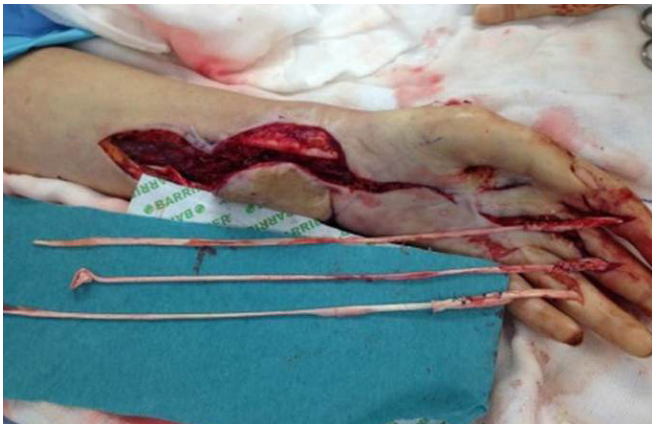**Figure 4.** Fixation of MP joints at 90° flexion posture.



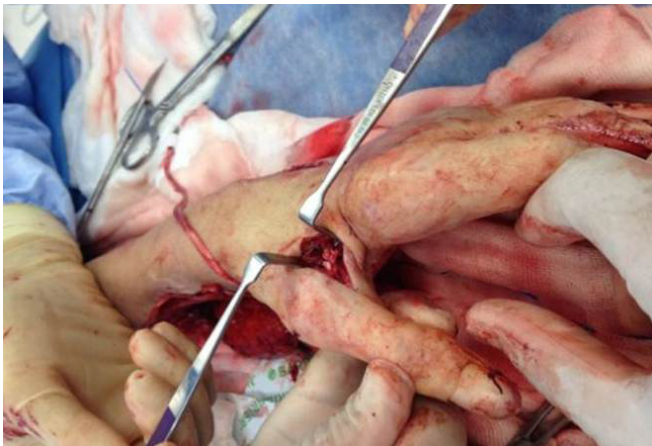**Figure 5.** Opponensplasty of the first thumb.

the extensor digiti minimi tendon was identified (Figure 5). The tendon was freed distally and withdrawn proximally from the incision on the dorsal aspect of the wrist and the little finger extensor hood at MP joint was repaired. The tendon was passed around the ulnar border of the wrist, and subcutaneously across the palm by using a tendon passer and was attached to the abductor pollicis longus (APB) tendon insertion at the base of the proximal phalanx. Postoperatively, all the 4 fingers and the thumb were immobilized for 3 weeks. After 3 weeks the pins and splint were removed and rehabilitation was initiated.

The second operation was also performed under general anesthesia. A pneumatic tourniquet was placed at the level of the arm. The surgery started with attention to the groin flap that was covering the musculo-tendinous junction area of forearm flexors. An incision was carried out from proximal forearm to the mid-palm across the radial border of flap. The muscle bellies of deep flexors and flexor pollicis longus (FPL) were identified. Fibrotic bands and adhesences were removed and their excursions were tested by manually stretching the tendinous ends. The tonus, colour and excursion of muscles were good to be used as motor unit of flexor system. Flexor digitorum profundus tendons of 2<sup>nd</sup>, 3<sup>rd</sup> and 4<sup>th</sup> fingers were dissected and released from adhesences and withdrawn distally out of A2 pulleys from incisions over proximal phalanges. Because of their appropriate caliber and length, long extensor tendons of 4<sup>th</sup> fingers in both feet and 3<sup>rd</sup> finger of left foot were harvested for grafting. The grafts were interposed between muscle belly and tendon ends of 2<sup>nd</sup>, 3<sup>rd</sup> and 4<sup>th</sup> fingers' deep flexor (Figure 6). All grafts were passed under A4 and A2 pulleys in order to prevent bowstringing of grafts. Another tendon graft was also interposed to bridge muscle belly and distal tendon end of FPL at forearm level. The last step of operation was reconstruction of thumb adduction by extensor carpi radialis longus as motor unit (Figure 7). Through a longitudinal wrist incision extending to dorsal aspects of the index and middle finger metacarpals, the extensor carpi radialis longus tendon was divided at its insertion on the metacarpal base. The proximal end of the tendon is retrieved into a second longitudinal incision proximal to the extensor retinaculum. The dorsal interosseous fascia between the 2<sup>nd</sup> and 3<sup>rd</sup> metacarpals was incised, and a passage was created in the intermetacarpal space by excising the fibrotic tissues. A longitudinal incision was then made on the ulnar side of the MP joint of the thumb, and a tendon graft was passed through this tunnel to the thumb and was sutured to the tendon of the adductor pollicis. The proximal end of the tendon graft was then sutured to the ECRL tendon. Postoperatively, the hand was immobilized in a plaster splint with the thumb and the wrist in neutral and the fingers in flexed position. After 4 weeks, the splint was removed and



**Figure 6.** Long extensors of the 3<sup>rd</sup> and 4<sup>th</sup> are harvested for grafting and interposed between muscle belly and tendon ends of the 2<sup>nd</sup>, 3<sup>rd</sup> and 4<sup>th</sup> deep finger flexors.



**Figure 7.** Adductorplasty of the thumb.

physical therapy programme was initiated.

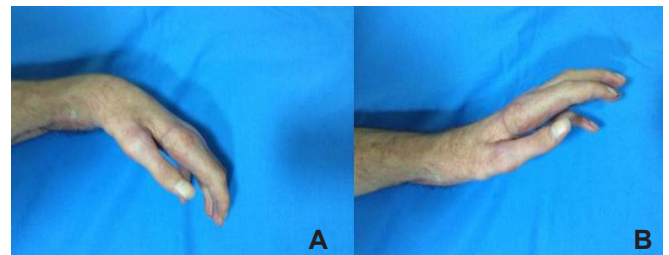
The patient was followed up to 10 months after final surgery. At the final examination the patient had an opposed thumb facing the all four fingers. The MP joints of 2<sup>nd</sup>, 3<sup>rd</sup>, 4<sup>th</sup> and 5<sup>th</sup> fingers were supple and had full passive range of motion. The reconstructed 1<sup>st</sup>, 2<sup>nd</sup> and 3<sup>rd</sup> fingers had all active 50 degrees of flexion and full extension (Figure 8a-b and Figure 9). PIP and DIP joints had no active motion but were steady against resistance during both flexion and extension. The patient was able to adduct and pinch the thumb. Opposition movement was no more than resting position but steady against resistance (Figure 10). Over all the patient was able to hold a pen between his thumb and index finger.

**Discussion**

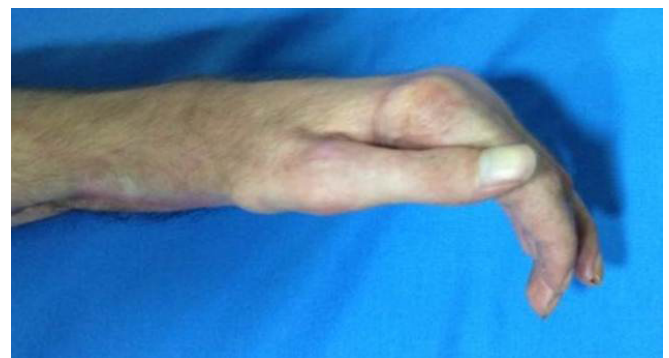
Electrical burn injuries are most commonly work related injuries. They often involve young males who are usually electrical company linesmen, electricians or

electrical construction workers. Mortality rate of these type of injuries are high and mainly due to arrhythmia at the scene of the injury [7]. If the patient survives it might leave a lifelong functional impairment at the patient. Usually extremities are affected and the sustained burns are thermal. The severity of the burn is related to the heat build up which increases with tissue resistance and volume density [8]. Deep muscle compartments are especially susceptible to necrosis since they are adjacent to bone. Bony tissue has highest tissue resistance followed by fatty tissue, tendon, skin, muscle, vessels and nerves, respectively [9].

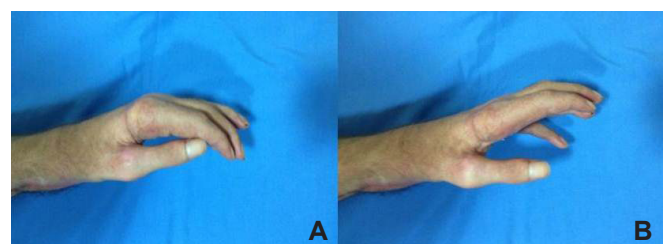
Skin represents an initial barrier to flow of current and serves as insulation to the deeper tissues. Once this skin resistance breaks down, current enters the underlying tissue whose internal tissue resistance, with the exception of bone, is negligible compared with current flow [10]. The amount of tissue damage is the result of



**Figure 8. (A,B)** Wrist flexion and extension in last control.



**Figure 9.** Flexion of 2<sup>nd</sup>, 3<sup>rd</sup>, 4<sup>th</sup> and 5<sup>th</sup> fingers at the end of the procedures.



**Figure 10. (A,B)** Opposition and abduction of the thumb.

complex interaction of several factors including amperage, voltage, tissue resistance, the duration and type of the current and the surface area over which the current makes contact [11]. The hands and upper extremities are most frequent entry sites of electrical current.

If the interstitial pressure of the compartment exceeds the capillary perfusion pressure, it results in muscle ischemia. This decrease in perfusion leads to a further increase in capillary permeability and extravasation of intravascular fluid, enhancing the interstitial pressure of the compartment. After 6-8 hours of ischemia, muscle damage becomes irreversible. This vicious cycle must be interrupted by fasciotomies, which limit ischemic injury to the muscle. Necrosis of the entire limb is the most serious complication, necessitating amputation usually within 2-3 days after injury. On the other hand various systemic complications, associating morbidities, prolonged hospital stay, multiple visits to operating room and very long rehabilitation processes are not uncommon with these type of injuries [12].

In the acute management phase of the patient, fluid and electrolyte balance must be regulated and the urinary output must be maintained. If the patient survives the acute period the treatment shifts to provide functional status and reconstructive phase starts [13]. We put a special consideration to our patient whose non-amputated extremity was actually not suitable for a reconstruction with tendon transfers.

There are some prerequisites for tendon transfer for the donor site in the upper extremity. These are mainly full passive joint mobility at the extremity and an acceptable distal sensation. Other important factors are a viable tissue through which the tendon can be transferred, normal or near normal motor strength in the donor field, an acceptable excursion of the transferred tendon and a good compliance of the overlying soft tissues [14]. So the patient was actually not an ideal candidate who would meet these criteria. He had failed sensation due to electrical burn and the condition of soft tissues, especially stiffness was important limitations for such an intervention.

However the patient had also an amputated extremity distal to the elbow on the contralateral site. If the left site would also undergo an amputation sur-

gery that would have a great emotional impact on the patient. So we decided to reconstruct the extremity as much as possible in order to gain a functioning hand.

At the end of this multiple operation sessions the patient was able to use his thumb for pinch and hold an object. He was also able to make some flexion over his mp, pip and dip joints. Compared to an amputation procedure the patients psychological status was less deteriorated as he can fulfill his daily activities as much as he can.

#### **Conflict of interest statement**

The authors have no conflicts of interest to declare.

#### **References**

1. Fordyce TA, Kelsh M, Lu ET, Sahl JD, Yager JW. Thermal burn and electrical injuries among electric utility workers, 1995-2004. *Burns* 2007;33:209-20.
2. Arasli Yilmaz A, Köksal AO, Özdemir O, Acar M, Küçükonyalı G, Inan Y, et al. Evaluation of children presenting to the emergency room after electrical injury. *Turk J Med Sci* 2015;45:325-8.
3. Schulze SM, Weeks D, Choo J, Cooney D, Moore AL, Sebens M, et al. Amputation Following Hand Escharotomy in Patients with Burn Injury. *Eplasty* 2016;16:e13.
4. Belliappa PP, McCabe SJ. The burned hand. *Hand Clin* 1993;9:313-24.
5. Gajbhiye AS, Meshram MM, Gajjarwar RS, Kathod AP. The management of electrical burn. *Indian J Surg* 2013;75:278-83.
6. Siemers F, Mailänder P. Treatment of hand burns. *Unfallchirurg* 2009;112:558-64.
7. Pruitt BA Jr, Goodwin CW, Pruitt SK. Burns: including cold, chemical and electrical injuries. In: Sabiston DC, (ed.) *Textbook of Surgery: The Biological Basis of Modern Surgical Care*. 14th ed. Philadelphia, WB Saunders Co, 1991:178-209.
8. Muir IFK. The treatment of electrical burns. *Br J Plast Surg* 1958;10:292-6.
9. Zelt RG, Daniel RK, Ballard PA, Grissette Y, Heroux P. High-voltage electrical injury: chronic wound evolution. *Plast Reconstr Surg* 1988;82:1027-39.
10. Rai J, Jeschke MG, Barrow RE, Herndon DN. Electrical injuries. A 30-year review. *J Trauma* 1999;46:933-6.

11. Koumbourlis AC. Electrical injuries. *Crit Care Med* 2002;30(11 Suppl):424-30.
12. Singerman J, Gomez M, Fish JS. Long-term sequelae of low-voltage electrical injury. *J Burn Care Res* 2008;29:773-7.
13. Sheridan RL, Greenhalgh D. Special problems in burns. *Surg Clin North Am* 2014;94:781-91.
14. Seiler JG 3rd, Desai MJ, Payne SHJ. Tendon transfers for radial, median, and ulnar nerve palsy. *Am Acad Orthop Surg* 2013;21:675-84.