

# A Rare and Often Unrecognized Cause of Hematochezia and Tenesmus in Childhood: Solitary Rectal Ulcer Syndrome

Deniz Ertem\*; Yesim Acar§; Esin Kotiloglu Karaa‡; and Ender Pehlivanoglu, MD\*

**ABSTRACT.** Solitary rectal ulcer syndrome (SRUS) is an unusual disorder of childhood, which usually presents with rectal bleeding, mucous discharge, prolonged straining, tenesmus, and localized pain in the perineal area. After the first description by Cruveilhier, Madigan and Morson further detailed the clinical and pathologic features of SRUS in 1969. The pathogenesis of the syndrome is not well-understood. The postulated mechanism responsible for rectal prolapse in most cases seems to be excessive straining efforts during which high intra-abdominal pressure forces the anterior rectal mucosa firmly into the contracting puborectalis muscle. The anterior rectal mucosa is frequently forced into the anal canal and as a consequence becomes strangulated, causing congestion, edema, and ulceration.

Histologically, the presence of fibromuscular obliteration of the lamina propria with disorientation of muscle fibers is characteristic, which could be secondary to chronic mechanical and ischemic trauma and inflammation by hard stools, and intussusception of the rectal mucosa. Although the syndrome is well-recognized in adults, the pediatric experience with this condition is limited and often remains unrecognized or misdiagnosed. A misdiagnosis has been reported in one fourth of adult cases, and the correct diagnosis usually delayed approximately 5 to 7 years. There are few pediatric case reports in English literature. Here, we describe 2 children with SRUS, aged 11 and 14 years, whose SRUS was diagnosed 2 and 6 years, respectively, after the onset of the first signs and symptoms. *Pediatrics* 2002;110(6). URL: <http://www.pediatrics.org/cgi/content/full/110/6/e79>; rectal bleeding, solitary rectal ulcer syndrome.

ABBREVIATION. SRUS, solitary rectal ulcer syndrome.

Solitary rectal ulcer syndrome (SRUS) is an unusual disorder of childhood, which usually presents with rectal bleeding, mucous discharge, prolonged straining, tenesmus, and localized pain in the perineal area.<sup>1-6</sup> After the first description by Cruveilhier,<sup>7</sup> Madigan and Morson<sup>8</sup> further detailed the clinical and pathologic features of SRUS in 1969. The pathogenesis of the syndrome is not well-understood. The postulated mechanism responsible

for rectal prolapse in most cases seems to be excessive straining efforts during which high intra-abdominal pressure forces the anterior rectal mucosa firmly into the contracting puborectalis muscle.<sup>9-12</sup> The anterior rectal mucosa is frequently forced into the anal canal and as a consequence becomes strangulated, causing congestion, edema, and ulceration.<sup>1-3</sup>

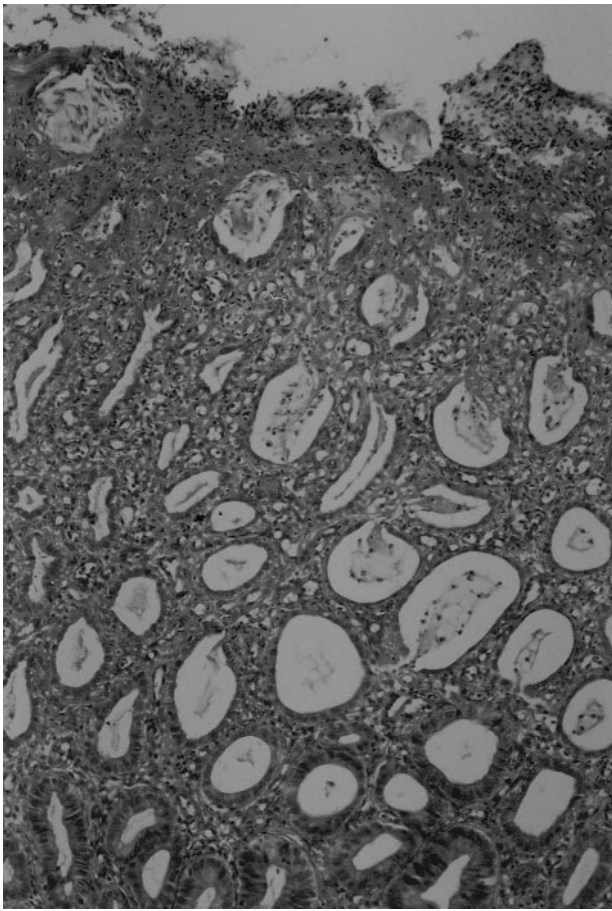
Histologically, the presence of fibromuscular obliteration of the lamina propria with disorientation of muscle fibers is characteristic, which could be secondary to chronic mechanical and ischemic trauma and inflammation by hard stools, and intussusception of the rectal mucosa.<sup>2,3,12-17</sup> Although the syndrome is well-recognized in adults, the pediatric experience with this condition is limited and often remains unrecognized or misdiagnosed.<sup>1-6,13,14</sup> A misdiagnosis has been reported in one fourth of adult cases, and the correct diagnosis usually delayed approximately 5 to 7 years.<sup>2,3,15</sup> There are few pediatric case reports in English literature.<sup>1-6</sup> Here, we describe 2 children with SRUS, aged 11 and 14 years, whose SRUS was diagnosed 2 and 6 years, respectively, after the onset of the first signs and symptoms.

## CASE REPORTS

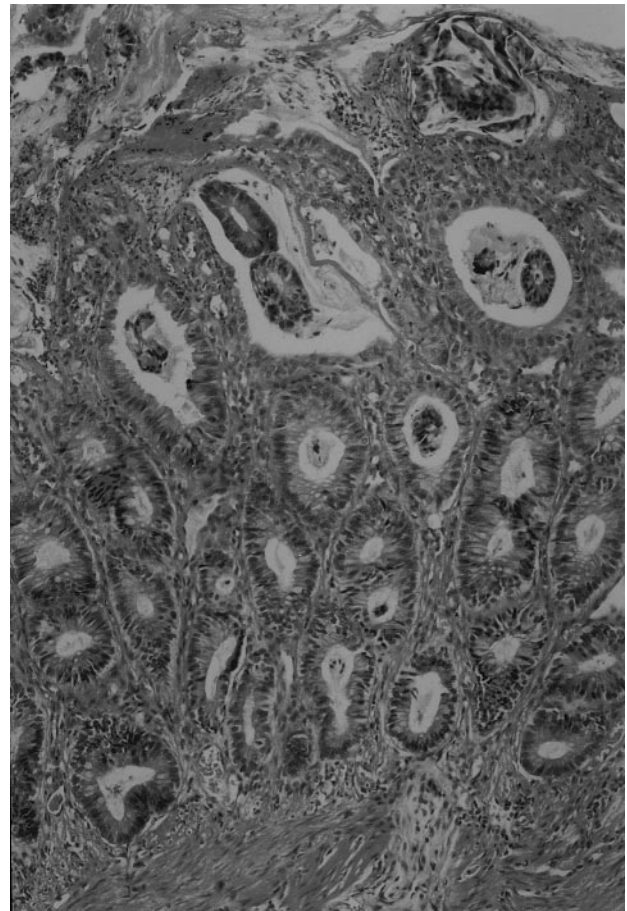
### Case 1

An 11-year-old girl was referred to our outpatient clinic with a 2-year history of rectal bleeding, digital extraction of feces, and intermittent rectal prolapse during defecation. She had hard stools every other day, containing fresh blood on the surface of it. There was a history of regular laxative use, but the hematochezia had not been resolved despite treatment. There was no history of weight loss, fever, arthralgia, skin rash, abdominal pain, change in appetite or daily activity, intake of antibiotics, or bleeding tendency. The physical examination, including digital rectal examination, was normal. Her anthropometric measurements were at the 50th percentile for both height and weight. The laboratory findings revealed hypochromic and microcytic anemia (hemoglobin 10.7 g/dL, hematocrit 33.8%, mean corpuscular volume 62.7 fl, platelet count  $343 \times 10^3/\text{mm}^3$ ), normal erythrocyte sedimentation rate (10 mm/h), and normal coagulation profile. White blood cell count was  $6800/\text{mm}^3$ ; liver function tests, and serum proteins were within normal ranges. Stool examination for ova, parasites, and cultures were negative 3 times. Autoimmune markers (perinuclear antineutrophil cytoplasmic antibody and antineutrophil cytoplasmic antibody) were negative. Colonoscopy revealed 2 ulcers 15 and 20 mm in diameter surrounded by a hyperemic halo and covered with fibrinous exudates on the anterior rectal wall 4 to 5 cm from the anus. Several biopsies were obtained from both the center and the margin of the ulcers. The rest of the colonoscopic examination up to the caecum was normal. Histopathological examination revealed erosion and superficial ulceration with

From the \*Division of Pediatric Gastroenterology and Nutrition, ‡Department of Pathology, §Okmeydani Social Security Teaching Hospital, Marmara University School of Medicine, Istanbul, Turkey, Received for publication Mar 7, 2002; accepted Aug 14, 2002. Reprint requests to (E.P.) Division of Pediatric Gastroenterology and Nutrition, Marmara University School of Medicine, Tophanelioglu Cd. 13-15, 81190, Altunizade-Istanbul, Turkey. E-mail: dertem@hotmail.com PEDIATRICS (ISSN 0031 4005). Copyright © 2002 by the American Academy of Pediatrics.



**Fig 1.** Superficial rectal mucosa showing erosion and ulceration covered with inflammatory exudates (arrows) and regenerative changes in glandular epithelium (hematoxylin-eosin stain,  $\times 10$ ).



**Fig 2.** Fibrous enlargement of lamina propria by extension of muscle fibers (arrows) and muscle bundles intermingled around the crypts (hematoxylin-eosin stain,  $\times 20$ ).

inflammatory cell infiltration in the lamina propria, distortion of crypts, and regenerative changes in crypt epithelium (Fig 1). There was expansion of the lamina propria with the extension of fibroblasts around the crypts (Fig 2). Biopsy samples obtained from the normal-looking colonic segments were also normal histologically, and no parasite or granuloma or inclusion bodies were detected in the biopsy samples. The macroscopic involvement of the distal part of the rectum and microscopic examination of the macroscopic lesions led us to the diagnosis of SRUS. An increase in dietary fiber and regular use of laxatives were advised, and she was treated with sulfasalazine enema for 6 months. The symptoms resolved for a few months but then recurred despite the passage of soft stool with easy defecation. Detrimental effects of the worsening of symptoms in lifestyle of both the child and her parents led us to refer the patient to a pediatric surgeon for surgical intervention. Because the SRUS in this patient was associated with mucosal rectal prolapse, Ekehorn sacrorectopexy was performed at the end of 1.5 years of conservative treatment. Her signs and symptoms (rectal bleeding, rectal prolapse, feeling of incomplete defecation, digital extraction of feces) resolved gradually during the 18 months of follow-up after the surgical procedure. A repeat colonoscopy performed 12 months after the rectopexy revealed healing of the rectal ulcers.

## Case 2

A 14-year-old boy was admitted to our outpatient clinic with hematochezia. He first reported bloody stool at 9 years of age. He complained of painful, frequent defecations and engaged in prolonged straining with passage of blood and mucous on the surface of stool and intermittent mucosal prolapse during defecation. Two years before his visit to our clinic, he had undergone a rectosigmoidoscopic examination, and an ulcer was found. It was thought to be malignant until the pathologist, without additional morphologic description, reported it as a benign lesion. There was no

history of abdominal pain, constipation, weight loss, change in daily activity or appetite, recent use of antibiotics, arthralgia, aphthous skin, or oral lesions. Physical assessment, including digital rectal examination, was normal. The laboratory investigation revealed a normal complete blood count and blood coagulation profile. The erythrocyte sedimentation rate was 5 mm/h, autoimmune markers (perinuclear antineutrophil cytoplasmic antibody and antineutrophil cytoplasmic antibody) both were negative. Microscopic examination of stool showed 4 to 5 leukocytes, and 10 to 15 erythrocytes but negative for ova and parasites 3 times. Stool cultures were also negative for pathogenic microorganisms. Flexible colonoscopy revealed a circumferential ulcer 3 to 4 cm in length 5 to 6 cm distal to the anal verge. The surface of the ulcer was covered with grayish exudates, and the ulcer was well demarcated from the surrounding normal mucosa. The mucosal and vascular structures beyond this ulcer up to the caecum were completely normal. Multiple biopsies were obtained from both ulcer center and ulcer margin and from normal-looking parts of the total colonic segments. Histopathological examination of the mucosa from the ulcer showed epithelial hyperplasia with goblet cell depletion, regenerative crypt epithelium, and fibrous enlargement of the lamina propria. Biopsy samples obtained from the normal-looking colonic segments all were normal histologically, and no parasite or granuloma or inclusion bodies were detected in the biopsy samples. After the exclusion of infective and inflammatory causes of rectal ulcer, clinical history and macroscopic and microscopic examinations of the colonic tissue led us to the diagnosis of SRUS. A high-fiber diet and sucralfate enema were prescribed to the patient, and the symptoms resolved for the first few months. Four months later, he returned to our clinic with bloody stools with mucous and intermittent rectal prolapse. Corticosteroid enemas were administered to the patient for the next 4 weeks, but he did not benefit from this treatment. Because his family refuses surgical treatment, he has been receiving high-fiber diet

and laxatives for past 2 years. He still has infrequent rectal passage of blood and mucus after straining during defecation and rectal prolapse if he becomes constipated.

## DISCUSSION

SRUS is a benign condition of the rectum that is found most often in young adults.<sup>9–11</sup> Because the clinical presentation varies, the diagnosis requires a high index of suspicion of both the clinician and the pathologist.<sup>2,15,16</sup> This entity either is rare in children or usually goes unrecognized or misdiagnosed in pediatric practice.<sup>1–6,13</sup>

It has been noted previously that the term “solitary rectal ulcer” is a misnomer because only one fourth of the adults with SRU have true rectal ulcer, and the lesion is not necessarily solitary or ulcerated.<sup>9,14,16</sup> Thus, an unusual-appearing rectal lesion in a patient who complains of hematochezia and tenesmus with or without rectal prolapse should arouse the suspicion of SRUS. Both of the children described here had history of straining, anal pain, and passage of blood and mucus during defecation for a prolonged period of time. Careful inquiry made it clear that intermittent rectal mucosal prolapse was also experienced during forceful straining episodes. The most important diagnostic investigation is colonoscopic examination of the children with hematochezia. Thus, it is important to consider this diagnosis, visualize the anorectal junction carefully, and accomplish a full colonoscopic examination and obtain biopsies from both normal- and pathologic-looking sites to exclude inflammatory bowel disease.

SRUS is rarely reported in children because it is difficult to recognize both the macroscopic and histopathological changes during childhood.<sup>1–4</sup> Even in adults, it has been reported that the time interval between the onset of symptoms and the establishment of accurate diagnosis varies between 1 and 31 years (median: 7.8 years).<sup>15</sup> It should be realized that a prolonged period of misdiagnosis may have important consequences, such as anemia secondary to massive hemorrhage or poor appetite in a growing child and distress to the child’s family.<sup>8</sup> The most common clinicopathologic diagnostic confusion may be inflammatory bowel disease, infectious proctocolitis, intussusception, hemorrhoids, prolapsing rectal polyp, or sexual abuse in children, whereas villous adenoma or adenocarcinoma should also be included in the differential diagnosis of SRUS in adulthood.<sup>10,13,14,16</sup> Although a rectal ulcer had been found in our second case 2 years before the admission, the macroscopic and microscopic morphology of the lesion was overlooked. Last, 5 years should not have passed for this case to get the accurate diagnosis.

The macroscopic appearance of the rectal lesion may vary from hyperemia to ulceration or polypoid lesion. In addition, rectal lesion may be multiple or circumferential and usually occurs on the anterior or anterolateral wall of the rectum, which is not a consistent feature of SRUS.<sup>9,11,14,17</sup> The ulcerated lesion was located on the anterior wall of the rectum in the first case, whereas it was circumferential in our second case. The rest of the colonoscopic examination

was completely normal in both cases, which was also confirmed histopathologically by examining the biopsies taken from normal-appearing segments of the entire colon. The histopathological findings were typical in our cases, which was the obliteration of lamina propria by fibroblasts and muscle fibers derived from muscularis mucosa in the region of ulcer. The epithelium may show mucosal architectural distortion with hyperplastic or villiform changes.<sup>8,10,15,16</sup> All of these architectural changes in SRUS may mimic inflammatory bowel disease, ileocecal intussusception, prolapsing rectal polyp, or adenocarcinoma. The presence of fibromuscular obliteration of the lamina propria is not a feature of inflammatory bowel disease.<sup>9,10</sup> The tendency for the presence of misplaced glands in the submucosa in SRUS may mislead to the consideration of carcinoma of the rectum. These mucus-filled glands are lined by normal colonic epithelium devoid of cytologic dysplasia and allow the pathologist to be sure about the benign nature of the lesion.<sup>10,16</sup> It has been suggested that the morphologic changes could be explained by rectal prolapse and ischemic mucosal injury, which might be secondary to the occlusion of the anal canal by the anterior rectal wall during excessive straining on defecation.<sup>18,19</sup>

In the pediatric age group, there are few reported cases of SRUS that have undergone detailed investigation.<sup>1–3</sup> Because the treatment protocols in these cases vary extremely and clinical outcome is poorly documented, there are limited therapeutic experiences in children with SRUS.<sup>1–6</sup> It is usually considered that neither medical nor surgical management of SRUS has been successful, and recurrent ulceration is common.<sup>8</sup> The initial clinical approach of SRUS in children should be reassurance of the child and the parents about the benign nature of the disease and to suggest conservative measures, which include avoidance of straining, use of high-fiber diet, and intermittent use of laxatives to prevent constipation.<sup>13</sup> A few pediatric case reports have demonstrated improvement during follow-up after the administration of local sulfasalazine or steroid enemas.<sup>5,20</sup> In adult literature, it has been reported that one third of cases can have symptoms that are sufficient enough to warrant surgery.<sup>14,15,21</sup> It has also been stated that almost one third to one half of the cases have rectal prolapse.<sup>15,21</sup> In the absence of rectal prolapse, local procedures such as sphincter repair and anorectal myotomy are preferred.<sup>9,11,14</sup> In contrast, in patients with mucosal or full-thickness rectal prolapse with severe symptoms, rectopexy (Ekehorn sacrorectopexy, Ripstein sling, or retrorectal fixation) results in symptomatic relief in approximately 40% to 60% of patients.<sup>17,21–23</sup> However, it is not possible to draw a conclusion from these studies for treatment of pediatric patients with SRUS. Both of the patients presented here experienced intermittent rectal prolapse, and both of them completed 1-year conservative treatment. Although they first responded to the dietary management and local sulfasalazine enema, symptoms recurred during follow-up. The first patient underwent a rectopexy

operation, and she has been asymptomatic since 1.5 years after the operation.

### CONCLUSION

SRUS is a well-defined but nonspecific entity with various presentations. The cause is primarily unknown; however, ischemic mucosal injury frequently associated with rectal prolapse seems to be the most likely pathogenic factor. An early diagnosis requires a high index of suspicion of not only the physician but also the pathologist. Report of larger series and long-term follow-up are required for establishment of conservative and surgical treatment protocols in children.

### REFERENCES

1. Eigenmann PA, Le Coultre C, Cox J, Dederding JP, Belli DC. Solitary rectal ulcer: an unusual cause of rectal bleeding in children. *Eur J Pediatr*. 1992;151:658–660
2. Figueroa-Colon R, Younoszai MK, Mitros FA. Solitary ulcer syndrome of the rectum in children. *J Pediatr Gastroenterol Nutr*. 1989;8:408–412
3. Sondheimer JM, Slagle TA, Bryke CR, Hill RB. Solitary rectal ulcer syndrome in a teenaged boy. *J Pediatr Gastroenterol Nutr*. 1985;4:835–838
4. De la Rubia L, Villaespesa AR, Cebrero M, et al. Solitary rectal ulcer syndrome in children. *J Pediatr* 1993;122:733–736
5. Kiristioğlu I, Balkan E, Kilic N, Dogruyol H. Solitary rectal ulcer syndrome in children. *Turk J Pediatr*. 2000;42:55–60
6. Godbole P, Botterill I, Newell SJ, Sagar PM, Stringer MD. Solitary rectal ulcer syndrome in children. *J R Coll Surg Edinb*. 2000;45:411–414
7. Crueveilhier J. *Ulcere Chronique du Rectum*. Anatomie Pathologique du Corps Humain. Paris, France: JB Billiere; 1829
8. Madigan MR, Morson BC. Solitary ulcer of the rectum. *Gut*. 1969;10: 871–881
9. Ford MJ, Anderson JR, Gilmour HM, et al. Clinical spectrum of “solitary ulcer” of the rectum. *Gastroenterology*. 1983;84:1533–1540
10. Rutter KRP, Riddell RH. The solitary rectal ulcer syndrome of the rectum. *Baillieres Clin Gastroenterol*. 1975;4:505–530
11. Martin CJ, Parks TG, Biggart JD. Solitary rectal ulcer syndrome in Northern Ireland 1971–1980. *Br J Surg*. 1981;68:744–747
12. Jones PN, Lubowski DZ, Swash M, Henry MM. Is paradoxical contraction of puborectalis muscle of functional importance. *Dis Colon Rectum*. 1987;30:667–670
13. Siafakas C, Vottler TP, Andersen JM. Rectal prolapse in pediatrics. *Clin Pediatr*. 1999;38:63–72
14. Tjandra JJ, Fazio VW, Church JM, et al. Clinical conundrum of solitary rectal ulcer. *Dis Colon Rectum*. 1992;35:227–234
15. Tjandra JJ, Fazio VW, Petras RE, et al. Clinical and pathologic factors associated with delayed diagnosis in solitary rectal ulcer syndrome. *Dis Colon Rectum*. 1993;36:146–153
16. Saul H, Sollenberger CL. Solitary rectal ulcer syndrome: its clinical and pathological underdiagnosis. *Am J Surg Pathol*. 1985;9:411–421
17. Keighley MR, Shouler P. Clinical and manometric features of the solitary rectal ulcer syndrome. *Dis Colon Rectum*. 1984;27:507–512
18. Rutter KRP. Solitary rectal ulcer syndrome. *Proc R Soc Med*. 1975;68: 22–26
19. Rutter KRP. EMG changes in certain pelvic floor abnormalities. *Proc R Soc Med*. 1974;67:53–56
20. Kumar M, Puri AS, Srivastava R, Yachha SK. Solitary rectal ulcer in a child treated with local sulfasalazine. *Indian Pediatr*. 1994;31:1553–1555
21. Sitzler PJ, Kamm MA, Nicholls RJ, McKee RF. Long term clinical outcome of surgery for solitary rectal ulcer syndrome. *Br J Surg*. 1998;85: 1246–1250
22. Nicholls RJ, Simson JN. Anteroposterior rectopexy in the treatment of solitary rectal ulcer syndrome without overt rectal prolapse. *Br J Surg*. 1986;73:222–224
23. Schepens MA, Verhelst AA. Reappraisal of Ekehorn’s rectopexy in the management of rectal prolapse in children. *J Pediatr Surg*. 1993;8: 1494–1497

**A Rare and Often Unrecognized Cause of Hematochezia and Tenesmus in  
Childhood: Solitary Rectal Ulcer Syndrome**

Deniz Ertem, Yesim Acar, Esin Kotiloglu Karaa and Ender Pehlivanoglu

*Pediatrics* 2002;110:e79

DOI: 10.1542/peds.110.6.e79

**Updated Information &  
Services**

including high resolution figures, can be found at:  
<http://pediatrics.aappublications.org/content/110/6/e79>

**References**

This article cites 22 articles, 1 of which you can access for free at:  
<http://pediatrics.aappublications.org/content/110/6/e79#BIBL>

**Subspecialty Collections**

This article, along with others on similar topics, appears in the  
following collection(s):  
**Gastroenterology**  
[http://www.aappublications.org/cgi/collection/gastroenterology\\_sub](http://www.aappublications.org/cgi/collection/gastroenterology_sub)

**Permissions & Licensing**

Information about reproducing this article in parts (figures, tables) or  
in its entirety can be found online at:  
<http://www.aappublications.org/site/misc/Permissions.xhtml>

**Reprints**

Information about ordering reprints can be found online:  
<http://www.aappublications.org/site/misc/reprints.xhtml>

American Academy of Pediatrics

DEDICATED TO THE HEALTH OF ALL CHILDREN®



# PEDIATRICS®

OFFICIAL JOURNAL OF THE AMERICAN ACADEMY OF PEDIATRICS

## **A Rare and Often Unrecognized Cause of Hematochezia and Tenesmus in Childhood: Solitary Rectal Ulcer Syndrome**

Deniz Ertem, Yesim Acar, Esin Kotiloglu Karaa and Ender Pehlivanoglu

*Pediatrics* 2002;110:e79

DOI: 10.1542/peds.110.6.e79

The online version of this article, along with updated information and services, is  
located on the World Wide Web at:

<http://pediatrics.aappublications.org/content/110/6/e79>

Pediatrics is the official journal of the American Academy of Pediatrics. A monthly publication, it has been published continuously since 1948. Pediatrics is owned, published, and trademarked by the American Academy of Pediatrics, 345 Park Avenue, Itasca, Illinois, 60143. Copyright © 2002 by the American Academy of Pediatrics. All rights reserved. Print ISSN: 1073-0397.

## American Academy of Pediatrics

DEDICATED TO THE HEALTH OF ALL CHILDREN®

