

An Unusual Flexor Hallucis Longus Muscle

By

Jasna GÜRBÜZ, Safiye ÇAVDAR and Ümit ŞEHİRLİ

*Marmara University, School of Medicine, Department of Anatomy, Haydarpaşa 81326, İstanbul, Turkey

– Received for Publication, November 13, 1998 –

Key Words: Unusual, Flexor hallucis longus muscle

Abstract: During the dissection of the posterior compartment of the left leg, an unusual flexor hallucis longus muscle of a fifty two years-old male cadaver was observed.

On the medial side of the flexor hallucis longus, on its lower distal half, a prominent aponeurotic structure was observed. A small unusual muscle mass was attached to this aponeurotic structure. The muscular fibres of the unusual mass were arranged in form of bipennate muscle. It originated via a broad tendon from the muscular fibres of the tibialis posterior and the deep transverse fascia covering the same muscle. It inserted on the aponeurosis of the lower medial half of the flexor hallucis longus muscle.

Having in mind the very different pathology in the region of the ankle and the foot, the significance of such a muscle mass could be of practical importance.

Real anomalies of the muscles in the calf are rare. These variations may include an extra slip of origin associated with gastrocnemius and soleus³⁾, and rarely, a muscle slip associated with the popliteus as a popliteus minor⁸⁾. The more common anomalous muscle of the leg is the accessory flexor digitorum longus¹⁾. A rare muscle was described as “peroneocalcaneus muscle”. This muscle is sometimes regarded as being associated with the tibialis posterior and sometimes with the flexor hallucis longus¹⁾.

The aim of this study is to describe an anomalous muscle attached to the flexor hallucis longus, which has not been discussed in literature. Further, the presence of this muscle can be of interest from a clinical and morphological point of view.

Observations

The fifty two year-old human cadaver was fixed with formaldehyde. During dissection for educational purposes, an unusual flexor hallucis longus muscle in the postero-medial compartment of the left leg was exposed.

The unusual muscle mass originated via a broad tense tendon from the muscular fibers of the tibialis

posterior muscle and the deep transverse fascia. It inserted on the aponeurosis of the lower medial side of the flexor hallucis longus. The muscular fibres of this unusual mass were arranged in the form of bipennate muscle (Fig. 1). The fleshy portion of the muscle was 7.2 cm and the tendinous portion was 13.0 cm long. The muscular fibers of the unusual muscle was 11.0 cm above the medial malleolus.

The unusual muscle mass was innervated by muscular branches from the tibial nerve. Its blood supply was from branches of the peroneal artery.

Discussion

The lower limb, embriologically develops from mesoderm, about 44 days after fertilization. The lower limbs arise from the inferior buds which lie opposite to the second to the fifth lumbar and the upper three sacral segments. Variations of the musculature of the lower limb can be due to the extensive migration and rearrangement of the muscles during its development⁴⁾.

Kosugi *et al.*⁵⁾ divided the muscles in two groups; the first group possessed many variations which are referred to as muscles on the way to differentiation

and the second group having not so many variations, in other words stable, differentiated muscles. According to this definition, the posterior compartment muscles are rather stable group of muscles. Therefore, it is a matter of question whether this case can be evaluated as a past form or a future form on the way to differentiation.

The flexor hallucis longus is a muscle involved in various clinical conditions. Its tendon is the superior choice for reconstruction due to its length, strength and anatomic location^{6,13}). Furthermore, the flexor hallucis longus does not seem to be essential for good push-off and for stabilizing the medial longitudinal arch^{2,6}). Therefore, the tendon of the flexor hallucis longus muscle is being used to repair many sports injuries, spontaneous ruptures, pes planus in children and paralytic clawing of the hallux in children with congenital deformity^{6,12,13}).

During some strenuous sport activities e.g. as seen in tennis players, in ballet dancers, competitive divers⁷) and marathon runners⁹) the fleshy part of the flexor hallucis longus can be entrapped into the retinaculum flexorum. This kind of entrapment results in trigger ankle and occasional locking of the great toe^{7,8,11}). There was no anatomical relation between the unusual muscle mass and retinaculum flexorum but a close relation with the tibial nerve at the lower posterior leg was observed. In the case of tibial nerve syndrome, without positive history of fracture or injury, the presence of a muscle mass, such as in our case, should be taken into consideration. However, premorbid historical information in our case, was insufficient to make clinical correlation with the anatomical findings.

The flexor hallucis longus is a bipennate muscle. The unusual muscle mass on its medial border can be considered as the opposing fibres of the bipennate flexor hallucis longus muscle. But the tendinous raphe in the central portion of the unusual muscle mass and its different insertion make this case unique.

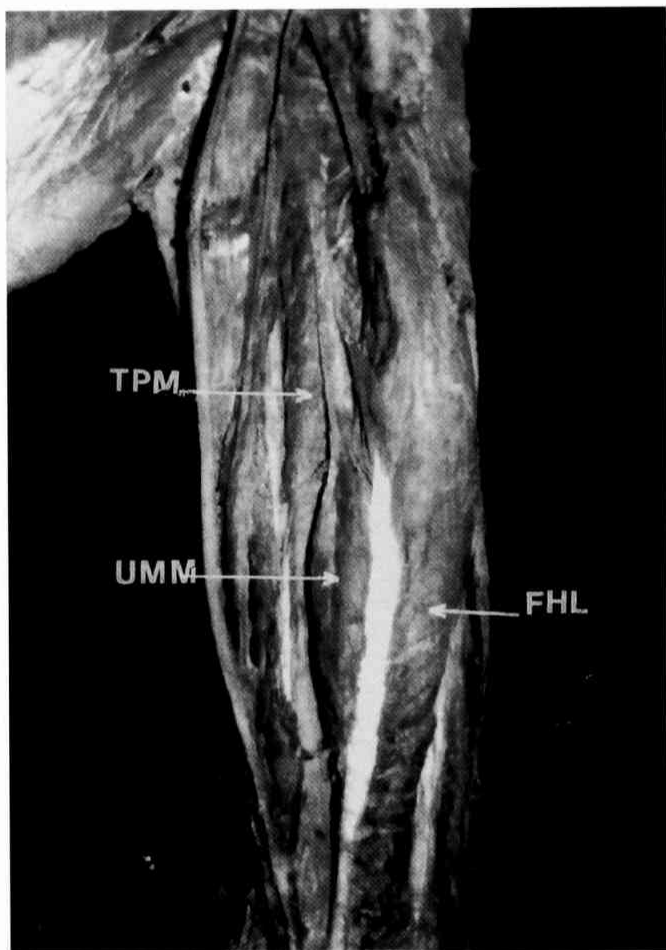
During the numerous surgical procedures concerned with the flexor hallucis longus, the presence of such a prominent tendon and an extra muscle mass may lead to confusion. Keeping in mind such a variation may avoid possible complications.

Acknowledgement

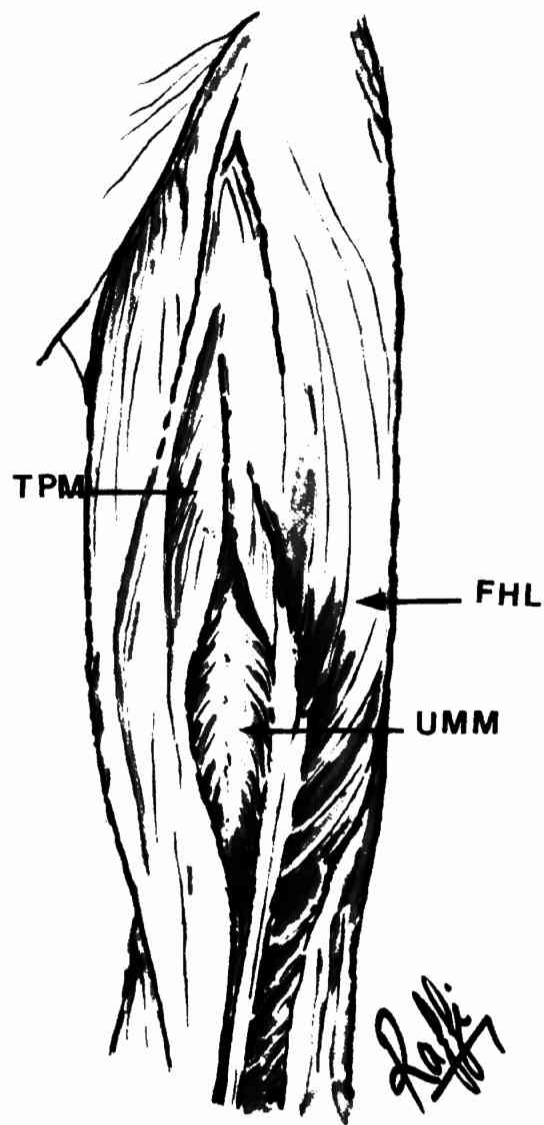
We thank to Dr. Raffi Gürünlüoğlu for his contribution by drawing the figure.

References

- 1) Driver JR and Denison AB. The morphology of the long accessorius muscle. *Anat Rec* 1914; **8**:341.
- 2) Frenette JP and Jackson DW. Lacerations of the flexor hallucis longus in the young athlete. *J Bone Joint Surg Am* 1977; **59**:673-676.
- 3) Hollinshead WH. *Anatomy for surgeons*. 2nd ed, Harper and Row, London, pp 799-802, 1969.
- 4) Hamilton WJ, Boyd JD and Mossman HW. Cardiovascular system. In: *Human Embryology*. 4th edn. Williams and Wilkins, pp 271-290, 1978.
- 5) Kosugi K, Shibata S and Yamashita H. Anatomical study on the variation of extensor muscles of human forearm: The relation between differentiation and variation. *Jikeikai Med J* 1988; **36**:93-111.
- 6) Masterson E, Jagannathan S, Borton D and Stephens MM. Pes planus in childhood due to tibialis posterior tendon injuries. *J Bone Joint Surg* 1994; **76-B**:444-446.
- 7) McCarroll JR, Ritter MA and Becker TE. Triggering of the great toe. *Clin Ortop* 1983; **175**:184-185.
- 8) Moorman CT, Raymond RM and Basset FH. So-called trigger ankle due to an aberrant flexor hallucis longus muscle in a tennis player. *J Bone Joint Surg* 1992; **74-A**:294-295.
- 9) Parsons FG and Robinson A. Eighth report of the committee of collective investigation of the Anatomical Society of Great Britain and Ireland, for year 1897-98. *J Anat & Physiol* 1898; **33**:189.
- 10) Romash MM. Closed rupture of the flexor hallucis longus tendon in a long distance runner: report of a case and review of the literature. *Foot Ankle Int* 1994; **15**:433-436.
- 11) Sammarco GJ and Miller EH. Partial rupture of flexor hallucis longus tendon in classical ballet dancers. *J Bone Joint Surg* 1979; **61-A**:149-151.
- 12) Shanahan MD, Douglas DL, Sharrard WJ, Duckworth T and Betts R. The long-term results of the surgical management of paralytic pes cavus by soft tissue release and tendon transfer. *Z Kinderchir* 1985; **40**:Suppl 1P 37-41.
- 13) Wapner KL, Hecht PJ, Shea JR and Allardyce TJ. Anatomy of second muscular layer of the foot: considerations for tendon selection in transfer for Achilles and posterior tibial tendon reconstruction. *Foot Ankle Int* 1994; **15**:420-423.
- 14) Williams PL, Warwick R, Dysonand M and Bannister LH. 37th ed, *Gray's Anatomy*, Churchill Livingstone, Edinburg, pp 648-651, 1989.



a



b

Explanation of Figures

Plate I

Fig. 1a. The cadaveric appearance of the unusual flexor hallucis longus muscle in the posterior compartment of the leg. (Abbreviations: TPM: Tibialis Posterior Muscle, FHL: Flexor Hallucis Longus, UMM: Unusual Muscle Mass)

Fig. 1b. Schematic drawing of the unusual flexor hallucis longus muscle.