

Use of a Gelatin-Thrombin Hemostatic Matrix for Secondary Bleeding After Pediatric Tonsillectomy

Adem Binnetoglu, MD; Berat Demir, MD; Ali Cemal Yumusakhuylu, MD; Tekin Baglam, MD; Murat Sari, MD

IMPORTANCE Secondary posttonsillectomy bleeding associated with oozing from multiple sites or overcauterized tonsillar bed deserves special evaluation.

OBJECTIVE To evaluate the use of an absorbable, flowable gelatin-thrombin hemostatic matrix (GTHM) sealant for secondary bleeding after tonsillectomy.

DESIGN, SETTING, AND PARTICIPANTS This was a retrospective data analysis, with information gathered from medical records of pediatric patients with secondary posttonsillectomy bleeding treated with the GTHM between 2012 and 2016 at a referral center and a local satellite facility. Forty-two pediatric patients admitted with secondary bleeding after tonsillectomy characterized by diffuse bleeding, multiple bleeding sites, or an overcauterized tonsillar bed, were treated with GTHM. Exclusion criteria were a bleeding disorder, genetic syndrome associated with abnormal oropharyngeal anatomy, and hemorrhage from a single site.

EXPOSURES GTHM was used to treat posttonsillectomy secondary bleeding.

MAIN OUTCOMES AND MEASURES Patient medical records were reviewed for information relevant to this study: (1) patient history, the tonsillectomy surgical technique used, and whether there were prior bleeding episodes (and if so, methods of treatment); (2) physical examination and laboratories on presentation, operative report details, and results of treatment; (3) hospital course and whether any further bleeding episodes occurred; and (4) hospital follow-up information (range, 3-20 months).

RESULTS The study population comprised 22 boys (52%) and 20 girls (48%) (a total of 42 patients), and the mean (SD) age was 7 (2.7) years (range, 4-14 years). Two patients had presented with recurrent secondary bleeding necessitating multiple operations, but the others had only 1 episode. The mean day of occurrence of bleeding was on the eighth day (range, day 7-12; median, day 10). Only 2 patients required blood transfusions: they were the same patients who underwent multiple operations for recurrent episodes of secondary bleeding. All patients except for 1 (41 of 42) were discharged without further bleeding following treatment. No adverse effects were reported.

CONCLUSIONS AND RELEVANCE Results suggest that GTHM is generally simple, safe, and effective for use in the treatment of posttonsillectomy secondary bleeding types not associated with a direct vein or artery source but oozing from multiple sites and/or overcauterized tonsillar bed that cannot be stopped by traditional hemostatic methods.

JAMA Otolaryngol Head Neck Surg. 2016;142(10):954-958. doi:10.1001/jamaoto.2016.1678
Published online July 14, 2016.

Author Affiliations: Department of Otorhinolaryngology-Head and Neck Surgery, Pendik Training and Research Hospital, Marmara University Medical Faculty, Istanbul, Turkey.

Corresponding Author: Adem Binnetoglu, MD, Department of Otorhinolaryngology-Head and Neck Surgery, Pendik Training and Research Hospital, Marmara University Medical Faculty, Fevzi Çakmak Mah, Muhsin Yazıcıoğlu Cad, No.10 Üst Kaynarca, Pendik, Istanbul, Turkey (adembinnet@hotmail.com).

Tonsillectomy is one of the most common surgical procedures performed by otolaryngologists.¹ Posttonsillectomy bleeding is a common complication of tonsillectomy, but can be life-threatening if diagnosed late or not treated properly.² Posttonsillectomy bleeding is commonly classified as primary (<24 hours) or secondary (≥24 hours) depending on how long after surgery it occurs. Many studies have been performed to determine the best method for achieving hemostasis with posttonsillectomy bleeding. In these studies, monopolar cautery, bipolar cautery, ligation, embolization, and absorbable hemostatic agents have been used and compared. An absorbable, flowable gelatin-thrombin hemostatic matrix (GTHM) agent (FloSeal Hemostatic Matrix, Baxter Inc) was first approved in 1999 by the US Food and Drug Administration (FDA) and has been used in cardiac, vascular, and spinal surgery.^{3,4} It is a combination of a gelatin matrix and thrombin, and stops bleeding by making composite particles of fibrin clot at the bleeding site by biophysical hemostasis. GTHM is applied to the surface of the bleeding tissue, fills the area, and (due to the granules in the compound) conforms to the shape of the wound surface. Blood accumulates and is exposed to thrombin, and a clot forms around the mechanically stable matrix provided by the granules. Because of the structural integrity of the gelatin fibrin matrix, it remains in place at the tissue surface. GTHM is absorbed in 6 to 8 weeks, depending on wound healing.^{3,4}

The purpose of our study was to investigate whether GTHM may be used successfully to manage pediatric posttonsillectomy secondary bleeding. To our knowledge, there are no available data on the use of GTHM for this particular application.

Methods

Patient Selection and Evaluation

Medical records from a total of 42 patients who were admitted to our hospital between January 2012 and March 2016 were retrospectively reviewed for this study. The institutional review board of Pendik Training and Research Hospital, Marmara University Medical Faculty, approved this study. Cases included pediatric patients who had undergone tonsillectomy owing to recurrent tonsillitis and upper airway obstruction and met specific clinical criteria: (1) onset of bleeding 24 hours or more after tonsillectomy (secondary); (2) diffuse or multiple bleeding sites, or an overcauterized tonsillar bed that is any observable tissue necrosis secondary to excessive cauterization of tonsillar fossa on physical examination; and (3) they had GTHM used for urgent bleeding control. Patients with 1 or more of the following were excluded: bleeding diathesis; genetic conditions involving characteristic anatomical features associated with inadequate surgical exposure (including Down syndrome, Prader-Willi syndrome, and Angelman syndrome, as well as mucopolysaccharidosis); and bleeding from a single source originating from a vein or artery that could be controlled with traditional methods (ligation, cautery).

Detailed patient history, including previous bleeding episodes, family history of bleeding disorders, physical examination findings, laboratory studies, and intraoperative notes,

Key Points

Question Can gelatin-thrombin hemostatic matrix (GTHM) agent be used to manage pediatric posttonsillectomy secondary bleeding effectively?

Findings Retrospective medical records of 42 patients were reviewed. All patients except for 1 (41 of 42) were discharged without further bleeding following treatment. No adverse effects were reported.

Meaning Based on this study, GTHM is a simple, safe, and effective technique that can be used as a first-line treatment for a patient with secondary posttonsillectomy bleeding, especially patients with oozing from multiple sites and/or from an overcauterized tonsillar bed.

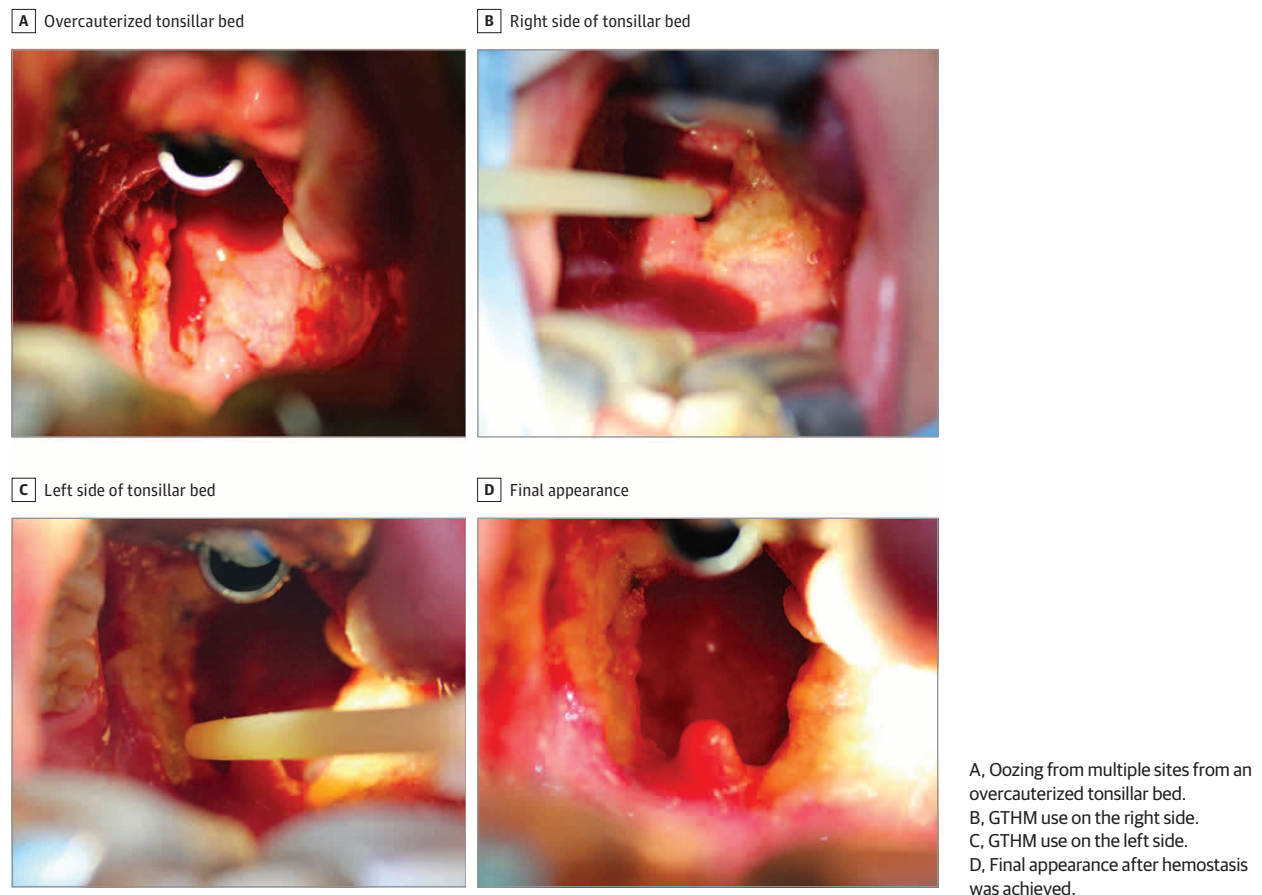
were reviewed retrospectively from the hospital records. All patients had basic screening tests for bleeding disorders: complete blood cell count, prothrombin time/partial thromboplastin time, international normalized ratio, bleeding time or platelet function assay, thrombin time, peripheral blood smear review, and fibrinogen. In addition, in patients with a suspected bleeding diathesis, a detailed bleeding panel was performed; factor assays of II, V, VII, VIII, IX, X, XI, and XII; von Willebrand factor antigen and activity (Ristocetin assay); mixing studies; a coagulation factor inhibitor panel; platelet aggregation studies; platelet-associated immunoglobulin levels; PAI-1 activity and alpha 2-antiplasmin levels; and activated protein C resistance testing. Preoperative blood transfusion was performed for patients with decreased hemoglobin level (<7 g/dL [70 g/L]) and/or symptoms of tachycardia and hypotension.

After obtaining written informed consent from the parents, all patients underwent urgent bleeding control under general anesthesia in the operating room with the use of GTHM. After bleeding was controlled, intravenous fluids and amoxicillin-clavulanic acid were given. For pain management, paracetamol was used. Nonsteroid anti-inflammatory drugs were avoided owing to possible platelet dysfunction.⁵ Oral intake was started on day 1 following the procedure.

Surgical Technique

General anesthesia was given to all patients. Blood transfusion was performed if indicated intraoperatively. Patients were closely monitored and, after normothermia, normovolemia, and an adequate hemoglobin level (>10 g/dL) were obtained, intubation was performed, and the procedure began. The patients were put in Rose position, in which both the head and neck are extended and a silicone bag is placed under the shoulder blades. A Boyle-Davis mouth gag was placed to obtain an optimum surgical field for bleeding control. In patients with bleeding from one source that originated from a vein or artery, bleeding control was obtained by traditional methods (bipolar cautery or ligation), whereas GTHM was used to obtain hemostasis in patients with diffuse bleeding or multiple bleeding sites from the tonsillar bed, or who were found to have excessive cauterization from prior surgery. Five milliliters of GTHM were squeezed onto the area to cover the bleeding site

Figure. Intraoperative Use of Gelatin-Thrombin Hemostatic Matrix (GTHM)



and the tonsillar bed. Next, the area was gently compressed with a surgical gauze pad for 5 minutes to obtain equal distribution of the hemostatic agent over the tonsillar bed (Figure).

After the procedure, the criteria for discharge included a nonbleeding tonsillar bed, adequate oral intake, and no need for blood transfusion.

Outcome Parameter

Postoperative follow-up medical records were evaluated to determine whether further bleeding necessitating intervention occurred.

Statistical Analysis

Statistical analyses were performed using SPSS software (version 15.0 for Windows; SPSS Inc). The sample characteristics are presented as numbers, means (SDs), and ranges. Differences in the group were analyzed with McNemar test, and significance was set at $P < .05$.

Results

The study population comprised 22 boys (52%) and 20 girls (48%) (a total of 42 patients), and the mean (SD) age was 7 (2.7) years (range, 4-14 years). Two patients had presented with re-

current secondary bleeding necessitating multiple operations, but the others had only 1 episode. The mean day of occurrence of bleeding was on the eighth day (range, day 7-12; median, day 10). Only 2 patients required blood transfusions: they were the same patients who underwent multiple operations for recurrent episodes of secondary bleeding. Importantly, after treatment with GTHM at our institution, there were no recurrences of posttonsillectomy bleeding in 41 of the 42 patients during the 3-month follow-up period.

On physical examination, 32 patients were found to have unilateral diffuse oozing from the tonsillar beds, and 10 showed bilateral diffuse oozing. Nine patients had tonsillectomy with the use of bipolar electrocautery at our institution. Of the 33 patients who had tonsillectomies at other facilities, 14 had operations with the use of bipolar electrocautery; 13 had thermal welding; and the rest (6), had monopolar electrocautery.

One 10-year-old patient had recurrent secondary hemorrhagic episodes that required 4 different operations. Bipolar cauterization was performed the first 3 times at another facility before she was referred to our hospital after bleeding recurred the fourth time. Physical examination on her arrival showed extensive cauterization of the tonsillar bed with multiple sites of oozing. A detailed bleeding panel was performed because of suspected bleeding diathesis. However, results of all the coagulation tests were in normal limits. Bleeding

was due to overcauterization, so we decided to use GTHM for bleeding control to prevent further tissue necrosis (Figure). After bleeding was controlled, it did not recur, and the patient was discharged on day 4 when she achieved adequate oral intake. Follow-up on day 14 showed complete reepithelization of the surgical sites.

The other patient with recurrent hemorrhage was a 6-year-old boy with a history remarkable for the fact that he was conceived by in vitro fertilization after 13 unsuccessful attempts. He had 5 episodes of secondary bleeding. The first occurred on day 10, with a single focus of bleeding from the left upper pole, and bleeding was stopped with bipolar cautery. On day 16, he had diffuse bleeding from the left tonsillar bed, and GTHM was used to obtain hemostasis. On day 26, he developed a massive pulsatile hemorrhage from the left tonsillar bed, and digital subtraction angiography was performed in the operating room to determine the source. The study showed that the external carotid artery (ECA) was eroded just distal to the bifurcation point, with an eroded segment of 2.42 mm, and embolization was successfully performed at that time. On day 28, again there was massive pulsatile bleeding from the left tonsillar bed. On repeated neck exploration, an area of necrosis of the ECA and a portion of the common carotid artery (CCA) were found. The occlusion test demonstrated adequate contralateral circulation in the circle of Willis; therefore, the ECA was ligated with a hemoclip, and the necrosed segment of CCA was excised and an end-to-end anastomosis was performed. A pectoralis myocutaneous flap was used to seal the tonsillar bed. On day 30, a hematoma developed in the left side of the neck, requiring neck exploration once more. There was bleeding from the CCA with extensive necrosis. Owing to the amount of necrosis, the proximal and distal stumps of the CCA and the ICA were ligated. After the operation, no neurological sequelae were noted, and the patient was discharged on day 40. At follow-up 1 year later, he showed no evidence of long-term complications.

Discussion

In this study, we evaluated the efficacy of GTHM for controlling secondary bleeding after pediatric tonsillectomy. We found that GTHM to be an effective product for this application, particularly for patients with multiple bleeding sites and/or an overcauterized tonsillar bed. Although tonsillectomy is one of the most commonly performed surgical procedures in the pediatric population across the world, it is still one of the greatest challenges for otorhinolaryngologists owing to bleeding complications, which can sometimes be fatal.¹ There are new surgical and hemostatic techniques (eg, thermal welding, bipolar radiofrequency, harmonic scalpel, and laser); however, morbidity remains a major problem.^{6,7} Posttonsillectomy bleeding is a serious complication that causes significant morbidity, with rates of 0.28% to 20% (variable rates have been reported with different surgical techniques), and rare mortality.⁸

Lowe and van der Meulen⁹ reported that the rate of secondary bleeding after tonsillectomy depends on the surgical technique: they found the postoperative bleeding rate to be

higher for bipolar diathermy tonsillectomy than with the cold knife technique. In addition, the rates of bleeding and pain after tonsillectomy has been shown in several studies to be increased with cauterization.^{10,11}

In many studies involving other surgical sites, it has been shown that GTHM controls intraoperative and postoperative bleeding effectively. These procedures have included prostatectomy, thoracolumbar spinal surgery, thyroidectomy, and dacryocystorhinostomy.¹²⁻¹⁵ Gall et al¹⁶ prospectively studied 18 patients to examine GTHM use for bleeding after endoscopic sinus surgery. They reported that it is safe and effective for use during and after surgery, and does not affect wound healing.

Docimo et al¹⁴ studied 206 patients who were separated into 4 groups according to the hemostatic technique used: standard total thyroidectomy, harmonic scalpel, GTHM, and a combination of the harmonic scalpel and GTHM. They reported that the combination of the harmonic scalpel and GTHM is effective for reducing postsurgical drain output and providing a complementary hemostatic approach in patients undergoing total thyroidectomy. Côté et al¹⁷ performed a prospective clinical trial on epistaxis patients with continued hemorrhage after adequate nasal packing. Their results suggest that GTHM is highly effective in the treatment of persistent epistaxis.

Mathiasen and Cruz¹⁸ looked at GTHM use vs cauterization for the treatment of intraoperative bleeding during adenoidectomy in 70 patients. They found that, compared with cauterization, procedures done using GTHM took significantly less time to achieve hemostasis and were associated with less blood loss. Furthermore, the patients treated with GTHM returned to a regular diet sooner and used less prescription pain medication. Jo et al¹⁹ performed a prospective, randomized clinical trial of 68 consecutive patients undergoing cold steel adenotonsillectomy. Patients received either GTHM or electrocautery for hemostasis, and the efficacy of the 2 treatments was compared. Results showed that patients treated with GTHM had shorter operative times, less blood loss, less postoperative pain, and use of pain medications, a faster return to oral intake, and faster mobility.

Similar to these studies, we used GTHM as a hemostatic agent to obtain control of secondary bleeding in pediatric patients with diffuse or multiple tonsillar bleeding sites, and/or with bleeding associated with overcauterization. We found GTHM to be an effective agent for this application. This is very important because, in cases such as these, traditional cauterization techniques cannot be used.

It is important to state that multiple bleeding episodes, younger age, higher difference of preoperative and postoperative hemoglobin concentration, inadequate oral intake, and secondary infections are the comorbid factors that can prolong hospitalization and follow-up period. For such patients, hospitalization, and follow-up period should be individualized. They should be hospitalized until they attain normal hemoglobin concentration, adequate oral intake, and complete reepithelization. However, patients without comorbid factors can be discharged after 1 day of hospitalization, and should be followed up on an outpatient basis on postoperative days 2, 4, 7, and 14 until complete reepithelization is achieved.

In this study, we did not gather information on the operative time or degree of pain reported by the patients. Furthermore, an important drawback for our study was the absence of a control group. This can be explained by the fact that traditional cauterization techniques were not used in study patients owing to the risk of further tissue necrosis. However, the use of a control group would have allowed comparisons between groups for different parameters such as these. Future studies on secondary posttonsillectomy bleeding events comparing GTHM use with other bleeding control methods are necessary to confirm its associated benefits in this setting. Furthermore, greater numbers of

patients with the inclusion of a control group are required to determine the true efficacy of GTHM treatment for secondary posttonsillectomy bleeding.

Conclusions

This results of this study suggest that GTHM is a simple, safe, and effective technique that can be used as a first-line treatment for a patient with secondary posttonsillectomy bleeding characterized by oozing from multiple sites and/or from an overcauterized tonsillar bed.

ARTICLE INFORMATION

Accepted for Publication: May 11, 2016.

Published Online: July 14, 2016.
doi:10.1001/jamaoto.2016.1678.

Author Contributions: Dr Binnetoglu had full access to all of the data in the study and takes responsibility for the integrity of the data and the accuracy of the data analysis.

Study concept and design: All authors.

Acquisition, analysis, or interpretation of data: Binnetoglu, Demir, Baglam.

Drafting of the manuscript: Binnetoglu, Demir, Baglam.

Critical revision of the manuscript for important intellectual content: Yumusakhuylu, Baglam, Sari.

Statistical analysis: Binnetoglu, Demir.

Administrative, technical, or material support: Binnetoglu, Demir, Baglam, Yumusakhuylu.

Study supervision: Binnetoglu, Baglam, Sari.

Conflict of Interest Disclosures: All authors have completed and submitted the ICMJE Form for Disclosure of Potential Conflicts of Interest, and none were reported.

Additional Information: This work was done in Pendik Training and Research Hospital, Marmara University Medical Faculty.

REFERENCES

- National Center for Health Statistics. Ambulant and inpatient procedures in the United States. In: *Vital and Health Statistics. DHHS Publications No. (PHS) 98-1793*. Hyattsville, MD: Public Health Service; 1994.
- Randall DA, Hoffer ME. Complications of tonsillectomy and adenoidectomy. *Otolaryngol Head Neck Surg*. 1998;118(1):61-68.
- Oz MC, Cosgrove DM III, Badduke BR, et al; Fusion Matrix Study Group. Controlled clinical trial of a novel hemostatic agent in cardiac surgery. *Ann Thorac Surg*. 2000;69(5):1376-1382.
- Renkens KL Jr, Payner TD, Leipzig TJ, et al. A multicenter, prospective, randomized trial evaluating a new hemostatic agent for spinal surgery. *Spine (Phila Pa 1976)*. 2001;26(15):1645-1650.
- D'Souza JN, Schmidt RJ, Xie L, Adelman JP, Nardone HC. Postoperative nonsteroidal anti-inflammatory drugs and risk of bleeding in pediatric intracapsular tonsillectomy. *Int J Pediatr Otorhinolaryngol*. 2015;79(9):1472-1476.
- Parsons SP, Cordes SR, Comer B. Comparison of posttonsillectomy pain using the ultrasonic scalpel, coblator, and electrocautery. *Otolaryngol Head Neck Surg*. 2006;134(1):106-113.
- Chimona T, Proimos E, Mamoulakis C, Tzanakakis M, Skoulakis CE, Papadakis CE. Multiparametric comparison of cold knife tonsillectomy, radiofrequency excision and thermal welding tonsillectomy in children. *Int J Pediatr Otorhinolaryngol*. 2008;72(9):1431-1436.
- Liu JH, Anderson KE, Willging JP, et al. Posttonsillectomy hemorrhage: what is it and what should be recorded? *Arch Otolaryngol Head Neck Surg*. 2001;127(10):1271-1275.
- Lowe D, van der Meulen J; National Prospective Tonsillectomy Audit. Tonsillectomy technique as a risk factor for postoperative haemorrhage. *Lancet*. 2004;364(9435):697-702.
- Mitic S, Tinnereim M, Lie E, Saltyte BJ. A pilot randomized controlled trial of coblation tonsillectomy versus dissection tonsillectomy with bipolar diathermy haemostasis. *Clin Otolaryngol*. 2007;32(4):261-267.
- Ferri E, Armato E, Capuzzo P. Argon plasma coagulation versus cold dissection tonsillectomy in adults: a clinical prospective randomized study. *Am J Otolaryngol*. 2007;28(6):384-387.
- Martorana E, Ghaith A, Micali S, et al. A retrospective analysis of the hemostatic effect of FloSeal in patients undergoing robot-assisted laparoscopic radical prostatectomy. *Urol Int*. 2016;96(3):274-279.
- Gazzeri R. Commentary on: Efficacy, security, and manageability of gelified hemostatic matrix in bleeding control during thoracic and lumbar spine surgery: FloSeal vs Surgiflo. *J Neurol Surg A Cent Eur Neurosurg*. 2016;77(2):143-145.
- Docimo G, Tolone S, Conzo G, et al. A gelatin-thrombin matrix topical hemostatic agent (FloSeal) in combination with harmonic scalpel is effective in patients undergoing total thyroidectomy: a prospective, multicenter, single-blind, randomized controlled trial. *Surg Innov*. 2016;23(1):23-29.
- Durrani OM, Fernando AI, Reuser TQ. Use of a novel topical hemostatic sealant in lacrimal surgery: a prospective, comparative study. *Ophthal Plast Reconstr Surg*. 2007;23(1):25-27.
- Gall RM, Witterick IJ, Shargill NS, Hawke M. Control of bleeding in endoscopic sinus surgery: use of a novel gelatin-based hemostatic agent. *J Otolaryngol*. 2002;31(5):271-274.
- Côté D, Barber B, Diamond C, Wright E. FloSeal hemostatic matrix in persistent epistaxis: prospective clinical trial. *J Otolaryngol Head Neck Surg*. 2010;39(3):304-308.
- Mathiasen RA, Cruz RM. Prospective, randomized, controlled clinical trial of a novel matrix hemostatic sealant in children undergoing adenoidectomy. *Otolaryngol Head Neck Surg*. 2004;131(5):601-605.
- Jo SH, Mathiasen RA, Gurushanthaiah D. Prospective, randomized, controlled trial of a hemostatic sealant in children undergoing adenotonsillectomy. *Otolaryngol Head Neck Surg*. 2007;137(3):454-458.