

Case Report

Severe hypogammaglobulinaemia and opportunistic infections after rituximab therapy in a renal transplant recipient

Arzu Kahveci, Ebru Asicioglu, Elif Ari, Hakki Arikan, Serhan Tuglular and Cetin Ozener

Division of Nephrology, Department of Internal Medicine, Marmara University School of Medicine, Istanbul, Turkey

Correspondence and offprint requests to: Arzu Kahveci; E-mail: drarzukahveci@yahoo.com

Abstract

Infectious complications are the leading causes of morbidity and mortality among renal transplant recipients. Hypogammaglobulinaemia may develop as a result of immunosuppressive therapy and is associated with an increased risk of opportunistic infections particularly in the 6-month post-transplant period. Rituximab, which is used for antibody-mediated rejection (AMR), may also contribute to the development of hypogammaglobulinaemia via B-cell depletion. Intravenous immunoglobulin replacement may be beneficial in this setting. With the following case report, we aim to increase the awareness of opportunistic infections and severe hypogammaglobulinaemia in renal transplant recipients treated with rituximab for acute AMR.

Keywords: hypogammaglobulinaemia; infection; renal transplantation; rituximab

Introduction

Acute antibody-mediated rejection (AMR) has been observed in up to 8% of patients after renal transplantation, resulting in allograft loss [1]. The monoclonal anti-CD20 antibody rituximab has been used successfully in patients resistant to conventional treatment for AMR [2]. In this population, long-term effects of rituximab in regard to hypogammaglobulinaemia and infectious complications are not exactly known. With the following report, we aim to increase the awareness of opportunistic infections and severe hypogammaglobulinaemia (level of IgG < 3.5 g/L) in patients treated with rituximab for acute AMR.

Case report

A 43-year-old male underwent renal transplantation from his 3/6-matched, ABO-compatible uncle in May 2008. He presented to the hospital with general malaise, cough and fever in December 2008. His primary renal disease was chronic glomerulonephritis, and he had been on peritoneal

dialysis without residual renal function since 2005. Pre-transplant crossmatch was negative and panel-reactive antibodies were not available. Immunosuppression consisted of daclizumab for induction, and corticosteroids, tacrolimus and mycophenolate mofetil (MMF) for maintenance therapy. Even though the urine output was 1500 cc on the first post-transplant day, it decreased to 400 cc on the second day. Colour duplex sonography was normal, and a renal biopsy was performed. The biopsy showed acute AMR with immunostaining for C4d. He received 10 courses of plasma exchange therapy and four infusions of rituximab (375 mg/m²/week for 4 weeks). His renal function improved significantly with the serum creatinine level stabilizing at 132.6 µmol/l (1.5 mg/dl) under maintenance immunosuppressive therapy with prednisolone (15 mg/day), tacrolimus (3 mg/day) and MMF (1000 mg/day). The mean tacrolimus level was 9.2 ng/ml during the follow-up.

In July 2008, he developed cytomegalovirus (CMV) viraemia, without invasive tissue disease with CMV pp65 antigenaemia (by the immunofluorescent assay in peripheral blood: 11 positive cells per 2 × 10⁵ leucocytes) and positive PCR DNA. MMF was discontinued, and oral valganciclovir was administered for 3 weeks until CMV tests became negative. MMF was re-started with a dose of 500 mg/day. In the fourth month post-transplant, the CD-19⁺ B-cell count was 0% in peripheral blood, while the creatinine level was 179.5 µmol/l (2.03 mg/dl). In October 2008, he presented with diarrhoea due to *Salmonella typhi* infection that responded to ciprofloxacin treatment. Within the same month, he was hospitalized for *Escherichia coli* septicaemia and treated with meropenem and metronidazole. In December 2008, the patient required hospitalization in the intensive care unit for severe pneumonia. He was severely hypoxic and required oxygen therapy with non-invasive mechanical ventilation for respiratory support. The chest x-ray showed bilateral parenchymal infiltration. Laboratory results were as follows: white blood cells 1.5 × 10⁹/l (1.5 × 10³ µl), platelets 104 × 10⁹/l (104 × 10³ µl), haemoglobin 90 g/l (9.5 g/dl), C-reactive protein 348 mg/l (normal range <5 mg/l), BUN 35.7 mmol/l (100 mg/dl), creatinine 556.9 µmol/l (6.3 mg/dl), total protein 65 g/l (6.5 g/dl) and albumin 36 g/l (3.6 g/dl). MMF was

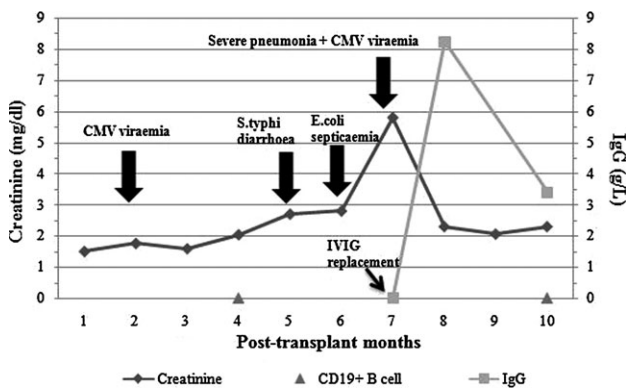


Fig. 1. Post-transplant course of the patient.

stopped because of pancytopenia. The galactomannan antigen assay in serum was positive. He was treated with cefepime, liposomal amphotericin B and trimethoprim-sulfamethoxazole for possible *Pneumocystis carinii* infection with adjusted doses for 14 days. Blood and deep tracheal aspirate sample cultures were negative. During this time, he developed cytomegalovirus viraemia (positive 40 cells per 2×10^5 leucocytes) that was treated with intravenous ganciclovir. Because of recurrent opportunistic infections, hypogammaglobulinaemia was suspected and confirmed. Gammaglobulin assays revealed severe hypogammaglobulinaemia: IgA 300 mg/l (normal range 700–4100 mg/l), IgM <186 mg/l (normal range 400–2200 mg/l) and IgG <1.45 g/l (normal range 7–16 g/l). Intravenous immunoglobulin (IVIg) was administered at a dose of 400 mg/kg for five consecutive days. Fourteen days after hospitalization, pneumonia resolved and the patient improved clinically. CMV antigenaemia and galactomannan levels were negative. MMF was re-initiated at a dose of 1000 mg/day in addition to tacrolimus (2 mg/day) and prednisolone (10 mg/day) after the leucocyte count increased. His creatinine level decreased to 182.1 $\mu\text{mol/l}$ (2.06 mg/dl) and was stable thereafter. During the 3-month follow-up, even though B-cell depletion persisted, no other severe infectious complication was noted in our patient (Figure 1).

Discussion

Secondary hypogammaglobulinaemia has been reported in solid organ transplant patients particularly during the 6-month post-transplant period [3]. The cause of hypogammaglobulinaemia is unclear in renal transplant recipients. Reductions in the number of total B cell and CD4⁺ T cells as well as B-cell dysfunction are thought to be responsible for the pathogenesis. The nature and intensity of the immunosuppressive therapy affect T-cell function, which in turn may alter B-cell function indirectly. High doses of steroids are lympholytic and may affect leucocyte activation. MMF may also affect B-cell function directly. Immunoglobulin production may be altered as a result of these directly or indirectly affected B-cell functions [4].

Rituximab, which is used for acute AMR, inhibits B-cell proliferation while inducing cellular apoptosis. This

in turn may aggravate the development of hypogammaglobulinaemia in a similar manner. Hypogammaglobulinaemia and persistent B-cell depletion have also been described in patients receiving rituximab for rheumatoid arthritis, systemic lupus erythematosus and haematological disorders [5–7]. Therefore, it may be logical to measure the CD19⁺ and CD20⁺ B-cell counts in peripheral blood along with gammaglobulin assays in patients treated with rituximab.

Hypogammaglobulinaemia is associated with severe opportunistic infections in solid organ recipients. Indeed, recently Broeders *et al.* showed that combined hypogammaglobulinaemia was associated with more frequent infections, in particular respiratory, in renal transplant patients [3]. Since the use of rituximab in renal transplant recipients, a trend towards an increased rate of infectious complications has been reported [8]. However, data on this consequence of rituximab therapy are scant, and most of the previously published reports describing the use of rituximab did not address infectious complications specifically. According to Grim *et al.*, the infectious complication rates were 48% versus 11% among rituximab recipients and non-rituximab recipients, respectively. However, all of these patients were ABO-incompatible or positive crossmatch renal transplant recipients who were also treated with plasmapheresis and antithymocyte globulin [8]. In three recently published articles, we noticed that patients treated with rituximab for acute AMR had various infection rates: 87% [9] and 43% [10,11]. According to these papers, infectious complications can be observed for up to 2 years in renal transplant recipients treated with rituximab. However, there were no control groups. We also noticed that there are no discernable trends among these studies. Although a significant reduction in infection rates after administration of IVIg among hypogammaglobulinaemic heart transplant recipients was observed [12], to our knowledge, there is no prospective trial addressing the impact of IVIg replacement on infectious outcomes in hypogammaglobulinaemic renal transplant recipients, in particular treated with rituximab.

There are a number of vulnerable points that must be addressed before generalizing our results to renal transplant recipients treated with rituximab. First, immunoglobulin levels were not measured before and after the use of rituximab in our patient, and this is the most important limitation of our argument. However, since our patient did not have any recurrent infections prior to rituximab therapy, it may be safe to assume that he also did not have hypogammaglobulinaemia. Secondly, a traditional dose of rituximab regimen (3–5 weekly 375 mg/m² doses) was given to our patient and it is still questioned whether the lowest effective dose of rituximab causes a decreased rate of infectious complications and hypogammaglobulinaemia. According to Mulley *et al.*, a low incidence of infectious events was observed in their cohort treated with a single low-fixed dose of rituximab (375 mg/m²) compared to the traditional dose described by Faguer *et al.*, 43% versus 87%, respectively [9,11].

In conclusion, renal transplant recipients treated with rituximab should be followed up closely for infections. Also, the monitoring of immunoglobulin levels and IVIg replacement as needed in high-risk patients receiving

intensive immunosuppressive therapy for rejection may help to prevent infectious complications.

Conflict of interest statement. None declared.

References

1. Crespo M, Pascual M, Tolkoff-Rubin N *et al.* Acute humoral rejection in renal allograft recipients: I. Incidence, serology and clinical characteristics. *Transplantation* 2001; 71: 652–658
2. Becker YT, Becker BN, Pirsch JD *et al.* Rituximab as treatment for refractory kidney transplant rejection. *Am J Transplant* 2004; 4: 996–1001
3. Broeders EN, Wissing KM, Hazzan M *et al.* Evolution of immunoglobulin and mannose binding protein levels after renal transplantation: association with infectious complications. *Transpl Int* 2008; 21: 57–64
4. Mawhorter S, Yamani MH. Hypogammaglobulinemia and infection risk in solid organ transplant recipients. *Curr Opin Organ Transplant* 2008; 13: 581–585
5. Edwards JC, Cambridge G, Leandro MJ. B cell depletion therapy in rheumatic disease. *Best Pract Res Clin Rheumatol* 2006; 20: 915–928
6. Walker AR, Kleiner A, Rich L *et al.* Profound hypogammaglobulinemia 7 years after treatment for indolent lymphoma. *Cancer Invest* 2008; 26: 431–433
7. Cooper N, Davies EG, Thrasher AJ. Repeated courses of rituximab for autoimmune cytopenias may precipitate profound hypogammaglobulinaemia requiring replacement intravenous immunoglobulin. *Br J Haematol* 2009; 146: 120–122
8. Grim SA, Pham T, Thielke J *et al.* Infectious complications associated with the use of rituximab for ABO-incompatible and positive cross-match renal transplant recipients. *Clin Transplant* 2007; 21: 628–632
9. Faguer S, Kamar N, Guilbeaud-Frugier C *et al.* Rituximab therapy for acute humoral rejection after kidney transplantation. *Transplantation* 2007; 83: 1277–1280
10. Tanriover B, Wright SE, Foster SV *et al.* High-dose intravenous immunoglobulin and rituximab treatment for antibody-mediated rejection after kidney transplantation: a cost analysis. *Transplant Proc* 2008; 40: 3393–3396
11. Mulley WR, Hudson FJ, Tait BD *et al.* A single low-fixed dose of rituximab to salvage renal transplants from refractory antibody-mediated rejection. *Transplantation* 2009; 87: 286–289
12. Carbone J, Sarmiento E, Palomo J *et al.* The potential impact of substitutive therapy with intravenous immunoglobulin on the outcome of heart transplant recipients with infections. *Transplant Proc* 2007; 39: 2385–2388

Received for publication: 15.4.09; Accepted in revised form: 5.10.09