Journal of Orthopaedics 21 (2020) 337–339

Contents lists available at ScienceDirect

Journal of Orthopaedics

journal homepage: www.elsevier.com/locate/jor

Comparison of proximal junctional kyphosis rate according to fusion level

Görkem Kıyak [a], Tevfik Balıkçı [b,*], Murat Bezer [c]

[a] Dept of Orthopaedic Surgery, Academic Hospital, Nuhkuyusu cad. No:94, 34664, Üsküdar, Istanbul, Turkey
[b] Dept of Orthopaedic Surgery, Medistate Hospital, Rüzgarlıbahçe Bahce Mahallesi Cumhuriyet Caddesi No:24 PK, 34805, Beykoz, İstanbul, Turkey
[c] Marmara University Hospital Fevzi Çakmak Mahallesi Muhsin Yazıcıoğlu cad NO 10 PK, 34899 Pendik, İstanbul

ARTICLE INFO

Keywords:
Proximal junctional kyphosis
Fusion level
Scheuermann's kyphosis

ABSTRACT

Introduction: There are two main accepted reasons of Proximal junctional kyphosis (PJK) after Scheuermann's kyphosis treatment; overcorrection of initial curve and fusion that is too short proximally. The purpose of this study was to evaluate the incidence of PJK in patients who have been previously treated for Schuermann's kyphosis with a curve exceeding 70° and corrected under 40° according to proximal fusion level T2 or T3.
Methods: We retrospectively evaluated 30 patients treated for Schuermann's kyphosis with single stage posterior only procedure. We included patients that we achieved at least 50% correction of the initial curve. The surgeries were performed at the same institution by a single senior spinal surgeon. Patients were divided into two groups according to proximal fusion level T2 (16 patients) or T3 (14 patients) and evaluated for PJK, follow-ups ended three years after surgery.
Results: Mean age was 22.7 in T2 and 21.6 years in T3 group. Mean preoperative Cobb angle was 78° in T2 and 78.7° in T3 group. The mean postoperative Cobb angle was 33.2° in T2 and 35° in T3 group. None of the patients showed neurologic complications. Four patients had PJK in T3 group and one needed revision.
Conclusions: Selecting T2 as the proximal fusion level in Schuermann's kyphosis may decrease the incidence of PKJ. Studies with a larger number of patients needed to verify our results.

1. Introduction

Scheuermann's disease is defined as an abnormal arcuate kyphosis that develops during adolescence.[1] Its etiology has been a matter of controversy, and essentially still is unknown.[2] Major criteria for the diagnosis of Scheuermann's kyphosis are irregular vertebral plates and wedging of more than 5° for at least three adjacent vertebrae at the apex of the curve.[3,4] It is the most common cause of severe thoracic kyphosis in adolescence with reported prevalence of 1%–8%.[5]

The initial treatment is nonoperative.[6] Treatment using a Milwaukee brace was shown to be effective to relieve pain and correct curves less than 70° in skeletally immature patients. This indication for brace treatment remains accepted.[7]

Operative management has been recommended for patients with progressive kyphosis over 70°, for patients with persistent back pain, and sometimes for unacceptable cosmetic deformity.[8,9]

According to studies in literature, Junctional kyphosis may occur in 20–30% of the cases.[10–12] Overcorrection of deformity (more than 50% of its initial curve) and fusion that is too short proximally and that does not include the whole kyphosis are two main reasons in studies.[10,13,14]

The aim of this study was to investigate the effect of proximal fusion level on PKJ in patients with Scheuermann's kyphosis whose deformity corrected more than 50% of initial curve.

2. Materials and methods

The study included a total of 30 patients divided into two groups according to the proximal fusion level T2 (16 patients) or T3 (14 patients) who underwent a single-staged correction by segmental all pedicle screw constructs. Patients who had a minimum two years clinic and radiologic follow-up included the study. Patients with an symptomatic kyphosis with a Cobb angle of 70° or more, a thoracic type Scheuermann's kyphosis, and no previous surgical treatment for the kyphosis were selected for retrospective follow-up. Indications for surgery were a failure of conservative treatment with progressive kyphosis or pain; thoracic (T2-T12) deformity of greater than 70° or thoracolumbar deformity (T2-L2) of greater than 40° or both; and radiographic wedging consistent with the diagnosis. All surgeries were performed by the same surgeon, and the surgical technique did not change during the course of the study.

* Corresponding author.
E-mail addresses: drgorkemkiyak@gmail.com (G. Kıyak), tevfikbalikci@hotmail.com (T. Balıkçı), drmuratbezer@gmail.com (M. Bezer).

https://doi.org/10.1016/j.jor.2020.06.016
Received 9 May 2020; Accepted 21 June 2020
Available online 8 July 2020
0972-978X/© 2020 Professor P K Surendran Memorial Education Foundation. Published by Elsevier B.V. All rights reserved.

Standardized long deformity radiographs, both posteroanterior and lateral, were obtained preoperatively, postoperatively, and at intervals until a minimum 3-year follow-up. Measurements were performed by an independent observer and angles were determined by the Cobb method on the standing lateral view.

Abnormal proximal junctional kyphosis was defined as.

- Proximal junction sagittal Cobb >10°
- Proximal junction sagittal Cobb of at least 10° greater than preoperative measurements.

The levels instrumented were determined by first determining the first lordotic disc space as described by Lowe and Kasten[10] and planning the distal level to be at the first vertebrae distal to this disc space. The instrumentation was planned proximally over the apex of the deformity. The upper end of the instrumentation was chosen on the basis of instrumenting over the apex of the deformity to normally aligned the thoracic spine.

3. Surgical procedure

The patients were uniformly placed on a Jackson type operating table with appropriate positioning. Standard midline approach utilized. After complete exposure of the spine, the interspinous ligaments are removed at each level. The spinous processes are then removed and stored to use later for bone grafting. Pedicle screw instrumentation was placed under fluoroscopic control and free hand technique. Bilateral pedicle screws instrumented to each and every segment at fusion level for all patients(Fig. 1). Ligamentum flavum is removed, and a partial bilateral laminectomy is performed with Kerrison rongeur at desired levels. The facet joints on both sides of a spinal level are removed, including the superior articulating facet of the lower vertebra and the inferior articulating facet of the upper vertebra. The inferior aspect of the spinous process of the upper vertebra is also removed. After the bone resection deformity corrected by gradual compression across the osteotomy site and cantilever bending. (Fig. 2 a, b). Anterior column height is gained by increasing height through the disc space. The lower lamina at all segments is decorticated for arthrodesis and bone grafting performed. After rod placement and kyphosis correction, final tightening ensues.

Ambulation with a hyperextension brace was allowed on the second day of surgery.

4. Results

From 2000 to 2012, 30 patients had single-staged posterior approach surgery combined with Smith-Petersen osteotomies. There were no reoperations for nonunion or instrumentation failure. All patients had, at least, 3-year follow-up.

İn T3 group mean age was 22.7 years (range 18–30). There were eleven male and three female patients. Mean pre operative Cobb angle was 78° (range 72°–85°) and 33.2° (range 28°–38°) post operatively. The amount of loss of correction at the final follow-up was 3° (range 0°–6°).

Mean deformity correction was 57.6° (range 53°–61°) at latest follow-up.

İn T2 group mean age was 21.6 years (range 17–28). There were ten male and six female patients. Mean preoperative Cobb angle was 78.7° (range 72°–84°) and 35° (range 29°–40°) postoperatively. The amount of loss of correction at the final follow-up was 4° (range 2°–8°).

Mean deformity correction was 53.8° (range 50°–59°) at latest follow-up.

İn four patients (all in T3 group) PJK observed. One patient with PKJ needed revision. There was one superficial wound infection treated with antibiotics. No early or late deep infections observed(Fig. 3).

Statistical analysis was performed with GraphPad Prism software (V 6.07.).

Clinical survival of surgeries, with PKJ as the end point, was, 100% for the T2 group and 71.4% for the T3 group. Survival curve comparison of two groups showed statistically significant difference according to both Mantel-Cox test and Gerhan-Breslow-Wilcoxon test ($P < 0.05$). (Fig. 4).

Fig. 1. Bilateral all pedicle screw placement.

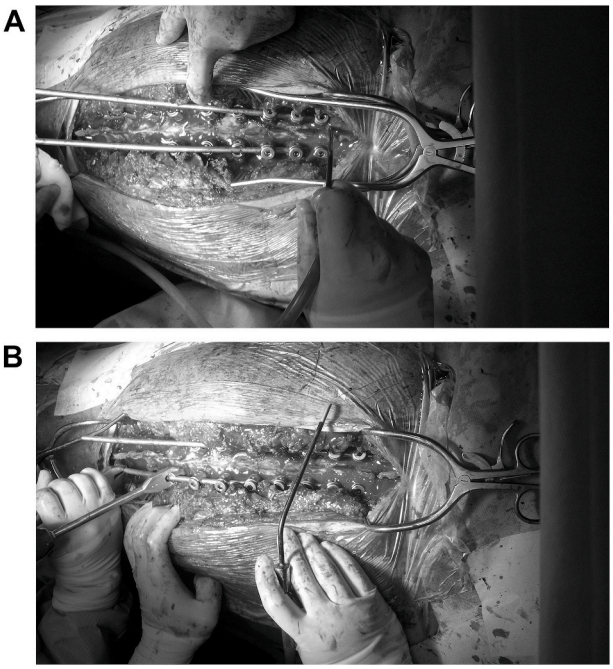

Fig. 2. 2a and 2b: Cantilever bending maneuver and deformity correction.

5. Discussion

Patients undergoing surgical treatment have major concerns about the cosmetic appearance of their back. Limited correction of deformity affects the patient satisfaction after surgery. The fear of over correction, proximal junctional kyphosis, and neurological damage prevents surgeons from achieving better cosmetic results and patient satisfaction.

Current intraoperative neurophysiological monitoring devices allow surgeons to place pedicle screws and correct deformity safely.[17] With this advancement in spinal surgery, neurological damage caused by deformity correction in Scheuermann's disease is not a big concern as it was used to. Spinal surgeons can able to correct kyphotic deformity under 40° with careful monitoring.

Lowe and Kasten reported Proximal junctional kyphosis occurred in five patients and was associated with overcorrection (>50%) of the kyphosis.[10] But recent studies did not find a correlation between the

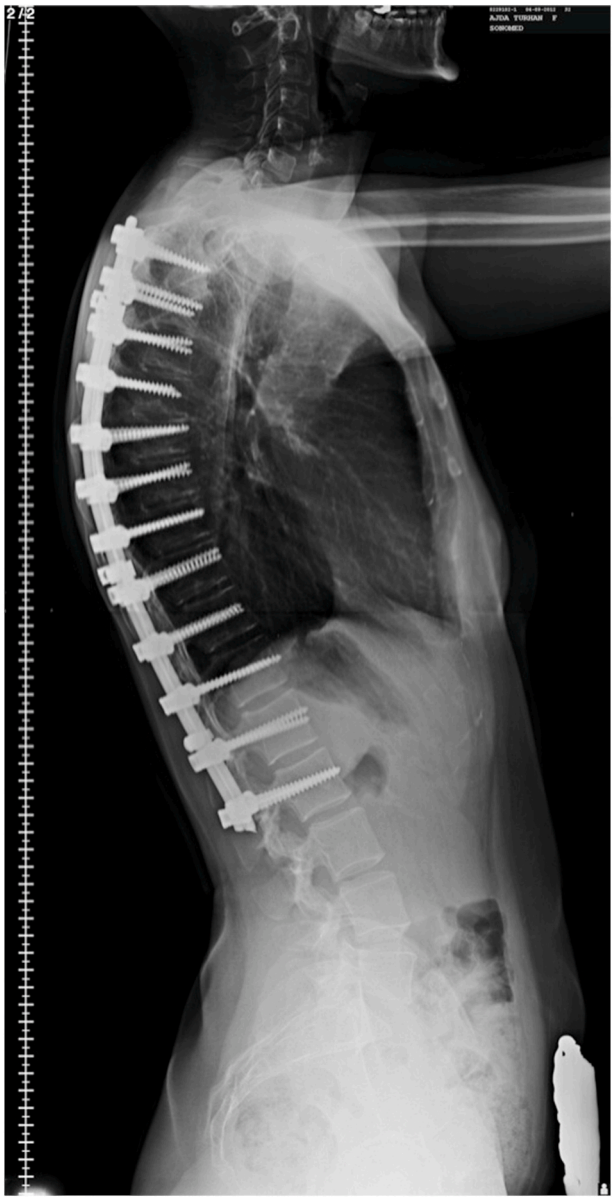

Fig. 3. Follow-up x-ray of patient no: 9 with PKJ in T3 group. This patient needed revision.

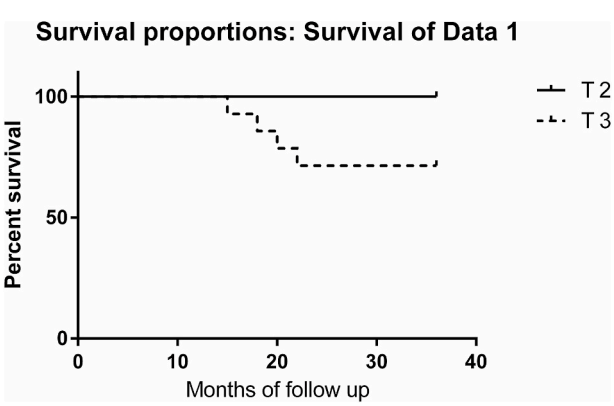

Fig. 4. Kaplan-Meier survivorship curves of two group.

amount of correction and proximal junctional kyphosis and focused on the upper most vertebra added to the instrumentation.[14–16]

Disruption of junctional ligamentum flavum that may lead PKJ can be avoided with careful dissection. However, this may cause inadequate visualization and difficulty in pedicle screw placement. A Study by Denis et al. stated that failure to incorporate the proximal end vertebra to instrumentation is the main reason for PKJ by far, and the most common cause of inappropriate end vertebra selection was a poor visualization of the upper thoracic vertebra.[18]

In our study all surgeries were performed by a single spinal surgeon at the same hospital. Surgical procedures, types of implants, the amount of deformity correction and surgical goals were all uniform. The only differential was proximal fusion level. The amount of deformity correction was not found correlated with PKJ in our study. All patients who developed PKJ had proximal fusion level as T3.

Selecting T2 as the proximal fusion level in Schuermann's kyphosis may decrease the incidence of PKJ. Studies with a larger number of patients needed to verify our results.

Declaration of competing interest

None.

References

1 Scheuermann HW. Kyphosis dorsalis juvenilis. *Ugeskr Laeger*. 1920;82:385.
2 Ascani E, La Rosa G. Scheuermann's kyphosis. In: Weinstein SL, ed. *The Pediatric Spine: Principles and Practice*. New York: Raven Press; 1994:557–584.
3 Bradford DS. Juvenile kyphosis. *Clin Orthop*. 1977;128:45–55.
4 Sorensen KH. *Scheuermann's Juvenile Kyphosis*. Copenhagen: Enjar Munksgaard Forlag; 1964, 214–22.
5 Wenger DR, Frick SL. Scheuermann kyphosis. *Spine*. 1999;24:2630–2639.
6 Bradford DS, Moe JH, Montalvo FJ, et al. Scheuermann's kyphosis and roundback deformity: results of Milwaukee brace treatment. *J Bone Joint Surg [Am]*. 1974;56: 740–758.
7 Murray PM, Weinstein SL, Spratt KF. The natural history and long-term follow-up of Scheuermann kyphosis. *J Bone Joint Surg Am*. 1993;75:236–248.
8 Albanese SH, Albanese SL. Management of Scheuermann's kyphosis. *Semin Spine Surg*. 1998;10:23–28.
9 Lowe TG. Current concepts review, Scheuermann disease. *J Bone Joint Surg Am*. 1990;72:940–945.
10 Lowe TG, Kasten MD. An analysis of sagittal curves and balance after Cotrel-Dubousset instrumentation for kyphosis secondary to Scheuermann's disease. A review of 32 patients. *Spine*. 1994;19:1680–1685.
11 Glattes RC, Bridwell KH, Lenke LG, et al. Proximal junctional kyphosis in adult spinal deformity following long instrumented posterior spinal fusion: incidence, outcomes and risk factor analysis. *Spine*. 2005;30:1643–1649.
12 Denis F, Sun EC, Winter RB. Incidence and risk factors for proximal and distal junctional kyphosis following surgical treatment for Scheuermann kyphosis. *Spine*. 2009;34:E729–E734.
13 Hosman AJ, de Kleuver M, Anderson PG, et al. Analysis of the sagittal plane after surgical management for Scheuermann's disease: a view on overcorrection and the use of an anterior release. *Spine*. 2002;27:167–175.
14 Lonner BS, Newton P, Betz R, et al. Operative management of Scheuermann's kyphosis in 78 patients. Radiographic outcomes, complications, and technique. *Spine*. 2007;32:2644–2652.
15 Yanık HS, Ketenci IE, Polat A, et al. Prevention of proximal junctional kyphosis after posterior surgery of Scheuermann kyphosis: an operative technique. *J Spinal Disord Tech. Mar;*. 2015;28(2):E101–E105.
16 Hamzaoglu A, Ozturk C, Korkmaz MF, Karatoprak O, Enercam M, Tezer M. A new technique to prevent proximal junctional kyphosis in the surgical treatment of Schuermann disease. *NASS 24th Annual meeting/Spine J*. 2009;9. IS – 205S.
17 M1 Gavaret, Jouve JL, Péréon Y, et al. Intraoperative neurophysiologic monitoring in spine surgery. Developments and state of the art in France in 2011. *Orthop Traumatol Surg Res*. 2013 Oct;99(6 Suppl):S319–S327.
18 Dennis F, Sun EC, Winter RB. Incidence and risk factors for proximal and distal junctional kyphosis following surgical treatment for Scheuermann kyphosis: minimum five-year follow-up. *Spine*. 15 September 2009;34(20):E729–E734.