

## Whole lung lavage for pulmonary alveolar proteinosis: still the most up-to-date treatment

*Pulmoner alveoler proteinozis için tüm akciğer lavajı: Hala en güncel tedavi*

Tunç Laçın,<sup>1</sup> Bedrettin Yıldızeli,<sup>1</sup> Emel Eryüksel,<sup>2</sup> Berrin Ceyhan,<sup>2</sup> Sait Karakurt,<sup>2</sup>  
Nural Bekiroğlu,<sup>3</sup> Turgay Çelikel,<sup>2</sup> Mustafa Yüksel<sup>2</sup>

*Institution where the research was done:*

Marmara University Pendik Training and Research Hospital, İstanbul, Turkey

*Author Affiliations:*

Departments of <sup>1</sup>Thoracic Surgery, <sup>2</sup>Chest Diseases, Marmara University Pendik Training and Research Hospital, İstanbul, Turkey

<sup>3</sup>Departments of Biostatistics, Marmara University, Faculty of Medicine, İstanbul, Turkey

### ABSTRACT

**Background:** This study aims to evaluate the significance of whole lung lavage on prelavage and postlavage blood gas analysis values of patients with pulmonary alveolar proteinosis.

**Methods:** Data of nine patients (1 male, 8 females; mean age 38.2 years; range 29 to 60 years) who were diagnosed to have pulmonary alveolar proteinosis with interventional techniques between January 1998 and May 2010 at Marmara University Hospital Department of Thoracic Surgery were reviewed. Patients' prelavage pulmonary function tests, pre- and postlavage blood gas analyses, and radiologic images were evaluated. Restrictive ventilatory pattern and impaired gas exchange were detected and whole lung lavage was performed in all patients.

**Results:** No major complications were observed during whole lung lavage. Each lung was washed with 15-30 L of physiological saline solution. Patients were followed-up in the intensive care unit intubated for a mean of 2.6 days (range, 1 to 16 days). Mean duration of stay at intensive care unit was 3.5 days (range, 1-16 days). One patient died 16 days after her fifth lavage due to respiratory arrest during an attempt for percutaneous tracheostomy. Increment of the postlavage partial pressures of oxygen and oxygen saturations was statistically significant. All patients showed subjective improvement.

**Conclusion:** Our experience suggests that whole lung lavage is a safe technique when strict adherence to lavage protocol is maintained. Postlavage symptomatic relief is rapid and oxygenation improves significantly.

**Keywords:** Hypoxia; pulmonary alveolar proteinosis; whole lung lavage.

### ÖZ

**Amaç:** Bu çalışmada, pulmoner alveoler proteinozlu hastalarda tüm akciğer lavajının lavaj öncesi ve sonrası kan gazı analizi değerlerindeki önemi değerlendirildi.

**Çalışma planı:** Ocak 1998 - Mayıs 2010 tarihleri arasında Marmara Üniversitesi Hastanesi Göğüs Cerrahisi bölümünde girişimsel teknikler ile pulmoner alveoler proteinoz tanısı konulan dokuz hastanın (1 erkek, 8 kadın; ort. yaş 38.2 yıl; dağılım 29-60 yıl) verileri incelendi. Hastaların lavaj öncesi solunum fonksiyon testleri, lavaj öncesi ve sonrası kan gazı analizleri ve radyolojik görüntüleri değerlendirildi. Tüm hastalarda restriktif solunum paterni ve bozulmuş gaz değişimi tespit edildi ve tüm akciğer lavajı uygulandı.

**Bulgular:** Tüm akciğer lavajı sırasında majör komplikasyon görülmedi. Her akciğer 15-30 L serum fizyolojik solüsyonu ile yıkandı. Hastalar ortalama 2.6 gün (dağılım, 1-16 gün) entübe olarak yoğun bakım ünitesinde takip edildi. Ortalama yoğun bakım yatış süresi 3.5 gün (dağılım, 1-16 gün) idi. Bir hasta beşinci lavajından 16 gün sonra perkütan trakeostomi açılırken solunum durması nedeniyle kaybedildi. Lavaj sonrası oksijen parsiyel basıncı ve oksijen saturasyonlarının yükselmesi istatistiksel olarak anlamlı idi. Bütün hastalarda subjektif düzelme görüldü.

**Sonuç:** Deneyimimize göre, lavaj protokolüne tamamen uyulursa tüm akciğer lavajı güvenilir bir tekniktir. Lavaj sonrası semptomatik düzelme hızlıdır ve oksijenizasyon anlamlı düzeyde iyileşir.

**Anahtar sözcükler:** Hipoksi; pulmoner alveoler proteinoz; tüm akciğer lavajı.



Available online at  
www.tgkdc.dergisi.org  
doi: 10.5606/tgkdc.dergisi.2017.13268  
QR (Quick Response) Code

Received: March 13, 2016 Accepted: March 30, 2016

Correspondence: Tunç Laçın, MD. Marmara Üniversitesi Pendik Eğitim ve Araştırma Hastanesi Göğüs Cerrahisi Anabilim Dalı, 34890 Üst Kaynarca, Pendik, İstanbul, Turkey. Tel: +90 532 - 702 52 24 e-mail: tunclacin@gmail.com

©2017 All right reserved by the Turkish Society of Cardiovascular Surgery.

Whole lung lavage is a method of choice to remove alveolar phospholipoproteins which are responsible for the gas-exchange abnormalities.<sup>[1]</sup> Idiopathic pulmonary alveolar proteinosis (PAP) is a rare lung disease of impaired alveolar macrophage function, suggesting mainly a defect in granulocyte-macrophage colony stimulating factor (GM-CSF) signaling.<sup>[2]</sup> Currently, PAP occurs in three clinically distinct forms which are acquired (or idiopathic), congenital, and secondary PAP.<sup>[2]</sup> Alveolar macrophages in acquired form of PAP show less chemotactic and phagocytic activity and reduced cellular adherence due to anti-GM-CSF antibodies.<sup>[2-5]</sup> The congenital form, characterized by an acute onset after birth, is caused by mutations of the genes encoding surfactant protein B or C or the GM-CSF receptor beta subunit, or ABCA3.<sup>[6-9]</sup> Secondary PAP develops in association with conditions involving functional impairment of alveolar macrophages which are inhalation of inorganic dust, malignancies, immunodeficiency disorders, hematologic disorders, and pharmacologic immunosuppression.<sup>[10]</sup>

In acquired PAP, dyspnea, the most common presenting symptom, and cough occur on mild to moderate exertion. Some patients may become symptomatic acutely after supervening infection. Physical examination is often normal, clubbing is present in about one third of cases. Patients with advanced disease may have central and peripheral cyanosis.<sup>[11]</sup>

The series reported in the literature suggest a male preponderance (male:female ratio 3:1). Peak onset is in the third or fourth decade of life with over 80% of reported cases occurring in this age group.<sup>[2]</sup> However, there are reports of the disease occurring in neonates, children, and the elderly.<sup>[5,12]</sup>

Because of the pathogenesis is not completely known, the current mainstay of treatment for PAP is the mechanical removal of the proteinaceous material which is responsible for the functional and gas-exchange abnormalities observed in this disorder via whole lung lavage. The main indication for whole lung lavage is presence of limitation in daily activities due to dyspnea. Although, to our knowledge, no randomized controlled studies are present, there are several studies showing improved exercise tolerance and symptoms. Objective improvements in pulmonary function, arterial oxygenation, and shunt fraction following whole lung lavage are also observed.<sup>[4,12]</sup> Radiological clearing occurs gradually in the first few days after lavage, the time period varying between individuals.<sup>[5,13]</sup> Whole lung lavage is associated with improvements in macrophage function and a decreased

incidence of opportunistic infections.<sup>[5,13]</sup> In this study, we aimed to evaluate the value of whole lung lavage on prelavage and postlavage blood gas analysis values of patients with PAP.

## PATIENTS AND METHODS

We retrospectively reviewed medical records of nine patients (1 male, 8 females; mean age 38.2 years; range 29 to 60 years) undergoing pulmonary alveolar lavage with the diagnosis of PAP between January 1998 and May 2010 at Marmara University Hospital Department of Thoracic Surgery. We performed a total of 19 lavages. Procedure was performed unilaterally, five times in one patient, once in two patients, and bilateral sequential lavage was done to the remaining. We followed-up the patients at the intensive care unit (ICU) after the procedure. The study protocol was approved by the Medical Faculty of Marmara University Ethics Committee. The study was conducted in accordance with the principles of the Declaration of Helsinki.

Pre-lavage evaluation included chest X-rays and high resolution computed tomographic (CT) scans of thorax, complete blood counts, arterial blood gas measurements, and pulmonary function testing. Pulmonary function tests of the whole group showed a restrictive ventilatory pattern with an impaired gas exchange. Bronchoscopy in eight patients and pathological examination of biopsied lingula in one patient confirmed the diagnosis of PAP.

For lung lavage, we chose the side to be washed depending on the distribution and severity of alveolar involvement as evidenced on radiologic images. Patients underwent double lumen intubation under general anesthesia. Both lungs were ventilated with 100% oxygen to eliminate nitrogen from the alveolar gas. We then isolated the lung to be treated at the end of the expiration. We instilled warm (36-37 °C) neutral sterile saline (0.9% saline with 0.6 mmol sodium bicarbonate per liter saline) into the lung through a closed system at the same rate as oxygen was adsorbed until the estimated functional residual capacity value has been reached. At this point, the lung was completely de-gassed and filled full of saline. We let tidal volume increments (500-1200 mL) of the saline into the lung under gravitational force at each cycle. We controlled the temperature, volume of saline instilled, and fluid balance carefully. After passive recovery of the opaque fluid over a closed silicon tube system, we began the next washing cycle. We performed vigorous chest percussion during all cycles of instillation and recovery. Every six-cycle, we changed the position from supine to left lateral or right lateral oblique



**Figure 1.** Appearance of viscous, milky lipoprotein material removed by lavage. Bottle on left was obtained from the very first cycle, precipitation of lipoprotein material at the bottom was noted. Bottle on right is from the last cycle of same patient.

position. The initial returns were typically very milky or turbid and we repeated the process of filling and draining the lungs with saline until the fluid recovered was clear (Figure 1). We performed whole lung lavage procedures in an identical way, each lung being lavaged with volumes of 15-30 L of saline solution. At the end of the procedure, the residual saline from the lung and resumed ventilation with 100% oxygen was drained and aspirated. We replaced the double lumen tube with a single lumen tube and examined the endobronchial system by a fiberoptic bronchoscope to check for the patency and to aspirate the remaining lavage fluid. Vital parameters such as arterial saturation of

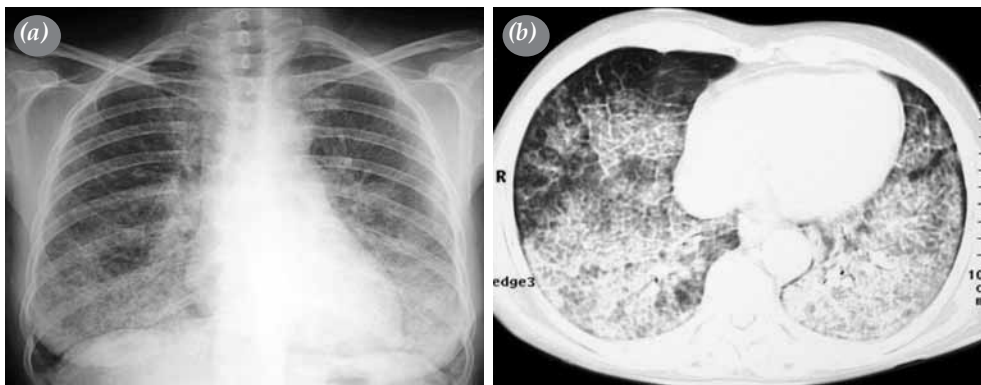
oxygen, central venous pressure, end-tidal carbon dioxide blood pressure, airway pressure, ventilation per minute, body temperature, and heart rate were recorded to control hemodynamic stability during the procedure. The patients were transferred to the ICU intubated and continued mechanical ventilation with positive end expiratory pressure (PEEP) of 7.5 cm H<sub>2</sub>O. Criteria for extubation were partial pressure of carbon dioxide <40 mmHg, partial pressure of oxygen (pO<sub>2</sub>) >65 mmHg, vital capacity >10 mL/kg, fraction of inspired oxygen <0.5, tidal volume >5 mL/kg, PEEP <5 cmH<sub>2</sub>O, and spontaneous respiration of 20-30/minute with no excessive or thick secretions. Chest radiographs were taken and arterial blood gases, electrolytes, and complete blood counts were measured routinely during the postlavage period. For staged lavages, we preferred an interval of at least one week.

### Statistical analysis

Prelavage and postlavage blood gas values were analyzed by Wilcoxon signed ranks test. We considered a *p* value of 0.05 or less to indicate a statistically significant outcome. Statistical analysis was performed with IBM SPSS version 19.0 software (IBM Corporation, Armonk, NY, USA).

## RESULTS

All patients with idiopathic PAP underwent whole lung lavage. The major symptom was dyspnea in all patients. Cough was the coexisting symptom in two patients. Chest radiographs demonstrated bilateral infiltration with reticular pattern and CT of thorax showed the appearance of wide spread air space consolidation, with bilaterally thickened interlobular septa (Figure 2). Prelavage arterial blood gases were



**Figure 2.** Radiographic appearance of pulmonary alveolar proteinosis. (a) A posteroanterior chest radiograph showing bilateral infiltrates. (b) High resolution computed tomography scan of the chest showing patchy areas of ground-glass opacification, appearance of wide spread air space consolidation, with bilaterally thickened interlobular septa.

**Table 1. Patient characteristics and preoperative blood gas analysis**

Patient no	Age/Gender	pH	pO <sub>2</sub>	pCO <sub>2</sub>	HCO <sub>3</sub>	SO <sub>2</sub> (%)	Habit
1	31/F	7.42	55.0	33.4	22.0	89.0	Nonsmoker
2*	40/F	7.45	86.0	29.0	20.2	96.9	Smoker
3	37/F	7.43	70.0	37.7	23.0	94.0	Nonsmoker
4*	41/M	7.41	50.7	34.9	21.9	86.0	Smoker
5	29/F	7.44	72.0	38.0	25.4	95.0	Nonsmoker
6*	30/F	7.43	47.7	41.8	26.8	84.5	Smoker
7*	46/F	7.42	61.7	34.3	22.2	92.0	Nonsmoker
8	60/F	7.47	60.0	33.1	23.7	92.6	Nonsmoker
9	32/F	7.42	75.0	37.0	24.0	93.0	Smoker

pH: Power of hydrogen; pO<sub>2</sub>: Partial pressure of oxygen; pCO<sub>2</sub>: Partial pressure of carbon dioxide; HCO<sub>3</sub>: Bicarbonate; SO<sub>2</sub>: Saturation of oxygen; \* Blood gas analysis under oxygen supply of 2 L/minute.

hypoxic in four patients (partial pO<sub>2</sub> ≤60 mmHg) although two of them were under oxygen supply of 2 L/minute (Table 1). Partial pO<sub>2</sub> of seventh patient was at the hypoxia limit while receiving oxygen supply of 2 L/minute. We performed a total of 19 lavage procedures to nine patients. No major complication occurred perioperatively. Mean duration of lavage was 233 minutes (range, 135 to 420 minutes). Total amount of the lavage fluid volume ranged between 15 to 30 L of saline solution. An average of 1.47 L (range, 0 to 4.2 L) of saline solution remained in the lung after the procedure. The patients remained intubated for 2.6 days (range, 1 to 16 days) after the procedure. Mean stay at ICU was 3.5 days (range, 1-16 days). One patient died on 16<sup>th</sup> postoperative day of her fifth lavage because of respiratory arrest during the attempt for percutaneous tracheostomy. Overall hospital stay was 5.4 days (range, 3 to 16 days).

Oxygen saturations and partial pressures of oxygen improved considerably after whole lung lavage and both oxygen saturations and partial pressures of oxygen were statistically significant (p<0.05). Median prelavage and postlavage measurements of oxygen saturation and pO<sub>2</sub> were 92% (range, 84% to 97%) and 95.5% (range, 87 to 97%), 60.8 mmHg

**Table 2. Table comparing median values of prelavage and postlavage oxygen saturation, partial pressure of oxygen, and carbon dioxide**

	Preoperative	Postoperative	<i>p</i>
SO <sub>2</sub> %	92	95.5	0.017
pO <sub>2</sub> mmHg	60.8	73.5	0.012
pCO <sub>2</sub> mmHg	34.6	35	0.327

SO<sub>2</sub>: Saturation of oxygen; pO<sub>2</sub>: Partial pressure of oxygen; pCO<sub>2</sub>: Partial pressure of carbon dioxide; Wilcoxon signed ranks test was used to analyze the values. Prelavage and postlavage values of oxygen saturation and partial pressures were statistically significant (p≤0.05).

(range, 47.7 to 86) and 73.5 mmHg (range, 64 to 88), respectively (Table 2).

## DISCUSSION

Pulmonary alveolar proteinosis, first described by Rosen *et al.*<sup>[14]</sup> in 1958, is a rare disease of impaired alveolar macrophage function caused by neutralizing anti-GM-CSF autoantibodies and represents a syndrome with a number of possible etiologies.<sup>[2-9,15]</sup> Accumulation of phospholipoproteinaceous material in the alveoli results in a non-specific radiographic pattern of air space consolidation. The consolidation is usually bilateral and patchy and in some patients is very extensive, despite relatively mild respiratory symptoms. High resolution CT of thorax demonstrates the expected appearance of wide spread air space consolidation, but also thickened interlobular septa, clearly visible within the affected lung and producing the so-called crazy paving pattern.<sup>[5,16]</sup>

Although the appearance on high resolution CT scan of the thorax often indicates the diagnosis, it should be confirmed by analysis of bronchoalveolar lavage fluid. Milky fluid is usually obtained from bronchoalveolar lavage of an affected segment (Figure 1).<sup>[5]</sup> Increased levels of lactate dehydrogenase,<sup>[17]</sup> tumor markers,<sup>[18]</sup> mucin-like glycoprotein,<sup>[19]</sup> the surfactant proteins A,<sup>[20]</sup> and D<sup>[21]</sup> were also been recorded in PAP.

Because the pathogenesis is not completely known, the current mainstay of treatment for PAP is the mechanical removal of the proteinaceous material which is responsible for the functional and gas-exchange abnormalities observed in this disorder via whole lung lavage.<sup>[11,22,23]</sup> However, the severe hypoxemia in PAP patients and the difficulty of the technique have limited its application to medical centers and to more advanced cases.<sup>[24]</sup> The clinical

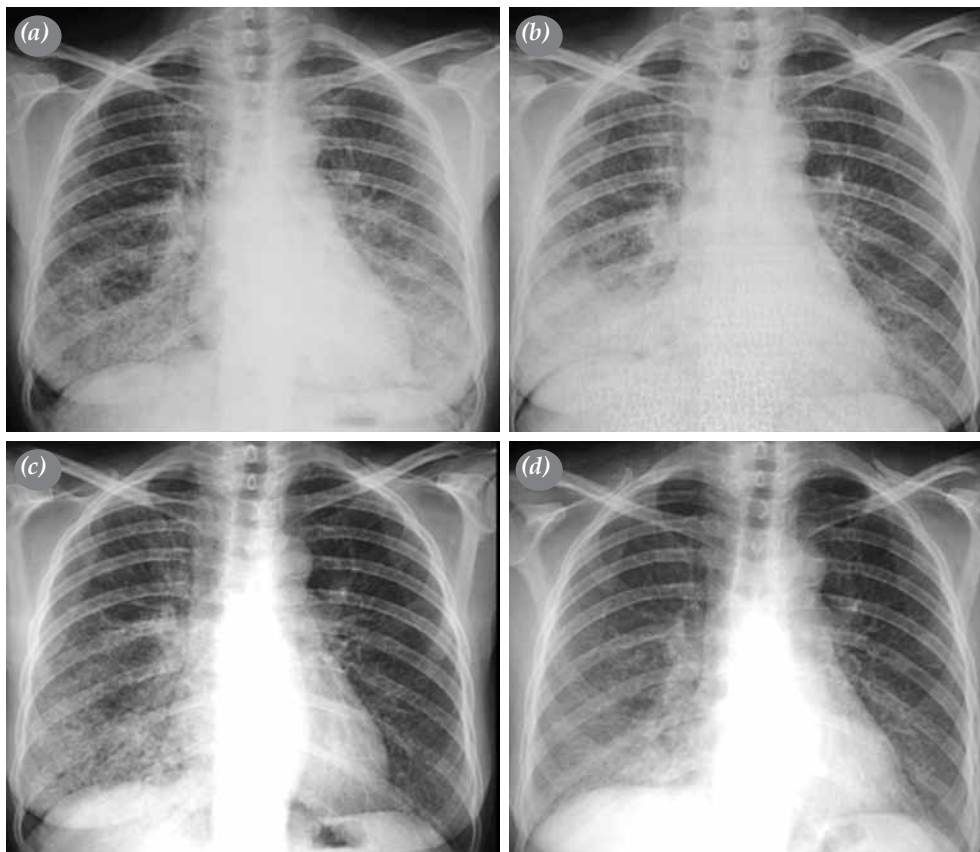
course and prognosis with or without bronchoalveolar lavage are variable. Some patients require lavage every few months while others remain in remission for several years.

Historically, corticosteroids, potassium iodide, and streptokinase were administered with variable success.<sup>[5]</sup> Diaz et al.<sup>[25]</sup> showed improvement in one patient with surfactant activator, ambroxol, although this would be expected to exacerbate the intraalveolar accumulation of surfactant. Some patients treated with aerosolized trypsin to hydrolyze the protein material developed allergic reaction. Treatment with GM-CSF is a possibility, although its long-term safety has not been determined.<sup>[3,5]</sup> An alternative procedure is selected segmental or lobar lavage by fiberoptic bronchoscopy (FOB). Lobar lavage by FOB is a simple and safe procedure that may be useful in patients with PAP in whom whole lung lavage via general anesthesia may be hazardous, and in patients with less advanced disease from whom proteinaceous

substances can be removed with a small volume of lavage fluid.<sup>[5,26-28]</sup>

Whole lung lavage is well tolerated by most patients despite concerns regarding the effect of a large-volume isotonic saline solution lavage on the lung. Safety measures include the correct placement of the double lumen endobronchial tube, checking for the leaks prior to lavage and close monitoring of the patient during the procedure. The short-term outcome and success of the procedure seem to depend on the capacity of the lung to rapidly remove the residual alveolar fluid that remains in the lung after lavage.<sup>[28]</sup>

In the study of Chesnutt et al.<sup>[28]</sup> a FOB inserted through the endobronchial tube was used to carry out sequential segmental lung lavage with serial 50 mL saline solution instillation to a total of 1.7 to 4.2 L. The authors demonstrated the rate and mechanism for removal of residual alveolar fluid after lung lavage. Alveolar epithelial clearance was rapid ( $53 \pm 14\%$ /hour) and appeared to be independent of catecholamine



**Figure 3.** Sixty-year-old female patient presenting with severe dyspnea, who was diagnosed to have PAP with bronchoscopic lavage. (a) Chest X-ray shows bilateral infiltrates of reticular pattern. A left lavage was performed first. (b) Immediate chest X-ray taken after left lavage. (c) Chest X-ray one month after left lavage, immediately before right. (d) Final X-ray after right lavage.

mechanism. This rapid rate of alveolar epithelial fluid transport explains why patients with PAP tolerate large volumes.<sup>[27]</sup> This study also provides the first data demonstrating a rapid rate of alveolar fluid clearance from the *in vivo* human lung in the absence of preexistent pulmonary edema.<sup>[28]</sup>

The major adverse effect of whole lung lavage is hypoxemia, particularly during the emptying phase, which decreases airway pressure and increases the perfusion of the lavaged lung.<sup>[5,29]</sup> Arterial oxygenation improves during the filling phase due to the increase in airway pressure and shunting of blood to the contralateral ventilated lung. Emptying of the lung causes a decrease in airway pressure and perfusion of the surfactant filled alveoli creates a shunt in the lung undergoing treatment and hence a fall in partial pO<sub>2</sub>.<sup>[5]</sup>

Hemodynamic instability may occur with single lung ventilation, which may necessitate invasive monitoring and further complicate the course of treatment.<sup>[29,30]</sup> Whole lung lavage requires general anesthesia and an experienced anesthesiologist. Leakage of the lavage fluid into the contralateral ventilated lung must be avoided.<sup>[24]</sup> Major risks of whole lung lavage concern the correct placement of the double lumen endobronchial tube. If placed wrongly, lavage fluid may spill into the ventilated lung. Barotrauma might occur with rapid instillation of large volumes of fluid. The repeated replacement of a double-lumen endotracheal tube may lead to endotracheal granuloma and stenosis. Other reported complications include pleural collections, hydropneumothoraces, and surgical emphysema.<sup>[11]</sup> The risk of hypothermia is minimized by careful monitoring of patient's core temperature. A postoperative care facility is also needed.<sup>[4,5]</sup>

During the follow-up, the major complication is infection with unusual organisms such as *Mycobacterium*, *Aspergillus*, *Pneumocystis carinii*, and various fungi and viruses.<sup>[5]</sup> One patient in our study received intravenous antibiotics covering Gram positive and negative organisms because of high fever (>38.5 °C) and recovered in five days. In our study, all patients received prophylactic broad spectrum antibiotics for 14 days postoperatively. Corticosteroids are not advised to be used as empirical treatment due to its potential to exacerbate opportunistic infections.<sup>[5]</sup>

Our study group showed significant improvement in management of the symptoms and oxygenation. Prelavage and postlavage values of oxygen saturation and partial pressures were statistically significant (Table 2). Postlavage X-rays showed clearance of the infiltrates (Figure 3). All patients are under

annual follow-up. All are symptomless except for a 33-year-old patient who is still smoking one pack/day, using home oxygen.

Our study was limited by its retrospective nature. The rarity of the disease limits the number of available patients for whole lung lavage. The number of patients evaluated in this study is low due to the single center nature.

In conclusion, whole lung lavage appears to be the most effective treatment of pulmonary alveolar proteinosis. Although this is a procedure that requires general anesthesia and has the risks of hemodynamic instability, leakage of lavage fluid into the contralateral lung, pleural collection, hydropneumothorax, emphysema, and endotracheal granuloma or stenosis because of repeated procedures, whole lung lavage is a reliable technique in experienced hands. A collaborative team of anesthesiologists and chest physicians should be involved in the management of the patient from the day of admission. The patient should be informed of the need for endotracheal tube and artificial ventilation in the immediate postoperative period. Whole lung lavage is a promising intervention in optimal treatment of pulmonary alveolar proteinosis providing significant improvements in oxygenation and symptoms.

#### Declaration of conflicting interests

The authors declared no conflicts of interest with respect to the authorship and/or publication of this article.

#### Funding

The authors received no financial support for the research and/or authorship of this article.

#### REFERENCES

1. Goldstein LS, Kavuru MS, Curtis-McCarthy P, Christie HA, Farver C, Stoller JK. Pulmonary alveolar proteinosis: clinical features and outcomes. *Chest* 1998;114:1357-62.
2. Trapnell BC, Whitsett JA, Nakata K. Pulmonary alveolar proteinosis. *N Engl J Med* 2003;349:2527-39.
3. Schoch OD, Schanz U, Koller M, Nakata K, Seymour JF, Russi EW, et al. BAL findings in a patient with pulmonary alveolar proteinosis successfully treated with GM-CSF. *Thorax* 2002;57:277-80.
4. Cheng SL, Chang HT, Lau HP, Lee LN, Yang PC. Pulmonary alveolar proteinosis: treatment by bronchofiberscopic lobar lavage. *Chest* 2002;122:1480-5.
5. Shah PL, Hansell D, Lawson PR, Reid KB, Morgan C. Pulmonary alveolar proteinosis: clinical aspects and current concepts on pathogenesis. *Thorax* 2000;55:67-77.
6. Nogee LM, Wert SE, Proffit SA, Hull WM, Whitsett JA. Allelic heterogeneity in hereditary surfactant protein B (SP-B) deficiency. *Am J Respir Crit Care Med* 2000;161:973-81.
7. Nogee LM, Dunbar AE, Wert S, Askin F, Hamvas A,

- Whitsett JA. Mutations in the surfactant protein C gene associated with interstitial lung disease. *Chest* 2002;121:20-1.
8. Dirksen U, Nishinakamura R, Groneck P, Hattenhorst U, Noguee L, Murray R, et al. Human pulmonary alveolar proteinosis associated with a defect in GM-CSF/IL-3/IL-5 receptor common beta chain expression. *J Clin Invest* 1997;100:2211-7.
  9. Shulenin S, Noguee LM, Annilo T, Wert SE, Whitsett JA, Dean M. ABCA3 gene mutations in newborns with fatal surfactant deficiency. *N Engl J Med* 2004;350:1296-303.
  10. Seymour JF, Presneill JJ. Pulmonary alveolar proteinosis: progress in the first 44 years. *Am J Respir Crit Care Med* 2002;166:215-35.
  11. Prakash UB, Barham SS, Carpenter HA, Dines DE, Marsh HM. Pulmonary alveolar phospholipoproteinosis: experience with 34 cases and a review. *Mayo Clin Proc* 1987;62:499-518.
  12. Paschen C, Reiter K, Stanzel F, Teschler H, Griese M. Therapeutic lung lavages in children and adults. *Respir Res* 2005;6:138.
  13. Claypool WD, Rogers RM, Matuschak GM. Update on the clinical diagnosis, management, and pathogenesis of pulmonary alveolar proteinosis (phospholipidosis). *Chest* 1984;85:550-8.
  14. Rosen SH, Castleman B, Liebow AA. Pulmonary alveolar proteinosis. *N Engl J Med* 1958;258:1123-42.
  15. Venkateshiah SB, Thomassen MJ, Kavuru MS. Pulmonary alveolar proteinosis. Clinical manifestations and optimal treatment strategies. *Treat Respir Med* 2004;3:217-27.
  16. Godwin JD, Müller NL, Takasugi JE. Pulmonary alveolar proteinosis: CT findings. *Radiology* 1988;169:609-13.
  17. Hoffman RM, Rogers RM. Serum and lavage lactate dehydrogenase isoenzymes in pulmonary alveolar proteinosis. *Am Rev Respir Dis* 1991;143:42-6.
  18. Hirakata Y, Kobayashi J, Sugama Y, Kitamura S. Elevation of tumour markers in serum and bronchoalveolar lavage fluid in pulmonary alveolar proteinosis. *Eur Respir J* 1995;8:689-96.
  19. Nakajima M, Manabe T, Niki Y, Matsushima T. Serum KL-6 level as a monitoring marker in a patient with pulmonary alveolar proteinosis. *Thorax* 1998;53:809-11.
  20. Kuroki Y, Tsutahara S, Shijubo N, Takahashi H, Shiratori M, Hattori A, et al. Elevated levels of lung surfactant protein A in sera from patients with idiopathic pulmonary fibrosis and pulmonary alveolar proteinosis. *Am Rev Respir Dis* 1993;147:723-9.
  21. Honda Y, Kuroki Y, Matsuura E, Nagae H, Takahashi H, Akino T, et al. Pulmonary surfactant protein D in sera and bronchoalveolar lavage fluids. *Am J Respir Crit Care Med* 1995;152:1860-6.
  22. Abdelmalak BB, Khanna AK, Culver DA, Popovich MJ. Therapeutic Whole-Lung Lavage for Pulmonary Alveolar Proteinosis: A Procedural Update. *J Bronchology Interv Pulmonol* 2015;22:251-8.
  23. Demirer E, Okutan O, Taş D, İncedayı M, Uysal A, Kartaloğlu Z, et al. Pulmonary alveolar proteinosis in Turkey: a review of twenty four cases. *Turk Gogus Kalp Dama* 2013;21:723-30.
  24. Cheng SL, Chang HT, Lau HP, Lee LN, Yang PC. Pulmonary alveolar proteinosis: treatment by bronchofiberscopic lobar lavage. *Chest* 2002;122:1480-5.
  25. Diaz JP, Manresa Presas F, Benasco C, Guardiola J, Munoz L, Clariana A. Response to surfactant activator (ambroxol) in alveolar proteinosis. *Lancet* 1984;1:1023.
  26. Dixit R, Chaudhari LS, Mahashur AA. Anaesthetic management of bilateral alveolar proteinosis for bronchopulmonary lavage. *Chest* 1998;113:1718-9.
  27. Nagasaka Y, Takahashi M, Ueshima H, Tohda Y, Nakajima S. Bronchoalveolar lavage with trypsin in pulmonary alveolar proteinosis. *Thorax* 1996;51:769-70.
  28. Chesnutt MS, Nuckton TJ, Golden J, Folkesson HG, Matthey MA. Rapid alveolar epithelial fluid clearance following lung lavage in pulmonary alveolar proteinosis. *Chest* 2001;120:271-4.
  29. Rogers RM, Szidon JP, Shelburne J, Neigh JL, Shuman JF, Tantom KR. Hemodynamic response of the pulmonary circulation to bronchopulmonary lavage in man. *N Engl J Med* 1972;286:1230-3.
  30. Aguinaga MA, Santos P, Renes E, Alvaro PF, Lorente JA, Maudes A, et al. Hemodynamic changes during whole bronchoalveolar lavage in two cases of pulmonary alveolar proteinosis. *Intensive Care Med* 1991;17:421-3.