

Pulmonary Artery Sarcoma Masquerading as Chronic Pulmonary Thromboembolism

Ugur Coskun, MD
Umit Yasar Sinan, MD
Ilknur Calpar, MD
Bedrettin Yildizeli, MD
Mehmet Yanartas, MD
Deniz Filinte, MD
Mehmet Serdar
Kucukoglu, MD

Drs. Coskun and Sinan contributed equally to this article.

Key words: Diagnosis, differential; endarterectomy; fluorodeoxyglucose F18/ diagnostic use; hemangiosarcoma/diagnosis/surgery; positron emission tomography; pulmonary artery/pathology/surgery; pulmonary embolism; sarcoma/diagnosis/surgery; tomography, X-ray computed; tunica intima; vascular neoplasms/diagnosis/surgery

From: Department of Cardiology (Drs. Calpar, Coskun, Kucukoglu, and Sinan), Istanbul University Institute of Cardiology, 34096 Istanbul; Departments of Thoracic Surgery (Dr. Yildizeli) and Pathology (Dr. Filinte), Marmara University School of Medicine, 34722 Istanbul; and Department of Cardiovascular Surgery (Dr. Yanartas), Kartal Kosuyolu Training and Research Hospital, 34846 Istanbul; Turkey

Address for reprints: Umit Yasar Sinan, MD, Cardiology Department, Viransehir State Hospital, 63700 Sanliurfa, Turkey

E-mail: drumityasar@hotmail.com

© 2014 by the Texas Heart[®] Institute, Houston

We describe the case of a 60-year-old woman who presented with pulmonary artery sarcoma, a very rare tumor of the cardiovascular system. Her tumor was initially misdiagnosed as chronic pulmonary thromboembolism, and she underwent pulmonary endarterectomy.

Early diagnosis of primary pulmonary artery sarcoma is crucial. That alternative should always be considered before settling on a diagnosis of pulmonary embolism. Suspicion should be aroused by the failure of anticoagulant treatment to alleviate pulmonary perfusion abnormalities and systemic symptoms. Surgical resection of the tumor—preferably by pulmonary endarterectomy, followed by reconstruction as needed—is currently the most promising treatment for pulmonary artery sarcoma. (*Tex Heart Inst J* 2014;41(5):518-22)

Pulmonary artery (PA) sarcoma, a very rare tumor of the cardiovascular system, is often misdiagnosed as acute or chronic pulmonary thromboembolism because its clinical presentation and radiologic findings resemble those of thromboembolism.^{1,2} The prognosis is usually poor: the tumor is invasive and often involves vital structures such as the heart, which makes radical resection challenging.³ We describe the case of a 60-year-old woman with PA sarcoma that was initially misdiagnosed.

Case Report

In February 2013, a 60-year-old woman presented at our emergency department with progressive dyspnea and palpitation. The dyspnea had started after a long bus ride. Her New York Heart Association (NYHA) functional class was II/III. On physical examination, she was positive for jugular venous distention. Auscultation revealed a grade 3/6 systolic ejection murmur in the left parasternal and 2nd intercostal areas. Her hemodynamic state was stable. Her electrocardiogram showed sinus rhythm and a pattern of right ventricular (RV) strain. The patient's cardiothoracic ratio was greater than 50%, and her natriuretic pro-brain peptide level was high. Transthoracic echocardiography (TTE) and computed tomography (CT) of the chest showed RV dilation with impaired function and a mass (2.7 × 1.3-cm) extending from the pulmonary valve into the right and left PAs and into all sub-branches, which suggested a pulmonary embolus (Figs. 1 and 2). Systolic PA pressure (sPAP) derived by Doppler echocardiography was 122 mmHg. Laboratory investigations for hypercoagulable disorders were within normal limits. Malignancy was ruled out by positron emission tomography-CT (PET-CT). Doppler studies of the lower-extremity veins were normal. A diagnosis of subacute pulmonary thromboembolism was made on the basis of the patient's clinical presentation and imaging results, and we began anticoagulation with heparin. Thrombolytic therapy was not started because of her stable hemodynamic condition.

Subsequently, the patient was placed on warfarin therapy for 3 months and monitored. Her echocardiogram revealed a dilated RV with reduced systolic function and moderate tricuspid regurgitation, no decrease in the size of the mass, and normal left ventricular function. Her sPAP was 122 mmHg. Computed tomograms of her chest showed web-like filling defects in the pulmonary vasculature on the right and left lower lobes, arising from a pulmonary-valve condition that was consistent with

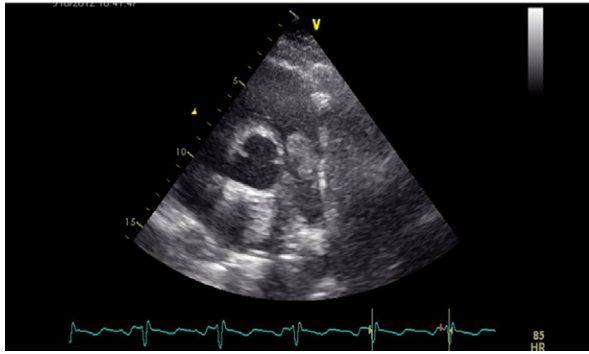


Fig. 1 Transthoracic echocardiogram shows a 2.7 × 1.3-cm mass extending from the pulmonary valve into the pulmonary artery.

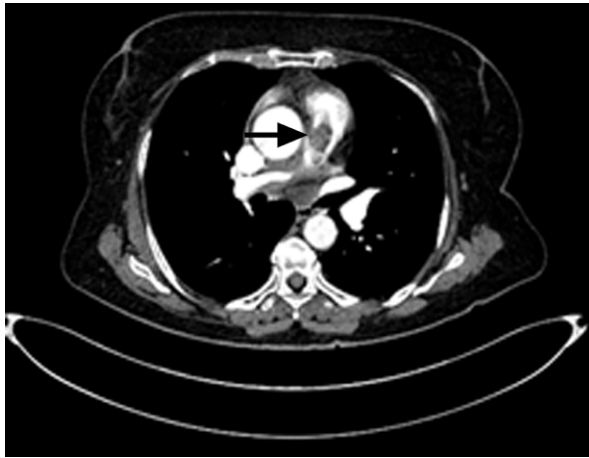


Fig. 2 Thoracic computed tomogram shows right ventricular dilation and a mass suggestive of a pulmonary embolus (arrow) extending from the pulmonary valve into the right and left pulmonary arteries.

chronic thromboembolic disease (Fig. 3). Her 6-minute walk-test distance was 122 m. We decided upon pulmonary endarterectomy, because our patient was in NYHA functional class III, had PA hypertension, had no significant comorbidities, and showed CT angiographic evidence of PA tree obstruction despite 3 months of anticoagulation. Other causes of PA hypertension had been excluded.

With the patient under general anesthesia, we performed surgery through a median sternotomy, using extracorporeal circulation with periods of circulatory arrest under deep hypothermia (18–20 °C), to preserve the right and left PAs. The endarterectomy specimen was circumferentially followed to the segmental and subsegmental branches in each lobe (Fig. 4).

Upon our attempt to wean the patient from cardiopulmonary bypass (CPB), large amounts of dark blood appeared in the endotracheal tube when mechanical ventilation and pulmonary blood flow were established. Because the bleeding was profuse and continuous, we reinstated CPB. When fiberoptic bron-

choscopy was performed, bleeding was noted from the left lower lobe bronchus of the tracheobronchial tree. Ten cm H₂O of positive end-expiratory pressure (PEEP) was applied to both lungs, and the left lower lobe bronchus was occluded with a Fogarty balloon catheter. We made a quick decision not to wean the patient from CPB because of hypoxia and hemodynamic instability; instead, we instituted right femoral venoarterial extracorporeal membrane oxygenation (VA-ECMO), as previously described.⁴

The patient was supported in the intensive care unit for 10 days on VA-ECMO. Although the pulmonary hemorrhage subsided on postoperative day 4, her RV function and PAH did not improve. On day 10, she

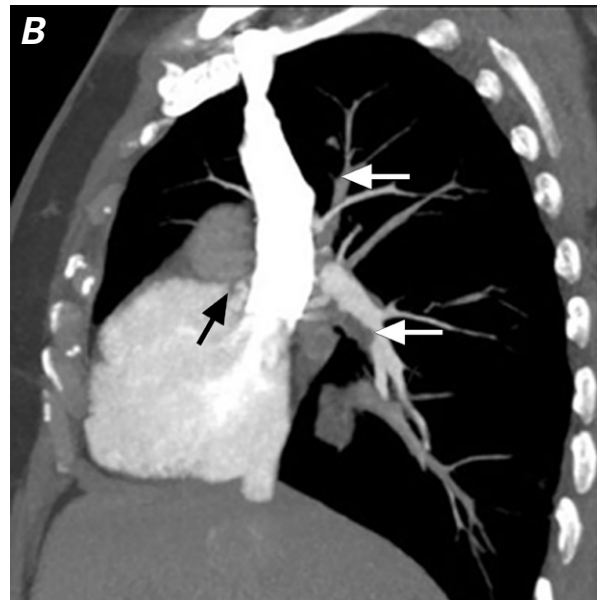
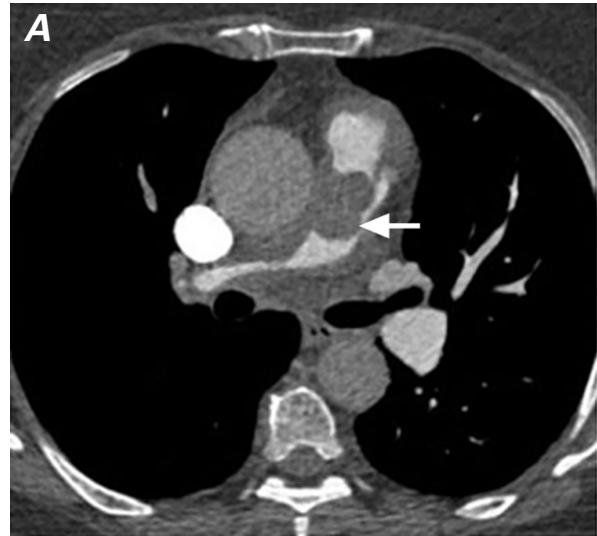


Fig. 3 Computed tomograms appear to show **A**) a pulmonary embolism (arrow) and **B**) endoluminal thromboemboli extending from the pulmonary valve (black arrow) into the right and left pulmonary arteries (white arrows).

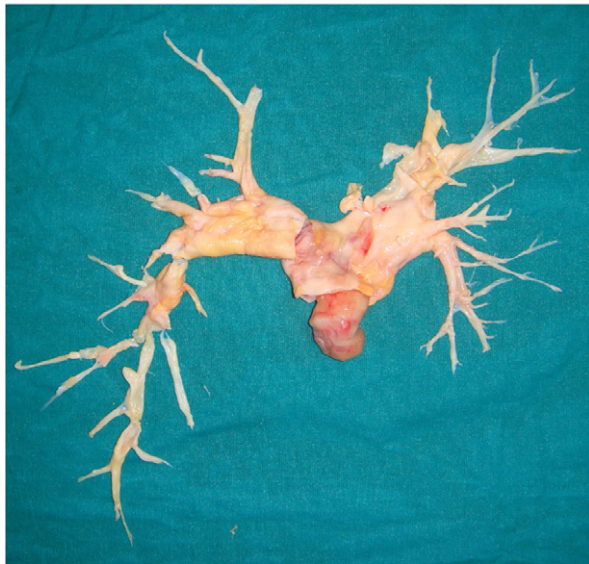


Fig. 4 Photograph shows the specimen from our patient's pulmonary endarterectomy. Note that the endarterectomy extended from the pulmonary valve into the sub-lobar branches of the right and left pulmonary arteries.

died of right-sided heart failure and reperfusion lung injury.

On histologic examination, the tumor contained—in a hypocellular, collagenized stroma—markedly atypical spindle and oval cells, with pleomorphic nuclei. Mitotic activity was high and atypical mitoses were seen frequently. Immunohistochemical studies showed strong positive immunoreactivity for vimentin, smooth-muscle actin, and MyoD1, together with weak positive immunoreactivity for desmin. There was no reactivity for CD31 or CD34. The diagnosis of PA sarcoma was made (Fig. 5).

Discussion

Pulmonary artery sarcoma is a very rare tumor. It was first described in 1923 by Mandelstamm⁵ in a study arising from an autopsy, and, since then, a couple of hundred cases of primary PA sarcoma have been described.⁶ The prognosis is poor, with survival periods ranging from 6 months to 2 years, and the combination

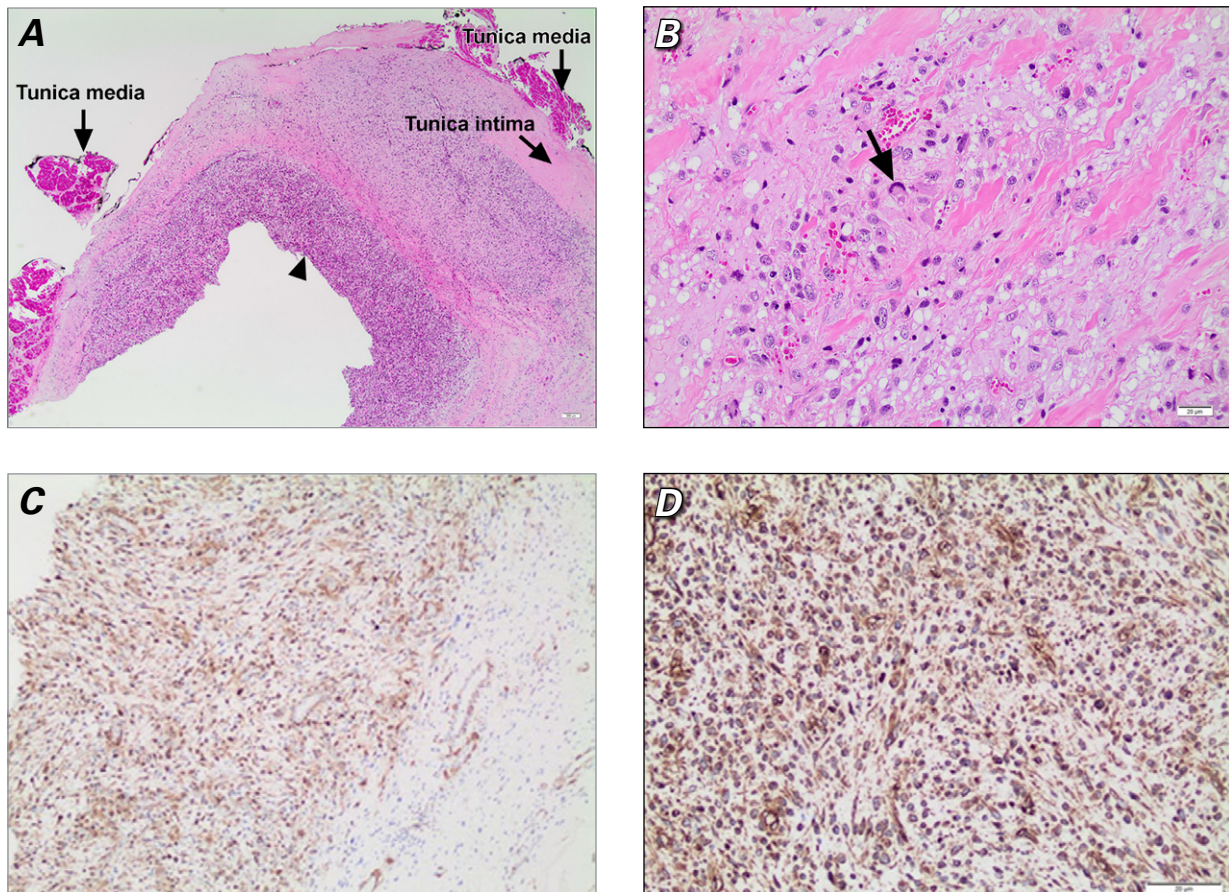


Fig. 5 Photomicrographs show the histologic characteristics of the angiosarcoma. **A**) Arrowhead shows infiltration of malignant cells in the vascular wall (H & E, orig. $\times 20$). **B**) Arrow shows atypical mitotic figure (H & E, orig. $\times 400$). Under immunohistochemical staining, the tumor cells show strong diffuse immunoreactivity for **C**) smooth-muscle actin (orig. $\times 100$) and **D**) vimentin (orig. $\times 200$).

of chemotherapy and radiation therapy is the treatment of choice.³

We present a case, in a 60-year-old woman, of primary sarcoma of the pulmonary trunk that had been misdiagnosed as chronic pulmonary thromboembolism. This extremely rare disease is usually indistinguishable from acute or chronic thromboembolic disease of the PAs, because the clinical and radiologic findings of PA hemangiosarcoma are so similar. Indeed the clinical history of patients with PA sarcoma is so strikingly similar to that of patients with thromboembolic disease that they are rarely diagnosed immediately.⁷ Yet the clinical presentation is variable and metastases are present in 66% to 89% of patients at the time of diagnosis.⁸

Echocardiography is a readily available nondiagnostic tool to detect these tumors, and a screening test in patients with varied presentations can aid in making a proper diagnosis. Meng and colleagues⁹ reported that the sensitivities of TTE and transesophageal echocardiography in detecting these primary masses are 93% and 97%, respectively. Although CT provides more information on the anatomy of the intravascular process, it cannot differentiate between thrombus and tumor. Blackmon and colleagues³ have suggested that, in patients who do not respond to the initial anticoagulation, further investigation with gadolinium-enhanced magnetic resonance imaging should be undertaken. Park and associates¹⁰ reported 2 cases with a mass-like lesion in the PA. The investigators performed endobronchial ultrasound-guided transbronchial needle aspiration (EBUS-TBNA) to differentiate PA sarcoma from thromboembolism. However, Montani and co-authors¹¹ suggested that EBUS-TBNA should not be included in the management of PA sarcoma or thromboembolic disease because proximal obstruction of the PAs by sarcoma or thromboembolic material can cause hypertrophy of systemic bronchial arteries, increasing the risk of hemorrhage from TBNA. They believed that physicians should be aware of the potential sequelae of EBUS-TBNA in patients with PA sarcoma or thromboembolic disease. ¹⁸F-fluorodeoxyglucose PET (¹⁸FDG-PET) plays an important role in the evaluation of pleuropulmonary neoplasm. Because PET evaluates tumor metabolic activity, it has high sensitivity and high negative predictive value for the diagnosis of lung neoplasm. Indeed, ¹⁸F-FDG-PET reveals increased radiotracer uptake in sarcoma lesions, as it does in many types of neoplasms. Dias and colleagues¹² presented 2 case reports to emphasize the importance of ¹⁸F-FDG-PET as a noninvasive method for the diagnostic investigation of patients whose presentation (on CT angiography) of a contrast filling defect in the PA is atypical for thromboembolism. Neoplasms should then be considered upon ¹⁸F-FDG-PET scanning—especially in the event of positive radiotracer uptake in the regions that correspond to the filling defects seen on CT angiography.

Radical surgical resection remains the therapy of choice for PA sarcomas. It has been reported that bilateral pulmonary endarterectomy might yield significant survival rates because it provides completeness of resection without sacrificing the pulmonary vascular bed.⁶ These tumors arise from the intima and rarely extend through the adventitia to invade surrounding structures, so resection might result in complete removal. Because the tumor often involves vital cardiac structures such as the pulmonary valve (30% of cases), radical surgical resection can be challenging. Neoadjuvant chemoradiotherapy might shrink the tumor and thereby enable its resection.⁸ However, in the event of initial misdiagnosis (as in our patient) and severe RV dysfunction requiring immediate surgery, there might not be time for neoadjuvant chemotherapy.

In summary, an alternative diagnosis of primary PA sarcoma should always be considered before settling on a diagnosis of pulmonary embolism. Early diagnosis of PA sarcoma is crucial. Suspicion should be aroused by the failure of anticoagulant treatment to alleviate pulmonary perfusion abnormalities and systemic symptoms. Surgical resection of the tumor—preferably by pulmonary endarterectomy, followed by reconstruction as needed—is currently the most promising treatment for PA sarcoma.

References

1. Kaplinsky EJ, Favaloro RR, Pombo G, Perrone SV, Vigliano CA, Schnidt JL, Boughen RP. Primary pulmonary artery sarcoma resembling chronic thromboembolic pulmonary disease. *Eur Respir J* 2000;16(6):1202-4.
2. Dornas AP, Campos FT, Rezende CJ, Ribeiro CA, Amaral NF, Correa Rde A. Intimal sarcoma of the pulmonary artery: a differential diagnosis of chronic pulmonary thromboembolism. *J Bras Pneumol* 2009;35(8):814-8.
3. Blackmon SH, Rice DC, Correa AM, Mehran R, Putnam JB, Smythe WR, et al. Management of primary pulmonary artery sarcomas. *Ann Thorac Surg* 2009;87(3):977-84.
4. Yildizeli B, Arslan O, Tas S, Eldem B, Aksoy E, Kocak T, Sunar H. Management of massive pulmonary hemorrhage following pulmonary endarterectomy. *Thorac Cardiovasc Surg* 2014;62(1):89-91.
5. Mandelstamm M. Über primäre Neubildungen des herzens. *Virchows Arch Pathol Anat* 1923;245:43-54.
6. Mussot S, Ghigna MR, Mercier O, Fabre D, Fadel E, Le Cesne A, et al. Retrospective institutional study of 31 patients treated for pulmonary artery sarcoma. *Eur J Cardiothorac Surg* 2013; 43(4):787-93.
7. Chaubey S, Benson C, Khan H, Monaghan M, Shah AM, Judson I, Wendler O. Six-year survival of a patient with pulmonary artery angiosarcoma. *Asian Cardiovasc Thorac Ann* 2012;20(6):728-30.
8. Kim CH, Dancer JY, Coffey D, Zhai QJ, Reardon M, Ayala AG, Ro JY. Clinicopathologic study of 24 patients with primary cardiac sarcomas: a 10-year single institution experience. *Hum Pathol* 2008;39(6):933-8.
9. Meng Q, Lai H, Lima J, Tong W, Qian Y, Lai S. Echocardiographic and pathologic characteristics of primary cardiac tumors: a study of 149 cases. *Int J Cardiol* 2002;84(1):69-75.

10. Park JS, Chung JH, Jheon S, Choi DJ, Yoon HI, Lee JH, et al. EBUS-TBNA in the differential diagnosis of pulmonary artery sarcoma and thromboembolism. *Eur Respir J* 2011;38(6):1480-2.
11. Montani D, Jais X, Sitbon O, Darteville P, Simonneau G, Humbert M. EBUS-TBNA in the differential diagnosis of pulmonary artery sarcoma and thromboembolism. *Eur Respir J* 2012;39(6):1549-50.
12. Dias OM, Lombardi EM, Canzian M, Soares Junior J, Vieira Lde O, Terra Filho M. 18F-fluorodeoxyglucose positron emission tomography as a noninvasive method for the diagnosis of primary pulmonary artery sarcoma. *J Bras Pneumol* 2011;37(6):817-22.