



Aplastic Anemia Associated with Oral Terbinafine: A Case Report and Review of the Literature

Oral Terbinafin İlişkili Aplastik Anemi: Bir Olgu Sunumu ve Literatür Derlemesi

Bülent Kantarcıoğlu¹, Hüseyin Kemal Türköz², Güven Yılmaz³, Funda Pepedil Tanrıku³,
Işık Kaygusuz Atagündüz³, Cafer Adıgüzel³, Tülin Fıratlı Tuğlular³

¹Okmeydanı Training and Research Hospital, Clinic of Hematology, İstanbul, Turkey

²Marmara University Faculty of Medicine, Department of Pathology, İstanbul, Turkey

³Marmara University Faculty of Medicine, Department of Hematology, İstanbul, Turkey

Abstract:

Onychomycosis (OM) is a common fungal infection of the toenails and/or fingernails that is highly prevalent in the general population and also responsible for significant morbidity. OM is caused by dermatophytes, nondermatophytic molds, or yeast. Today systemic antifungal agents are considered as the gold standard for all types of OM. Here we report a case of aplastic anemia associated with oral terbinafine use and a review of the literature on hematological toxicities associated with terbinafine.

Key Words: Onychomycosis, Terbinafine, Aplastic anemia, Hematological toxicity, Pancytopenia, Adverse events

Özet:

Onikomikoz (OM) el ve ayak tırnaklarının sık görülen fungal enfeksiyonudur. Genel toplumda prevalansı yüksek bir hastalık olması nedeniyle önemli morbiditeye yol açmaktadır. OM dermatofitler, nondermatofitik küf mantarları veya mayalar ile ortaya çıkan hastalıklardır. Günümüzde onikomikozun tedavisinde sistemik antifungal ajanlar tüm OM tiplerinde altın standart tedavi olarak kabul edilmektedir. Biz burada, oral terbinafin kullanımı sırasında gelişen bir aplastik anemi olgumuzu ve literatürde terbinafine ile ilişkilendirilmiş olan hematolojik toksisitelerin derlemesini sunuyoruz.

Anahtar Sözcükler: Onikomikoz, Aplastik anemi, Terbinafin, Hematolojik toksisite, Pansitopeni, Yan etkiler

Introduction

Onychomycosis is a very frequent fungal nail infection. The prevalence can be as high as 28%-40%, especially in elderly populations. Terbinafine is an antifungal agent with both fungicidal and fungistatic properties, which is highly effective and is the most frequently used agent in onychomycosis. Oral terbinafine is generally well tolerated with minimal reports of serious drug reactions. These rare

adverse events are mostly reported as case presentations, and it is important to be familiar with them in order to be able to evaluate the risk and inform patients accordingly [1,2,3]. Here we report a case of aplastic anemia (AA) associated with oral terbinafine use and a review of the literature on hematological toxicities associated with terbinafine. Written informed consent was obtained from the patient and her husband for publication of this manuscript and accompanying images.

Address for Correspondence: Bülent KANTARCIOĞLU, M.D.,
Okmeydanı Training and Research Hospital, Clinic of Hematology, İstanbul, Turkey
Phone: +90 532 547 62 08 E-mail: bulentkantarcioğlu@gmail.com

Received/Geliş tarihi : April 7, 2013

Accepted/Kabul tarihi : May 14, 2013

Case Presentation

A 41-year-old female presented with malaise, severe fatigue, nausea, and vaginal bleeding in April 2011. In her past history she was healthy, except that she reported taking terbinafine pills for 8 weeks for the treatment of longstanding recurrent toenail onychomycosis. She did not report any immune reactions or allergies to any drugs or substances. Her previous gynecological examination was normal, with a normal β -human chorionic gonadotropin level. Her complete blood count (CBC) revealed pancytopenia with white blood cell count of $3.2 \times 10^9/L$, absolute neutrophil count of $0.8 \times 10^9/L$, hemoglobin of 7.4 g/dL, and platelet count of $34 \times 10^9/L$. Her physical examination was unremarkable with no evidence of lymphadenopathy or organomegaly, except for a few petechiae and ecchymoses on bilateral legs. Peripheral blood smear was consistent with pancytopenia. Reticulocyte count was 0.7. Liver enzymes were elevated [AST: 61 U/L (N: 10-37 U/L), ALT: 117 U/L (N: 10-40 U/L), ALP: 434 U/L (N: 0-270 U/L), GGT: 471 U/L (N: 7-49 U/L)]. Renal function tests and lactate dehydrogenase were normal. Bone marrow aspiration and biopsy revealed severe reduction of all cell lineages without evidence of neoplastic infiltration, dysplasia, or fibrosis. The counted cellularity was 5% in bone marrow. Bone marrow karyotype analysis was normal. A gastroenterology consultation performed for the liver enzyme abnormalities did not provide an etiologic factor, pointing toward drug-induced hepatitis. Further work-ups, including levels of vitamin B12 and folate; neck, chest, and abdominopelvic computerized tomography; serology and polymerase chain reaction (PCR) tests for viral hepatitis, human immunodeficiency, Epstein-Barr virus, parvovirus B19, and cytomegalovirus; FLAER test for paroxysmal nocturnal hemoglobinuria; antinuclear antibody test; HLA-DRB1*15; and quantiferon test for tuberculosis, were all negative. The patient was diagnosed with AA, which was not severe at that time. Terbinafine treatment was stopped. Due to the use of a drug with probable hematologic toxicity, follow-up with supportive care was planned for the patient. During 3-4 weeks of follow-up time, blood values worsened with the need for erythrocyte and thrombocyte transfusions, in accordance with very severe AA (SAA). She did not have a matched related donor for transplantation. After confirming the diagnosis with a second bone marrow biopsy, she received rabbit antithymocyte globulin (ATG) plus cyclosporine-A (CYC). The clinical outcome after ATG + CYC was poor due to transient worsening of hematopoiesis and infectious complications. She spent 3 months in the hospital with perianal abscess, invasive aspergillosis, zoster virus reactivation, and several catheter infections. She required physical and psychological rehabilitation. Fortunately, the blood values began to recover at the end of the fourth month and full hematologic recovery was achieved at the end of the

sixth month. The patient is still in complete remission after 18 months of ATG + CYC treatment (Figures 1 and 2).

Discussion and Review of the Literature

Onychomycosis refers to all fungal infections of the nails. It is difficult to cure, has high recurrence rates, and can significantly affect a patient's quality of life. Topical therapies are generally ineffective, and today treatment with systemic antifungal agents is accepted as the gold standard method for onychomycosis. In clinical trials, continuous terbinafine has repeatedly demonstrated higher efficacy when compared to other antifungal treatments. The recommended dosage for the treatment of onychomycosis is 250 mg/day orally for 12 weeks for toenails and 6 weeks for fingernails [1,2,3].

Oral terbinafine is generally well tolerated with minimal reports of serious drug reactions. Two large-scale postmarketing surveillance studies showed that the incidence of serious

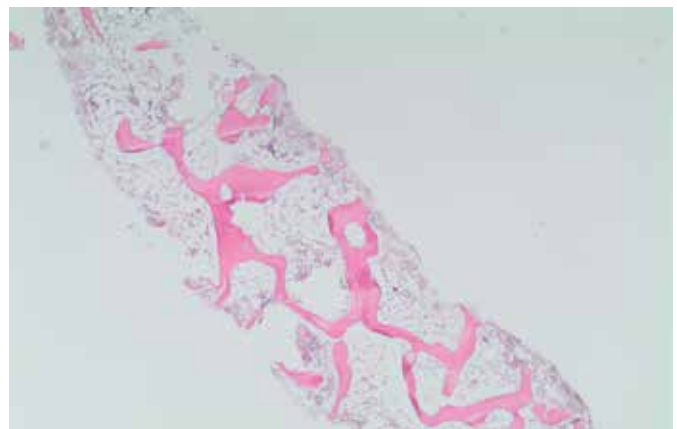


Figure 1. Bone marrow trephine biopsy: low cellularity in the bone marrow consistent with aplastic anemia (H&E, 20x).

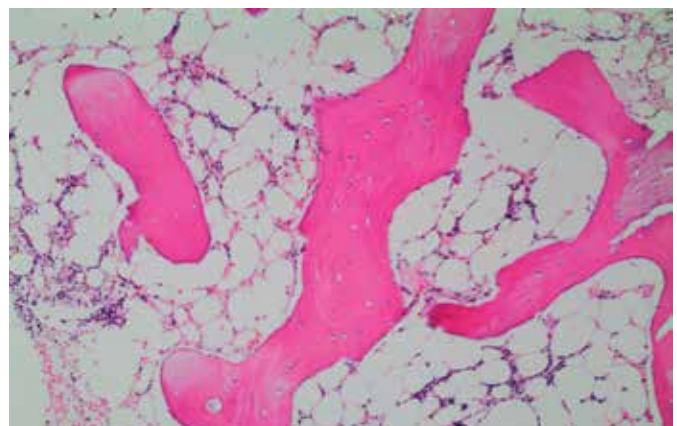


Figure 2. Bone marrow trephine biopsy: a few hematopoietic cells intermixed with lymphocytes and plasmacytes in interstitial areas (H&E, 100x).

Table 1. Reported cases of terbinafine-associated hematological toxicity in the literature.

Reference Number	Age (years)/ Sex	Duration of Terbinafine Treatment	Nadir of Cytopenia	Reported Symptoms	Terbinafine Dose	Management	Reported Outcome
9	60/F	32 days	WBC 1.2 Neu 0.00	Mouth/tongue ulceration, fever, myalgia, malaise	250 mg/day	Hospitalized, i.v. anti-biotics, G-CSF	Recovered
9	35/not reported	34 days	WBC 2.9 Neu 0.3	Mouth ulcers, cellulitis	250 mg/day	Cephalexin	Recovered
9	78/M	27 days	WBC 2.4 Neu 0.9	Flu-like illness	250 mg/day	No treatment reported	Recovered
9	69/F	31 days	WBC 2.18 Neu 0.3	Mouth/tongue ulceration, anorexia	250 mg/day	No treatment reported	Recovered
9	44/F	35 days	Neu 0.03	Mouth ulceration, fever, chills, headache	250 mg/day	Hospitalized, i.v. antibiotics	Recovered
9	74/F	32 days	WBC 1.5 Neu 0.5	None reported	250 mg/day	Hospitalized, i.v. antibiotics, G-CSF	Recovered
9	79/F	Not reported	Not given; agranulocytosis reported	Septic shock	250 mg/day	Hospitalized, i.v. antibiotics	Died
9	68/F	39 days	WBC 1.9 Neu 0.04	None reported	250 mg/day	No treatment reported	Recovered
9	63/F	46 days	Neu 0.14	None reported	250 mg/day	G-CSF, one dose	Recovered
9	61/F	27 days	WBC 3.8 Neu 0.9	Mouth ulceration	250 mg/day	No treatment reported	Not yet recovered
9	66/F	67 days	WBC 2.2 Neu 0.04	Mouth ulceration, ageusia	250 mg/day	None reported	Recovered
9	73/F	46 days	Neu 0.00	Mouth and tongue ulceration, fever, anorexia, candidiasis	250 mg/day	Hospitalized, i.v. antibiotics, amphotericin, nystatin	Not yet recovered

Table 1. Reported cases of terbinafine-associated hematological toxicity in the literature.

10	60/M	6 weeks	WBC 1.6 Neu 0.11	Mouth ulceration, fever, cellulitis, sepsis syndrome	Not reported	Hospitalized, i.v antibiotics, G-CSF	Recovered
11	55/F	4 weeks	WBC 1.6 Neu 0.00	Fever, dehydration, sepsis syndrome	250 mg/day	Hospitalized, i.v antibiotics, G-CSF	Recovered
12	42/M	30 days	WBC 3.5 Neu 0.34	Fever, tongue ulceration,	250 mg/day	Hospitalized, i.v antibiotics, G-CSF	Recovered
13	63/M	4 weeks	WBC 1400 Neu not reported Hct 24.6 Plt 68,000	Fever, gum bleeding	Not reported	Hospitalized, i.v antibiotics, G-CSF	Recovered
14	15/M	4 weeks	WBC 2900 Neu 0.00	Fever, sore throat	250 mg/day	Oral penicillin, observation	Recovered
15	53/F	Not reported	WBC 1.9 Neu 0.01	Fatigue	250 mg/day	G-CSF	Recovered
15	75/M	63 days	WBC 500 Hb 13.5 Plt 99,000	Nausea, vomiting, diarrhea, fever, abdominal pain	250 mg/day	Hospitalized, i.v antibiotics	Recovered
16	53/F	Not reported	Plt 8000	Ecchymosis, buccal hematoma	250 mg/day	Hospitalized, prednisolone 1.5 mg/kg/day	Recovered
17	53/F	Not reported	Plt 63,000	Epistaxis	250 mg/day	Observation	Recovered
Presented case	41/F	8 weeks	WBC 1.5 Neu 0.2 Hb 6.5 Plt 12,000 Rtc 0.1%	Malaise, fatigue, nausea, vaginal bleeding	250 mg/day	Supportive care initially	Not recovered spontaneously, recovery obtained with ATG + CYC

M: male, F: female, WBC: white blood cell, Neu: neutrophil, Hb: hemoglobin, Hct: hematocrit, Plt: platelet, Rtc: reticulocyte count.

side effects was <1% [4,5]. In contrast, 2 studies of registry data from Austria and Denmark drew attention to blood dyscrasias associated with terbinafine [6,7]. Notable adverse events have been reported, including hepatitis requiring liver transplantation [8], drug-induced lupus reactions, severe skin reactions such as Stevens-Johnson syndrome, and, much less often, neutropenia/agranulocytosis and thrombocytopenia [9,10,11,12,13,14,15,16,17]. To our knowledge, ours is the first reported case of AA associated with terbinafine use.

AA is usually diagnosed within the setting of pancytopenia and hypocellular bone marrow when other diseases are excluded. SAA is almost always fatal if untreated. Once SAA is established, therapy should not be delayed in the hope of spontaneous recovery [18,19].

Many drugs have been associated with AA. The vast majority of patients exposed to these drugs do not develop AA and the reason for idiosyncratic reactions is unknown. AA can develop as a direct response to exposure, but it can also develop indirectly through immune-mediated mechanisms. P-glycoprotein (P-gp), the MDR-1 gene product, and the multidrug resistance-associated protein are energy-dependent transmembrane efflux pumps for a variety of lipophilic drugs. Underexpression of P-gp in normal cells might allow cytoplasmic accumulation of drugs and enhance their toxic effects. Two studies found that P-gp activity was decreased in patients with AA; levels were lowest in a subgroup with drug-induced AA [20,21]. In our case, the prolonged use of the highly lipophilic agent terbinafine might have caused direct toxicity, leading to AA.

Additionally, in a recently published study, the release of IL-8 and TNF α was significantly increased by treatment with terbinafine, which can explain how terbinafine may also cause immune-mediated injury [22]. Lupus-like reactions reported with terbinafine use may be an additional evidence of immune-mediated injury as an underlying mechanism. However, in most cases, the trigger of the mechanism of AA remains unclear. Historically, drug-induced AA has not been easily distinguished from idiopathic forms of the disease since causality is difficult to establish [23].

A review of hematologic toxicities associated with the use of terbinafine showed that the duration of terbinafine exposure leading to hematological toxicity is almost 1 month; the degree of cytopenia can be severe and patients mostly presented with infectious complications requiring hospitalization. While the clinical outcome was reversible in most cases, our patient required additional treatment with a high burden of risk and complications (Table 1).

In conclusion, keeping in mind the slow and persistent course of onychomycosis requiring long-term treatment, the high rate of success achieved with terbinafine, and the

wide range of the population receiving terbinafine treatment, we advise detailed information of patients in regard to adverse events and we recommend monitorization of CBC at baseline and every month during terbinafine treatment. To our knowledge, this is the first case report of irreversible SAA following treatment with terbinafine that required immunosuppressive treatment with ATG + CYC. This case highlights the need for routine blood count monitoring during treatment with terbinafine. In these patients, clinicians should consider the rare incidence of SAA when there is agranulocytosis or pancytopenia.

Conflict of Interest Statement

The authors of this paper have no conflicts of interest, including specific financial interests, relationships, and/or affiliations relevant to the subject matter or materials included.

References

1. Shemer A. Update: medical treatment of onychomycosis. *Dermatol Ther* 2012;25:582-593.
2. Grover C, Khurana A. An update on treatment of onychomycosis. *Mycoses* 2012;55:541-551.
3. Van Duyn GL, Elewski BE. Recent updates in oral terbinafine: its use in onychomycosis and tinea capitis in the US. *Mycoses* 2011;54:679-685.
4. Hall M, Monka C, Krupp P, O'Sullivan D. Safety of oral terbinafine: results of a postmarketing surveillance study in 25,884 patients. *Arch Dermatol* 1997;133:1213-1219.
5. O'Sullivan DP, Needham CA, Bangs A, Atkin K, Kendall FD. Postmarketing surveillance of oral terbinafine in the UK: report of a large cohort study. *Br J Clin Pharmacol* 1996;42:559-565.
6. ADRAC. Terbinafine and blood dyscrasias. *Aust Adverse Drug React Bull* 2004;23:19.
7. Bangsgaard N, Saunte DM, Folkenberg M, Zachariae C. Serious adverse events reporting on systemic terbinafine: a Danish register-based study. *Acta Derm Venereol* 2011;91:358-359.
8. Pervez Z, Johnson MW, Rubin RA, Sellers M, Zayas C, Jones JL, Cross R, Thomas K, Butler B, Shrestha R. Terbinafine-induced hepatic failure requiring liver transplantation. *Liver Transpl* 2007;13:162-164.
9. Pillans PI, Boyd IW. Toenails and agranulocytosis. *Intern Med J* 2007;37:572-575.
10. Gupta AK, Soori GS, Del Rosso JQ, Bartos PB, Shear NH. Severe neutropenia associated with oral terbinafine therapy. *J Am Acad Dermatol* 1998;38:765-767.
11. Ornstein DL, Ely P. Reversible agranulocytosis associated with oral terbinafine for onychomycosis. *J Am Acad Dermatol* 1998;39:1023-1024.
12. Shapiro M, Li LJ, Miller J. Terbinafine-induced neutropenia. *Br J Dermatol* 1999;140:1196-1197.

13. Conjeevaram G, Vongthavaravat V, Sumner R, Koff RS. Terbinafine-induced hepatitis and pancytopenia. *Dig Dis Sci* 2001;46:1714-1716.
14. Aguilar C, Mueller KK. Reversible agranulocytosis associated with oral terbinafine in a pediatric patient. *J Am Acad Dermatol* 2001;45:632-634.
15. Kovacs MJ, Alshammari S, Guenther L, Bourcier M. Neutropenia and pancytopenia associated with oral terbinafine. *J Am Acad Dermatol* 1994;31:806.
16. Tsai HH, Lee WR, Hu CH. Isolated thrombocytopenia associated with oral terbinafine. *Br J Dermatol* 2002;147:627-628.
17. Grunwald MH. Thrombocytopenia associated with oral terbinafine. *Int J Dermatol* 1998;37:634.
18. Scheinberg P. Aplastic anemia: therapeutic updates in immunosuppression and transplantation. *Hematology* 2012;2012:292-300.
19. Guinan EC. Diagnosis and management of aplastic anemia. *Hematology* 2011;2011:76-81.
20. Calado RT, Garcia AB, Falcão RP. Decreased activity of the multidrug resistance P-glycoprotein in acquired aplastic anaemia: possible pathophysiologic implications. *Br J Haematol* 1998;102:1157-1161.
21. Calado RT, Garcia AB, Gallo DA, Falcão RP. Reduced function of the multidrug resistance P-glycoprotein in CD34+ cells of patients with aplastic anaemia. *Br J Haematol* 2002;118:320-326.
22. Mizuno K, Fukami T, Toyoda Y, Nakajima M, Yokoi T. Terbinafine stimulates the pro-inflammatory responses in human monocytic THP-1 cells through an ERK signaling pathway. *Life Sci* 2010;87:537-544.
23. Mintzer DM, Billet SN, Chmielewski L. Drug-induced hematologic syndromes. *Adv Hematol* 2009;2009:495863.