



CASE REPORT / OLGU SUNUMU

High glucose concentration in pericardial fluid: An indication for iatrogenic cardiac tamponade in a neonate

Perikard sıvısında yüksek glukoz konsantrasyonu: Yenidoğanda iyatrojenik perikardiyal tamponadın bir belirteci

Elif EROLU GUNAY, Aslı MEMISOGLU, Sinem ALTINYUVA USTA, Oyku TOSUN, Koray AK, Figen AKALIN

ABSTRACT

We present a case of neonatal pericardial tamponade due to umbilical venous catheterization, a rare, but life threatening complication. A newborn who developed sudden clinical deterioration at 44th hour following umbilical venous catheterization, is reported. Echocardiography showed marked pericardial effusion. Urgent pericardiocentesis was performed. Analysis of pericardial fluid revealed high glucose level consistent with the composition of total parenteral nutrition fluid being infused through the catheter. Pericardial tamponade should be considered in any infant with a central venous catheter who suddenly deteriorates and urgent pericardiocentesis should be attempted.

Keywords: Umbilical venous catheterization, Complication, Cardiac tamponade, Pericardial effusion

ÖZ

Umbilikal venöz kateterizasyon işlemi sonrasında gelişen nadir fakat yaşamı tehdit edici komplikasyonlardan biri perikardiyal tamponadır. Yenidoğan bir bebekte umbilikal venöz kateterizasyon işlemi sonrasında ani klinik kötüleşme ile prezente olan perikardiyal tamponad olgusunu sunuyoruz. Ekokardiyografide geniş perikardiyal effüzyon görülmüş ve acil perikardiyosentez yapılmıştır. Perikardiyal sıvı analizinde umbilikal kateterden gitmekte olan sıvı içeriğinin konsantrasyonunda glukoz seviyesi bildirilmiştir. Perikardiyal tamponad, umbilikal venöz kateterizasyon sonrasında ani klinik kötüleşme gösteren her hastada akla gelmelidir ve acil perikardiyosentez uygulanmalıdır.

Anahtar kelimeler: Umbilikal venöz kateterizasyon, Komplikasyon, Kardiyak tamponad, Yüksek glukoz konsantrasyonu, Perikardiyal effüzyon

Introduction

Umbilical venous catheterization (UVC) is frequently used in neonatal intensive care units. Several complications may occur due to an umbilical catheter placement. Pericardial effusion and cardiac tamponade are the most fatal ones. We herein, present a newborn who developed pericardial tamponade following UVC insertion.

Case Report

A 3600 g male infant was consulted to pediatric cardiology at 44th hour after birth due to sudden deterioration, cyanosis, tachypnea and tachycardia. He was born at 36th week of gestation, to a 34-year-old mother with gestational diabetes. At 8th hour of age, the infant became plethoric and tachypneic, blood samples showed polycythemia and low glucose levels. He was admitted to the neonatal intensive care unit and an UVC, (5 Fr gauge-polyvinyl chloride catheter)

Elif Erolu Gunay (✉), Aslı Memisoglu, Sinem Altunyuva Usta, Öykü Tosun, Figen Akalin
Sub-department of Pediatric Cardiology, Department of Child Health and Pediatrics, School of Medicine, Marmara University Hospital, Pendik, Istanbul, Turkey
e-mail: eliferolu@yahoo.com

Koray Ak
Department of Cardiovascular Surgery, School of Medicine, Marmara University Hospital, Pendik, Istanbul, Turkey

Submitted/Gönderme: 18.07.2016 Accepted/Kabul: 27.09.2016

was placed in order to perform partial exchange transfusion and high dextrose infusion. The position of the catheter was checked by X-ray and the catheter tip was seen at the right atrium in the first check and then repositioned (Figure 1). At 44th hour after birth, the infant became more tachypneic and cyanosed. Heart rate was 190 bpm, blood pressure was 54/28 mmHg. Chest X-ray showed cardiomegaly. Echocardiography revealed presence of pericardial effusion surrounding all cardiac chambers and measured 1.5cm wide behind the left ventricle, right and left atria were compressed during filling suggesting cardiac tamponade, the catheter tip was observed at the junction of inferior vena cava and right atrium (Figure 2). Contrast study with agitated saline was performed through UVC, echo-contrast filled the right heart chambers, however no extravasation of contrast material into the pericardial cavity was observed (Figure 3). Urgent pericardiocentesis was performed, 40 ml of straw-coloured serous fluid was drained. After the drainage of the pericardial fluid, his vital signs were within the normal range and oxygen requirement decreased within a few minutes. Analysis of the pericardial fluid revealed high glucose level of 1363 mg/dl (LDH 49 U/l, total protein 0.2 gr/dl). Examination of pericardial fluid revealed no cellular infiltration and culture of pericardial fluid was sterile. Infusion through the UVC was stopped and the catheter was removed immediately after initial pericardial fluid laboratory results were obtained. There was no subsequent reaccumulation of the pericardial effusion. The infant was discharged on the 7th day of life and subsequent follow-up has shown him to be healthy.

Discussion

Umbilical venous catheterization is frequently used in neonatal intensive care units. There are several complications due to UVC placement like arrhythmia, intracardiac thrombosis, systemic and pulmonary embolization, endocarditis, myocardial perforation, pleural effusion, pericardial effusion and cardiac tamponade [1]. Pericardial effusion and cardiac tamponade is one of the most life threatening complication due to UVC placement in neonates.

Pericardial effusion due to UVC placement may occur from a direct lesion or endothelial damage because of the small repeating movements of the tip of the catheter, upper extremity position or abdominal girth variations [2-4]. Incorrect position of UVCs or central venous catheter (CVCs) is not a rare reason for pericardial tamponade with cardiorespiratory instability and sudden cardiac collapse [5, 6].

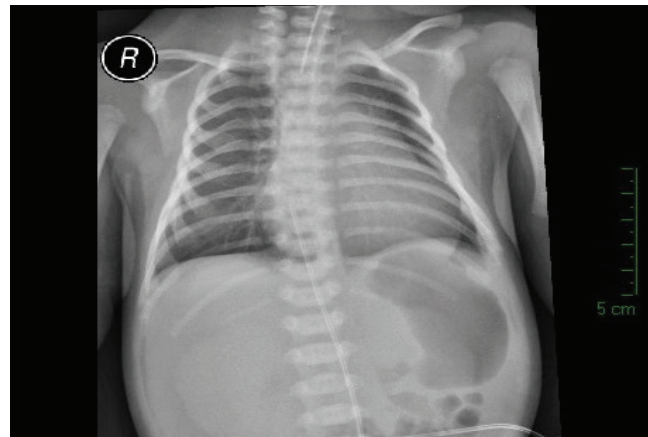


Figure 1: Direct roentgenogram showing the tip of the umbilical venous catheter (UVC) located in the right atrium

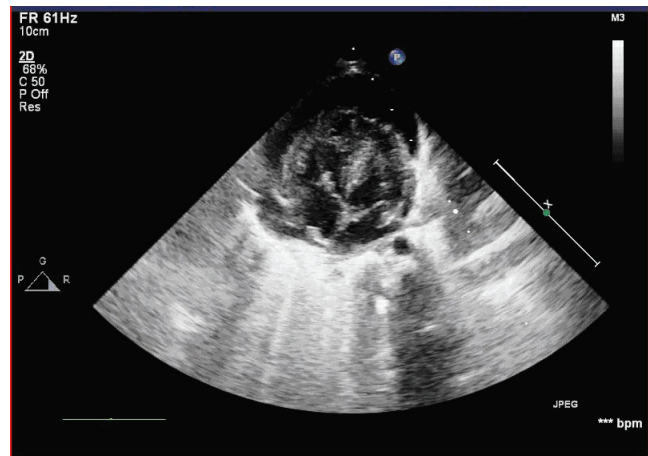


Figure 2: Echocardiogram showing a large pericardial effusion

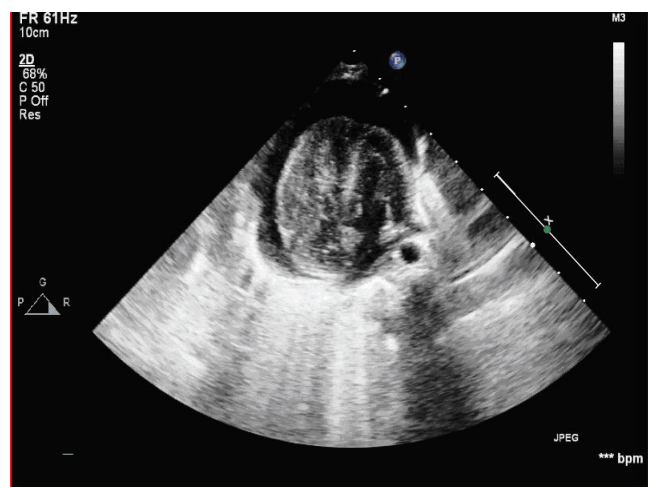


Figure 3: Echocardiogram showing contrast filling the right heart chambers and no agitated saline leakage into the pericardial cavity

Anteroposterior chest radiography is the most used method for confirming appropriate UVC position. But it may not be a proper method for confirmation of placement of catheters. In the study of Ades et al., the sensitivity and specificity of anteroposterior chest roentgenogram in evaluating inappropriate UVC position were 32% and 89% respectively. In that study echocardiography with saline contrast injection was performed within 24 hours of catheter placement. It was revealed that UVCs were located ideally at the right atrial / inferior vena cava junction in only 23% of the patients [7]. Furthermore, cardiac tamponade may occur despite normal catheter position [8]. In our patient echocardiography showed catheter tip at the junction of inferior vena cava and right atrium. However, attempts of catheter placement was done before the achievement of correct position. In contrast echocardiography there was no contrast material transition into the pericardial cavity. This may be due to microtraumatic lacerations which were smaller than the bubbles of agitated saline and let the leak of fluid but capture the contrast. There were no other risk factors in our patient to cause large pericardial effusion such as septicemia or cardiovascular anomaly, only maternal diabetes mellitus. Analysis of high glucose level in pericardial fluid which was consistent with the composition of the fluid being infused through the catheter proved that UVC was the cause of the pericardial effusion and tamponade via extravasation. In the literature, in some cases, complications due to pericardial effusion are seen within 3 to 5 days after CVC placement [8,9]. Symptoms occurred a little earlier in our patient.

Conclusion

Clinical sudden deterioration following UVC placement should alert the clinicians about pericardial tamponade in

neonates. High glucose content of the pericardial fluid suggests leakage of parenteral nutrition fluid into the pericardial space.

References

1. Green C, Yohannan MD. Umbilical arterial and venous catheters: placement, use, and complications. *Neonatal Netw* 1998; 17:23-8.
2. Nadroo AM, Glass RB, Lin J, Green RS, Holzman IR. Changes in upper extremity position cause migration of peripherally inserted central catheters in neonates. *Pediatrics* 2002; 110:131-6.
3. Salvadori S, Piva D, Filippone M. Umbilical venous line displacement as a consequence abdominal girth variation. *J Pediatr* 2002; 141: 737. doi: 10.1067/mpd.2002.128111
4. Keeney SE, Richardson CJ. Extravascular extravasation of fluid as a complication of central venous lines in the neonate. *J Perinatol* 1995;15:284-8.
5. Gálvez-Cancino F, de la Luz Sánchez-Tirado M. Cardiac tamponade associated with umbilical venous catheter (UVC) placed in inappropriate position. *Med Mex* 2015;151:396-8.
6. Abiramalatha T, Kumar M, Shabeer MP. Pleural effusion caused by a malpositioned umbilical venous catheter in a neonate. *BMJ Case Rep* 2015;30;2015. doi: 10.1136/bcr-2015-212705.
7. Ades A, Sable C, Cummings S, Cross R, Markle B, Martin G. Echocardiographic evaluation of umbilical venous catheter placement. *J Perinatol* 2003; 23:24-8. doi: 10.1038/sj.jp.7210851
8. Onal EE, Saygılı A, Koc E, Türkyılmaz C, Okumus N, Atalay Y. Cardiac tamponade in a newborn because of umbilical venous catheterization: is correct position safe? *Pediatric Anesthesia* 2004; 14: 953-6. doi: 10.1111/j.1460-9592.2004.01385.x
9. Abiramalatha T, Kumar M, Shabeer MP, Thomas N. Advantages of being diligent: lessons learnt from umbilical venous catheterisation in neonates. *BMJ Case Rep* 2016. doi: 10.1136/bcr-2015-214073.