



Gastrointestinal sarcoidosis presenting with malabsorption at an early age

Erken yaşta malabsorbsiyon ile ortaya çıkan gastrointestinal sarkoidoz olgusu

Özlem Kalaycık Şengül, Bilge Şahin Akkelle, Burcu Volkan, Engin Tutar, Çiğdem A. Çelikel, Deniz Ertem

Department of Pediatric Gastroenterology, Hepatology and Nutrition, Marmara University Faculty of Medicine, İstanbul, Turkey

The known about this topic

Childhood sarcoidosis at very early ages (<5 years) has unique clinical features, characterized by the triad of arthritis, rash and uveitis. In the pediatric age group, prominent gastrointestinal symptoms at initial presentation are extremely rare. The liver is the most common extrapulmonary involvement in sarcoidosis.

Contribution of the study

This patient is the youngest in the literature, he presented with gastrointestinal and hepatic symptoms in the absence of pulmonary involvement at onset. The distinctive feature of this case is the absence of arthritis, rash and uveitis, which are specifically described in early-onset childhood sarcoidosis.

Abstract

Sarcoidosis is a chronic multisystemic granulomatous disease that predominantly involves the thoracic lymph nodes and lungs and primarily occurs in young adults. Isolated extrapulmonary localization is uncommon in adults, and exceptionally rare in the pediatric age group. A 4-year-old male patient with chronic diarrhea and abdominal distention for the last 8 months is presented. Endoscopic biopsies, obtained during gastroscopy and colonoscopy, revealed noncaseating granulomas in all segments of the gastrointestinal tract. A noncaseating granuloma was also demonstrated in the liver biopsy. Granulomatous inflammation of both the gastrointestinal system and liver along with elevated serum angiotensin-converting enzyme were consistent with sarcoidosis. The peculiarity of our pediatric sarcoidosis was the involvement of whole gastrointestinal system, which is exceptionally rare in all age groups. Furthermore, this is the youngest case in the literature with gastrointestinal and hepatic sarcoidosis in the absence of pulmonary involvement at onset.

Keywords: Extra-pulmonary involvement, intestine, liver, pediatric sarcoidosis, stomach

Cite this article as: Kalaycık Şengül Ö, Şahin Akkelle B, Volkan B, Tutar E, Çelikel ÇA, Ertem D. Gastrointestinal sarcoidosis presenting with malabsorption at an early age. *Turk Pediatri Ars* 2020; 55(4): 441-4.

Öz

Sarkoidoz, ağırlıklı olarak torasik lenf nodları ve akciğerleri tutan bir kronik multisistemik granülomatöz hastalıktır ve çoğunlukla genç erişkinlerde görülür. İzole ekstrapulmoner tutulum erişkinlerde sık görülmemekle birlikte çocukluk yaş grubunda çok daha nadirdir. Son 8 aydır kronik ishal ve abdominal distansiyonu olan 4 yaşında bir erkek hasta sunuldu. Gastroskopi ve kolonoskopide alınan biyopsilerde, gastrointestinal sistemin tüm segmentlerinde nonkazeifiye granülomlar tespit edildi. Ayrıca, karaciğer biyopsisinde de nonkazeifiye granülom saptandı. Hem gastrointestinal sistemin hem de karaciğerin granülomatöz inflamasyonu, anjiotensin-dönüştürücü enzim yüksekliği ile birlikte değerlendirildiğinde sarkoidoz ile uyumlu görüldü. Pediatrik sarkoidoz olgumuzun en önemli özelliği, tüm yaş gruplarında son derece nadir görülen gastrointestinal sistem tutulumunun vakamızda yaygın olarak saptanmasıydı. Ayrıca bu olgu başlangıçta akciğer tutulumu olmadan, gastrointestinal ve hepatik tutulumun birlikte görüldüğü dizindeki en genç olgudur.

Anahtar sözcükler: Bağırsak, ekstra pulmoner tutulum, karaciğer, mide, pediatrik sarkoidoz

Introduction

Sarcoidosis is a multisystem inflammatory disorder of unknown etiology that manifests with noncaseating

epitheloid granulomas predominantly in the thoracic lymph nodes and lungs. The most common extrapulmonary presentation in adults is abdominal involvement, particularly the liver (1). Sarcoidosis primarily

Corresponding Author/Sorumlu Yazar: Deniz Ertem E-mail/E-posta: denizertem@marmara.edu.tr

Received/Geliş Tarihi: 13.06.2019 **Accepted/Kabul Tarihi:** 14.11.2019

©Copyright 2020 by Turkish Pediatric Association - Available online at www.turkpediatriarsivi.com

©Telif Hakkı 2020 Türk Pediatri Kurumu Derneği - Makale metnine www.turkpediatriarsivi.com web adresinden ulaşılabilir.

DOI: 10.14744/TurkPediatriArs.2019.93274

OPEN ACCESS This work is licensed under a Creative Commons Attribution-NonCommercial 4.0 International License.



occurs in young adults and is relatively uncommon in children (2) Early-onset childhood sarcoidosis before the age of 5 years has unique clinical features, characterized by the triad of arthritis, rash, and uveitis. The prominent gastrointestinal symptoms at initial presentation are also rare in the pediatric age group, and there are scarce case reports. Furthermore, clinically prominent gastrointestinal sarcoidosis is exceptionally rare before the age of 5 years (3, 4).

We report the youngest patient in the literature with sarcoidosis. He presented with chronic diarrhea and failure to thrive. The distinctive feature of the case is the absence of arthritis, rash, and uveitis, which are specifically described in early-onset childhood sarcoidosis.

Case

A 4-year-old male patient was admitted with chronic diarrhea and abdominal distention for the last 8 months. His anthropometric measurements revealed severe chronic malnutrition (height for age was below 80%) without edema. On physical examination, the patient had abdominal distention and mild hepatomegaly. He was anemic (hemoglobin 10.9 g/dL), and had elevated liver function tests (LFT) (aspartate aminotransferase 83 U/L, alanine aminotransferase 71 U/L, γ -glutamyl transferase 128 U/L, alkaline phosphatase 390 U/L) and hypoalbuminemia (2.7 g/dL). The viral serology for hepatotropic viruses and specific autoantibodies for autoimmune hepatitis were all negative, serum alpha-1 antitrypsin as well as serum ceruloplasmin level was within normal limits. Proteinuria and gastrointestinal loss of protein were excluded as the etiology of hypoalbuminemia. The sedimentation rate was 7 mm/h. Stool microbiologic examinations for viral, bacterial, fungal, and parasite infections were all negative. Ultrasonography demonstrated hepatomegaly and a conglomerate of mesenteric lymph nodes, measuring maximum 16 mm in diameter.

The patient underwent an upper gastrointestinal endoscopy and colonoscopy. Every part of the gastrointestinal tract, including the terminal ileum was normal. However, non-caseating granulomas were detected both in the mucosa and submucosa of the upper gastrointestinal and colonic (including ileal) biopsy samples (Fig. 1, 2). Histopathologic examination of the biopsies was not consistent with Crohn's disease (CD), but suggestive of sarcoidosis or chronic granulomatous disease (CGD). Thus, the patient was further investigated for primary immunodeficiencies. Serum immunoglobulins (Ig), IgG subclasses, and tests for neutrophil superoxide production (nitroblue tetrazolium assay - NBT) and the dihydrorodamine ox-

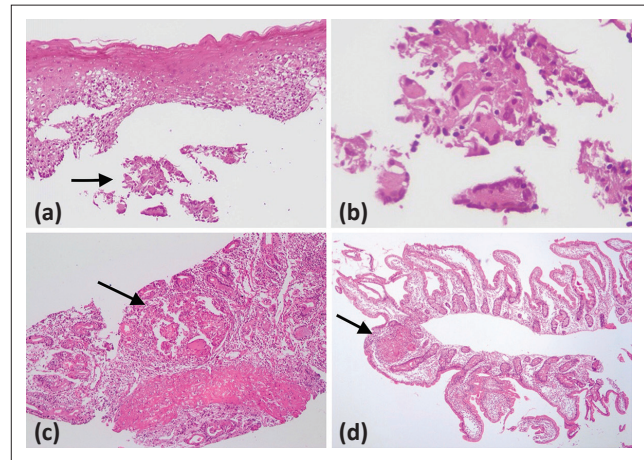


Figure 1. Granulomatous inflammation of the upper gastrointestinal tract. Esophagus (a 10x, b), corpus of the stomach (c 10x), duodenum (d 10x)

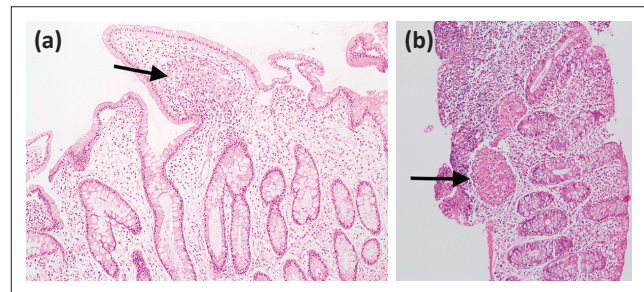


Figure 2. Granulomatous inflammation of the ileum (a 10x) and colon (b 10x)

idation test (DHR) were within normal limits. Although the biopsies were not consistent with CD, anti-saccharomyces cerevisiae antibodies were tested in the patient, which were negative. The presence of uveitis or other ophthalmologic pathologies were also investigated, and this was also normal.

An indeterminate quantiferon test in this patient, coexisting with conglomerated abdominal lymph nodes, entailed a detailed examination for tuberculosis. A normal high-resolution computed tomography of the lungs and a negative gastric juice culture for acid-fast bacillus excluded mycobacterium tuberculosis infection.

Thereafter, a liver biopsy was performed, which revealed granulomas including foreign body giant cells without central necrosis in portal regions, and mild sinusoidal fibrosis in periportal spaces (Fig. 3). Granulomatous inflammation of both the gastrointestinal system and liver along with elevated serum angiotensin-converting enzyme (ACE) levels (117 U/L, N<52 U/L) were consistent with sarcoidosis. The patient was treated with 2 mg/kg/day methylprednisolone. His chronic diarrhea improved,

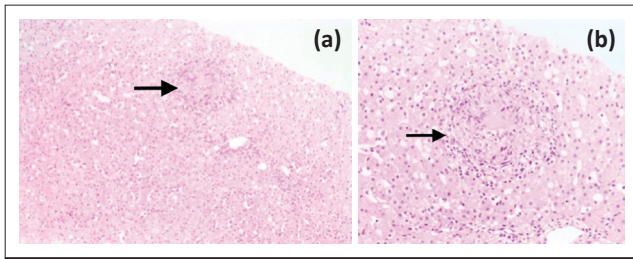


Figure 3. Granulomatous inflammation of the liver (a 40x, b 40x)

and serum ACE levels decreased to normal (18.8 U/L) by the end of the first month of therapy. The dosage of corticosteroid was gradually reduced to 4 mg/day and the patient has been on follow-up for a year with normal LFTs and regression of hepatomegaly. Written informed consent was obtained from the patient.

Discussion

Sarcoidosis is an inflammatory disease that predominantly affects the lungs and lymph nodes. Isolated extrapulmonary sarcoidosis at onset is unusual. Gastrointestinal sarcoidosis is very rare, comprising less than 5% of the cases, depending mostly on autopsy studies (1, 5). However, the paucity of the gastrointestinal symptoms may underestimate the real incidence. Gastric sarcoidosis causes gastritis, gastric ulcers or mild inflammation such as erythema and friability in the stomach, which is the most frequently affected organ of the gastrointestinal tract. However, sarcoidosis of the colon is even rarer and usually asymptomatic. Histopathologic inflammation in the presence of noncaseating granulomas may occur in colorectal sarcoidosis despite the presence of a normal-appearing mucosa in colonoscopy, which is similar to our case (5, 6). Our patient manifested with chronic diarrhea and failure to thrive, which required early endoscopic examination. The peculiarity of our case was that non-caseating granulomas were demonstrated in all endoscopic biopsy samples obtained from the esophagus, stomach, duodenum, terminal ileum, and colon, but they were macroscopically normal. Generally, the paucity of the gastrointestinal manifestations in sarcoidosis and specifically, the younger age of this patient could account for the absence of macroscopic lesions in endoscopy and colonoscopy.

The incidence of small and/or large bowel involvement in sarcoidosis is not known, and there are only a few reported cases. It has been stated that the small intestine was the least commonly involved site (7, 8). The differential diagnosis of gastrointestinal sarcoidosis includes several more commonly seen diseases such as CD, celiac disease, CGD, fungal infection, and intestinal

tuberculosis (5, 7). Sarcoidosis of the colon is also very rare and may mimic CD, thus the differentiation of the two diseases is particularly difficult. Histopathologic and clinical findings, which may favor the diagnosis of sarcoidosis rather than CD, include mucosal involvement instead of transmural inflammation, absence of perianal disease or fistulas, and elevated serum ACE levels (4). The presence of non-caseating granuloma consisting of multinucleate giant cells is the gold standard for the diagnosis of sarcoidosis (7). Moreover, confirmation of granulomas in extra-intestinal organs strongly supports the diagnosis of sarcoidosis (4). Elevated LFTs and the detection of granulomas in the liver biopsy later supported the diagnosis of sarcoidosis in this patient.

The liver is the most common extrapulmonary involvement in sarcoidosis. Asymptomatic elevation of LFTs in the context of known sarcoidosis is the most common presentation (1). However, only a few patients develop progressive clinical features such as liver cirrhosis, portal hypertension, chronic cholestasis, and liver failure (9). Although asymptomatic hepatic sarcoidosis does not require treatment, glucocorticoids can reduce the liver size, the number of granulomas, and improve organ function in symptomatic patients (1). In accordance with previously published data, LFTs returned to normal and liver size reduced in our patient after glucocorticoid therapy.

The current therapy of choice for childhood sarcoidosis is corticosteroids, usually initiated at 1 to 2 mg/kg/day for 4 to 8 weeks as induction treatment (2, 4). The disease activity is monitored clinically, radiographically, and through serum ACE levels (2, 7). In our case, diarrhea improved, and serum ACE levels decreased to normal by the end of the first month of therapy. Maintenance treatment is usually required for at least 6 months for most age groups, and then the dose is tapered when possible.

Prognosis and natural history of sarcoidosis in children are not well documented because of the rarity of the disease, and the small number of reported series. However, the overall prognosis of childhood sarcoidosis is better than in adults (2).

To the best of our knowledge, this is the youngest patient in the literature with gastrointestinal and hepatic sarcoidosis in the absence of pulmonary involvement at onset. Though rare, sarcoidosis should be considered even in small children with malabsorption and granulomatous inflammation of the gastrointestinal tract.

Informed Consent: Written informed consent of the patient was obtained.

Peer-review: Externally peer-reviewed.

Author Contributions: Concept - Ö.K.Ş., B.Ş.A., D.E.; Design - Ö.K.Ş., D.E.; Supervision - E.T., Ç.A.Ç., D.E.; Materials - Ö.K.Ş., Ç.A.Ç., D.E.; Data Collection and/or Processing - Ö.K.Ş.; Analysis and/or Interpretation - Ö.K.Ş., B.Ş.A., B.V., E.T., Ç.A.Ç., D.E.; Literature Review - Ö.K.Ş.; Writing - Ö.K.Ş., D.E.; Critical Review - D.E.

Conflict of Interest: No conflict of interest was declared by the authors.

Financial Disclosure: The authors declared that this study has received no financial support.

Hasta Onamı: Hastanın bilgilendirilmiş, yazılı onamı alınmıştır.

Hakem Değerlendirmesi: Dış bağımsız.

Yazar Katkıları: Fikir - Ö.K.Ş., B.Ş.A., D.E.; Tasarım - Ö.K.Ş., D.E.; Denetleme - E.T., Ç.A.Ç., D.E.; Malzemeler - Ö.K.Ş., Ç.A.Ç., D.E.; Veri Toplanması ve/veya İşlemesi - Ö.K.Ş.; Analiz ve/veya Yorum - Ö.K.Ş., B.Ş.A., B.V., E.T., Ç.A.Ç., D.E.; Literatür Taraması - Ö.K.Ş.; Yazıyı Yazan - Ö.K.Ş., D.E.; Eleştirel İnceleme - D.E.

Çıkar Çatışması: Yazarlar çıkar çatışması bildirmemişlerdir.

Mali Destek: Yazarlar bu çalışma için mali destek almadıklarını beyan etmişlerdir.

References

1. Al-Kofahi K, Korsten P, Ascoli C, et al. Management of extrapulmonary sarcoidosis: challenges and solutions. *Ther Clin Risk Manag* 2016; 12: 1623–34.
2. Gedalia A, Khan TA, Shetty AK, et al. Childhood sarcoidosis: Louisiana experience. *Clin Rheumatol* 2016; 35: 1879–84.
3. Boyum RD, Yeung KJ, Kaplan KJ, et al. Pediatric gastrointestinal sarcoidosis presenting with protein-losing enteropathy. *J Pediatr Gastroenterol Nutr* 2007; 44: 152–6.
4. Alawdah L, Nahari A, Alshahrani D, et al. Pediatric gastrointestinal sarcoidosis: Successful treatment with infliximab. *Saudi J Gastroenterol* 2016; 22: 391–5.
5. Erra P, Crusco S, Nugnes L, et al. Colonic sarcoidosis: unusual onset of a systemic disease. *World J Gastroenterol* 2015; 21: 3380–7.
6. Gezer NS, Başara I, Altay C, et al. Abdominal sarcoidosis: cross-sectional imaging findings. *Diagn Interv Radiol* 2015; 21: 111–7.
7. Stemboroski L, Gaye B, Makary R, et al. Isolated Gastrointestinal Sarcoidosis Involving Multiple Gastrointestinal Sites Presenting as Chronic Diarrhea. *ACG Case Rep J* 2016; 3: e198.
8. Hourigan SK, Baldwin K, Halfpenny C, et al. Gastrointestinal sarcoidosis in an adolescent presenting with hemorrhage from a bleeding duodenal ulcer. *J Pediatr Gastroenterol Nutr* 2009; 49: 474–6.
9. Saito H, Ohmori M, Iwamuro M, et al. Hepatic and gastric involvement in a case of systemic sarcoidosis presenting with rupture of esophageal varices. *Intern Med* 2017; 56: 2583–8.