



Research Article

Effects of Intraperitoneal Zoledronic Acid Administration on Cerebral Vasospasm Following Experimental Subarachnoid Hemorrhage in Rats

Aykan ULUS¹, Özgür ÇELİK², Ayça ARSLANHAN³, Özlem Tuğçe ÇİLİNGİR⁴, Mazhar ÖZKAN⁵, Ayşe Mine YILMAZ⁶, Suheyla Uyar BOZKURT⁷, Mustafa İbrahim ZİYAL⁸

¹Ondokuz Mayıs University, School of Medicine, Department of Neurosurgery, Samsun, Türkiye ²Duzce University, School of Medicine, Department of Neurosurgery, Duzce, Türkiye ³Marmara University, Institute of Neurological Sciences, Laboratory of Molecular Neurosurgery, Istanbul, Türkiye ⁴Marmara University, School of Medicine, Department of Histology and Embryology, Istanbul, Türkiye ⁵Marmara University, School of Medicine, Department of Anatomy, Istanbul, Türkiye ⁶Marmara University, School of Medicine, Department of Biochemistry, Istanbul, Türkiye ⁷Marmara University, Institute of Neurological Sciences, Department of Neuropathology, Istanbul, Türkiye ⁸Marmara University, Institute of Neurological Sciences, Department of Neurosurgery, İstanbul, Turkey

Summary

Background: Early brain injury and cerebral vasospasm are major factors determining outcome for patients who experience subarachnoid hemorrhage (SAH). This study was performed to investigate the potential therapeutic effects of zoledronic acid on cerebral vasospasm in an experimental SAH model.

Methods: Fifteen male Sprague Dawley rats were assigned randomly to one of three groups. Animals in Group I were subjected to sham operation and received no treatment after the procedure (sham group, n=5). Animals in Group II were subjected to SAH and received no treatment after SAH induction (SAH group, n=5). Animals in Group III were subjected to SAH and received 0.1 mg/kg intraperitoneal zoledronic acid injection 2 hours after SAH induction (treatment group, n=5). Animals were euthanized 48 hours after the surgical procedures. Neurological deficit grading, basilar artery vasospasm indices, arterial wall thicknesses, and cross-sectional luminal areas were evaluated. Data were statistically compared by Kruskal-Wallis and Mann-Whitney U tests.

Results: The treatment group showed a better functional neurological amelioration in comparison to SAH group. However, the difference failed to reach statistical significance. In the treatment group, mean basilar artery vasospasm index and mean basilar artery wall thickness were found to be significantly smaller than those of the SAH group, while mean basilar artery cross-sectional luminal area in the treatment group was insignificantly greater than that of the SAH group.

Conclusions: These findings revealed that intraperitoneal zoledronic acid administration attenuated vasospastic changes such as increased vasospasm index and arterial wall thickness in an experimental rat model of SAH.

Key words: Cerebral vasospasm, subarachnoid hemorrhage, vascular morphometry, neurological outcome, zoledronic acid

İntraperitoneal Zoledronik Asid Uygulamasının Ratlarda Deneysel Subaraknoid Kanama Modeliyle Oluşturulmuş Serebral Vazospazm Üzerine Etkisi

Özet

Amaç: Subaraknoid kanamalı (SAK) hastalarda sonucu belirleyen major faktörler erken beyin hasarı ve serebral vazospazmdır. Bu çalışma zoledronik asidin deneysel SAK modeliyle oluşturulmuş serebral vazospazm üzerine potansiyel tedavi edici etkisini araştırmak amacıyla gerçekleştirilmiştir.

Metod: Onbeş adet erkek Sprague Dawley rat rastlantısal olarak üç gruba ayrıldı. Grup I'deki ratlara sham operasyonu yapıldı ve işlem sonrası bir tedavi verilmedi (sham grubu, n=5). Grup II'deki ratlara SAK oluşturuldu ve işlem sonrası tedavi verilmedi (SAK grubu, n=5). Grup III'deki ratlara SAK oluşturuldu ve 2 saat sonra 0.1 mg/kg intraperitoneal zoledronik asid verildi (tedavi grubu, n=5). Ratlar cerrahi işlemler tamamlandıktan 48 saat sonra sakrifiye edildi. Nörolojik defisit dereceleri, baziller arter vazospazm indeksi, arterial duvar kalınlığı ve lumen kesit alanları değerlendirildi. Veriler istatistiksel olarak Kruskal-Wallis ve Mann Whitney U testleri kullanılarak karşılaştırıldı.

Bulgular: Tedavi grubunda ortalama baziller arter vazospazm indeksi ve ortalama arter duvar kalınlığı SAK grubuna göre istatistiksel anlamlı olarak daha az bulundu. Tedavi grubu SAK grubuna göre istatistiksel olarak anlamlı olmamakla birlikte daha iyi bir fonksiyonel nörolojik iyileşme gösterdi ve baziller arter kesit alanı daha genişti.

Sonuç: Bu bulgular ratlarda deneysel SAK modelinde intraperitoneal zoledronik asid uygulamasının vazospazm indeksi ve arterial duvar kalınlığı gibi vazospastik değişiklikleri iyileştirdiğini göstermektedir.

Anahtar Kelimeler: Serebral vazospazm, subaraknoid kanama, vasküler morfometri, nörolojik iyileşme, zoledronik asid

INTRODUCTION

Subarachnoid hemorrhage (SAH) is a devastating disease with a mortality rate of 15% before hospital admission and 40-45% within 30 days posthemorrhage⁽³⁴⁾. Neurological impairment affecting life quality has been reported in 49-73% of survivors⁽¹²⁾. Early brain injury and cerebral vasospasm have been widely claimed as the most important causes of delayed cerebral ischemia and poor outcome in these patients.

Despite an abundance of scientific work, the underlying mechanisms in cerebral vasospasm due to SAH still remain obscure, hindering the development of consistently efficacious treatment modalities. Many molecular pathways have been proposed to take place in the development of cerebral vasospasm, indicating that the process is rather complex and multifactorial. It has been suggested that increased activity of

RhoA/Rho kinase pathway and reduced activity of endothelial nitric oxide synthase (eNOS) are involved in this complicated setting^(7,21,30). Supporting, RhoA/Rho kinase pathway inhibition and eNOS upregulation have been previously documented to attenuate cerebral vasospasm^(13,22). Zoledronic acid (ZA) is an inhibitor of farnesyl pyrophosphate synthase (FPPS), which is an essential enzyme in the mevalonate pathway. Inhibition of this pathway inhibits RhoA activation and leads to eNOS over-expression^(15,16).

The aim of the present study was to investigate the effects of ZA, a third generation biphosphonate, on cerebral vasospasm and neurological outcome following experimentally induced SAH in rats.

MATERIAL AND METHODS

Experiments were performed after the approval of the study protocol by the

Animal Research Ethics Committee. Fifteen male Sprague-Dawley Rats weighing 280-300 grams were used. All animals were kept at the same environmental conditions, including the temperature, humidity, and light/dark cycles. Throughout the experiments, the animals had free access to food and water. The rats were assigned randomly to one of three groups, as follows: animals in Group I underwent sham operation and received no treatment (sham group, n=5), animals in Group II were subjected to SAH, but received no treatment (SAH group, n=5), and animals in Group III were subjected to SAH, and received a single dose of 0.1 mg/kg intraperitoneal Zoledronic acid (ZOLENAT, Mustafa Nevzat, Istanbul, Turkey) 2 hours after SAH induction (treatment group, n=5). Neurological assessment and morphometric evaluation were performed by four investigators blinded to the surgical procedure.

Induction of Experimental SAH and Sham Operation

Any surgical approach was performed after having the animals anesthetized by intramuscular injection of 100 mg/kg ketamine (KETALAR, Eczacıbasi, Istanbul, Turkey) and 10 mg/kg xylazine (ROMPUN, Bayer, Istanbul, Turkey). All animals breathed spontaneously during the procedures. Cardiac rhythm, heart rate, and body temperature were monitored. The right femoral artery was catheterized for monitoring blood pressure and for blood gas analysis. Arterial blood gases were analyzed during the procedure, and parameters were maintained within the physiological range. A midline occipito-cervical incision was made, and suboccipital muscles were dissected to expose the atlanto-occipital membrane. The membrane was punctured by a 27-gauge needle to withdraw cerebrospinal fluid (CSF) from the cisterna magna. The withdrawn CSF was re-injected into the cisterna magna in the sham-operated group. A 0.25 ml volume of non-

heparinized autologous blood obtained from the femoral artery was gently injected into the cisterna magna in the SAH and treatment groups. The animals were then kept in a head-down position with an angle of 30° for 15 minutes to achieve dissemination of blood through the basal cisterns. The animals returned to their cages after recovering from anesthesia. The treatment group received a single dose of 0.1 mg/kg intraperitoneal ZA 2 hours after SAH induction. As there is no previous research of ZA in SAH induced rats, we decided to give 0.1 mg/kg ZA that is commonly used in osteoporosis or cancer researches^(1,24,36). Neurological function was scored in all animals at 12th, 24th, and 48th hours after the surgical procedure.

Perfusion-Fixation

All of the animals were euthanized by perfusion and fixation 48 hours after the surgical intervention having the last neurological scoring completed. The animals were anesthetized and monitored as described previously. A thoracotomy was then performed to cannulate the left ventricle and to open the right atrial wall. After perfusion by a flushing solution (saline, 37°C, 1000 ml), a fixative was perfused (2% paraformaldehyde, 2.5% glutaraldehyde in 0.1 M phosphate buffer, pH 7.4 at 37°C, 500 ml). Perfusion was performed by using a perfusion pump with a standard pressure. The cerebrum, cerebellum, and brainstem were removed en bloc in each animal, and were stored overnight in the fixative solution at 4°C.

Neurological Assessment

Neurological evaluation was performed at the 12th, 24th, and 48th hours after SAH induction according to the neurological grading system described by Bederson et al⁽²⁾. Briefly, rats were gently lifted up by the tail just above the floor. Rats extending both forelimbs toward the floor were accepted as neurologically intact (grade 0). Animals with flexion of one forelimb without further deficits were classified as

mildly symptomatic (grade 1). After placing the rats on a plastic coated surface, animals were observed for their resistance to lateral push and animals with reduced resistance were classified as moderately symptomatic (grade 2). Rats were then allowed to move freely and observed for circling behavior. Rats with consistent unidirectional circling were classified as severely symptomatic (grade 3).

Morphometric Analysis of Basilar Arteries

The part of the brainstem with the basilar artery was isolated. Each basilar artery was sliced into two equal preparations (proximal and distal) with the adjacent brainstem. The preparations were then embedded into paraffin blocks and cross-sections with 0.5 μm thickness were sliced. A cross-section sample from each part of each basilar artery was selected randomly. The sections were mounted onto glass slides, stained with hematoxylin-eosin, and investigated by a light microscope. Each section was digitally photographed at 20x magnification. Vasospasm indices (ratio of wall ring surface area / cross-sectional luminal area), arterial wall thicknesses, and cross-sectional luminal areas were obtained by using a computer-assisted morphometry software (Spot for Windows) after appropriate calibration. Calculations for both cross-sectional luminal area and wall ring surface area (the value achieved by subtracting cross-sectional luminal area from whole-vessel cross-sectional area) were performed indirectly from perimeters of target regions with the formula "Surface = Perimeter² / 4 π " to avoid misleading results due to vessel wall depression as discussed previously⁽⁴⁾.

Statistical Analysis

Data were expressed as mean \pm SD. Statistical comparisons among three groups were performed by using Kruskal-Wallis analysis of variance, and Mann-Whitney U test was used to compare two groups where indicated. Statistical significance was set at $p < 0.05$.

RESULTS

The physiological parameters, including body weight, mean arterial blood pressure, and mean blood gas values were not different among the groups. A subarachnoid clot on the anterior surface of the brainstem, significant narrowing of the arteries, and inflammatory cells around the outer adventitia were observed in the SAH and treatment groups (Figure 1).

Neurological Assessment

The experimental procedure was well tolerated by all of the animals. The neurological deficit scores at the 12th, 24th, and 48th hours postoperatively, are presented in Figure 2. Contrary to the sham-operated rats, SAH-induced animals were significantly impaired, independent of being treated or not. However, ZA-treated rats showed a better neurological amelioration compared to the SAH group due to the neurological assessments, but the difference was not statistically significant.

Morphometric Analysis of Basilar Arteries

The mean vasospasm indices were 0.26 ± 0.03 , 0.42 ± 0.08 and 0.25 ± 0.05 in the sham, SAH, and treatment groups, respectively (Figure 3). The vasospasm index in the SAH group was significantly greater than those of the sham and treatment groups ($p < 0.05$), while this measure was almost the same in the latter two groups indicating the restoring effect of ZA treatment on vasospasm.

The mean basilar artery wall thickness values were 14.83 ± 1.04 , 23.00 ± 1.17 and 14.90 ± 3.05 μm in the sham, SAH, and treatment groups, respectively (Figure 4). Basilar artery wall thickness in the sham group was significantly lower than that of the SAH group ($p < 0.05$) but almost the same with that of the treatment group ($p > 0.05$). This measure was also significantly lower in the treatment group in comparison with the SAH group ($p < 0.05$).

The mean cross-sectional areas were 81273 ± 4873 , 57218 ± 15113 and $75795 \pm 22479 \mu\text{m}^2$ in the sham, SAH, and treatment groups, respectively (Figure 5). The mean arterial cross-sectional area in the sham group was significantly higher than that of the SAH group ($p < 0.05$) and

insignificantly higher than that of the treatment group ($p > 0.05$). The mean arterial cross-sectional luminal area in the treatment group was also higher than that of the SAH group, but this difference failed to attain statistical significance ($p > 0.05$).

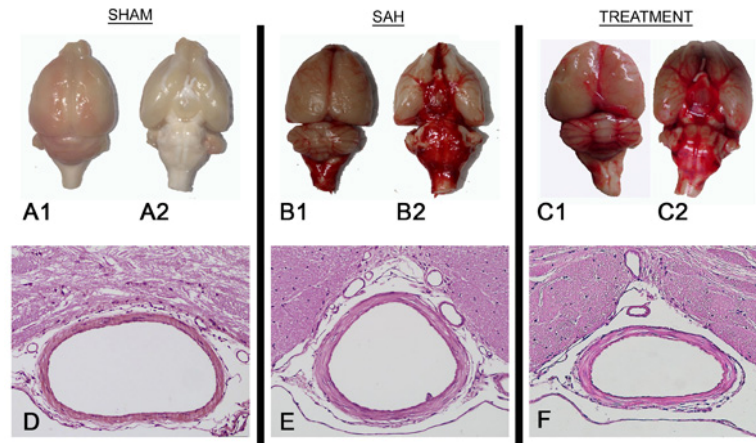


Figure 1: Photographs of samples from each group after en bloc removal of the cerebrum, cerebellum, and brainstem (upper row), photographs of cross-sectional samples from each group at 20x magnification (lower row).

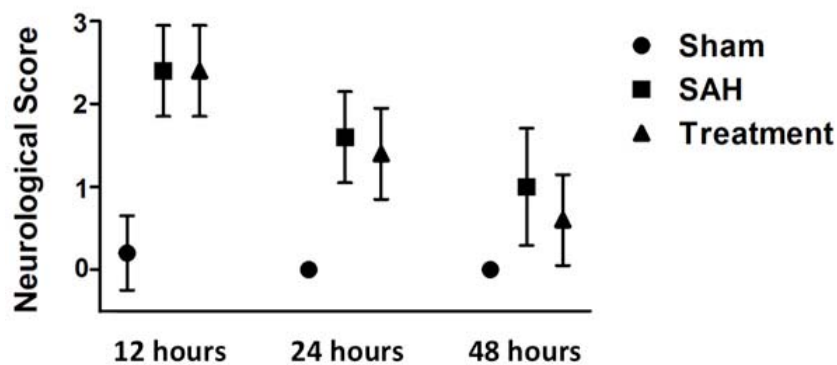


Figure 2: Time course of the neurological impairment in the rats after surgery (0 = no deficit, 1 = mildly, 2 = moderately, 3 = severely symptomatic).

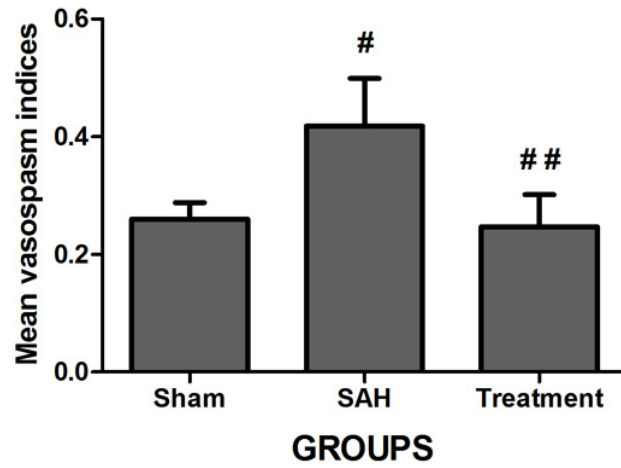


Figure 3: Mean basilar artery vasospasm index (ratio of wall ring surface area/cross-sectional luminal area, mean±SD). #: $p < 0.05$ vs sham group, ##: $p < 0.05$ vs SAH group.

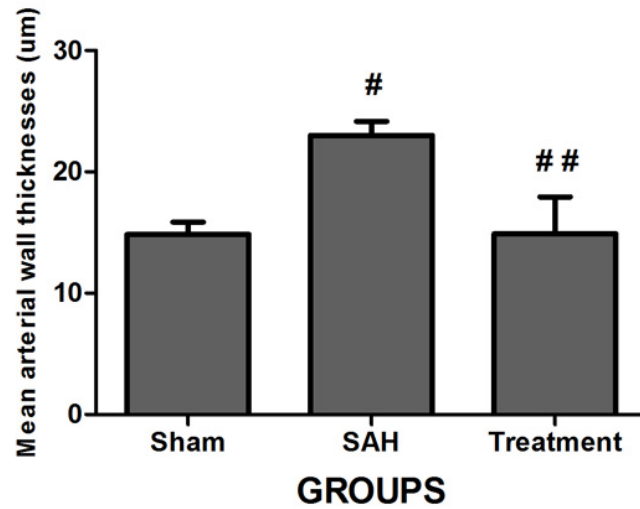


Figure 4: Mean basilar artery wall thickness (mean±SD). #: $p < 0.05$ vs sham group, ##: $p < 0.05$ vs SAH group.

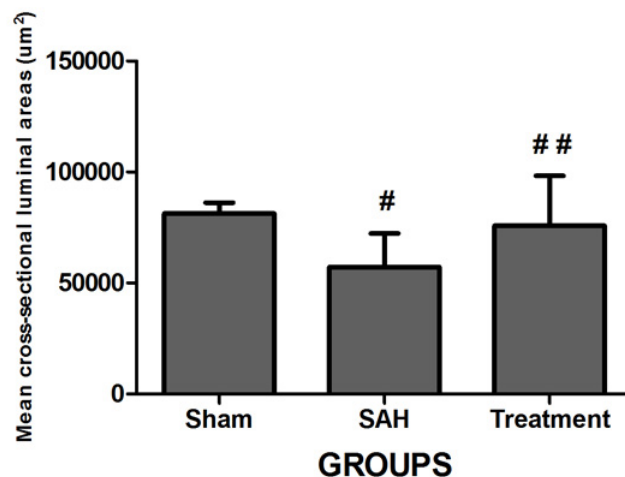


Figure 5: Mean basilar artery cross-sectional luminal areas (mean±SD). #: $p < 0.05$ vs sham group. ##: $p > 0.05$ vs SAH group.

DISCUSSION

Cerebral vascular spasm in the early stage of SAH occurs through a calcium-dependent mechanism in response to hemoglobin exposure released from subarachnoid clot. The intracellular level of calcium increases and drives myosin light chain (MLC) kinase to phosphorylate myosin light chains, to result in transient contraction. In contrast to the above-mentioned mechanism underlying the changes within the acute phase, the prolonged stage of vascular spasm has been accepted to result from a calcium-independent setting mediated by several complex mechanisms⁽⁸⁾. Activation of RhoA by clot-derived substances in the subarachnoid space has been postulated to be the major activator of this scenario. Clot-derived substances activate RhoA, which in turn activates Rho kinase. Rho kinase inhibits the MLC phosphatase. Predomination of MLC kinase over MLC phosphatase increases the phosphorylation of MLC, resulting in prolonged contraction in the absence of high intracellular calcium levels^(7,21). Meanwhile, activated RhoA also downregulates the expression and phosphorylation of the enzyme eNOS, which synthesizes NO, a major relaxant factor released from the endothelial cells.

However, the exact mechanism of action of RhoA on eNOS gene expression has not been clarified yet. There are multiple controlling steps on the regulation of eNOS, such as gene expression, co- and posttranslational modification and phosphorylation⁽⁹⁾. RhoA has been suggested to downregulate eNOS expression by altering eNOS mRNA stabilization⁽³⁾. Reduced eNOS activity following SAH has previously been reported as a major contributor of cerebral vasospasm⁽¹⁰⁾. Additionally, apart from RhoA-mediated mechanisms, vascular wall damage following SAH might be another cause of the reduced eNOS activity. SAH has been reported to be a triggering factor for vascular wall damage via two separate mechanisms. The first involves the detrimental effects of reactive oxygen species in combination with lipid peroxidation products resulting in endothelial and smooth muscle damage⁽⁸⁾. The second involves pro-apoptotic effects of an inflammatory cascade dominantly mediated by tumor necrosis factor α (TNF- α) and interleukin-1 β (IL-1 β) on the endothelial cells⁽¹⁴⁾. Eventually, intimal damage has been postulated to affect the fragile balance between the vasoconstrictors and vasodilators acting on the vascular wall⁽²³⁾.

Some intermediate products of mevalonate pathway, which takes place in cholesterol biosynthesis, seem to be appealing targets in preventing vasospasm via effecting RhoA/Rho kinase- and eNOS-associated mechanisms mentioned above (Figure 6). Farnesyl pyrophosphate synthase (FPPS) catalyzes the synthesis of farnesyl

pyrophosphate (FPP), which in turn results in the production of geranylgeranyl pyrophosphate (GGPP). Isoprenylation of this substance mediates activation of RhoA (small G proteins), which results in activation of Rho kinase and inhibition of eNOS effectivity⁽¹⁶⁾.

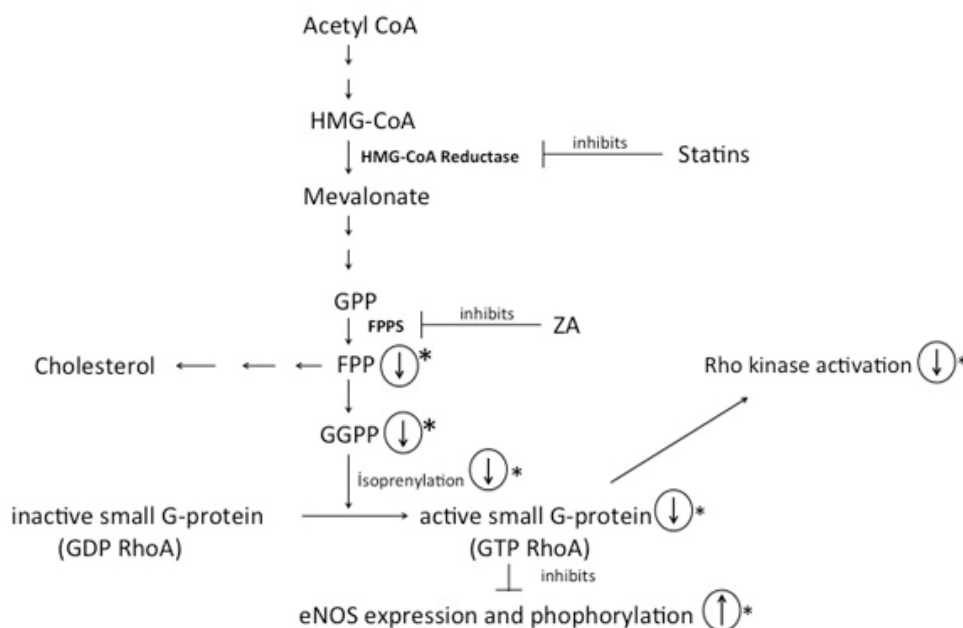


Figure 6: ZA and statins inhibit the key enzymes in mevalonate pathway. (GPP: geranyl pyrophosphate, FPP: farnesyl pyrophosphate, GGPP: geranylgeranyl pyrophosphate, FPPS: farnesyl pyrophosphate synthase, ZA: zoledronic acid, HMG-CoA: hydroxy methyl glutaryl coenzyme A, eNOS: endothelial nitric oxide synthase) * Arrows in the circle show the effect of ZA

Substantial number of previous in vivo experimental studies demonstrated the beneficial effects of targeting RhoA/Rho kinase pathway and eNOS to combat cerebral vasospasm^(5,17,18,25,28,29). However, limited number of pharmacological agents, such as statins and fasudil were documented to be effective in clinical trials^(30,32). Statins, the inhibitors of the enzyme HMG-CoA reductase in the mevalonate pathway, have been widely used for antilipidemic therapy in cardiovascular diseases. Meanwhile, inhibition of this pathway was found to be promising in eNOS upregulation in cardiovascular diseases such as heart

failure and hypertension^(31,33,37). Regarding all these findings and the satisfactory outcomes in the treatment of cardiovascular diseases, several researchers have focused on the potential vasodilator effect of statins in the treatment of SAH-induced vasospasm. Subsequent experimental and clinical studies documented the beneficial effects of statins in attenuating cerebral vasospasm as expected^(20,26,27).

Zoledronic acid (ZA), a third generation bisphosphonate, is a potent inhibitor of osteoclast-mediated bone resorption. This agent has been widely used in the treatment of postmenopausal osteoporosis

and cancer treatment-induced bone loss to reduce fracture risk. Recent studies have shown that ZA also exerts anti-tumoral effect. It has been used in breast cancer and multiple myeloma treatment as adjuvant therapy^(11,19,35). ZA is an inhibitor of farnesyl pyrophosphate synthase (FPPS), which is another essential enzyme in mevalonate pathway. Chen et al. reported that chronic inhibition of FPPS with alendronate, another FPPS inhibitor, improved endothelial function in spontaneously hypertensive rats by suppressing RhoA activation and increasing phospho-eNOS/eNOS ratio⁽⁶⁾. Although ZA treatment has well-documented effects on RhoA- and eNOS-related mechanisms, to the best of our knowledge, no published data regarding the potential therapeutic value of this agent against SAH-induced vasospasm exist in the literature.

The findings from the morphometric evaluation in the present study revealed the therapeutic value of ZA in attenuation of vasospasm, achieving a 41% decrease in the vasospasm index, a 35% decrease in mean arterial wall thickness, and a 33% increase in mean cross-sectional luminal area. The decreases due to ZA treatment in the above-mentioned measures of vasospasm were significant except the latter. Additionally, although being non-significant, ZA treatment provided a better functional amelioration at the 24th and 48th hours after SAH induction.

Statistical insignificance in mean cross-sectional luminal area findings might be due to the multifactorial pathophysiologic nature of cerebral vasospasm. Different dosing regimens and administration routes should be considered and immunohistochemical studies should be performed in order to understand the acting mechanism of ZA in cerebral vasospasm. The probable side effects of ZA, as an anticancer drug, should also be taken into consideration.

CONCLUSION

The present study clearly demonstrates that ZA attenuates SAH-induced vasospastic changes, including increased vasospasm index and arterial wall thickness. ZA treatment provided a slight but insignificant amelioration in the SAH-induced decrease in cross-sectional luminal area in rats. A remarkable but insignificant improvement in neurological functions was also observed. Our findings indicate that this treatment modality is a promising candidate for further experimental studies to evaluate maximal therapeutic effect with different dosing regimens.

Declaration of interest: The authors report no conflicts of interest. The authors alone are responsible for the content and writing of this paper.

Correspondence to:

Aykan Ulus

E-mail: aykanulus@gmail.com

Received by: 16 November 2014

Revised by: 17 August 2015

Accepted: 17 August 2015

The Online Journal of Neurological Sciences (Turkish) 1984-2015

This e-journal is run by Ege University Faculty of Medicine, Dept. of Neurological Surgery, Bornova, Izmir-35100TR

as part of the Ege Neurological Surgery World Wide Web service.

Comments and feedback:

E-mail: editor@jns.dergisi.org

URL: <http://www.jns.dergisi.org>

Journal of Neurological Sciences (Turkish)

Abbr: J. Neurol. Sci.[Turk]

ISSNe 1302-1664

REFERENCES

1. Bäckman U, Svensson A, Christofferson RH, Azarbayjani F. The bisphosphonate, zoledronic acid reduces experimental neuroblastoma growth by interfering with tumor angiogenesis. *Anticancer Res.* 2008 May-Jun;28(3A):1551-7.
2. Bederson JB, Pitts LH, Tsuji M, Nishimura MC, Davis RL, Bartkowski H. Rat middle cerebral artery occlusion: evaluation of the model and development of a neurologic examination. *Stroke.* 1986 May-Jun;17(3):472-6.
3. Brandes RP. Statin-Mediated Inhibition of Rho: Only to Get More NO? *Circ Res.* 2005;96:927-29.
4. Celik O, Bay HH, Arslanhan A, Oroğlu B, Bozkurt SU, Sehirli US, Ziyal MI. Effect of hyperbaric oxygen therapy on cerebral vasospasm: a vascular morphometric study in an experimental subarachnoid hemorrhage model. *Int J Neurosci.* 2014 Aug;8:593-600.
5. Chang CZ, Wu SC, Kwan AL, Hwang SL, Howng SL. Magnesium lithospermate B alleviates the production of endothelin-1 through an NO-dependent mechanism and reduces experimental vasospasm in rats. *Acta Neurochir (Wien).* 2011 Nov;153(11):2211-7.
6. Chen GP, Li L, Yang Y, Fu M, Yao L, Wu T, Zhang XQ, Hu SJ. Chronic inhibition of farnesyl pyrophosphate synthase improves endothelial function in spontaneously hypertensive rats. *Biochem Pharmacol.* 2010 Dec 1;80(11):1684-9.
7. Chrissobolis S, Sobey C. Recent evidence for an involvement of Rho-Kinase in cerebral vascular disease. *Stroke.* 2006;37:2174-180.
8. Findlay JM. Cerebral vasospasm. In: *Youmans Neurological Surgery.* Ed: Winn HR. 6th ed. Philadelphia, Elsevier Saunders, 2011. Chapter 364; p. 3791-800.
9. Govers R, Ravelink TJ. Cellular regulation of endothelial nitric oxide synthase. *Am J Physiol Renal Physiol.* 2001;280:F193-F206.
10. Hino A, Tokuyama Y, Weir B, Takeda J, Yano H, Bell GI, Macdonald RL. Changes in endothelial nitric oxide synthase mRNA during vasospasm after subarachnoid hemorrhage in monkeys. *Neurosurgery.* 1996;39(3):562-68.
11. Huang WW, Huang C, Liu J, Zheng HY, Lin L. Zoledronic acid as an adjuvant therapy in patients with breast cancer: a systematic review and meta-analysis. *PLoS One.* 2012;7(7):e40783.
12. Kapapa T, Woischneck D, Tjahjadi M. Long-term health-related quality of life after spontaneous nontraumatic subarachnoid hemorrhage: self and proxy reports in a 10-year period. *World Neurosurg.* 2014 Jan;81(1):105-9.
13. Khurana VG, Smith AL, Baker TA, Eguchi D, O'Brien T, Katusic ZS. Protective vasomotor effects of in vivo recombinant endothelial nitric oxide synthase gene expression in a canine model of cerebral vasospasm. *Stroke.* 2002;33:782-89.
14. Kimura H, Gules I, Meguro T, Zhang JH. Cytotoxicity of cytokines in cerebral microvascular endothelial cell. *Brain Res.* 2003;990(1-2):148-56.
15. Laufs U, La Fata V, Plutzky J, Liao JK. Upregulation of endothelial nitric oxide synthase by HMG CoA reductase inhibitors. *Circulation.* 1998;97:1129-35.
16. Laufs U, Liao JK. Post-transcriptional regulation of endothelial nitric oxide synthase mRNA stability by Rho GTPase. *J Biol Chem.* 1998;273:24266-71.
17. Lin CL, Shih HC, Lieu AS, Lee KS, Dumont AS, Kassell NF, Howng SL, Kwan AL. Attenuation of experimental subarachnoid hemorrhage--induced cerebral vasospasm by the adenosine A2A receptor agonist CGS 21680. *J Neurosurg.* 2007 Mar;106(3):436-41.
18. Lin CL, Su YF, Dumont AS, Shih HC, Lieu AS, Howng SL, Lee KS, Kwan AL. The effect of an adenosine A1 receptor agonist in the treatment of experimental subarachnoid hemorrhage-induced cerebrovasospasm. *Acta Neurochir (Wien).* 2006 Aug;148(8):873-9.
19. Locke FL, Morgan GJ. What is the evidence for the use of bisphosphonate therapy in newly diagnosed multiple myeloma patients lacking bone disease? *Hematology Am Soc Hematol Educ Program.* 2012;2012:350-3.
20. McGirt MJ, Pradilla G, Legnani FG, Thai QA, Recinos PF, Tamargo RJ, Clatterbuck RE. Systemic administration of simvastatin after the onset of experimental subarachnoid hemorrhage attenuates cerebral vasospasm. *Neurosurgery.* 2006 May;58(5):945-51.
21. Motohiko Sato M, Tani E, Fujikawa H, Kaibuchi K. Involvement of Rho-Kinase-mediated phosphorylation of myosin light chain in enhancement of cerebral vasospasm. *Circ Res.* 2000;87:195-200.
22. Naraoka M, Munakata A, Matsuda N, Shimamura N, Ohkuma H. Suppression of the Rho/Rho-Kinase pathway and prevention of cerebral vasospasm by combination treatment with statin and fasudil after subarachnoid hemorrhage in rabbit. *Transl Stroke Res.* 2013;4:368-74.
23. Ostrowski RP, Zhang JH. Hyperbaric oxygen for cerebral vasospasm and brain injury following subarachnoid hemorrhage. *Transl Stroke Res.* 2011;2:316-27.
24. Palacio EP, Müller SS, Sardenberg T, Mizobuchi RR, Galbiatti JA, Durigan A Jr, Savarese A, Ortolan EV. Detecting early biomechanical effects of zoledronic Acid on femurs of osteoporotic female rats. *J Osteoporos.* 2012;2012:162806.
25. Pradilla G, Garzon-Muvdi T, Ruzevick JJ, Bender M, Edwards L, Momin EN, Thompson RC, Tamargo RJ. Systemic L-citrulline prevents cerebral vasospasm in haptoglobin 2-2 transgenic mice after subarachnoid hemorrhage. *Neurosurgery.* 2012 Mar;70(3):747-56.
26. Rikitake Y, Liao JK. Rho GTPases, statins, and nitric oxide. *Circ Res.* 2005 December 9; 97(12):1232-35.

27. Sabri M, Ai J, Marsden PA, Macdonald RL. Simvastatin re-couples dysfunctional endothelial nitric oxide synthase in experimental subarachnoid hemorrhage. *PLoS One*. 2011 Feb 23;6(2):e17062.
28. Shao Z, Li J, Zhao Z, Gao C, Sun Z, Liu X. Effects of tetramethylpyrazine on nitric oxide/cGMP signaling after cerebral vasospasm in rabbits. *Brain Res*. 2010 Nov 18;1361:67-75.
29. Shih HC, Lin CL, Wu SC, Kwan AL, Hong YR, Howng SL. Upregulation of estrogen receptor alpha and mediation of 17beta-estradiol vasoprotective effects via estrogen receptor alpha in basilar arteries in rats after experimental subarachnoid hemorrhage. *J Neurosurg*. 2008 Jul;109(1):92-9.
30. Siuta M, Zuckerman SL, Mocco J. Nitric oxide in cerebral vasospasm: Theories, measurement, and treatment. *Neurol Res Int*. 2013;2013:972417.
31. Sun HX, Zeng DY, Li RT, Pang RP, Yang H, Hu YL, Zhang Q, Jiang Y, Huang LY, Tang YB, Yan GJ, Zhou JG. Essential role of microRNA-155 in regulating endothelium-dependent vasorelaxation by targeting endothelial nitric oxide synthase. *Hypertension*. 2012 Dec;60(6):1407-14.
32. Suzuki Y, Shibuya M, Satoh S, Sugimoto Y, Takakura. A postmarketing surveillance study of fasudil treatment after aneurysmal subarachnoid hemorrhage. *Surg Neurol*. 2007 Aug;68(2):126-31.
33. Tousoulis D, Oikonomou E, Siasos G, Stefanidis C. Statins in heart failure-With preserved and reduced ejection fraction. An update. *Pharmacol Ther*. 2014 Jan;141(1):79-91.
34. van Gijn J, Kerr RS, Rinkel GJ. Subarachnoid haemorrhage. *The Lancet*. 2007;369(9558):306-18.
35. Winter MC, Coleman RE. Bisphosphonates in the adjuvant treatment of breast cancer. *Clin Oncol*. 2013 Feb;25(2):135-45.
36. Yu NY, Ruys AJ, Zenios M, Godfrey C, McDonald M, Kiely P, Mikulec K, Little DG, Schindeler A. Bisphosphonate-laden acrylic bone cement: mechanical properties, elution performance, and in vivo activity. *J Biomed Mater Res B Appl Biomater*. 2008 Nov;87(2):482-91.
37. Zhang Z, Wang M, Xue SJ, Liu DH, Tang YB. Simvastatin ameliorates angiotensin II-induced endothelial dysfunction through restoration of Rho-BH4-eNOS-NO pathway. *Cardiovasc Drugs Ther*. 2012 Feb;26(1):31-40.