

Unintentional Weight Loss in Adults 65 Years or Older

A Symptom of Physical and Psychiatric Etiologies

Nurdan Şentürk Durmuş, MD, Büşra Can, MD, and Aslı Tufan, MD

Abstract: Unintentional weight loss is defined as a more than 5% decrease in body weight within 1 year. Various physical and psychiatric etiologies cause unintentional weight loss, including major depressive disorder (MDD). We present the case of a 69-year-old woman who lost 10 kg in 2 months. She had anhedonia, mobility limitations, and incontinence. Her Mini Nutritional Assessment score indicated malnutrition, whereas her Geriatric Depression Scale score indicated a diagnosis of MDD. Whole-body fluorodeoxyglucose (FDG)-positron emission tomography/computed tomography showed intensely increased FDG uptake in the muscles adjacent to the right and left mandibular rami and the temporal muscle, compatible with jaw clenching associated with the patient's MDD. Subsequent temporal muscle biopsy did not suggest the causes of malignant disorders, dermatomyositis, or polymyositis. Having ruled out all possible organic pathologies, the patient was thus diagnosed with MDD. Escitalopram was prescribed for her MDD, and oral nutritional supplement treatments were initiated for her malnutrition. Patients who present with unintentional weight loss should be assessed first for physical etiologies, and then psychiatric etiologies, particularly as weight loss may be a major symptom of MDD in older adults.

Key Words: FDG-PET/CT, major depressive disorder, older adults, unintentional weight loss

(*J Nerv Ment Dis* 2022;210: 640–642)

Unintentional weight loss is described as a more than 5% decrease in body weight within 1 year. Its prevalence varies between 15% and 20% in older adults who are 65 years or older (Gaddey and Holder, 2014). Unintentional weight loss is associated with dependency, frailty, fractures, increased risk of infections, sarcopenia, morbidity, and mortality (Chapman, 2011; Gaddey and Holder, 2014). When older adults present with unintentional weight loss, physical causes should be considered first; examinations for malignancies appropriate for the age and sex of the person should be performed (Gaddey and Holder, 2014). Organic diseases, including endocrine, cardiopulmonary, infectious, neurological, gastrointestinal, and renal diseases; malignancies; and medications may cause unintentional weight loss (Gaddey and Holder, 2014).

Another important reason for weight loss is psychiatric problems, most commonly major depressive disorder (MDD) (Chapman, 2011). The prevalence of MDD is approximately 1% to 10% in adults 65 years or older (Vieira et al., 2014). Older females are more prone to be diagnosed with MDD than older males (Vieira et al., 2014). MDD in older age has a clinical spectrum ranging from mild to major

(Vieira et al., 2014). There is a higher prevalence of somatic complaints in older adults with MDD. These include decreased appetite, weight loss, sleep problems, pain, anhedonia, exhaustion, functional deficits, and cognitive problems (Casey, 2017). In fact, in older adults, MDD is more likely to present as a loss of appetite/weight versus depressed mood (Chapman, 2011). MDD is related to disability, immobility, impaired quality of life, falls, and mortality (Vieira et al., 2014). Various scales are used for diagnosing MDD in older adults, including the Geriatric Depression Scale (GDS) (Brink et al., 1982) and the Hamilton Depression Scale (Hamilton, 1960). A GDS cutoff score of more than 14 indicates a diagnosis of MDD (Brink et al., 1982). Psychotherapy, including cognitive-behavioral therapy, and psychotropic medications including selective serotonin reuptake inhibitors (SSRI), serotonin-norepinephrine reuptake inhibitors, and other antidepressants, can be used for treatment (Bottino et al., 2012; Phillips, 2012). SSRIs are the first class of medications for the initial treatment of MDD in older adults, as they offer the most favorable safety and efficacy (Bottino et al., 2012; Casey, 2017).

“Geriatric failure to thrive,” which affects 5% to 35% of older adults, is a term that includes weight loss, decreased appetite, and apathy (Casey, 2017; Phillips, 2012), which may be accounted for by the physical and/or psychiatric etiologies mentioned above. Given the variety of possible origins, it is therefore important to assess people presenting with unintentional weight loss for both etiologies (e.g., detailed medical history, thorough physical examination, relevant laboratory tests, photo/functional imaging).

The case presented below illustrates how unintentional weight loss in older people can be systematically evaluated to first rule out physical causes, before determining a correct MDD diagnosis. Here, we report on an older adult woman, presenting with symptoms of unintentional weight loss, malnutrition, and “failure to thrive,” who had assessment results that were incompatible with organic etiologies but were consistent with those of MDD. Written informed consent was obtained from the patient.

CASE PRESENTATION

A 69-year-old woman presented to the outpatient clinic with unintentional weight loss. She reported having lost approximately 10 kg in 2 months (from 45 to 35 kg). After her husband's cancer diagnosis, she started eating less and withdrawing from the family. She avoided her daily routines, stayed in bed all day, and had trouble sleeping at night. She complained of new-onset mobility limitations and reported a fall in the previous year. When fecal and urinary incontinence developed, her family insisted that she consult a doctor. She was unwillingly brought to our outpatient clinic by her son. Family history was unremarkable for MDD. Past individual history was significant for hyperlipidemia, osteoporosis, and a previous MDD episode 5 years ago. She was treated for MDD for 6 months and then quit treatment on her own. She did not smoke or drink alcohol. Last year, her husband was diagnosed with colon cancer and received chemotherapy. A review of her past individual symptoms was negative for fever, night sweats, cough, nausea, vomiting, arthritis, arthralgia, dysuria, urgency, or any alarm symptoms.

Division of Geriatrics, Department of Internal Medicine, Marmara University Medical School, Istanbul, Turkey.

Send reprint requests to Nurdan Şentürk Durmuş, MD, Divisions of Geriatrics, Department of Internal Medicine, Marmara University Medical School, Fevzi Çakmak Mahallesi Muhsin Yazıcıoğlu Caddesi No: 10 Üst Kaynarca, Pendik, İstanbul, Turkey 34890. E-mail: nurdansenturkdurmus@hotmail.com.

Ethical considerations statement: Written informed consent was obtained from the patient.

Copyright © 2022 Wolters Kluwer Health, Inc. All rights reserved.

ISSN: 0022-3018/22/21008-0640

DOI: 10.1097/NMD.0000000000001517

TABLE 1. Admission Laboratory Values of the Patient With Unintentional Weight Loss

	On Admission	Reference Range
White blood cell, $\times 10^3/\mu\text{L}$	5.100	4.000–10.000
Neutrophil, $\times 10^3/\mu\text{L}$	3.690	1.400–6.200
Hemoglobin, g/dL	11.9	12.0–17.0
Hct, %	38	36.0–50.0
MCV, fL	91.4	82.0–97.0
Thrombocyte, $\times 10^3/\mu\text{L}$	214	150.0–400.0
Glucose, mg/dL	84	65–110
Creatinine, mg/dL	0.45	0–1.2
GFR, mL/m	70	
Sodium, mEq/L	141	136–146
Potassium, mEq/L	3.5	3.5–5.1
Calcium, mEq/L	9	8.8–10.6
Phosphorus, mEq/L	2.4	2.8–4.0
Magnesium, mEq/L	2	1.8–2.6
AST, U/L	14	10–37
ALT, U/L	6	10–40
Total protein, g/dL	6.6	6.4–8.3
Albumin, g/dL	3.6	3.5–5.2
C-reactive protein, mg/L	17.15	0–5
Sedimentation, mm/hr	48	0–30
Prothrombin time, sec	14.8	11–13
INR	1.09	
aPTT, sec	30.3	28–36
D-dimer, mg/dL	0.51	0–0.5
Creatinine kinase, U/L	38	0–190
LDH, U/L	170	0–248
Ferritin, $\mu\text{g/L}$	55	30–400
25-OH vitamin D, $\mu\text{g/L}$	32	30–80
Vitamin B12, ng/L	450	197–771

Values written in boldface are outside the reference range.

ALT indicates alanine aminotransferase; aPTT, activated partial thromboplastin time; AST, aspartate aminotransferase; GFR, glomerular filtration rate; Hct, hematocrit; INR, international normalized ratio; LDH, lactate dehydrogenase; MCV, mean corpuscular volume.

On clinical examination, her affect was apathetic, her mood was depressed, and her speech was of slow rate. She was underweight (body mass index, 14.6 kg/m^2) with no palpable lymphadenopathy or organomegaly. As for the patient's geriatric assessment, she was completely dependent on basic and instrumental activities of daily living and had normal cognition (Mini-Mental State Examination score, 28/30). She was frail (fatigue, resistance, aerobic capacity, illnesses, and loss of weight [FRAIL], 4/5), malnourished (Mini Nutritional Assessment [MNA], 8/30), sarcopenic, and had slow gait speed (<0.8 m/sec). Her GDS score was 26/30.

Initial laboratory values included anemia (hemoglobin 11.9 g/dL; reference range, 12.0–17.0), high C reactive protein (17.15 mg/L; reference range, 0.0–5.0 mg/L), high sedimentation rate (48 mm/hr; reference, range, 0–30 mm/hr), and low phosphorus level (2.4 mg/dL; reference range, 2.8–4.0 mg/dL). Other laboratory parameters were normal (Table 1).

Electrocardiogram had sinus rhythm (65/m), normal conduction, and was completely normal with no ischemia. Echocardiography revealed an ejection fraction of 65% and normal wall motions. Cranial imaging was performed for new-onset neurological symptoms and fall history. Magnetic resonance imaging revealed cerebral and cerebellar atrophy, ischemic gliotic foci in bilateral centrum semiovale and

periventricular area, and right cerebellar hemisphere. Abdominal imaging and upper/lower gastrointestinal system endoscopies were reported as normal. Mammography and gynecological examination were also unremarkable. Whole-body fluorodeoxyglucose–positron emission tomography–computed tomography (FDG-PET/CT) imaging was performed to rule out malignancies. FDG-PET/CT showed intensely increased FDG uptake (standardized uptake value [SUV] max, 14.05; normal value is 2.5) in the muscles adjacent to the right and left mandibular rami as well as the right temporal muscle (SUV max, 9.81) (Fig. 1). A 6-mm-wide pericardial effusion was also detected. The patient was consulted with rheumatology for the presence of myositis-like involvement and pericardial effusion in FDG-PET/CT. Anti-nuclear antibody was weakly positive (1/100 dense fine mottled), and complement 3 (C3) and complement 4 (C4) levels were normal. Temporal muscle biopsy was performed from the site of FDG uptake. The biopsy findings were not compatible with malignancy, dermatomyositis, or polymyositis. Immunohistochemical staining revealed CD3 and CD20 positivity in rare scattered lymphoid cells; periodic acid–Schiff (PAS) staining was negative and trichrome staining revealed no fibrosis.

We concluded that the findings on FDG-PET/CT were compatible with chronic jaw clenching associated with the patient's depression. Having ruled out all possible organic causes, the patient was diagnosed with MDD with no underlying malignant or rheumatological diseases and malnutrition. Escitalopram (5 mg/day for the first week followed by 10 mg/day) and oral nutritional supplements (ONS) were initiated.

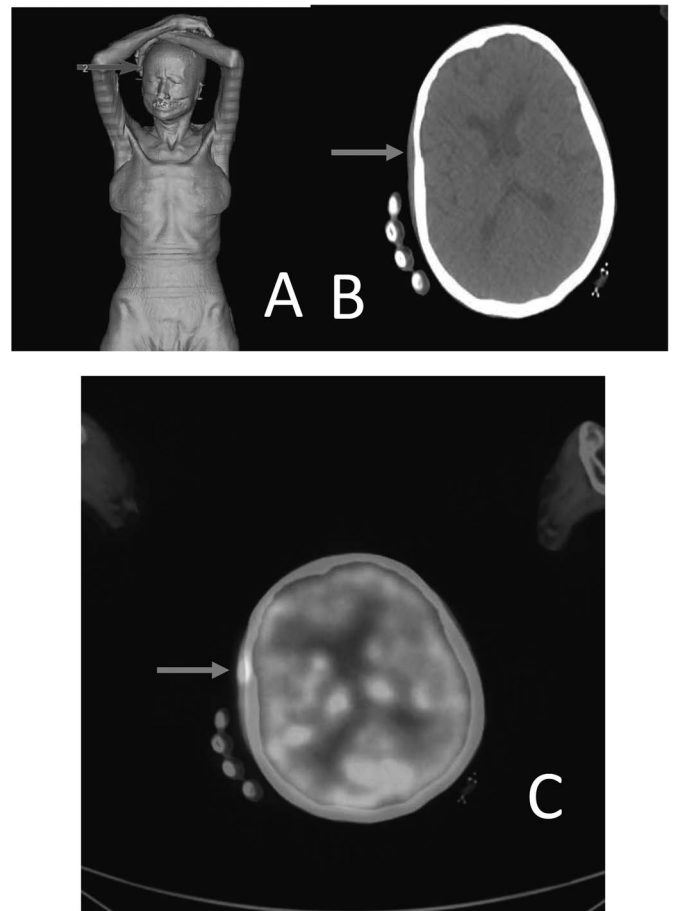


FIGURE 1. PET/CT images of the unintentional weight loss patient. The blue arrows show the site of the temporal muscle biopsy; volume-rendered image (A), CT image (B), and intensely increased FDG uptake on PET/CT (C).

Downloaded from http://journals.lww.com/jonmd by BhDMf5ePHKav1zEoum1tQANnA+kLjNEZgpsiH04XWl0hCymwCX1A WwYQp/ID3D00CRjv7TTSFAC3VVC1y0abggQZXdwnIKZBYtws= on 08/07/2023

The patient's appetite, anhedonia, chronic jaw clenching, and sleep problems improved under escitalopram and ONS treatment, and she started gaining weight.

DISCUSSION

In summary, the presenting case was determined to have weight loss due to MDD, not organics. This highlights the importance of taking a detailed medical history, as noted above. Gaddey and Holder (2014) suggest that patient assessments include comorbidities, medications, alcohol use, smoking, acute illness, appetite, eating habits, physical examination, and socioeconomic status (which may reveal risk factors). In addition, the current status of the patient's bodily symptoms should be evaluated (e.g., oral cavity/dentition, pulmonary, gastrointestinal, cardiovascular, rheumatological, neurological, and malnutrition risk).

The laboratory evaluation should include blood count, renal function tests, electrolytes, liver function tests, glucose, lactate dehydrogenase, C reactive protein, thyroid function tests, erythrocyte sedimentation rate, and urinalysis (Gaddey and Holder, 2014). If a patient has respiratory complaints, a smoking history, and/or risk factors for lung disease, chest imaging should also be performed. In this case, even though the patient's history pointed to depression, because of the severity of weight loss and new-onset neurological symptoms, we investigated the patient for malignant and neurological disorders. Temporal muscle involvement on FDG-PET/CT led to an investigation of myositis. Therefore, a more invasive procedure, namely, a muscle biopsy, was performed. The biopsy findings helped rule out myositis in our patient.

The potential for both physical and psychiatric etiologies for the symptom of unintentional weight loss is illustrated in a prior study by Metalidis et al. (2008). In their sample ($N = 114$), half of the participants ($n = 57$) were diagnosed with an organic disease, and 16% ($n = 16$) of the participants were diagnosed with a psychiatric disorder (MDD, $n = 8$; anxiety, $n = 5$; dementia, $n = 3$). This interconnection has also been shown in studies where a high GDS score was associated with a low MNA score, and participants with MDD have a poor appetite (Torres et al., 2010). To be thorough, it has been suggested that physicians perform a weight loss workup even if the patient is diagnosed with

MDD, as an underlying organic condition may also be present (Gaddey and Holder, 2014; Torres et al., 2010).

In conclusion, unintentional weight loss may be a symptom of physical and/or psychiatric etiologies. Assessments should first include a thorough medical examination to rule out organic causes for weight loss, and then a comprehensive psychiatric evaluation to determine a diagnosis(es), if appropriate (Gaddey and Holder, 2014; Torres et al., 2010). Given that both physical and psychiatric symptoms are associated with impairment in geriatric failure to thrive (Phillips, 2012), it is important that a comprehensive evaluation must be conducted not only to mitigate/eliminate symptoms but also to reduce the impact on related areas of functioning.

DISCLOSURE

The authors declare no conflict of interest.

REFERENCES

- Bottino CM, Barcelos-Ferreira R, Ribeiz SR (2012) Treatment of depression in older adults. *Curr Psychiatry Rep.* 14:289–297.
- Brink TL, Yesavage JA, Lum O, Heersema PH, Adey M, Rose TL (1982) Screening tests for geriatric depression. *Clin Gerontol.* 1:37–44.
- Casey DA (2017) Depression in older adults: A treatable medical condition. *Prim Care.* 44:499–510.
- Chapman IM (2011) Weight loss in older persons. *Med Clin North Am.* 95:579–593.
- Gaddey HL, Holder K (2014) Unintentional weight loss in older adults. *Am Fam Physician.* 89:718–722.
- Hamilton M (1960) A rating scale for depression. *J Neurol Neurosurg Psychiatry.* 23:56–62.
- Metalidis C, Knockaert DC, Bobbaers H, Vanderschueren S (2008) Involuntary weight loss. Does a negative baseline evaluation provide adequate reassurance? *Eur J Intern Med.* 19:345–349.
- Phillips RM (2012) Nutrition and depression in the community-based oldest-old. *Home Healthc Nurse.* 30:462–471 quiz 472–463.
- Torres SJ, McCabe M, Nowson CA (2010) Depression, nutritional risk and eating behaviour in older caregivers. *J Nutr Health Aging.* 14:442–448.
- Vieira ER, Brown E, Raue P (2014) Depression in older adults: Screening and referral. *J Geriatr Phys Ther.* 37:24–30.