

Osteocalcin and Cross-Linked C-Terminal Telopeptide of Type I Collagen in Gingival Crevicular Fluid during Piezocision Accelerated Orthodontic Tooth Movement: A Randomized Split-Mouth Study

HS Yıldırım, M Ateş¹, IO Gün¹, B Kuru², B Çakırer³, L Kuru

Department of Periodontology, Dental Faculty, Marmara University, Istanbul, ¹Private Practitioner in Orthodontics, Istanbul, ²Department of Periodontology, Dental Faculty, Yeditepe University, Istanbul, ³Department of Orthodontics, Dental Faculty, Okan University, Istanbul, Turkey

Received: 11-Aug-2022;
Revision: 11-Dec-2022;
Accepted: 12-Jan-2023;
Published: 15-May-2023

ABSTRACT

Background: Piezocision, a minimally invasive surgical procedure, has been used to accelerate tooth movement" is appropriate as a background to the abstract section. **Aim:** The aim of this randomized split-mouth study was to evaluate gingival crevicular fluid (GCF) osteocalcin (OC) and type I collagen cross-linked C-terminal telopeptide (ICTP) levels during canine distalization with and without piezocision acceleration. **Material and Methods:** Fifteen systemically healthy subjects (M:F 7:8, 16.27 ± 1.14 years) requiring extraction of maxillary first premolars before retraction of canines were included in the study. Piezocisions were randomly carried out on one of the maxillary canines while bilateral canines served as controls. Canine distalization was conducted using closed-coil springs applying a force of 150 g/side by using miniscrews as anchorage. GCF sampling was performed from maxillary canine mesial and distal sites at baseline, 1, 7, 14, and 28 days. The GCF levels of OC and ICTP were detected by enzyme-linked immunosorbent assay (ELISA). The rate of tooth movement was evaluated at 2-week intervals. **Results:** The amounts of canine distalization from baseline to 14 and 28 days in the piezocision group were significantly higher than the control group ($P < 0.05$). The GCF OC level of the piezocision group on the tension side and the ICTP level of the same group on the compression side were higher than the respective sides of the control group on day 14 ($P < 0.05$). **Conclusions:** Piezocision was found to be an effective treatment procedure for accelerating canine distalization accompanied by increased levels of OC and ICTP.

KEYWORDS: ICTP, osteocalcin, piezosurgery, tooth movement

INTRODUCTION

In recent years, accelerated tooth movement has become one of the most popular issues in the field of orthodontics. The duration of orthodontic treatment using fixed appliances requires approximately 2 years.^[1] Since canine distalization may take up to 8 months in extraction cases,^[2,3] additional surgical techniques, including corticotomy, micro-osteoperforations, corticision, piezopuncture, and piezocision, may be preferred for rapid tooth movement.^[4,5]

Piezocision, a minimally invasive surgical procedure, has been used to accelerate tooth movement since its introduction by Dibart in 2009.^[6] This technique

includes micro-incisions limited to buccal gingiva that allow the use of a piezoelectric knife to give osseous cuts to buccal cortex and thereby initiate the regional acceleratory phenomenon (RAP).^[6,7] Once RAP begins, regional soft and hard tissue processes such as perfusion, growth, and bone turnover increase above normal values.^[8] There is a localized surge in both osteoblastic

Address for correspondence: Dr. HS Yıldırım, Recep Tayyip Erdoğan Külliyesi Sağlık Yerleşkesi, Başbüyük Yolu 9/3 34854 Başbüyük Maltepe-İstanbul, Turkey. E-mail: yildirimselin@hotmail.com

This is an open access journal, and articles are distributed under the terms of the Creative Commons Attribution-NonCommercial-ShareAlike 4.0 License, which allows others to remix, tweak, and build upon the work non-commercially, as long as appropriate credit is given and the new creations are licensed under the identical terms.

For reprints contact: WKHLRPMedknow_reprints@wolterskluwer.com

How to cite this article: Yıldırım HS, Ateş M, Gün IO, Kuru B, Çakırer B, Kuru L. Osteocalcin and cross-linked C-terminal telopeptide of type I collagen in gingival crevicular fluid during piezocision accelerated orthodontic tooth movement: A randomized split-mouth study. Niger J Clin Pract 2023;26:470-7.

Access this article online	
Quick Response Code: 	Website: www.njcponline.com
	DOI: 10.4103/njcp.njcp_539_22

and osteoclastic activities resulting in decreased bone density accompanied by increased bone turnover.^[9]

Gingival crevicular fluid (GCF) is an extracellular fluid accumulating in the gingival sulcus.^[10] It is composed of serum and locally generated constituents such as host inflammatory cells and biological markers including enzymes, cytokines, interleukins, and tissue breakdown products.^[10] A large number of GCF components have been investigated as potential biochemical markers that stimulate cellular response of the underlying periodontal ligament and bone during tooth movement and bone turnover.^[11-14]

Osteocalcin (OC), a noncollagenous protein, is expressed by osteoblasts during mineralization of the bone extracellular matrix.^[11] Griffiths *et al.*^[12] reported that OC is detectable in the GCF during tooth movement and may be a diagnostic marker for bone turnover. Furthermore, Alfaqeh and Anil^[13] detected elevated GCF levels of OC during orthodontic treatment and suggested the indicative role of an increased rate of bone formation and active tooth movement.

Type I collagen cross-linked C-terminal telopeptide (ICTP) is released into the circulation as a consequence of bone resorption and collagen degradation.^[15] ICTP is specific to bone due to its unique amino acid sequences and constitutes 90% of the bone matrix. It is mediated by osteoclasts and found in urine, serum, and GCF as a bone degradation end-product.^[16] Consequently, the GCF level of ICTP has been considered as a specific marker for bone resorption during orthodontic treatment.^[17]

Although there are clinical studies^[2,3,5,18-28] and case reports^[6,7,29,30] on RAP using various techniques revealing substantial improvement in the velocity of tooth movement, little is known about the underlying biological activity of piezocision-accelerated tooth movement. Therefore, the aim of this study was to evaluate and compare canine distalization with and without piezocision acceleration with regard to the GCF OC and ICTP levels.

MATERIAL AND METHODS

The clinical research ethical committee of Akdeniz University, School of Medicine, approved the study protocol (04.03.2013/38). The research was conducted in accordance with the principles in the Helsinki Declaration of 1975 as revised in 2013 and registered at ClinicalTrials.gov (NCT04611984).

Study population

This randomized controlled split-mouth-designed clinical study was performed from March 2013 to May 2014 in the Departments of Orthodontics and Periodontology

of Marmara University, Istanbul, Turkey. Fifteen healthy subjects (M:F 7:8) 13–19 years old (mean age 16.27 ± 1.14 years) were enrolled. The inclusion criteria were as follows: Class I, II, or III malocclusion, proclined incisors requiring maxillary first premolar extraction with subsequent canine retraction, no previous orthodontic treatment, good periodontal health, and oral hygiene [plaque index (PI)^[31] and gingival index (GI)^[32] ≤ 1 , probing depth (PD) ≤ 3 mm, no radiographic bone loss]. The patients and their legal guardians agreed to participate in the research by signing a consent form.

Primary outcome and sample size calculation

The primary outcome of this study was the tooth movement. The sample size was calculated on the basis of a similarly designed study.^[33] Assuming that the common standard deviation for tooth movement is 0.47, a sample of 13 participants per group would provide 90% power to detect a true difference of 0.52 mm between the groups. Fifteen patients were enrolled in each group considering possible dropouts.

Orthodontic treatment

Orthodontic treatment was performed with a full-fixed Roth prescription straight wire appliance (MIB, Rueil, France) by one of the investigators (IOG). Following the extraction of maxillary first premolars, leveling and alignment of the upper dentition were performed by using 0.012-, 0.014-, and 0.016-in NiTi archwires, respectively, for at least 3 months to avoid RAP caused by extraction. After leveling, a 0.016-in steel archwire was applied to start canine distalization. Miniscrews with dimensions of 1.7×8.0 mm (Orthoeasy, Pforzheim, Germany) were placed between maxillary second premolar and first molar teeth bilaterally. At each session, patients' oral hygiene was evaluated, and oral hygiene instructions were given, if necessary.

Randomization and blinding

Bilateral maxillary canines were randomly assigned to either the piezocision or control group via a computer-generated randomization table with an allocation ratio of 1:1. The allocation sequence was concealed via sequentially numbered, sealed, and opaque envelopes by one of the investigators (MA). They were opened before piezocision procedure. The investigators applying the clinical (IOG) and surgical (HSY) procedures and patients were not blinded. Samples of GCF were obtained and numbered by another blinded researcher (LK).

Surgical procedure and canine retraction

Using a randomized split-mouth design, piezosurgery was carried out on the mesiobuccal and distobuccal aspects of the maxillary canine teeth, which were

allocated to the piezocision group, while bilateral canines served as the control group. Patients were instructed to rinse with 0.2% chlorhexidine digluconate mouthwash for 30 s before the procedure. Following the application of local infiltrative anesthesia (Ultracain Forte, Sanofi-Aventis, Germany), a vertical micro-incision of 3 mm was performed just below the interdental papilla on the attached gingiva with a no: 15 scalpels by one of the investigators (HSY).^[6] Cortical alveolar incisions to a depth of 3 mm were created via a piezosurgery knife (BS1 insert, Piezotome, Merignac, France) [Figure 1]. Immediately after, 0.016-in steel wires were placed, and closed coil springs extending from canine teeth to miniscrews were utilized with 150 gr of distalization force to retract canines bilaterally in all patients [Figure 1]. They were instructed not to use any nonsteroidal anti-inflammatory drug either during the postoperative or canine distalization procedure to avoid overlapping with RAP.

Distalization measurements

For distalization measurements, patients were evaluated at 2-week intervals at baseline and 14 and 28 days after the canine distalization. At each appointment, the force of canine distalization was measured via a force gauge (Dentaurum, Ispringen, Germany), and closed coil springs were reactivated if any force decay had occurred. The impression of the maxilla was initially obtained using alginate to prepare cast models. All measurements were carried out on the dental cast model via a digital caliper by the same investigator (MA). The space closure amount was based on the measurements of the distance between the contact points of the distal surface of the canine and the mesial surface of the second premolar. The change in distance between the three observation periods (baseline, 14, and 28 days) represented the canine movement amount, which was divided by the number of days between two sessions to obtain the retraction rate on a daily basis.

GCF collection

GCF samples were obtained from the maxillary canines on both the mesial and distal sides of each subject at beginning of retraction immediately before piezocision (day 0), on days 1 and 7, and before activation on days 14 and 28. GCF was obtained with paper strips (Periopaper, Oraflow, NY, USA) using the method described by Kuru *et al.*,^[34] and the GCF collected volumes were determined by Periotron® 8000 (Oraflow, NY, USA). GCF samples were stored at -80°C until laboratory analysis.

Determination of N-MID OC and ICTP

The GCF OC and ICTP levels in samples were detected using colorimetric sandwich ELISA kits (Serum

CrossLaps® ELISA and N-Mid® Osteocalcin ELISA kits, Immunodiagnostic Systems Ltd, Boldon, UK) according to the manufacturer's instructions.

Statistical analyses

Statistical analyses were carried out via IBM SPSS 22 software (IBM SPSS Statistics, IBM Corp., USA). Shapiro–Wilk's test was performed to test the distribution normality. Intergroup comparisons were performed with the Mann–Whitney *U* test. The Friedman test was carried out for multiple intragroup comparisons. A *P* < 0.05 was considered to be statistically significant.

RESULTS

Fifteen participants were enrolled, and none of the participants were lost during the follow-up period [Figure 2]. Healing was uneventful and no complications were observed after the piezocision procedure.

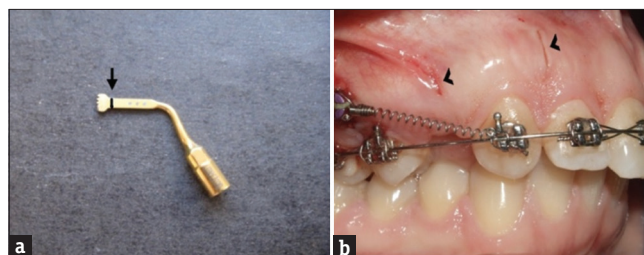


Figure 1: (a) Before piezocision, 3 mm was measured and a black line (arrow) was marked on the piezocision knife, and (b) piezocisions (arrowhead) were performed on the mesiobuccal and distobuccal aspect of the alveolar bone of the maxillary right canine

Table 1: Intra- and inter-group comparisons of distances (mm) between canine and second premolar at baseline, on 14 and 28 days, and the amount of canine movement (mm) between these time periods

Time points	Piezocision group	Control group	<i>P</i> *
	Mean±SD	Mean±SD	
	Median (min-max)	Median (min-max)	
Baseline	5.63±0.62	5.57±0.89	0.713
14 day	5.65 (4.42-6.59)	5.47 (4.07-7.68)	0.137
	4.87±0.68	5.30±0.92	
28 day	4.89 (3.79-6.20)	5.21 (3.59-7.26)	0.174
	4.37±0.74	4.88±1.00	
<i>P</i> #	0.0001	0.0001	
Δ0-14 days	0.76±0.28	0.27±0.13	0.0001
Δ14-28 days	0.75 (0.36-1.50)	0.25 (0.07-0.52)	0.389
	0.50±0.15	0.43±0.23	
Δ0-28 days	0.51 (0.23-0.79)	0.38 (0.14-0.86)	0.0001
	1.27±0.36	0.70±0.25	
	1.27 (0.74-2.20)	0.62 (0.32-1.11)	

SD: Standard deviation, #Friedman test, * Mann-Whitney *U* test, *P*<0.05

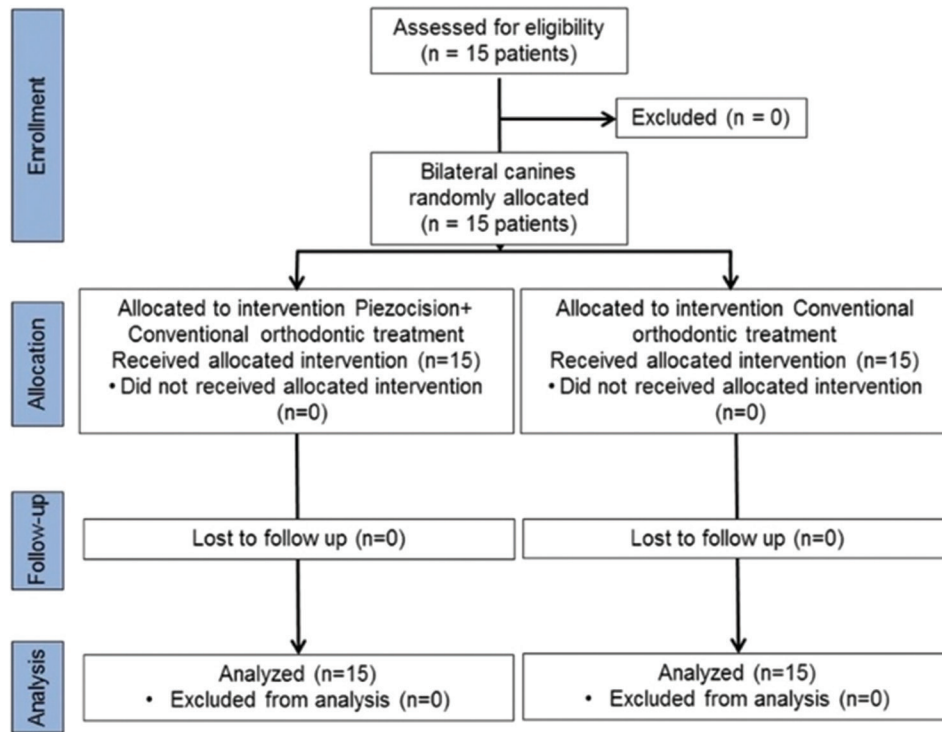


Figure 2: The flow chart of the study

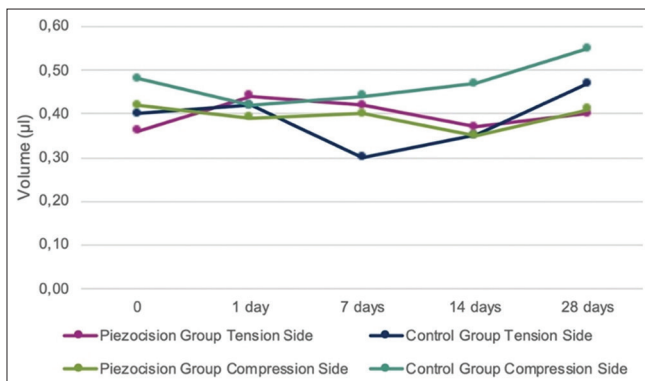


Figure 3: GCF volume (µl) obtained from tension and compression sides of the piezocision and control groups during 28-day study period

Clinical findings

The mean full-mouth clinical periodontal parameters of all subjects were as follows at baseline: PI 0.33 ± 0.09, GI 0.29 ± 0.08, bleeding on probing 4.99 ± 2.19%, and PD 1.86 ± 0.26 mm.

In terms of canine distalization, the mean distance between the canine and second premolar decreased from the baseline value of 5.63 ± 0.62 mm to 4.37 ± 0.74 mm at 28 days in the piezocision group (P = 0.0001) and from 5.57 ± 0.89 mm to 4.88 ± 1.00 mm in the control group (P = 0.0001) [Table 1]. The amount of canine distalization in the piezocision group was significantly higher than that in the control group at

Table 2: Retraction rate (mm/day) of canine movement of the groups on 14 and 28 days

Time points	Piezocision group Mean±SD Median (min-max)	Control Group Mean±SD Median (min-max)	P*
14 days	0.050±0.02 0.05 (0.02-0.10)	0.018±0.01 0.02 (0.01-0.04)	0.0001
28 days	0.045±0.01 0.04 (0.03-0.08)	0.025±0.01 0.02 (0.01-0.04)	0.0001

SD: Standard deviation, *Mann-Whitney U test, P<0.05

Δ0–14 days (0.76 ± 0.28 mm vs. 0.27 ± 0.13 mm, respectively) and at Δ0–28 days (1.27 ± 0.36 mm vs. 0.70 ± 0.25 mm, respectively) (P = 0.0001) [Table 1]. The piezocision group demonstrated higher retraction rates than the control group on both 14th and 28th days (P = 0.0001) [Table 2].

GCF volume

A total of 300 GCF samples were obtained from mesial and distal sides of the maxillary canines throughout the study period. GCF volumes of the tension and compression sides of both groups at different measurement time points remained similar during the 28-day experimental period, with minor fluctuations and without any intra- and intergroup differences (P > 0.05) [Figure 3].

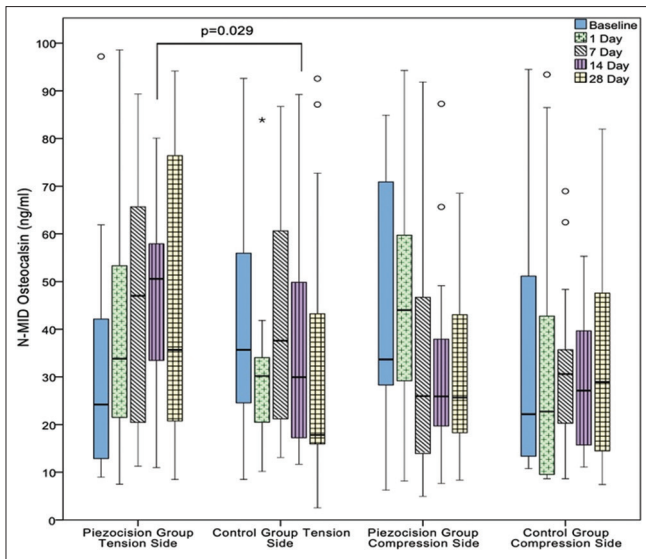


Figure 4: GCF N-MID OC level (ng/ml) in the tension and compression sides of the piezocision and control groups during 28-day study period. Connector indicates a significant difference. *P* value is given above the connector. * and ° indicate outliers

Levels of N-MID OC and ICTP in GCF

Compression sides of both groups demonstrated similar concentrations of N-MID OC in GCF at all time points ($P > 0.05$). Tension sides of both groups also showed similar N-MID OC concentrations in GCF ($P > 0.05$), except on day 14. The mean level of N-MID OC in the piezocision group was found to be almost sixfolds higher and statistically different than that in the control group ($P = 0.029$) [Figure 4].

The tension sides of both groups presented similar concentrations of ICTP in GCF throughout the study period at all time points ($P > 0.05$). Similarly, the compression sides of both groups showed similar ICTP levels in GCF ($P > 0.05$), except on day 14. The mean level of ICTP was significantly higher in the piezocision group than in the control group ($P = 0.015$) [Figure 5].

DISCUSSION

To the best of our knowledge, the present study is the first study that investigated clinically and biochemically the effect of piezocision-accelerated canine distalization on the OC levels in GCF as a bone formation marker and the ICTP levels in GCF as a bone resorption marker.

There is some evidence suggesting that the orthodontic tooth movement is faster in adolescents than adults.^[35,36] On the contrary, two recent systematic reviews and meta-analyses assessing retrospective nonrandomized studies concluded that the duration of comprehensive orthodontic tooth movement including canine retraction did not differ between adolescents and adult subjects.^[37,38]

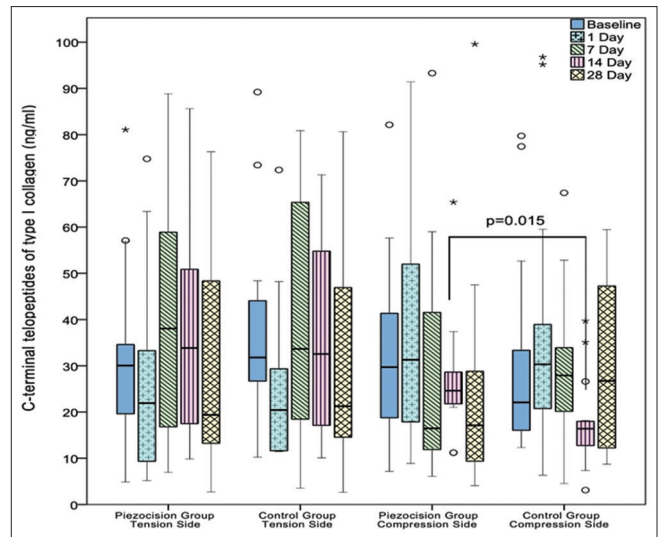


Figure 5: GCF ICTP level (ng/ml) in the tension and compression sides of the piezocision and control groups during 28-day study period. Connector indicates a significant difference, and *P* value is given above the connector. * and ° indicate outliers

Nevertheless, our study population consisted of young individuals ranging between 13 and 19 years old.

The results of this study showed that amount of canine distalization at 28 days was 1.27 ± 0.36 mm in the piezocision group and 0.70 ± 0.25 mm in the control group. In clinical studies examining piezocision-accelerated canine distalization, the amount of canine movement on day 28 was reported to be in the range of 0.50 ± 0.07 to 1.54 ± 0.4 mm in the piezocision groups and 0.30 ± 0.38 to 1.30 ± 0.78 mm in the control groups treated with conventional orthodontic treatment.^[2,3,18,19,22,23,26,27] Our results at 14 and 28 days were within the range specified in the abovementioned studies favoring the piezocision group. In contrast, some of the recent studies concluded that there is no difference between piezocision and conventional procedure regarding the rate of canine distalization.^[19,23] This contradictory finding may be due to the different surgical protocols of piezocision procedure utilized in these studies. Nevertheless, the sample sizes of relevant studies^[19,23] ranging from 17 to 20 subjects were larger than the sample size in our study. The canine retraction rate of the piezocision group was twofold greater than that of the control group at 28 days in the present study. This result was in concomitance with findings of Abbas *et al.*^[2] and Aksakalli *et al.*,^[3] who stated that orthodontic movement rate on the piezocision side was 1.5–2 times faster than that on the control side at 1 month. This acceleration may be explained by the RAP and decreased alveolar bone resistance to tooth movement. Surgical injury causes reversible decrease in bone mineral density, that is, transient osteopenia

in alveolar bone^[39] that reduces the resistance and enables rapid tooth movement through trabecular bone. Therefore, increased tooth movement in the piezocision group may be attributed to the increase in bone turnover associated with RAP transient osteopenia,^[6,39] decrease in hyalinization necrosis, and reduction in bone resistance to tooth movement.^[40] Corticotomy as a surgical method produces a greater amount of canine movement than piezocision, as reported by Abbas *et al.*,^[2] who used corticotomy versus piezocision and conventional orthodontic treatment in their groups. Corticotomy requires more extensive surgery, resulting in the enhancement of RAP associated with the severity of bone injury. On the other hand, piezocision is a minimally invasive technique that does not require flap elevation and involves only a 3-mm partial cut at the buccal side of interproximal bone to enhance RAP. Recently, new approaches have been proposed using either noninvasive diode laser irradiation to increase cellular activity during bone remodeling^[25] or Er:YAG laser-assisted minimally invasive flapless corticotomy performed to obtain alveolar cortical perforations with a 3-mm depth through the gingiva.^[5] However, the clinical and patient-reported outcomes of biostimulation via diode laser or microperforations via Er:YAG laser remain somewhat controversial and limited.

Recent studies on canine distalization compared the effectiveness of piezocision versus micro-osteoperforation defined as a surgical method in which small perforations are created in the bone around the teeth to accelerate orthodontic movement.^[20,21,24,28] However, the outcome of these studies is somewhat equivocal. While Alqadasi *et al.*^[21] reported no difference between micro-osteoperforation and piezocision, Farag *et al.*^[24] concluded that micro-osteoperforation was more effective method, whereas Simre *et al.*^[28] and Ramkumar *et al.*^[20] stated that the rate of canine retraction per month was significantly higher in the piezocision as compared to micro-osteoperforation technique.

The volume of GCF may vary according to the size of the gingival sulcus and the sampling techniques and is affected by factors such as chewing coarse foods, vigorous toothbrushing, gingival massage, smoking, sex hormones, plaque-induced gingival inflammation, and periodontal therapy.^[41] The present study indicated that orthodontic tooth movement did not cause any change in GCF volume during the 28-day experimental period. This finding was confirmed by other studies, such as Nishijima *et al.*^[42] and Dilsiz *et al.*,^[43] revealing a nonsignificant influence of mechanical stress on the GCF volume. In contrast, Capelli *et al.*^[44] and Drummond *et al.*^[14] reported that tooth movement forces result

in GCF volume elevation. No alterations in the GCF volume were observed in our study, which may also be attributed to the high oral hygiene level of the patients with low PI and GI values.

Analysis of constituents in GCF samples provides quantitative detection of biochemical markers for the evaluation of local cellular metabolism that reflects periodontal health and disease status,^[45] as well as orthodontic tooth movements.^[11-14] Bone turnover may be estimated by the assessment of matrix proteins or enzymes produced by osteoblasts or osteoclasts.^[46] Because it is important to investigate both bone formation and resorption markers to reflect the underlying molecular and cellular mechanism of bone turnover in tooth movement, both OC as a marker of bone formation and ICTP as a marker of bone resorption were investigated in this randomized split-mouth designed study to clarify the biochemical aspect of bone turnover in piezocision-accelerated orthodontic tooth movement. OC, known as bone Gla and calcium-binding protein, is a vitamin D- and K-dependent protein synthesized by osteoblasts and is deposited in bone extracellular matrix.^[15] The tension and compression sides of both groups demonstrated similar OC levels during our study period except on day 14. At the same time, the OC level in GCF was higher in the piezocision group tension side than the control group tension side parallel to high canine retraction rate in the piezocision group on day 14. Our findings suggesting an additional positive effect of piezocision procedure on canine retraction in both clinical and biochemical aspects are supported by a study by Alfaqeeh and Anil^[13] evaluating the influence of orthodontic movement on GCF OC level during canine retraction. They reported a peak in OC level in the pooled GCF samples on day 14 after retraction of canine chosen for the test group applied 125 gr force compared to the control side without any force application. Griffiths *et al.*^[12] collected GCF from the distal surface as the compression side of maxillary canines with fixed appliances during four stages (i.e., stage 1: before orthodontic appliance placement, stage 2: after orthodontic appliance placement, stage 3: retraction, and stage 4: retention) of conventional canine retraction and investigated the levels of OC, pyridinoline, and deoxypyridinoline. Similar to our results regarding the compression side, OC levels did not reveal any relation to the stages of orthodontic treatment. When all the findings of the present and the abovementioned studies are taken together, GCF OC levels reflect the bone activity for producing new bone matrix on the tension side, and 14 days is the time period with highest bone turnover activity.^[47-51]

Collagen type I is the major protein of the bone extracellular matrix and constituted as a triple helix, except for the two ends called N-terminal and C-terminal telopeptides.^[15] It is stabilized by the covalent cross-linking molecules pyridinoline and deoxypyridinoline, which are generated extracellularly after collagen deposition into the matrix and released from bone only during collagen breakdown or bone resorption.^[15] Griffiths *et al.*^[12] showed that pyridinoline and deoxypyridinoline were not detectable during four phases of conventional orthodontic treatment for canine distalization. In a split-mouth canine distalization study by Alfaqueeh and Anil,^[13] GCF type I collagen N-terminal cross-linked telopeptide (NTx) levels representing the bone resorption process increased significantly on the test side, where 125 gr force was applied, whereas no change was observed on the control side without any force application on days 14 and 21. To date, a number of orthodontic tooth movement studies have investigated GCF levels of pyridinoline, deoxypyridinoline, and NTx reflecting the anabolic and catabolic biologic activities in the alveolar bone.^[12,13] The results of the present study showed that the tension and compression sides of the groups demonstrated similar GCF ICTP levels at all time points except on day 14. Likewise, the ICTP level was significantly higher in the piezocision group compression side than in the control group compression side parallel to the high canine retraction rate in the piezocision group on day 14. Ferguson *et al.*^[52] analyzed recent 12 publications quantitatively and concluded that elevated catabolic bone biomarkers such as tumor necrosis factor-alpha and tartrate-resistant acid phosphatase were detected during 14 or 28 days after several surgical acceleration techniques including piezocision, corticotomy, and micro-osteoperforation. However, the differences were not found to be enough to discriminate catabolic bone activity among these techniques. According to the results of previous studies and our study, tooth distalization procedures stimulated bone turnover through increased osteoclastic activity on the compression side with higher bone resorption marker levels leading to tooth movement.

One of the limitations of the present study was the short follow-up period (28 days) of piezocision-accelerated canine distalization. Another limitation was the small sample size, although it was calculated as 13 subjects per group based on the power analysis. A longer follow-up period with larger sample size may be needed for future studies.

CONCLUSION

Within the limits of this study, piezocision was found to be an efficient treatment procedure for accelerating canine distalization supported by the accompanying increased levels of OC on the bone formation side and increased levels of ICTP on the bone resorption side at 14 days as a time period with the highest biological activity in bone.

Financial support and sponsorship

Nil.

Conflicts of interest

There are no conflicts of interest.

REFERENCES

1. Pilon JJ, Kuijpers-Jagtman AM, Maltha JC. Magnitude of orthodontic forces and rate of bodily tooth movement. An experimental study. *Am J Orthod Dentofacial Orthop* 1996;110:16-23.
2. Abbas NH, Sabet NE, Hassan IT. Evaluation of corticotomy-facilitated orthodontics and piezocision in rapid canine retraction. *Am J Orthod Dentofacial Orthop* 2016;149:473-80.
3. Aksakalli S, Calik B, Kara B, Ezirganli S. Accelerated tooth movement with piezocision and its periodontal-transversal effects in patients with Class II malocclusion. *Angle Orthod* 2016;86:59-65.
4. Yi J, Xiao J, Li Y, Li X, Zhao Z. Efficacy of piezocision on accelerating orthodontic tooth movement: A systematic review. *Angle Orthod* 2017;87:491-8.
5. Alfawal AMH, Hajeer MY, Ajaj MA, Hamadah O, Brad B. Evaluation of piezocision and laser-assisted flapless corticotomy in the acceleration of canine retraction: A randomized controlled trial. *Head Face Med* 2018;14:4.
6. Dibart S, Sebaoun JD, Surmenian J. Piezocision: A minimally invasive, periodontally accelerated orthodontic tooth movement procedure. *Compend Contin Educ Dent* 2009;30:342-4, 346, 348-50.
7. Dibart S, Surmenian J, Sebaoun JD, Montesani L. Rapid treatment of Class II malocclusion with piezocision: Two case reports. *Int J Periodontics Restorative Dent* 2010;30:487-93.
8. Frost HM. The regional acceleratory phenomenon: A review. *Henry Ford Hosp Med J* 1983;31:3-9.
9. Dibart S, Yee C, Surmenian J, Sebaoun JD, Baloul S, Goguet-Surmenian E, *et al.* Tissue response during piezocision-assisted tooth movement: A histological study in rats. *Eur J Orthod* 2013;36:457-64.
10. Lamster IB, Ahlo JK. Analysis of gingival crevicular fluid as applied to the diagnosis of oral and systemic diseases. *Ann N Y Acad Sci* 2007;1098:216-29.
11. Lian JB, Gundberg CM. Osteocalcin. Biochemical considerations and clinical applications. *Clin Orthop Relat Res* 1988;226:267-91.
12. Griffiths GS, Moulson AM, Petrie A, James IT. Evaluation of osteocalcin and pyridinium crosslinks of bone collagen as markers of bone turnover in gingival crevicular fluid during different stages of orthodontic treatment. *J Clin Periodontol* 1998;25:492-8.
13. Alfaqueh SA, Anil S. Osteocalcin and N-telopeptides of type I collagen marker levels in gingival crevicular fluid during different stages of orthodontic tooth movement. *Am J Orthod Dentofacial Orthop* 2011;139:e553-9.
14. Drummond S, Canavaro C, Perinetti G, Teles R, Capelli J Jr. The monitoring of gingival crevicular fluid volume during

- orthodontic treatment: A longitudinal randomized split-mouth study. *Eur J Orthod* 2012;34:109-13.
15. Swaminathan R. Biochemical markers of bone turnover. *Clin Chim Acta* 2001;313:95-105.
 16. Eriksen EF, Charles P, Melsen F, Mosekilde L, Risteli L, Risteli J. Serum markers of type I collagen formation and degradation in metabolic bone disease: Correlation with bone histomorphometry. *J Bone Miner Res* 1993;8:127-32.
 17. Teng GY, Liou EJ. Interdental osteotomies induce regional acceleratory phenomenon and accelerate orthodontic tooth movement. *J Oral Maxillofac Surg* 2014;72:19-29.
 18. Chawshii OF, Omer ZQ, Ikram O. Accelerated orthodontic canine retraction using minimally invasive orthocision. *Erbil Dent J* 2018;1:19-25.
 19. Omidkhoda M, Radvar M, Azizi M, Dehghani M. Evaluating the efficacy of a modified piezo-puncture method on the rate of tooth movement in orthodontic patients: A clinical study. *Turk J Orthod* 2020;33:13-20.
 20. Ramkumar A, Raghunath N, Avinash B. Evaluation and comparison of the rate of canine retraction using two accelerated orthodontic treatment techniques: An *in vivo* study. *World J Dent* 2020;11:105-11.
 21. Alqadasi B, Xia HY, Alhammadi MS, Hasan H, Aldhorae K, Halboub E. Three-dimensional assessment of accelerating orthodontic tooth movement-micro-osteoperforations vs piezocision: A randomized, parallel-group and split-mouth controlled clinical trial. *Orthod Craniofac Res* 2021;24:335-43.
 22. Raj SC, Prahraj K, Barik AK, Patnaik K, Mahapatra A, Mohanty D, et al. Retraction with and without piezocision-facilitated orthodontics: A randomized controlled trial. *Int J Periodontics Restorative Dent* 2020;40:e19-26.
 23. Hawkins VM, Papadopoulou AK, Wong M, Pandis N, Dalci O, Darendeliler MA. The effect of piezocision vs no piezocision on maxillary extraction space closure: A split-mouth, randomized controlled clinical trial. *Am J Orthod Dentofacial Orthop* 2022;161:7-19.e2.
 24. Farag T, Refai WMM, Nasef A, Elhiny OA, Hashem AS. Evaluation of the effect of micro-osteoperforations versus piezopuncture on the rate of orthodontic tooth movement associated with canine retraction. *Open Access Maced J Med Sci* 2021;9:113-9.
 25. Türker G, Yavuz İ, Gönen ZB. Which method is more effective for accelerating canine distalization short term, low-level laser therapy or piezocision? A split-mouth study. *J Orofac Orthop* 2021;82:236-45.
 26. Leehathorn P, Santiwong P, Chintavalakorn R. Effect of piezocision using double incisions at the maxillary first bicuspid extraction site on the rate of canine tooth movement: A randomized controlled trial. *M Dent J* 2022;42:175-90.
 27. Al-A'athal HS, Al-Nimri K, Alhammadi MS. Analysis of canine retraction and anchorage loss in different facial types with and without piezocision: A split-mouth-design, randomized clinical trial. *Angle Orthod* 2022;92:746-54.
 28. Simre SS, Rajanikanth K, Bhola N, Jadhav A, Patil C, Mishra A. Comparative assessment of corticotomy facilitated rapid canine retraction using piezo versus bur: A randomized clinical study. *J Oral Biol Craniofac Res* 2022;12:182-6.
 29. Omidkhoda M, Radvar M, Azizi M, Hasanzadeh N. Piezopuncture-assisted canine distalization in orthodontic patients: Two case reports. *J Dent (Shiraz)* 2018;19:74-82.
 30. Tunçer Nİ, Arman-Özçırpıcı A, Oduncuoğlu BF, Kantarcı A. Osseous outgrowth on the buccal maxilla associated with piezosurgery-assisted en-masse retraction: A case series. *Korean J Orthod* 2018;48:57-62.
 31. Silness J, Loe H. Periodontal disease in pregnancy. II. Correlation between oral hygiene and periodontal condition. *Acta Odontol Scand* 1964;22:121-35.
 32. Loe H, Silness J. Periodontal disease in pregnancy. I. prevalence and severity. *Acta Odontol Scand* 1963;21:533-51.
 33. Abed S, Al-Bustani A. Corticotomy assisted orthodontic canine retraction. *J Bagh College Dentistry* 2014;25:160-6.
 34. Kuru L, Kirby AC, Griffiths GS, Petrie A, Olsen I. Changes in soluble adhesion molecules in gingival crevicular fluid following periodontal surgery. *J Periodontol* 2005;76:526-33.
 35. Giannopoulou C, Dudic A, Pandis N, Kiliaridis S. Slow and fast orthodontic tooth movement: An experimental study on humans. *Eur J Orthod* 2015;38:404-8.
 36. Ireland AJ, Songra G, Clover M, Atack NE, Sherriff M, Sandy JR. Effect of gender and Frankfort mandibular plane angle on orthodontic space closure: A randomized controlled trial. *Orthod Craniofac Res* 2016;19:74-82.
 37. Abbing A, Koretsi V, Eliades T, Papageorgiou SN. Duration of orthodontic treatment with fixed appliances in adolescents and adults: A systematic review with meta-analysis. *Prog Orthod* 2020;5:21:37.
 38. Schubert A, Jäger F, Maltha JC, Bartzela TN. Age effect on orthodontic tooth movement rate and the composition of gingival crevicular fluid: A literature review. *J Orofac Orthop* 2020;81:113-25.
 39. Oliveira DD, Franco B, Villamarin R. Alveolar corticotomies in orthodontics: Indications and effects on tooth movement. *Dent Press J Orthod* 2010;15:144-57.
 40. Cano J, Campo J, Bonilla E, Colmenero C. Corticotomy-assisted orthodontics. *J Clin Exp Dent* 2012;4:e54-9.
 41. Khurshid Z, Mali M, Naseem M, Najeeb S, Zafar MS. Human gingival crevicular fluids (GCF) proteomics: An overview. *Dent J (Basel)* 2017;5:12.
 42. Nishijima Y, Yamaguchi M, Kojima T, Aihara N, Nakajima R, Kasai K. Levels of RANKL and OPG in gingival crevicular fluid during orthodontic tooth movement and effect of compression force on releases from periodontal ligament cells in vitro. *Orthod Craniofac Res* 2006;9:63-70.
 43. Dilsiz A, Kiliç N, Aydin T, Ates FN, Zihni M, Bulut C. Leptin levels in gingival crevicular fluid during orthodontic tooth movement. *Angle Orthod* 2010;80:504-8.
 44. Capelli J Jr, Kantarcı A, Haffajee A, Teles RP, Fidel R Jr, Figueredo CM. Matrix metalloproteinases and chemokines in the gingival crevicular fluid during orthodontic tooth movement. *Eur J Orthod* 2011;33:705-11.
 45. Champagne CM, Buchanan W, Reddy MS, Preisser JS, Beck JD, Offenbacher S. Potential for gingival crevice fluid measures as predictors of risk for periodontal diseases. *Periodontol* 2000 2003;31:167-80.
 46. Eastell R, Blumsohn A. The value of biochemical markers of bone turnover in osteoporosis. *J Rheumatol* 1997;24:1215-7.
 47. Bayliss L, Mahoney DJ, Monk P. Normal bone physiology, remodeling and its hormonal regulation. *Surgery* 2012;30:47-53.
 48. Kim YS, Kim SJ, Yoon HJ, Lee PJ, Moon W, Park YG. Effect of piezopuncture on tooth movement and bone remodeling in dogs. *Am J Orthod Dentofacial Orthop* 2013;144:23-31.
 49. Walsh JS. Normal bone physiology, remodeling and its hormonal regulation. *Surgery* 2015;36:1-6.
 50. Han J, He H. Effects of piezosurgery in accelerating the movement of orthodontic alveolar bone tooth of rats and the expression mechanism of BMP-2. *Exp Ther Med* 2016;12:3009-13.
 51. Staedt H, Dau M, Schiegnitz E, Thiem DGE, Tagadiuc O, Palarie V, et al. A collagen membrane influences bone turnover marker *in vivo* after bone augmentation with xenogenic bone. *Head Face Med* 2020;16:35.
 52. Ferguson DJ, Vaid NR, Wilcko MT. Assessing accelerated tooth movement techniques on their own catabolic merits: A review. *J World Fed Orthod* 2018;7:122-7.