

Cauda equina syndrome after induction of spinal anesthesia

SERDAR ÖZGEN, M.D., NIGAR BAYKAN, M.D., I. VARLIK DOĞAN, M.D., DENİZ KONYA M.D., AND M. NECMETTİN PAMIR, M.D.

Departments of Neurosurgery and Anesthesia, Marmara University Faculty of Medicine; and Marmara University Institute of Neurological Sciences, Istanbul, Turkey

In this report the authors present a case of cauda equina syndrome that developed following induction of spinal anesthesia in a patient who had no apparent preexisting bleeding abnormality. An acute subdural hematoma caused the syndrome and was believed to have resulted from direct vascular trauma during administration of spinal anesthesia or from vascular trauma combined with thrombocytopenia in the postoperative period.

KEY WORDS • subdural hematoma • spinal anesthesia • cauda equina syndrome

Cauda equina syndrome caused by ASSH is rare, and may be associated with blood dyscrasia, anticoagulation therapy, lumbar puncture, rupture of an arteriovenous malformation, tumor-related bleeding, or spinal trauma.^{1-3,5,7,16,20} Here we report a case of cauda equina syndrome that developed after spinal anesthesia had been administered in a patient who had no apparent preexisting bleeding abnormality.

CASE REPORT

History and Examination. This 69-year-old man, who had been diagnosed with benign prostatic hyperplasia, was scheduled for transurethral resection. The patient's preoperative physical and neurological examination findings were normal. Routine presurgical laboratory investigations revealed a hemoglobin level of 12.1 g/dl, hematocrit of 34.3%, leukocyte count of 6700/ μ l, platelet count of 192×10^3 / μ l, prothrombin time of 12.2 seconds, partial thromboplastin time of 34 seconds, and international normalized ratio of 1.04 (normal range 0.9-1.2). There were no abnormal findings on routine chest x-ray or electrocardiography studies.

First Operation. In the operating room, the patient was in the left lateral position and a 22-gauge spinal needle was introduced at the L3-4 intervertebral space. The first attempt resulted in a bloody tap and the needle was withdrawn. A second attempt was made at the same intervertebral space, and 3 ml of 0.5% bupivacaine was injected into the subarachnoid space. Sensory block to the level of T-10 was achieved and was considered to be adequate for surgery. During the operation 600 ml of blood was lost,

but this volume was not replaced. The patient stayed in the recovery room until he regained complete motor function in the lower extremities.

Postoperative Course. Four hours after surgery, postoperative testing revealed a hemoglobin level of 10 g/dl, hematocrit of 30.5%, platelet count of 120×10^3 / μ l, prothrombin time of 14.6 seconds, partial thromboplastin time of 40.4 seconds, and international normalized ratio of 1.28. The patient's bladder was irrigated four times during the night following surgery. Blood testing after the last irrigation showed a hemoglobin level of 9.2 g/dl, hematocrit of 28.7%, and platelet count of 70×10^3 / μ l. The hematological findings indicated anemia due to repeated bladder irrigation, and 2 U of packed red blood cells was administered. Twelve hours after the operation, the patient began to show progressive sensory and motor deficits in his lower limbs, but there was no associated pain. Results of a neurological examination revealed that his perineal sensation and rectal tone had decreased. Because a catheter had been inserted for irrigation, urinary incontinence could not be evaluated.

Magnetic resonance images of the lumbar spine demonstrated a subdural hematoma extending from T-12 to L-5. The lesion appeared heterogeneously hyperintense on T₁-weighted MR images, heterogeneously hyperintense on T₂-weighted MR images, and slightly enhanced with the intravenous administration of Gd (Figs. 1 and 2). A subdural hematoma related to spinal anesthesia was diagnosed, and the patient was transferred to the Neurosurgery Department.

Second Surgery and Postoperative Course. Surgery involving laminectomies at L-1, L-2, and L-3 was performed immediately. The dura mater in this region was opened with the aid of magnification, exposing an extensive clotted mass of blood under pressure. The clot was completely removed using aspiration. Once clot evacua-

Abbreviations used in this paper: ASSH = acute spinal subdural hematoma; CES = cauda equina syndrome; MR = magnetic resonance.

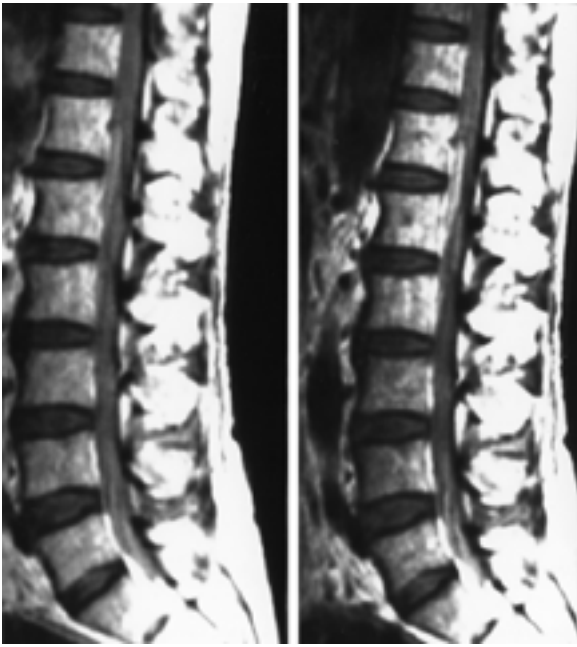

Fig. 1. *Left*: A noncontrast T₁-weighted sagittal MR image revealing a hyperintense mass in the subdural space at T-12 extending to L-5. *Right*: The mass enhanced slightly with intravenous administration of Gd.

tion was complete, the distended arachnoid sac, which also contained clotted blood, was gently separated from the roots of the cauda equina. No other abnormality, such as tumor or vascular malformation, was found at the site of the hematoma. Results of subsequent electromyography studies demonstrated the prolonged bulbocavernosus reflex latencies consistent with CES. The patient's neurological condition remained unchanged during the first 10 days after laminectomy, so he was referred for rehabilita-

tion at that stage. On examination 2 years later, he still manifested symptoms of CES.

DISCUSSION

The development of a hematoma in the spinal subdural or epidural space can lead to CES.^{6,14} Acute spinal subdural hematoma is a rare form of intraspinal hematoma that may be associated with hemorrhagic disorders, anticoagulation therapy, spinal surgery, tumors, vascular malformations, trauma, or iatrogenic factors such as spinal or epidural anesthesia.^{2,3,5,7,16,24} Phillips, et al.,¹⁹ reported no serious hemorrhagic complications in 10,440 patients who had received spinal anesthetic agents, even though 3% of these cases featured bloody taps and 6% involved multiple attempts at needle placement. Nonetheless, any impairment of hemostatic mechanisms can increase the risk of bleeding in the setting of spinal anesthesia, and patients on anticoagulation therapy are at particularly high risk for this type of complication.^{2,4,7} In our case of ASSH following administration of spinal anesthesia, there was no apparent preexisting bleeding abnormality.

There is vigorous debate about the source of bleeding and the mechanism underlying ASSH formation.^{11,16,21} In the brain, the subdural veins form a bridging pattern over the parenchymal surface, but this pattern does not exist in the spinal cord. The only vessels at the level of the cauda equina that are 1 mm in diameter or larger are the Adamkiewicz arteries, which run longitudinally and are located laterally in the subdural space. Several authors have postulated that a sudden increase in pressure in the abdomen and/or the thoracic cavity could raise the pressure inside spinal vessels, particularly the valveless radiculomedullary veins because these cross the subdural and subarachnoid spaces.^{11,21} If the normal pressure of the cerebrospinal fluid cannot neutralize this force immediately, the vessels might rupture. Morandi, et al.,¹⁵ asserted that ASSHs are caused by rupture of small extraarachnoidal vessels locat-

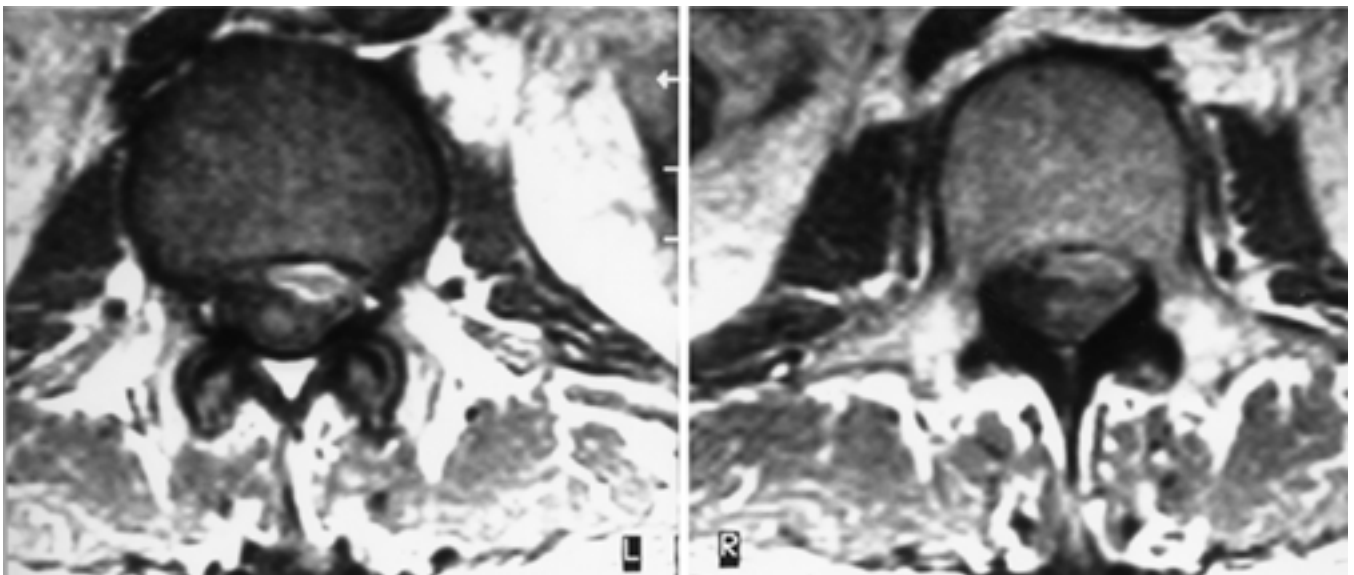


Fig. 2. Axial T₁-weighted MR images demonstrating a hyperintense mass at L-1.

ed on the inner surface of the dura. Thorsen²² reported multiple petechial hemorrhages on the surface of the brain after the induction of spinal anesthesia and concluded that these occurred because of traction of dural vessels in response to a drop in cerebrospinal fluid pressure. In the case featured in the present report, we were unable to identify the source of bleeding that led to ASSH formation.

The literature contains only a few case reports involving ASSH. The lesions in these cases were associated with trauma, other risk factors such as tumors, and clotting abnormalities.^{3,16,23} Lerner, et al.,¹³ described a patient with normal coagulation parameters who had developed an epidural hematoma, and they attributed this lesion to repeated lumbar dural puncture. Edelson, et al.,⁵ investigated subdural hemorrhage in patients with thrombocytopenia on anticoagulation therapy who had undergone diagnostic lumbar punctures, and speculated that trauma from these punctures was the cause of bleeding. Greensite and Katz⁶ documented a case of subdural hematoma in which dural puncture had been performed for epidural anesthesia. They concluded that aspirin therapy might have caused or facilitated expansion of the patient's lesion. Nielsen, et al.,¹⁸ reported that most bleeding during and after transurethral resection of the prostate is due to dilutional thrombocytopenia. Furthermore, they documented that fibrinolytic activity increases during this surgical procedure. The patient in our case was not receiving anticoagulation therapy, yet the latest platelet count was $70 \times 10^3/\mu\text{l}$ and we observed blood in the subarachnoid space during the laminectomy procedure. We suspect that the ASSH in this case might have developed after vessels were damaged during administration of spinal anesthesia or due to vessel trauma combined with postoperative thrombocytopenia.

The earliest symptom of spinal hematoma is back pain, followed at variable intervals by motor and sensory deficits, often with bowel and bladder dysfunction.³ Individual variations in the anatomy of the distal spinal cord and the cauda equina explain the variability in presenting signs and symptoms. Nicholson¹⁷ reported on a patient with diabetes who harbored a painless epidural hematoma. In our case, the patient developed CES with no painful symptoms. The fact that he experienced no pain in the first 12 hours following induction of spinal anesthesia delayed the diagnosis.

Magnetic resonance imaging is the method of choice for detecting spinal subdural hematoma. Identifying blood products on MR images is important in distinguishing this type of hematoma from other spinal lesions. Spinal subdural hematomas usually exhibit high signal intensity on both T₁- and T₂-weighted images. In the acute phase, most subdural hematomas are isointense or slightly hyperintense on T₁-weighted images and display a heterogeneous hyperintense signal on T₂-weighted images. In our case of ASSH, the lesion was heterogeneously hyperintense on T₁-weighted images and enhanced after contrast injection. Any patient with signs and symptoms of acute CES should undergo emergent MR imaging or computerized tomography myelography studies to identify the level of compression and to establish the craniocaudal extent and dorsoventral location of the hematoma. Once these fea-

tures are determined, decompression should be performed as soon as possible. Selective spinal angiography studies are recommended if no pathophysiology is demonstrated after the hematoma has been evacuated.²³ It is also important to perform angiography studies in neurologically stable patients with ASSH who are being treated nonsurgically.

Most authors consider ASSH to represent a surgical emergency, regardless of the patient's preoperative neurological status. Cauda equina syndrome is considered to be an absolute indication for decompression. The risk of poor functional outcome is greater in cases in which surgical decompression is delayed for several hours after neurological deficits have occurred. Research has shown that an intradural pressure higher than 70 mm Hg is associated with residual neurological deficit in patients with CES.²⁰ Once this critical pressure is surpassed, neurological deficit is inevitable. Domenicucci, et al.,³ found that the anatomical location of a spinal hematoma influences prognosis. Specifically, they noted that subarachnoid hemorrhage has a poorer prognosis than lesions confined to the subdural space. Some authors have asserted that ASSH confined to the lumbar level can be successfully managed by percutaneous drainage, but it is often impossible to remove solid blood clots in this way.¹² Spontaneous resolution of ASSH has been also reported in very rare cases.^{8,10}

In addition to subdural hematoma caused by administration of spinal anesthesia, direct toxicity from injected local anesthetic agents can cause CES. In reports of this in the literature, the proposed explanation for CES is sacral orientation of the catheter and overdose of a concentrated hyperbaric local anesthetic agent.²¹ One theory indicates that the anesthetic is distributed unevenly, so that the agent accumulates to toxic levels at isolated locations along the spinal column.^{9,21} Such complications have usually occurred after a spinal injection of concentrated hyperbaric 5% lidocaine for spinal anesthesia.⁹ The administration of a hyperbaric local anesthetic agent through a sacrally directed catheter results in restricted distribution and high peak local anesthetic concentration. Several factors can affect distribution of the agent, including catheter size, tip configuration, tip position, and injection rate. We used bupivacaine in our case because this agent is known to be safer than lidocaine for spinal anesthesia, it has a longer duration of action, and its injection into the spine is rarely associated with the occurrence of CES.

CONCLUSIONS

Cauda equina syndrome is a serious potential complication of spinal anesthesia. Even if a patient experiences no pain, the possibility of ASSH should be considered in anyone in whom spinal anesthesia has been administered and suddenly develops signs of cauda equina compression. Magnetic resonance imaging is the method of choice in diagnosing ASSH.

References

1. Chen HJ, Liang CL, Lu K, et al: Cauda equina syndrome caused by delayed traumatic spinal subdural haematoma. *Injury* 32: 505-507, 2001

2. Dickman CA, Shedd SA, Spetzler RF, et al: Spinal epidural hematoma associated with epidural anesthesia: complications of systemic heparinization in patients receiving peripheral vascular thrombolytic therapy. **Anesthesiology** **72**:947–950, 1990
3. Domenicucci M, Ramieri A, Ciappetta P, et al: Nontraumatic acute spinal subdural hematoma: report of five cases and review of the literature. **J Neurosurg (Spine 1)** **91**:65–73, 1999
4. Dripps RD, Vandam LD: Long-term follow-up of patients who received 10,098 spinal anesthetics: failure to discover major neurological sequelae. **JAMA** **156**:1486–1491, 1954
5. Edelson RN, Chernik NL, Posner JB: Spinal subdural hematomas complicating lumbar puncture. **Arch Neurol** **31**:134–137, 1974
6. Greensite FS, Katz J: Spinal subdural hematoma associated with attempted epidural anesthesia and subsequent continuous spinal anesthesia. **Anesth Analg** **59**:72–73, 1980
7. Grejda S, Ellis K, Arino P: Paraplegia following spinal anesthesia in a patient with chronic renal failure. **Reg Anesth** **14**:155–157, 1989
8. Hung KS, Lui CC, Wang CH, et al: Traumatic spinal subdural hematoma with spontaneous resolution. **Spine** **27**:E534–E538, 2002
9. Johnson ME: Neurotoxicity of lidocaine: implications for spinal anesthesia and neuroprotection. **J Neurosurg Anesthesiol** **16**:80–83, 2004
10. Juvonen T, Tervonen O, Ukkola V, et al: Widespread posttraumatic spinal subdural hematoma—imaging findings with spontaneous resolution: case report. **J Trauma** **36**:262–264, 1994
11. Langmayr JJ, Ortler M, Dessel A, et al: Management of spontaneous extramedullary spinal haematomas: results in eight patients after MRI diagnosis and surgical decompression. **J Neurol Neurosurg Psychiatry** **59**:442–447, 1995
12. Lee JL, Hong SC, Shin HJ, et al: Traumatic spinal subdural hematoma: rapid resolution after repeated lumbar spinal puncture and drainage. **J Trauma** **40**:654–655, 1996
13. Lerner SM, Gutterman P, Jenkins F: Epidural hematoma and paraplegia after numerous lumbar punctures. **Anesthesiology** **39**:550–551, 1973
14. Metzger G, Singbartl G: Spinal epidural hematoma following epidural anesthesia versus spontaneous spinal subdural hematoma. Two case reports. **Acta Anaesthesiol Scand** **35**:105–107, 1991
15. Morandi X, Carsin-Nicol B, Brassier G, et al: MR demonstration of spontaneous acute spinal subdural hematoma. **J Neuro-radiol** **25**:46–48, 1998
16. Morandi X, Riffaud L, Chabert E, et al: Acute nontraumatic spinal subdural hematomas in three patients. **Spine** **26**:E547–E545, 2001
17. Nicholson A: Painless epidural haematoma. **Anaesth Intensive Care** **22**:607–610, 1994
18. Nielsen JD, Gram J, Fabrin K, et al: Lack of correlation between blood fibrinolysis and the immediate or post-operative blood loss in transurethral resection of the prostate. **Br J Urol** **80**:105–110, 1997
19. Phillips OC, Ebner H, Nelson AT, et al: Neurologic complications following spinal anesthesia with lidocaine: a prospective review of 10,440 cases. **Anesthesiology** **30**:284–289, 1969
20. Russell NA, Benoit BG: Spinal subdural hematoma. A review. **Surg Neurol** **20**:133–137, 1983
21. Rydevik BL, Pedowitz RA, Hargens AR, et al: Effects of acute, graded compression on spinal nerve root function and structure. An experimental study of the pig cauda equina. **Spine** **16**:487–493, 1991
22. Thorsen G: Neurological complications after spinal anesthesia and results from 2493 follow-up cases. **Acta Chir Scand** **95 (Suppl 121)**:1–272, 1947
23. Vishteh AG, Theodore N, Spetzler RF: Nontraumatic acute spinal subdural hematoma. **J Neurosurg (Spine 1)** **93**:180–181, 2000
24. Zilkha A, Nicoletti JM: Acute spinal subdural hematoma. Case report. **J Neurosurg** **41**:627–630, 1974

Manuscript received April 16, 2004.

Accepted in final form May 10, 2004.

Address reprint requests to: Serdar Özgen, M.D., P.K.4 Göztepe 34730, Istanbul, Turkey. email: omurga@tnn.net.