



## CASE REPORT

### ACQUIRED LYMPHANGIECTASIS: A CASE REPORT (MAJOR HALLMARKS IN ITS DIFFERENTIAL DIAGNOSIS FROM LYMPHANGIOMA CIRCUMSCRIPTUM)

Ahmet Midi<sup>1</sup>, Özge Ayabakan<sup>2</sup> Aydın Sav<sup>3</sup>

<sup>1</sup> Özel Gaziosmanpaşa Hastanesi, Patoloji, İstanbul, Türkiye <sup>2</sup> Özel Gaziosmanpaşa Hastanesi, Dermatoloji, İstanbul, Türkiye <sup>3</sup> Marmara Üniversitesi Hastanesi, Patoloji Anabilim Dalı, İstanbul, Türkiye

#### ABSTRACT

Acquired lymphangiectasis is a superficial lymphatic dilatation caused by a wide range of scarring processes. Histologically indistinguishable from lymphangioma circumscriptum and commonly occurs in adults as a late sequel of surgery and radiation therapy. Patients usually present with numerous translucent vesicles in a chronic lymph edematous area several years after surgery with or without radiation therapy. We report a case of acquired lymphangiectasis, happened 17 years after the surgical intervention. Lesions were located the left subaxillary region. This is the first case that is reported so late in the literature after the surgery.

**Keywords:** Lymphangiectasis, Acquired, Lymphangioma circumscriptum

#### EDİNSEL LENFANJEKTAZİ: OLGU SUNUMU (LENFANJİOMA SİRKUMSKRİPTUMDAN AYIRICI TANISINDA BELİRLEYİCİ ÖZELLİKLER)

#### ÖZET

Edinsel lenfanjektazi skar oluşumuna bağlı oluşan, yüzeysel lenfatiklerin dilatasyonu ile karakterize bir lezyondur. Sıklıkla yetişkinlerde radyoterapi ve cerrahi işlemimin geç komplikasyonu olarak ortaya çıkar ve histolojik olarak lenfangioma sirkumskriptumdan ayrılması zordur. Hastalarda genellikle radyoterapi uygulanan ya da uygulanmayan cerrahi işleminden yıllar sonra kronik lenfödematöz bölgede çok sayıda şeffaf veziküller oluşur. Biz cerrahi işleminden 17 yıl sonra oluşan bir edinsel lenfanjektazi olgusu sunmaktayız. Lezyonlar sol subaksiller bölge yerleşimliydi. Olgumuz literatürde operasyon sonrası bu kadar geç evrede oluşan ilk yayın olma özelliği taşımaktadır.

**Anahtar Kelimeler:** Lenfanjektazi, Edinsel, Lenfanjioma sirkumskriptum

#### INTRODUCTION

Acquired lymphangiectasis (AL) is a condition in which dilated superficial lymphatics develop after damage to previously normal lymphatics. AL has been reported as clinically and histologically indistinguishable from congenital lymphangioma circumscriptum (LC)<sup>1-3</sup>. LC is predominantly a developmental malformation of infancy but it may arise at any age. AL is a similar acquired lesion arising in adults. AL is a disorder of superficial lymphatics resulting from obstruction of previously normal deep lymphatics, while LC describes a deep dermal and subcutaneous lymphatic malformation

with secondary superficial ectatic changes. AL is histologically indistinguishable from LC<sup>1-3</sup>. Although the etiopathogenesis of these two entities are different from each other their treatment options are similar. AL is an acquired dilation of lymphatics and can be associated with lymphedema after surgery and/or radiation therapy (RT).

Clinically, AL consists of several clusters of translucent, thick-walled, fluid-filled vesicles. The vesicles typically measure 2-10 mm in diameter. The affected area appears to be speckled by numerous translucent vesicles with normal-appearing skin among the lesions. Some lesions may become

#### Corresponding author:

Ahmet Midi

e-mail: [ahmetmidi@yahoo.com](mailto:ahmetmidi@yahoo.com)

Özel Gaziosmanpaşa Hastanesi, Patoloji, İstanbul, Türkiye

Marmara Medical Journal 2007;20(1);43-46



pedunculated with a hyperkeratotic verrucous surface mimicking a wart<sup>1-6</sup>. On microscopic examination, AL is characterized by large, dilated lymph vessels lined by a single layer of endothelial cells. They are usually found in the papillary dermis and the reticular dermis. Involvement in the deeper dermis is rare. The overlying epidermis is usually associated with acanthosis and hyperkeratosis<sup>1-4</sup>.

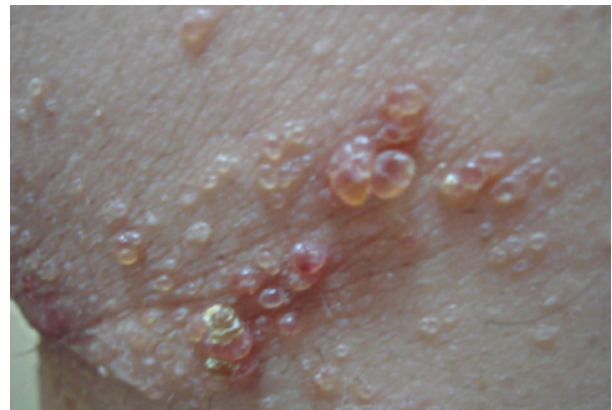The pathogenesis of AL is not known; however, surgical damage most likely causes fibrosis and lymphatic obstruction at the base of the reticular dermis and an accumulation of lymph fluid in the dermal lymphatics with resultant increased pressure<sup>7,8</sup>. This can then lead to saccular dilation of the superficial lymphatic channels with subsequent vesicle formation. Skin biopsy is primarily the diagnosis of AL based on clinical history and conventional light microscopy findings. There are many treatment modalities such as electrodesiccation, laser therapy, sclerotherapy, cryotherapy, and surgical excision. No medical care has been proven to be effective for AL. Daily compression through bandaging or hosiery in accessible areas has yielded acceptable results<sup>8-13</sup>. The treatment is relatively simple, though recurrences are not uncommon.

In this report we presented a case of AL happened 17 years later after surgery. Although LA and LC have similar treatment options they are distinctive entities. In addition, we want to call attention to the literature that LA and LC are used faulty interchangeably.

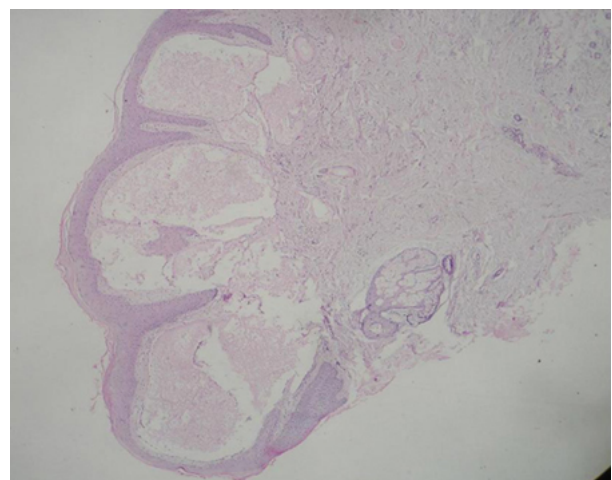
## CASE REPORT

A 25-year-old man presented to our outpatient clinic for evaluation of multiple small vesicular lesions on the left subaxillary regions. The lesion has been present for tree years. Twenty years earlier, he had had a surgical procedure on the same region. Surgical material had been diagnosed as a lipoma. He did not have radiotherapy. The cutaneous lesions started to develop seventeen years after surgery. On physical examination, the patient had numerous isolated and

translucent vesicles and bullae. There was associated pain, chronic drainage, and itching. The vesicles typically measure 2-15 mm in diameter (Fig. 1). We performed biopsy from lesions. On microscopic examination, the lesions surface was hyperkeratotic. Coexisting lymphedema was present in the papillary dermis. There were superficial dilated lymph vessels, lined by flat endothelial cells in a discontinuous layer, situated immediately beneath the epidermis (Fig. 2). There was fibrosis in the deep dermis and few mononuclear inflammatory cells throughout the papillary and reticular dermis. With these clinical and histological findings the patient was diagnosed as acquired lymphangiectasis.



**Fig. 1:** Left subaxillary regions showing multiple vesicles and bullae of varying size. There is oozing of clear fluid from papulovesicular lesions.



**Fig. 2:** Ectatic lymphatic spaces in the papillary dermis with subjacent chronic inflammatory cell infiltrate (Hematoxylin and eosin stain, x100)



## DISCUSSION

In the literature AL has been reported in 21 patients associated mostly with the treatment of malignancies of breast and cervix and is often coexistent with lymphedema<sup>2-6</sup>. There have also been reports of cutaneous lymphangiectasis after treatment of bronchial carcinoid<sup>14</sup>. Other reported cases without lymphedema include scarring from scrofuloderma, scleroderma, and cirrhosis<sup>7,15,16</sup>. In the literature, an AL case occurring fifteen years later after an operation is notified<sup>5</sup>. Our case is the first report of acquired lenfangiectasia in the literature at this localization and seventeen years after the surgery of the lipomas.

AL shares clinical and histologic features with the congenital lesion, LC. Some authors apply the terms acquired lymphangioma and LC interchangeably<sup>3,5,6</sup>. In both conditions, the typical cutaneous lesions are superficial small translucent vesicles. Although both share similar histological features, they are two distinct entities. The term acquired lymphangioma (lymphangiectasis) is used when dilated lymphatic channels arise following damage to previously normal deep lymphatics, whereas LC is used when lymphatic channel dilation occurs because of congenital malformations of the lymphatic system involving the skin and the subcutaneous tissues.

In the literature there is a case report as "lymphangioma circumscriptum of the vulva following surgical and radiological therapy of cervical cancer". But according our opinion the name of this case is more right as lymphangiectasis than LC<sup>17,18</sup>.

Lymphangiectasis lacks the subcutaneous muscle-coated cisternae characteristic of LC. Although no specific histological criteria exist with which to differentiate LC from lymphangiectasis, some believe that the absence of subcutaneous cisternae in lymphangiectasis is a true histological difference and that this finding reflects the difference in the pathogenesis of both disorders. The overlying epidermis is usually

associated with acanthosis and hyperkeratosis at these two conditions<sup>1-4</sup>. Usually, the lesion is present at birth or appears early in life at lymphangioma circumscriptum. It may be located in any anatomic site, but has a predilection for the axillary folds, shoulders, neck, proximal parts of the extremities, and tongue<sup>10</sup>.

We think that, deep dermal fibrosis and history of surgery are additional findings that differentiate these two lesions. Although many patients without chronic lymphedema have been reported in the literature, it is a common physical finding in patients with acquired lymphangioma. In addition, clinically acquired lymphangiectasis is similar to dermatitis herpetiformis, herpes simplex, herpes zoster and lymphangioma.

The presence of the red blood cells demonstrates that this is not a simple malformation of the lymphatic system, but is in fact sometimes a mixed malformation composed of lymphatic and blood vessels. In our case, erythematous appearance was present in the lesions, but on microscopic examinations malformations of the blood vessels was not present.

Consequently, AL and LC histologically are similar lesions. LC is a congenital malformation of the lymphatic system that occurs at birth or later. We think that same denomination must not be used for these two different entities. If there is RT or a history of surgery and a local lesion without a mass that characterizes superficial dilated lymph vessels must denominating as AL. Remembering that as well as our case AL may occur several years after surgery and/or RT applications. In addition to clinical story, lacking subcutaneous lymphatic dilations, fibrosis at reticular dermis, lymphedema at papillary and reticular dermis in this lesions its are findings that facilitation diagnosis of AL

## REFERENCES

1. Levers's histopathology of the skin. Ninth edition. Calonje E, Jones EW, 2005-Philadelphia;1047.



2. Ambrojo P, Cogolluda EF, Aguilar A, Sanchez Yus E, Sanchez de Paz F. Cutaneous lymphangiectases after therapy for carcinoma of the cervix a case with unusual clinical and histological features. Clin Exp Dermatol 1990; 15:57-59.
3. Celis, AV, Gaughf CN, Sanguenza, OP, Gourdin, FW. Acquired lymphangiectasis. South Med J 1999; 92:69-72.
4. Kaya TI, Kokturk A, Polat A, Tursen U, Ikizoglu G. A case of cutaneous lymphangiectasis secondary to breast cancer treatment. Int J Dermatol. 2001; 40:760-761.
5. Giannelli V, Rockley, PF. Acquired lymphangiectasis following mastectomy and radiation therapy--report of a case and review of the literature. Cutis 1996; 58:276-278.
6. Mallett RB, Curley GK, Mortimer PS. Acquired lymphangioma: report of four cases and a discussion of the pathogenesis. Br J Dermatol 1992; 126:380-382.
7. Tuffanelli DL. Letter: Lymphangiectasis due to scleroderma. Arch Dermatol 1975; 111:1216.
8. Mortimer PS, Simmonds RH, Rezvani M, Robbins ME, Ryan TJ, Hopewell JW. Time-related changes in lymphatic clearance in pig skin after a single dose of 18 Gy of X rays. Br J Radiol 1991; 64:1140-1146.
9. Weingold DH, White PF, Burton CS. Treatment of lymphangioma circumscriptum with tunable dye laser. Cutis 1990; 45:365-366.
10. Eliezri YD, Sklar JA. Lymphangioma circumscriptum: review and evaluation of carbon dioxide laser vaporization. J Dermatol Surg Oncol 1988; 14:357-364.
11. Bailin PL, Kantor GR, Wheeland RG. Carbon dioxide laser vaporization of lymphangioma circumscriptum. J Am Acad Dermatol 1986; 14:257-262.
12. Tasdelen I, Gokgoz S, Paksoy E, et al. Acquired lymphangiectasis after breast conservation treatment for breast cancer: report of a case. Dermatol Online J 2004; 10:9-13.
13. Peachey RDG, Lim CC, Whimster JW. Lymphangioma of the skin: a review of 65 cases. Br J Dermatol 1970; 83:519-527.
14. Ziv R, Schewach-Miller M, Trau U. Lymphangiectasia. A complication of thoracotomy for bronchial carcinoid. Int J Dermatol 1988; 27:123-126.
15. Di Leonardo M, Jacoby RA. Acquired cutaneous Lymphangiectasia secondary to scarring from scrofuloderma. J Am Acad Dermatol. 1986; 14:688-690.
16. Garcia-Doval I, de la Torre C, Losada A, Ocampo C, Rodriguez T, Cruces MJ. Acquired cutaneous lymphangiectasia in a patient with cirrhotic ascites. J Eur Acad Dermatol Venereol 1999; 13:109-112.
17. Jappe U, Zimmermann T, Kahle B, Peyzoldt D. Lymphangioma circumscriptum of the vulva following surgical and radiological therapy of cervical cancer. Sex Transm Dis 2002; 29:533-535
18. Abu-Hamad A, Provencher D, Ganjei P, Penalver M. Lymphangioma circumscriptum of the vulva: case report and review of the literature. Obstet Gynecol 1989; 73:496-499.
19. Huilgol SC, Neill S, Barlow RJ. CO(2) laser therapy of vulval lymphangiectasia and lymphangioma circumscriptum. Dermatol Surg 2002; 28:575-577.