

Original Article

# Isolated volar surgical approach for the treatment of perilunate and lunate dislocations

Hakan Başar, Betül Başar<sup>1</sup>, Bülent Ero<sup>2</sup>, Cihangir Tetik<sup>3</sup>

## ABSTRACT

**Background:** Volar and/or dorsal surgical approaches are used for surgical treatment of perilunate and lunate dislocations. There are no accepted approaches for treatment in the literature. We evaluated the functional results of isolated volar surgical approach for the treatment of perilunate and lunate dislocation injuries.

**Materials and Methods:** 9 patients (6 male and 3 female patients average age  $34.5 \pm 3.6$  years) diagnosed with perilunate or lunate dislocations between January 2000 and January 2009 were involved in the study. The reduction was performed through isolated volar surgical approach and K-wire fixation, fracture stabilization with volar ligament repair was performed. Range of wrist joint motion, fracture healing, carpal stability, grip strength, return to work were evaluated and also direct radiographs were taken routinely at each control. The scapholunate interval and the scapholunate angle were evaluated radiographically. Evaluations of the clinical results were done using the DASH, VAS and Modified Mayo Wrist Scores.

**Results:** The physical rehabilitation was started at 6<sup>th</sup> week, after the K-wires were removed. The average followup was 18.2 months (range 12-28 months). At the final followup, the average flexion extension arc was  $105.0 \pm 9.6^\circ$  (74.6% of the other side), the average rotation arc was  $138.8 \pm 7.8^\circ$  (81.5% of the other side) and the average radioulnar arc was  $56.1 \pm 9.9^\circ$  (86.4% of the other side). The grip strength was 0.55 bar; 83.2% that the uninjured arm. According to the Mayo Modified Wrist score, the functional result was excellent in five patients and good in four and the average DASH score was 22.8. The scapholunate interval was 2.1 mm and scapholunate angle was  $51^\circ$ .

**Conclusion:** The clinical and radiological results of the isolated volar surgical approach were satisfactory. The dorsal approach was not needed for reduction of dislocations during operations. Our results showed that an isolated volar approach was adequate.

**Key words:** Carpal instability, lunate dislocation, perilunate dislocation, volar surgical approach

## INTRODUCTION

Dislocation is seen in 10% of the carpal bone injuries and occurs after high energy trauma while the wrist is in hyperextension.<sup>1</sup> They tend to occur in young working age men.<sup>1</sup>

Department of Orthopedics and Traumatology, Sakarya Training and Research Hospital, Sakarya, Turkey, <sup>1</sup>Departments of Physical Medicine and Rehabilitation, Akyazı State Hospital, Sakarya, <sup>2</sup>Orthopaedic Surgery, Marmara University School of Medicine, <sup>3</sup>Orthopaedics and Traumatology, Acibadem Maslak Hospital, Istanbul, Turkey

**Address for correspondence:** Dr. Hakan Başar,  
Eski Kazımpaşa cad. yolu Arabacı alanı mah. Akkent villaları NO: 156/25  
Serdivan/Sakarya, Turkey.  
E-mail: hbasar80@hotmail.com

Access this article online	
Quick Response Code:	Website: <a href="http://www.ijoonline.com">www.ijoonline.com</a>
	DOI: 10.4103/0019-5413.132523

The perilunate injury was divided into four stages with a cadaveric study.<sup>2</sup> The lunotriquetral ligament disruption and displacement of lunate are seen in stage 3 perilunate injury. The lunate is displaced dorsal while its articular surface with distal radius is normal or near-normal (Perilunate dislocation) [Figure 1a]. Complete ligament disruption and volar dislocation of the lunate through the space of Poirier are seen in stage 4 perilunate injury. The radiolunate articulation is disrupted (Lunate dislocation) [Figure 1b]. Even though we cannot see these images in antero-posterior (AP) X-ray, it helps us confirm whether there is a fracture (e.g. styloid and carpal fractures).

Radiological diagnosis is important and the lateral X-ray plays a key role. The scapholunate angle is measured on lateral X-ray. Normally, the angle is between  $30^\circ$  and  $60^\circ$ . If this angle exceeds  $70^\circ$ , there is said to be a scapholunate dissociation.<sup>2</sup>

The treatment choices for perilunate and lunate dislocations are closed reduction and casting, open reduction-internal

fixation-ligament repair, trapeziolunate external fixation, limited wrist arthrodesis and proximal row carpectomy.<sup>1</sup>

Closed reduction (under appropriate anaesthesia) and casting are recommended in the treatment of acute perilunate and lunate dislocations to prevent the increase of edema and to decrease neurovascular complications. If reduction is successful then the definitive treatment (open surgery and internal fixation) might be delayed otherwise these cases should undergo an emergency open reduction and internal fixation. This treatment is adopted from the treatment of fractures and ligament injuries.<sup>3</sup> In open reduction and internal fixation there are several methods. In some, volar and dorsal approaches are handled together<sup>4,5</sup> whereas in the others only volar<sup>6</sup> or dorsal approaches are used.<sup>2,7,8</sup>

The aim of our study is to determine whether an isolated volar surgical approach is successful for the treatment of perilunate and lunate dislocation.

## MATERIALS AND METHODS

9 patients (6 males and 3 females average age of  $34.5 \pm 3.6$  years) diagnosed with perilunate or lunate dislocation between January 2000 and January 2009 were involved in the study. The average time from the occurrence of the dislocation to surgery was  $8.9 \pm 4.3$  h.

The mechanisms of injury were car accident for two patients, sports injury for three patients and falling

from a height on the wrist for four patients. The left wrist affected in two and the right wrist was affected in seven patients. There was only one patient in whom nondominant wrist had suffered. Scaphoid fracture and perilunate dislocation was diagnosed in two patients, the radial styloid fracture and perilunate dislocation was diagnosed in one patient, pure perilunate dislocation was diagnosed in two patients and pure lunate dislocation was diagnosed in four patients [Figure 2]. All cases presented with stage 3 or 4 dislocation of which five of them were perilunate dislocations and four of them were lunate dislocations. None of the cases presented with dorsal dislocation. Three (33.3%) patients had greater arc injuries, six (66.6%) patients had lesser arc injuries. Preoperative five patients (55.5%) had hypoesthesia at 1<sup>st</sup>, 2<sup>nd</sup>, 3<sup>rd</sup> and radial side of 4<sup>th</sup> finger.

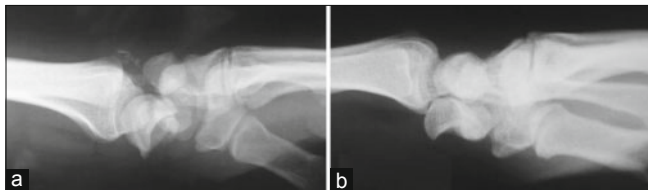
## Operative procedure

The palmar surgical approach was used *via* an extended carpal tunnel incision across the wrist in a zigzag fashion. Median nerve and flexor tendons were retracted radially. After the exploration of palmar capsule, volar capsular rent and lunate dislocation would be visible. The lunate was reduced back in between the capitate and radius while applying gentle longitudinal traction on the hand.

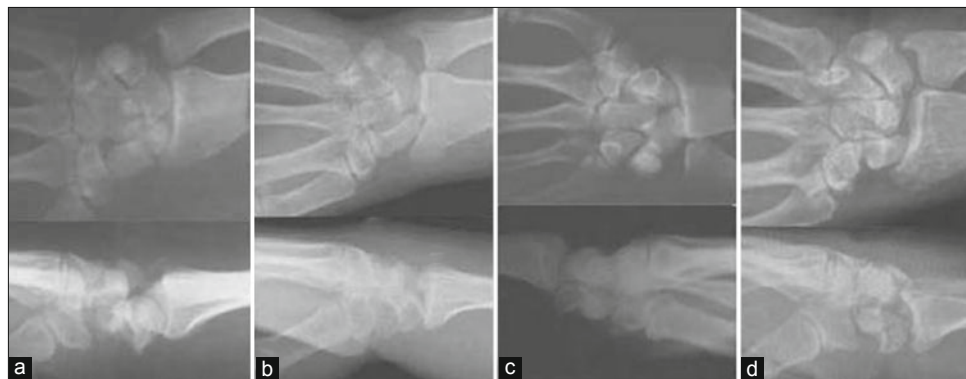
The deep volar luno triquetral ligament, scapho-lunate ligament and radiolunate ligaments were repaired [Figure 3]. The lunocapitate joint was stabilized with one crossed Kirschner wire.

The scaphoid fractures were fixed with a cannulated screw of 3.5 mm and grafted with the auto-graft. We always use bone graft for primary fixation of the scaphoid in our clinic. The radial styloid was fixed by a cannulated screw of 4.5 mm [Figure 4].

After operation, the wrist movements of the patients were prevented for one and a half month by implementing



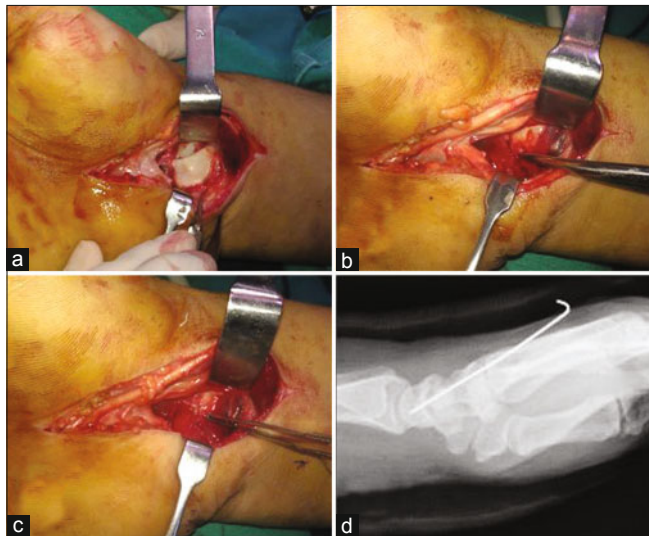
**Figure 1:** X-ray (lateral view) of wrist joint showing (a) Stage 3 perilunate injury. (b) Stage 4 perilunate injury



**Figure 2:** Preoperative X-ray of wrist joint anteroposterior and lateral views showing (a) scaphoid fracture with perilunate dislocation (b) A radial styloid fracture and perilunate dislocation (c) A pure lunate dislocation (d) A pure perilunate dislocation

short arm splint. K-wires were taken out on the 6<sup>th</sup> week and the exercises of movement expanding for wrist articulation and of isometric muscle restoration were started.

Wrist joint range of motion, fracture heal, carpal stability, the power of grasping, return to work were evaluated and also direct radiographs were taken routinely at each control. With these radiographs, scapholunate interval and scapholunate angle were evaluated. Evaluation of the clinical results was done using the DASH, VAS and Modified Mayo Wrist Scores.



**Figure 3:** (a) Peroperative clinical photographs of volar surgical approach to the lunate dislocation. (b) The deep volar luno-triquetral and scapho-lunate ligaments were ruptured. (c) The deep volar luno-triquetral and scapho-lunate ligaments have been repaired. (d) X-ray of wrist joint lateral view showing fixation with K-wires after open reduction of the lunate

## RESULTS

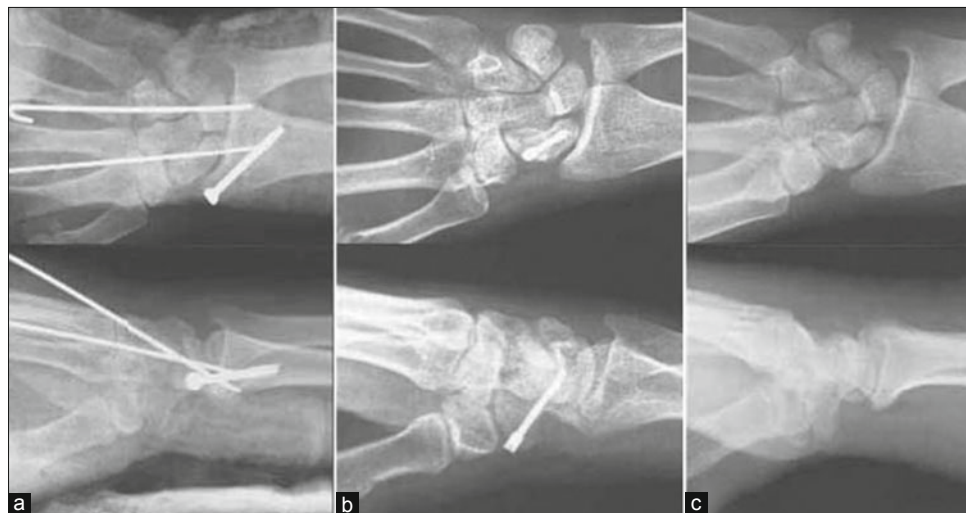
The average followup was 18.2 months (range 12-28 months). In all patients, anatomic reduction of lunate bone was maintained during followup period. The radial styloid and scaphoid fracture union was observed at 3<sup>rd</sup> month There were no cases of lunate avascular necrosis and radial styloid, scaphoid nonunion during followup period. Hypoesthesia immediately after surgery was observed in five patients and the problem resolved in due course of time.

The average flexion extension arc was  $105.0 \pm 9.6^\circ$  (range  $90-120^\circ$ ) (74.6% of the other side), the average rotation arc was  $138.8 \pm 7.8^\circ$  (range  $130-150^\circ$ ) (81.5% of the other side) and the average radioulnar arc was  $56.1 \pm 9.9^\circ$  (range  $45-70^\circ$ ) (86.4% of the other side). The grip strength was 0.55 bar and 83.2% of that of the uninjured arm.

In the tests carried out for clinical evaluation, the average DASH score was 22.8 (range 20.1-25.2). The Modified Mayo Wrist score was very good for five patients and good for four patients. The preoperative VAS which was measured 9.1 (range 8-10) reduced to 0.5 (range 0-1) in the final followup. In the final followup, the scapholunate interval was 2.1 mm (range 1.6-2.4 mm) and the scapholunate angle was found in normal limits of  $51^\circ$  (range  $47^\circ-58^\circ$ ).<sup>9</sup> All patients returned to work after 3-4 months postoperatively.

## DISCUSSION

Even though dislocation in carpal bones is rarely seen, it might lead to instability and functional loss in the wrist if it is not treated properly.<sup>10,11</sup> Misdiagnosis or late diagnosis of perilunate and lunate dislocations is reported up to 25%.<sup>11,12</sup>



**Figure 4:** X-ray of wrist joint anteroposterior and lateral views showing (a) The postoperative 1<sup>st</sup> day X-ray of radial styloid fracture and perilunate dislocation. (b) The postoperative 12<sup>th</sup> month X-ray of a scaphoid fracture and perilunate dislocation showing 4.5 mm cannulated screw in situ, k-wires have been removed (c) The postoperative 24<sup>th</sup> month X-ray of a radial styloid fracture and perilunate dislocation. K-wires and the 4.5 mm cannulated screw were taken out

This delay affects the prognosis unfavorably in comparison with early treatment.<sup>12</sup> Untreated perilunate injury leads to painful limited range of motion, wrist joint arthritis and median nerve compression.<sup>13</sup>

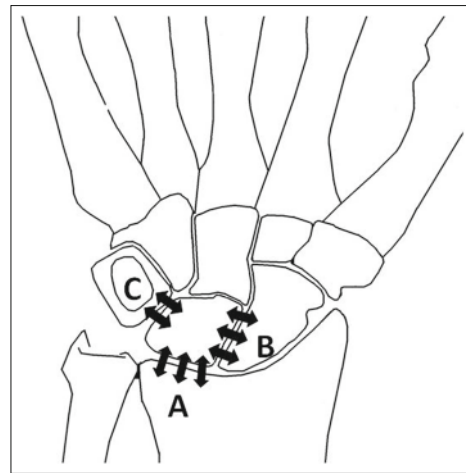
Although closed reduction is easy in acute perilunate and lunate dislocations, it is often difficult to maintain the reduction and the normal intercarpal integrity.<sup>14,15</sup> The ratio of reduction loss was 59% within 6 weeks of closed reduction and casting.<sup>15</sup> Most of the surgeons prefer open reduction due to the pain and loss of mobility resulting from residual carpal instability and progressive arthritis occurring frequently after closed reduction.<sup>12,15</sup>

Open reduction facilitates reduction and fixation and decrease possibility of residual instability. Open surgical reduction is performed with volar, dorsal or combined volar and dorsal approaches. Open surgical reduction of perilunate and lunate dislocation provides direct ligamentous repair and helps stability.<sup>2,4-8</sup>

Which surgical approach should be preferred? Dorsal, volar or a combined approach is controversial. The dorsal surgical approach provides a convenience in reduction of the scapholunate interval and repair of the dorsal ligaments, while the volar surgical approach allows to repair the important volar ligaments and to decompress the carpal tunnel.<sup>9</sup> Dorsal surgical approach could lead to scaphoid and lunate avascular necrosis.<sup>9</sup> In volar surgical approach the deep volar lunotriquetral ligament, scapholunate ligament and radiolunate ligaments can be repaired. In the dorsal surgical approach the scapholunate ligament and dorsal luno-triquetral ligament can be repaired<sup>9</sup> [Figure 5]. However, we obtained good results regarding stability without repairing the scapholunate ligament and dorsal lunotriquetral ligament as we used an isolated volar surgical approach.

Extended carpal tunnel incision is preferred during volar surgical approach. The median nerve is retracted radially. The lunate and volar capsular rent will be visible in the space of Poirier. Lunate dislocation is reduced; volar perilunate ligaments and capsule are repaired. Some authors recommend combined approaches.<sup>4</sup> They obtained high satisfactory results in 9 of 11 perilunate fracture-dislocations.<sup>4</sup>

In one study (Twenty five patients treated over an 11-year period for dorsal trans-scaphoid perilunate fracture-dislocations), the ratio of active range of wrist motion reduction was 20% in the patients treated *via* pure dorsal surgical approach. The range of flexion-extension arc was 104°, rotation arc was 152° and radioulnar deviation arc was 41°.<sup>16</sup> In our study we achieved similar results in terms of



**Figure 5:** Line diagram of wrist joint showing (A) Radiolunate ligament, (B) Scapholunate ligament, (C) Lunotriquetral ligament

flexion extension arc, rotation arc and radio-ulnar deviation arc. We achieved better results in term of grip strength.

In another study, the ratio of active range of wrist motion reduction was one-third compared with the opposite side, grip strength reduction ratio was 15-20% in the 25 patients (15 perilunate dislocations and ten perilunate fracture-dislocations) treated via a combined volar and dorsal surgical approach.<sup>17</sup> In our study we achieved better results in terms of both active range of wrist motion and grip strength. Also the possible complications due to the dorsal surgical approach were prevented. The dorsal surgical approach has a risk for lunate and scaphoid avascular necrosis due to disruption of the blood supply. Combined approach increases the probability of adhesion formation at both volar and dorsal sides of the wrist. These adhesions decrease the wrist range of motion.

We used volar surgical approach. The volar surgical approach allows median nerve exploration and carpal tunnel decompression. Also the perilunate and lunate dislocation and the fracture of the scaphoid are reduced easily with volar approach. The luno-triquetral ligament is important for volar intercalated instability.<sup>18</sup> The volar approach allows repair of the luno-triquetral ligament.

When the greater arc is injured together with the scaphoid fracture, nonoperative treatment of scaphoid fracture fails even if it is undisplaced. In those cases fixation of the scaphoid is recommended.<sup>19</sup> In our study, two scaphoid fractures and radial styloid fracture healed without complications. There were no nonunion. The scapho-lunate gap is important to evaluate the functional outcome. It is suggested that a scapho-lunate gap >3 mm leads to a poorer functional outcome.<sup>20</sup> The scapholunate interval at the final control was measured as 2.1 mm (range

1.6-2.4 mm) and this was maintained throughout the routine controls.

All treatment methods used in perilunate and lunate injuries focus on carpal integrity. This is important for a satisfactory outcome including the grip strength and wrist joint range of motion. We could achieve these results with an isolated volar surgical approach. Despite carpal integrity, the patients may suffer from osteoarthritic alterations and permanent instability in the wrist. Range of motion of the wrist might be limited even after anatomic reconstruction with rapidly developing painful radiocarpal osteoarthritis. The advantages of proximal row carpectomy should be kept in mind in such cases.<sup>21-23</sup>

## REFERENCES

1. Dobyns JH, Linscheid RL. Fractures and dislocations of the wrist. In: Rockwood and Green (Ed): Fractures in adults, 6<sup>th</sup> ed. Philadelphia, J B Lippincott; 2006. p. 858-909.
2. Kennedy SA, Allan CH. In brief: Mayfield JK, Johnson RP, Kilcoyne RK. Classification: Carpal dislocations and progressive perilunar instability. *Clin Orthop Relat Res* 2012;470:1243-5.
3. Cooney WP, Bussey R, Dobyns JH, Linscheid RL. Difficult wrist fractures. Perilunate fracture-dislocations of the wrist. *Clin Orthop Relat Res* 1987;214:136-47.
4. Sotereanos DG, Mitsionis GJ, Giannakopoulos PN, Tomaino MM, Herndon JH. Perilunate dislocation and fracture dislocation: A critical analysis of the volar-dorsal approach. *J Hand Surg* 1997;22:49-56.
5. Melone CP, Murphy MS, Raskin KB. Perilunate injuries. Repair by dual dorsal and volar approaches. *Hand Clin* 2000;16:439-48.
6. Chou YC, Hsu YH, Cheng CY, Wu CC. Percutaneous screw and axial Kirschner wire fixation for acute transscaphoid perilunate fracture dislocation. *J Hand Surg* 2012;37:715-20.
7. Inoue G, Kuwahata Y. Management of acute perilunate dislocations without fracture of the scaphoid. *J Hand Surg* 1997;22:647-52.
8. DiGiovanni B, Shaffer J. Treatment of perilunate and transscaphoid perilunate dislocations of the wrist. *Am J Orthop* 1995;24:818-26.
9. Melsom DS, Leslie IJ. Carpal dislocations. *Curr Orthop* 2007;21:288-97.
10. Palmar AK, Dobyns JH, Linscheid RL. Management of posttraumatic instability of the wrist secondary to ligament rupture. *J Hand Surgery* 1978;3:507-32.
11. Laporte M, Michot A, Choughri H, Abi-Chahla ML, Pelissier P. Perilunate dislocations and fracture-dislocations of the wrist, a review of 17 cases. *Chir Main* 2012;31:62-70.
12. Herzberg G, Comtet JJ, Linscheid RL, Amadio PC, Cooney WP, Stalder J. Perilunate dislocations and fracture-dislocations: A multicenter study. *J Hand Surg* 1993;18:768-79.
13. Herzberg G, Forissier D. Acute dorsal trans-scaphoid perilunate fracture-dislocations: Medium-term results. *J Hand Surg* 2002;27:498-502.
14. Apergis E, Maris J, Theodoratos G, Pavlakis D, Antoniou N. Perilunate dislocations and fracture-dislocations: Closed and early open reduction compared in 28 cases. *Acta Orthop Scand* 1997;275:55-9.
15. Adkison JW, Chapman MW. Treatment of acute lunate and perilunate dislocations. *Clin Orthop* 1982;164:199-207.
16. Knoll VD, Allan C, Trumble TE. Trans-scaphoid perilunate fracture dislocations: Results of screw fixation of the scaphoid and lunotriquetral repair with a dorsal approach. *J Hand Surg* 2005;30:1145-52.
17. Lutz M, Arora R, Kammerlander C, Gabl M, Pechlaner S. Stabilization of perilunate and transscaphoid perilunate fracture-dislocations via a combined palmar and dorsal approach. *Oper Orthop Traumatol* 2009;21:442-58.
18. Trumble TE, Bour CJ, Smith RJ, Glisson RR. Kinematics of the ulnar carpus related to the intercalated segment instability pattern. *J Hand Surg* 1990;15:384-92.
19. Malović M, Pavić R, Milosević M. Treatment of trans-scaphoid perilunate dislocations using a volar approach with scaphoid osteosynthesis and temporary Kirschner wire fixation. *Mil Med* 2011;176:1077-82.
20. Minami A, Ogino T, Ohshio I, Minami M. Correlation between clinical results and carpal instabilities in patients after reduction of lunate and perilunate dislocations. *J Hand Surg* 1986;11:213-20.
21. Cohen MS, Kozin SH. Degenerative arthritis of the wrist: Proximal row carpectomy versus scaphoid excision and four corner arthrodesis. *J Hand Surg* 2001;26:94-104.
22. Rettig ME, Raskin KB. Long term assessment of proximal row carpectomy for chronic perilunate dislocations. *J Hand Surg* 1999;24:1231-6.
23. Inoue G, Shionoya K. Late treatment of unreduced perilunate dislocations. *J Hand Surg* 1999;24:221-5

**How to cite this article:** Basar H, Basar B, Erol B, Tetik C. Isolated volar surgical approach for the treatment of perilunate and lunate dislocations. *Indian J Orthop* 2014;48:301-5.

**Source of Support:** Nil, **Conflict of Interest:** None.