

Serran Dalmak^a
Ekrem Ereka^a
Kamil Serdengeçti^a
Imer Okar^b
Uğur Ülkü^a
Mert Başaran^a

^a Nephrology Department,
Cerrahpaşa Medical Faculty, Istanbul;

^b Pathology Department,
Marmara University, Turkey

A Case Study of Adult-Onset Hypophosphatemic Osteomalacia with Idiopathic Fanconi Syndrome

Dear Sir,

Adult Fanconi syndrome is a metabolic disorder exhibiting hypophosphatemic osteomalacia renal glycosuria, generalized aminoaciduria and usually metabolic acidosis with normal anion gap due to the disorder of proximal tubulus [1]. In patients with Fanconi syndrome, most cases are sporadic and the prognosis is better without cystinosis [2]. To our knowledge, about 40 cases of idiopathic Fanconi syndrome to this day have been reported excluding those in which cystinosis and other acquired causes are suspected [2, 3]. Familial cases to this day are extremely rare and in some of these cases, the renal disease may progress to end stage in 10–20 years [2, 3]. Most of the cases, though, when adequately treated, remain free of symptoms and show no progressive deterioration [3].

Our patient was a 44-year-old woman who was admitted to hospital in November 1993 for severe bone pain and waddling gait. She had history of knee pain as well as polydipsia and polyuria for 20 years with no proven diabetes mellitus, inability to walk normally for 6 months. Her uncle died in his fifties with a renal disease of unknown etiology while her father and two brothers have renal stones without glycosuria. No evidence of renal disease was found in her siblings and other relatives. She is a housewife without a history of exposure to heavy metals and toxic substances. She did not experience sponta-

neous or traumatic fractures. She had no history of periodic paralysis. Her physical examination revealed a well-developed and nourished woman with a waddling gait. Her bones were extremely painful to palpation. The remainder of her physical findings were normal. She had hypophosphatemia, hypokalemia, generalized aminoaciduria, glycosuria, proteinuria, moderate renal failure, metabolic acidosis with normal anion gap, normal parathormone and calcitriol blood levels. Her daily urinary excretion of calcium-phosphorus levels were 260 mg (6.5 mmol/day) and 688 mg (130 mmol/l), respectively. Bone density investigated with photon absorptiometry revealed low mineral content in spine and femur with high risk of fracture. Under light microscopy her renal biopsy specimen showed sclerosis in some glomeruli, mononuclear infiltration and expansion in the interstitium, tubulus degeneration, protein infiltration and expansion of tubulus lumen, polykaryocytosis and vacuoles (fig. 1) similar to those reported in the literature [4]. Under polarized light no cystine crystals were observed. With electron microscopy, mitochondrial dilatation and destruction of cryptas in tubulus cells, multinuclear glomerular epithelial cells, basal lamina thickening around tubulus and glomerulus were observed (fig. 2).

Correction of acidosis with the use of oral sodium bicarbonate, oral phosphate and 1-

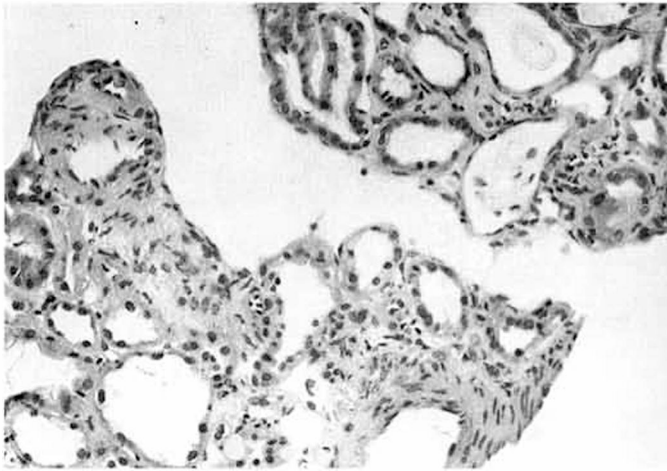


Fig. 1. Light microscopy showing mononuclear infiltration and expansion in the interstitium, tubular degeneration, protein infiltration, expansion of tubular lumen, polykaryocytosis.

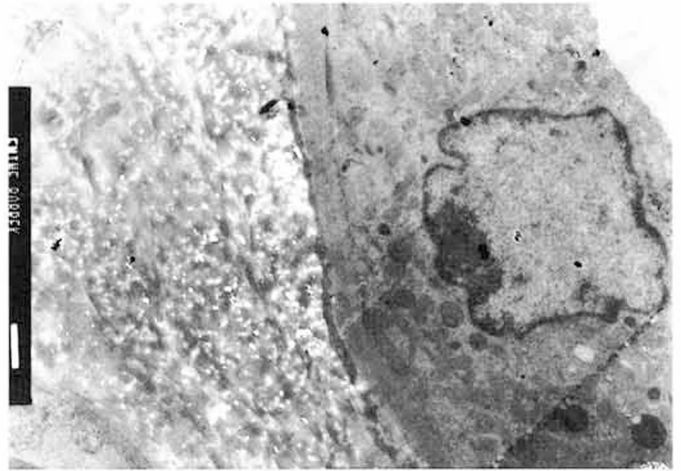


Fig. 2. Mitochondrial dilatation and destruction of crypts in tubulus cells, basal lamina thickening around tubulus and glomerulus in electron microscopy.

hydroxycholecalciferol such as suggested by Harrison et al. [5] has had marked benefits in her clinical and laboratory status. Since, the urinary phosphorus excretion in the normal population in Turkey was found to vary between 160 and 600 mg/day (mean 580); our patient's value (688 mg/day) should be considered as high and therefore compatible with renal leak.

References

- 1 Gottschalk CM, Schrier RW: Diseases of the kidney. Boston, Little Brown and Company, 1993, vol 1, pp 617-627.
- 2 Hunt DD, Stearns G, McKinley JB, Froning E, Hicks P, Bonfiglio M: Long-term study of family with Fanconi syndrome without cystinosis. *Am J Med* 1966;400:492-508.
- 3 Wen SF, Friedman AL, Oberley TD: Two case studies from a family with primary Fanconi syndrome. *Am J Kidney Dis* 1989;13:240-246.
- 4 Patrick A, Cameron JS, Ogg CS: A family with a dominant form of idiopathic Fanconi syndrome leading to renal failure in adult life. *Clin Nephrol* 1981;16:289-292.
- 5 Harrison NA, Batemann JM, Ledingham JGG, Smith R: Renal failure in adult-onset hypophosphatemic osteomalacia with Fanconi syndrome - A family study and review of literature. *Clin Nephrol* 1991;35:148-150.