

Evaluation of Necrotic, Edematous and Inflammatory Changes in Bone Marrow and Soft Tissue After Irrigation with Different Concentrations of NaOCl Solution: An Experimental Study in Rat Tibia

Kursad Aytekin¹ , Aslihan Duman² , Feyza Yıldız Aytekin³ , Ilkay Cinar⁴ , Esra Akdeniz⁵ , Selcuk Takir⁶ , Cem Zeki Esenyel¹ 



Presented in: This study was presented at 28th. National Turkish Orthopedics and Traumatology Congress, 30/10/2018-04/11/2018, Belek, Antalya/Turkey.

Cite this article as: Aytekin K, Duman A, Aytekin FY, et al. Evaluation of Necrotic, Edematous and Inflammatory Changes in Bone Marrow and Soft Tissue After Irrigation with Different Concentrations of NaOCl Solution: An Experimental Study in Rat Tibia. *Eurasian J Med* 2020; 52(3): 243-8.

¹Department of Orthopaedics and Traumatology, Giresun University School of Medicine, Giresun, Turkey

²Department of Pathology, Giresun University School of Medicine, Giresun, Turkey

³Department of Infectious Diseases and Clinical Microbiology, Ministry of Health Giresun University Prof. Dr. A. İlhan Özdemir Training and Research Hospital, Giresun, Turkey

⁴Department of Pathology, Ministry of Health Giresun University Prof. Dr. A. İlhan Özdemir Training and Research Hospital, Giresun, Turkey

⁵Department of Biostatistics, Marmara University School of Medicine, Istanbul, Turkey

⁶Department of Pharmacology, Giresun University School of Medicine, Giresun, Turkey

Received: July 5, 2019

Accepted: January 23, 2020

Available Online Date: June 9, 2020

Correspondence to: Kursad Aytekin
E-mail: kursadaytekin@gmail.com

DOI 10.5152/eurasianjmed.2020.19216



Content of this journal is licensed under a Creative Commons Attribution 4.0 International License.

ABSTRACT

Objective: We aimed to investigate effects of different concentrations (0.5-5%) of Sodium Hypochlorite (NaOCl) solution on healthy tissues, and determine the optimal concentration that does not harm to tissue.

Materials and Methods: 30 tibias of 15 male Wistar albino rats were used. The tibias were randomly divided into 5 groups (Saline, 0.5%, 1%, 2.5%, and 5% NaOCl). Tibias were reamed intramedullary, and irrigated with 20 ml of saline or increasing concentrations of (0.5-5%) NaOCl. The tibias were embedded in paraffin and the sections were stained with hematoxylin-eosin. All sections were assessed for edema, acute inflammation, or necrosis according to their density, in bone marrow and soft tissues.

Results: Pairwise comparisons revealed that irrigation of tibia with saline or 0.5% NaOCl solutions was not statistically significant in terms of necrosis in the bone marrows ($p=0.320$). However, irrigation of rat tibia with saline caused less necrosis in the bone marrows compared to high concentrations (1%, 2.5%, and 5%) of NaOCl (saline and 1% NaOCl, $p=0.017$; saline and 2.5% NaOCl, $p=0.0007$; saline and 5% NaOCl, $p=0.001$).

Conclusion: As an irrigation solution, the effects of 0.5% NaOCl are similar to those of saline in terms of edema, inflammation, and necrosis. There is a need for evaluation of necrosis for extended periods such as one week or one month by immunohistochemical methods and flow cytometry.

Keywords: Irrigation, irrigation solution, NaOCl, Saline, rat tibia.

Introduction

During orthopedic surgeries, despite all precautions, infections are likely to be encountered. Management of infections might require additional hospitalization or the use of systemic antibiotics which can impact the recovery of the patient and the expenses of the healthcare systems [1]. Proper conditions of operation area and local preventions like use of antiseptic solutions, irrigation, and ioban drape could reduce the risk of infections during the surgical procedures [1]. Among these precautions; the irrigation of the surgical field is one of the most important stages during orthopedic surgeries. For this purpose, solutions containing saline, antibiotics, chlorhexidine, or povidone-iodine are often preferred [2-5]. An ideal irrigation solution should be antibacterial and non-toxic to the healthy tissues [6]. Although saline is commonly used as an irrigation solution in orthopedic surgeries, it has no antimicrobial effect. The usage of antibiotics in irrigation solutions is not appropriate because of the risk of antibiotic resistance. Furthermore, chlorhexidine and povidone-iodine solutions have been reported to be cytotoxic in fibroblast cells [7], povidone-iodine causes irritation in the skin around the wound [8, 9], and chlorhexidine is not effective against some microorganisms including spores, viruses, and acid-fast bacteria [10].

NaOCl solution is used as a disinfectant in a wide range of applications, as it is an inexpensive solution that is effective against most of the known bacteria, viruses, spores, and parasites [11-13]. Moreover, most microorganisms cannot develop resistance against NaOCl because it attacks the proteins in a non-specific manner [11-13]. Due to its strong germicidal effect, 0.5-5% concentrations of NaOCl are often used as an irrigation solution in dentistry [14-16]. In addition, Dakin's solution, prepared with tap water and 0.5% NaOCl concentration, has been shown to be effective in wound healing of the diabetic foot diseases and chronic osteomyelitis [17, 18]. NaOCl in saline has been reported to be a good alternative to 'lavage with saline alone'

against bacterial infections [19, 20]. Taking this into consideration, we aimed to search for the potential usage of NaOCl solution as an irrigation solution in orthopedic surgeries to exploit the necrotic, edematous, and inflammatory changes in bone marrow and soft tissue. For this purpose, different concentrations (0.5-5%) of NaOCl solution were investigated histopathologically in terms of edema, inflammation, and necrosis in rat tibias.

Materials and Methods

All experiments were carried out according to the Guide for Care and Use of Laboratory Animals guidelines from the National Research Council and recommendations of the IASP [21], and were approved by the Animal Experiments Local Ethics Committee Giresun University (Decision no: 2018-1). Male Wistar albino rats with an average weight of 200-250 g (10-12 weeks) were used. The animals were obtained from Saki Yenili Laboratory Animals Farm (Ankara, Turkey). Rats were housed under standard temperature of $20\pm 2^{\circ}\text{C}$ and a humidity of 60-70% on a 12:12-h light/dark cycle with free access to standard rat chow and tap water.

Groups and Treatments

To investigate the effects of NaOCl on healthy bone tissues, a total of 30 tibias from 15 male Wistar albino rats were used in all experimentation procedures. Both right and left tibias of rats were used in the study to reduce the number of sacrificed animals, and the groups were formed in accordance with the number of tibias used. The tibias of rats were randomly divided into 5 groups. Group 1 served as a control in which saline (0.9% isotonic NaCl) was used as an irrigation solution. To investigate the effects of NaOCl as an irrigation solution, 4 groups were formed as follows: 0.5% NaOCl (Group 2), 1% NaOCl (Group 3), 2.5% NaOCl (Group 4), and 5% NaOCl (Group 5). All groups except control.

Surgical Procedure and Irrigation

Rats were anaesthetized with intraperitoneal injection of ketamine hydrochloride (50 mg/kg) and xylazine hydrochloride (5 mg/

kg). Supplemental analgesia was provided by buprenorphine (0.3 mg/kg) intraperitoneally. Then, the rat legs were wiped with povidone-iodine solution and covered with a sterile cover. Approximately 1-cm longitudinal incision on the skin was made on tuberositas tibia. The patellar tendon insertion point was gently reamed through the intramedullary of the tibia with an 18-gauge needle tip. Then the soft tissue at the location where the needle entered the bone was excised to allow solutions to flow out of the medulla. All tibias were irrigated with 20 mL of saline or increasing concentrations (0.5-5%) of NaOCl and the irrigation time (30 s) was measured with a stopwatch. During irrigation (30 s) a 22-gauge needle tip was used to ensure solution flow out from the medulla. After the irrigation process, the skin was sutured. All rats were sacrificed with high doses of ketamine/xylazine (100/50 mg/kg) 24 h after the surgery and the legs were dissected. All surgical procedures were performed by the same surgeon.

Histopathology

After the removal of soft tissue, rat tibias were fixed in 10% buffer formalin solution at 4°C and placed on agitation equipment at 400 rpm for 24 and 48 h, respectively. 10% formic acid was (Sigma-Aldrich) used until the decalcification was complete. Decalcified tissues were processed in a tissue processor (Thermo Scientific Excelsior ES) using ascending concentrations of ethanol (70%, 80%, 95%, $3\times 100\%$), three changes of xylene, and four changes of paraffin (60°C) for 40 min per solution. The samples were sectioned (Thermo Scientific Microm HM 340E) at a thickness of 4 μm after the specimens were soaked in ice water overnight. Tissue sections were mounted on poly-lysine slides and oven-dried at 45°C for a minimum of 5 h prior to staining. Following deparaffinization, slides were immersed in Mayer's hematoxylin for 2 min, differentiated in 0.5% acid alcohol for 30 sec, and then bluing was performed in tap water. Slides were stained with eosin for 30 sec and quickly rinsed in running tap water. Dehydration was performed in ascending concentrations of graded ethanol (50-100%) and cleared by xylene before the slides were coverslipped.

Two consecutive sections from each tibia were assessed for edema, acute inflammation, or necrosis in bone marrows and in the surrounding soft tissues. In the present study, we performed H&E staining to see the general structures of the bones and soft tissues, we observed the inflammation, necrosis, and the edema. Histopathological assessments were performed independently by 2 pathologists with

experience in musculoskeletal system pathology by using a light microscope (Olympus CX41) at 10x-40x-magnification.

Assessment of Edema, Inflammation, and Necrosis

To assess the edema in soft tissues, cells from striated muscles of legs were investigated, and the increase in cavities between cells and neutrophil infiltration were evaluated. Acute inflammation and the necrosis were investigated in cell series belonging to soft tissues and bone marrows. All specimens were evaluated through a score system as none (0), mild (1), moderate (2), and severe (3) according to the absence and presence (density) of edema, inflammation, and necrosis [22].

Statistical Analysis

Statistical analyses were performed using R 3.6 Statistical Software (www.r-project.org) which is a free software environment for statistical computing and graphics. Baseline characteristics of the groups were presented as median and interquartile range (IQR) since the measured variables were ordinal. The Kruskal-Wallis test was used as an omnibus test to compare the medians of the groups. Dunn Kruskal-Wallis multiple comparisons where p-values were adjusted with the Benjamini-Hochberg method were also provided. The Dunn test function in the "FSA" package of R statistical program was used for multiple comparisons. P values adjusted with the false discovery rate method were provided. The power analysis was conducted using G*Power 3.1. The appropriate sample size for the study was calculated by setting the significance level, power, and effect size as 0.5, 0.80, and 0.8, respectively, for all of the five groups. The required sample size using the ANOVA procedure in G*Power was calculated as 25. However, for a nonparametric test such as Kruskal-Wallis, the sample size was adjusted by adding 1 more tibia to each group so that the total number of tibias was 30. A P value of <0.05 was considered statistically significant.

Results

Comparing the two observations, the interclass correlation for edema, inflammation, and necrosis were 0.840 [95% confidence interval: CI: 0.624-0.912]; 0.830 [95% confidence interval: CI: 0.608-0.921], and 0.840 [95% confidence interval: CI: 0.618-0.942], respectively, and the p value was significant at 0.001 in each. The average irrigation duration of tibias between the groups were statistically insignificant ($p=0.832$).

A significant difference was found between the groups in terms of edema in soft tissues ($p=0.031$) (Table 1). The pairwise comparisons

Main Points

- NaOCl is a strong bactericidal. Different concentrations of NaOCl solutions were used for irrigation of rat leg in-vivo.
- The bone and soft tissue were evaluated histopathologically.
- 0.5% NaOCl did not harm the bone and soft tissue.
- Further studies are required for routinely usage of NaOCl as an irrigation solution at musculoskeletal system surgeries.

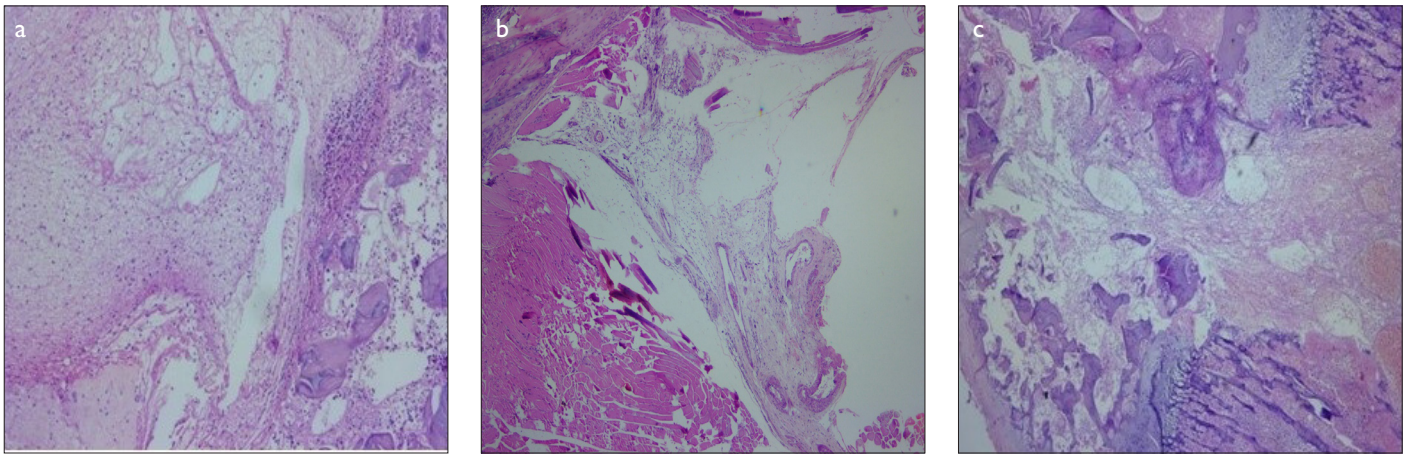


Figure 1. a-c. Hematoxylin-eosin staining of soft tissue inflammation (10x magnification). (a) Saline, (b) 0.5% NaOCl, and (c) 5% NaOCl

Table 1. Descriptive statistics and Kruskal Wallis test results						
Evaluated Parameters	Group 1 (SF)	Group 2 (0.5% NaOCl)	Group 3 (1% NaOCl)	Group 4 (2.5% NaOCl)	Group 5 (5% NaOCl)	Test statistics (p)
Irrigation time (s)	29.5 (3.5)	30 (2.25)	29.5 (3.75)	29 (2.5)	30 (2.5)	0.832
Edema in soft tissues	1.5 (1)	1 (0)	1.5 (1)	2 (0)	2 (0.75)	10.60 (0.031)*
Inflammation in soft tissues	1 (0.75)	1 (0)	1 (0)	1 (0.75)	2 (0)	16.42 (0.002)*
Inflammation in bone marrows	1 (0)	1.5 (1)	1.5 (1)	2 (0.75)	2 (0)	7.23 (0.1241)
Necrosis in soft tissues	0 (0)	0 (0)	1 (0.75)	1 (0.75)	1 (0)	11.86 (0.018)*
Necrosis in bone marrows	0 (0)	1 (0)	1.5 (1)	2 (0)	2 (0)	22.31 (<0.001)*

Data are expressed as medians with interquartile ranges in parentheses. NaOC: Sodium hypochlorite. *Statistically significant p value (p<0.05)

Table 2. Multiple comparisons for significant tests (adjusted p values)				
Comparisons	Edema in Soft Tissues	Inflammation in Soft Tissues	Necrosis in Soft Tissues	Necrosis in Bone Marrows
Saline -0.5% NaOCl	0.839	0.457	0.839	0.320
Saline -1% NaOCl	0.099	0.723	0.099	0.017
Saline -2.5% NaOCl	0.074	0.135	0.074	0.0007
Saline -5% NaOCl	0.066	0.003	0.066	0.001
0.5% NaOCl -1% NaOCl	0.172	0.651	0.172	0.197
0.5% NaOCl -2.5% NaOCl	0.117	0.438	0.117	0.015
0.5% NaOCl -5% NaOCl	0.074	0.023	0.074	0.031
1% NaOCl -2.5% NaOCl	0.793	0.233	0.793	0.287
1% NaOCl -5% NaOCl	0.734	0.008	0.734	0.438
2.5% NaOCl -5% NaOCl	0.865	0.189	0.865	0.670

with respect to edema in soft tissues did not reveal any significant difference. Thus, it can be concluded that the irrigation of tibias with saline or increasing concentrations of NaOCl were similar in terms of edema. However, it should be noted that the difference between Saline and 5% NaOCl in terms of edema in soft tissues was at the borderline (p=0.066) (Table 2).

A significant difference was found between the groups in terms of inflammation in soft tissues

(p=0.002) (Figure 1, Table 1); however, no significant difference was detected between the groups in bone marrows (p=0.1241) (Figure 2, Table 1).

The pairwise comparisons with respect to inflammation in soft tissues revealed that irrigation with saline was not significant compared to the irrigation with 0.5%, 1%, and 2.5% NaOCl solutions (p=0.457, p=0.723, and p=0.135, respectively) (Table 2). Tibias irrigated with saline had sig-

nificantly lower amounts of inflammation in soft tissues than the tibias irrigated with 5% NaOCl solution (p=0.003) (Table 2). Similar results were obtained with 0.5% and 1% NaOCl solutions compared to 5% NaOCl solution (p=0.023 and p=0.008, respectively) (Table 2).

Significant differences were found between the groups in terms of necrosis in soft tissues (Figure 3) and bone marrows (Figure 4) with p values of 0.018 and <0.001, respectively (Table 1). Interestingly the pairwise comparisons with respect to necrosis in bone marrow revealed that there was no statistically significant difference between the tibias irrigated with saline and those irrigated with 0.5% NaOCl solutions (p=0.320) (Table 2). However, the irrigation of rat tibias with saline caused significantly lower amount of necrosis in bone marrows compared to the irrigation solutions composed of higher (1%, 2.5%, and 5%) concentrations of NaOCl (saline vs. 1% NaOCl, p=0.017; saline vs. 2.5% NaOCl, p=0.0007; saline vs. 5% NaOCl, p=0.001) (Table 2).

According to these findings, we determined that as the concentration of NaOCl in irrigation solution increases, necrosis in bone marrows also increases (p=0.320) (Table 2).

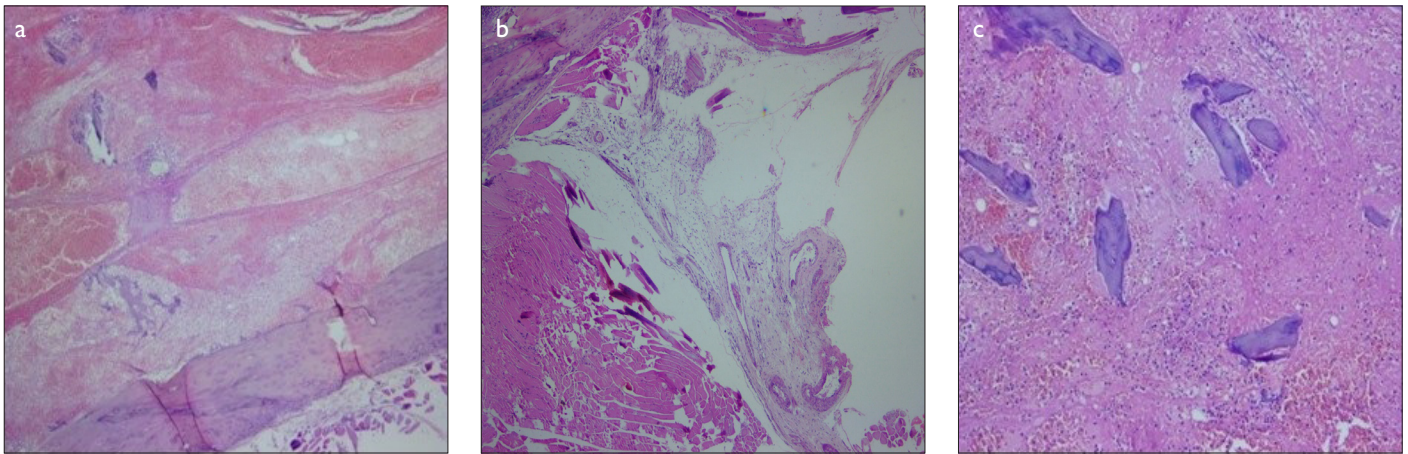


Figure 2. a-c. Hematoxylin-eosin staining of bone marrow inflammation (20x magnification). (a) Saline, (b) 0.5% NaOCl, and (c) 5% NaOCl

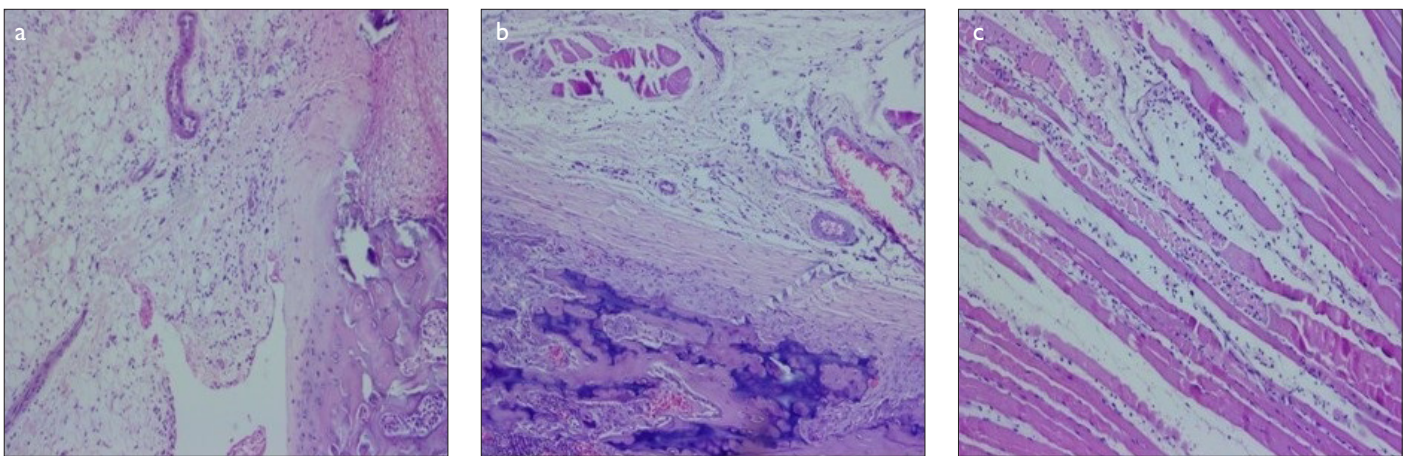


Figure 3. a-c. Hematoxylin-eosin staining of soft tissue necrosis (10x magnification). (a) Saline, (b) 0.5% NaOCl, and (c) 5% NaOCl

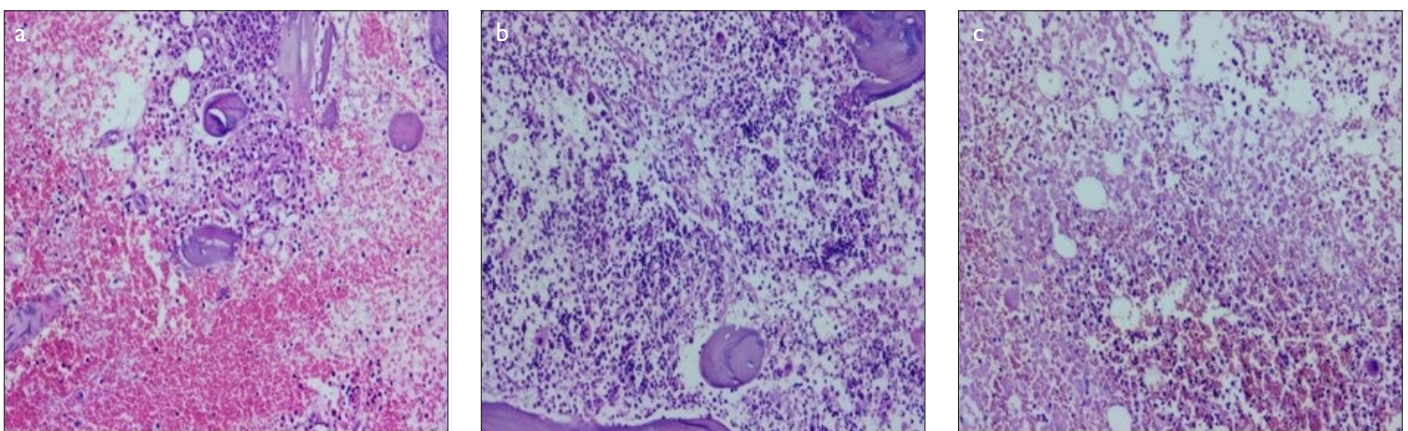


Figure 4. a-c. Hematoxylin-eosin staining of bone marrow necrosis (10x magnification). (a) Saline, (b) 0.5% NaOCl, and (c) 5% NaOCl

Discussion

A variety of preventive methods are applied to reduce the risk of infection in orthopedic surgeries [1]. Irrigation of the surgical site is effectively done in almost all cases. Several solutions including saline, antibiotic solutions, chlorhexidine, and povidone-iodine are preferred for this purpose. However, all these solutions have certain shortcomings. The ideal

irrigation solution has been considered to have bactericidal effect and remove pathogens mechanically without damaging the healthy tissues. NaOCl is often used as a disinfectant for drinking water and in hospital facilities, and it is also known to inactivate prions [13]. In addition, it is often used as an irrigation solution in dentistry due to its bactericidal effect with insignificant damage to healthy tissues. Dakin's

solution, used for wound care in the treatment of diabetic foot and for irrigation during the treatment of chronic osteomyelitis, is known to contain 0.5% NaOCl [16-18]. In several studies, it has also been shown to have bactericidal effect at concentrations of 0.5-5% [14-16]. In the mechanism of action for its bactericidal effect, it was proposed that the hypochlorite anion released in NaOCl solution combines

with the amino groups from the bacteria and forms chloramine which inhibits the bacterial enzymes and hence causes the inactivation of bacteria [13]. NaOCl is known to be toxic for vital tissues by inducing hemolysis, ulceration, inhibition of neutrophil migration, endothelial and fibroblast cell damage, or bone destruction [22]. Most of these studies, however, have been conducted using in vitro cell cultures or cadavers which are devoid of the cell (such as leukocytes, lymphocytes, and macrophages) support involving blood/veins/nerves and inflammation. The toxic effects of NaOCl may be neutralized with the inflammatory cytokines that it attracts toward the wound site. The dose or the concentration of the solution used is also important for toxicity. A recent study has reported that intra-articular injection of hydrogen sulfide at lower concentrations decrease the progression of gonarthrosis whereas higher concentrations are toxic [23]. Likewise, 70% alcohol is more bactericidal comparing to 100% alcohol as commonly known. Moreover, solutions such as povidone-iodine cannot be used for patients with iodine allergy, and hence NaOCl-based irrigation solutions can be good alternatives in these cases. In this study, we performed the experiments at NaOCl concentrations of 0.5-5% and investigated its plausible toxic effects on soft tissues, bone marrows, and laminar bones when used as an irrigation solution.

As NaOCl is commonly used in dentistry for irrigation, clinical complications occurring in humans have been previously reported [14]. These complications are generally observed as edema due to the transport of NaOCl into the periapical area, which resolves in a few days [14, 24]. In the present study, we observed similar levels of edema in tibias irrigated with saline and NaOCl solutions, which indicated that, with regard to edema, the undesirable effect of NaOCl solution during irrigation is similar to that of saline.

In several studies, a higher amount of inflammation was observed when the concentration of NaOCl solution was increased. For example, Pashley et al. [24] suggested that low concentrations of NaOCl caused less inflammation. Similar results were obtained for subcutaneous connective tissues of guinea pigs. Following exposure to different concentrations (0.5%, 2.5%, and 5%) of sodium hypochlorite, an increase in the inflammation was observed [25]. Taking these results into consideration, another parameter that we assessed in addition to edema was inflammation. We observed similar levels of inflammation in bone marrows of tibias irrigated with saline and increasing concentrations of

NaOCl (Table 1). Similar results were obtained for soft tissues of the 0.5% NaOCl-irrigated group and control group. However, when the concentration of NaOCl was increased, higher inflammation was observed in soft tissues. This is in accordance with the results obtained in the previous studies.

The cytotoxic potential of NaOCl is the most important criterion assessed in our study [26]. During reaming of the bone, the necrosis generally increases with increase in the speed of reaming [27]. Additionally, pressure of the irrigation also acts on the level of necrosis [28]. To reduce the iatrogenic risk of necrosis, we manually drilled during the surgery and performed the irrigation for similar durations with a syringe in the experiments. Statistically insignificant irrigation durations were observed for all groups ($p=0.832$). In the control group which was irrigated with saline, we did not observe necrosis. On the contrary, we found higher level of necrosis in soft tissues, bone marrows, and laminar bones for the groups irrigated with higher concentrations of NaOCl when compared to those irrigated with 0.5% NaOCl. Moreover, some studies point out the cytotoxic effects of NaOCl on cells [29, 30] in which the exposure times to the NaOCl solutions were in a wide range (10 min to 24 h). In a review by Willy et al. [31], however, the ideal exposure time to NaOCl solution for irrigation was proposed to be 1 min. In the present study, the irrigation durations of all the groups were comparable and all were exposed to NaOCl solution for 30 s. Heling et al. [26] reported that 0.01% NaOCl was cytotoxic for in-vitro human skin fibroblast cell cultures. On the contrary, 0.5% to 5% concentrations of NaOCl used for irrigation during several interventions were shown to induce necrosis in teeth [15, 16, 24, 32] comparable to the irrigation with saline which was similar to our results for live bones. This can be attributed to the similar anatomical and histological structures of teeth and bones.

The limitations of current study are, not to evaluate lower concentrations of NaOCl, not to evaluate at infectious conditions of musculoskeletal tissue, not to evaluate the long terms results of NaOCl irrigation, not to evaluate by different methods as immunohistochemical methods and flow cytometry.

In conclusion, despite adequate precautions, the risk of infection continues to be a problem in orthopedic surgeries. There are studies reporting successful results with irrigation and debridement of infected joint prosthesis surgery [33, 34]. Treatment with irrigation and

debridement is more preferable than changing the prosthesis for both doctors and patients [35]. It is clear that there is a need for advanced studies on the ideal fluid properties for use in irrigation. The bactericidal efficacy of NaOCl is extremely advantageous, especially to reduce risk of infection. Our report suggests that the side effects of 0.5% NaOCl as an irrigation solution is comparable to those of saline when considering the bactericidal potential of NaOCl. On basis of the results, we suggest irrigation by 0.5% NaOCl for both bone and soft tissue surgeries because of its antibacterial effect. However, this study revealed the need to evaluate necrosis with immunohistochemical methods and flow cytometry for longer periods (such as one week or one month).

Ethics Committee Approval: Ethics committee approval was received for this study from the ethics committee of Giresun University, Local Ethics Committee for Animal Experiments (Decision no: 2018-1).

Peer-review: Externally peer-reviewed.

Author Contributions: Concept - C.Z.E., K.A.; Design - K.A.; Supervision - C.Z.E., S.T.; Resources - C.Z.E.; Materials - K.A., A.D., F.Y.A., I.C.; Data Collection and/or Processing - K.A., A.D., I.C.; Analysis and/or Interpretation - K.A., E.A.; Literature Search - K.A., A.D., F.Y.A.; Writing Manuscript - K.A., F.Y.A., S.T.; Critical Review - S.T., C.Z.E.

Conflict of Interest: Authors have no conflicts of interest to declare.

Financial Disclosure: The authors declared that this study has received no financial support.

References

1. Aytekin K, Direkel Ş, Kir B, et al. Efficacy of the use of sterile plastic to cover the surgical field against infection in orthopedic operations. *J Con-temp Med* 2018; 8: 20-5.
2. Campbell ST, Goodnough LH, Bennett CG, et al. Antiseptics commonly used in total joint arthroplasty interact and may form toxic products. *J Arthroplasty* 2018; 33: 844-6. [\[Crossref\]](#)
3. Conroy BP, Anglen JO, Simpson W, et al. Comparison of castile soap, benzalkonium chloride, and bacitracin as irrigation solutions for complex contaminated orthopaedic wounds. *J Orthop Trauma* 1999; 13: 332-7. [\[Crossref\]](#)
4. George J, Klika AK, Higuera CA. Use of chlorhexidine preparations in total joint arthroplasty. *J Bone Joint Infect* 2017; 2: 15-22. [\[Crossref\]](#)
5. Smith DC, Maiman R, Schwechter EM, et al. Optimal irrigation and debridement of infected total joint implants with chlorhexidine gluconate. *J Arthroplasty* 2015; 30(10): 1820-2. [\[Crossref\]](#)
6. Tiemann A, Hofmann G. Wound irrigation within the surgical treatment of osteomyelitis. *GMS Interdiscip Plast Reconstr Surg DGPW* 2012; 1: DOI: 10.3205/iprs000008.

7. Sanchez IR, Nusbaum KE, Swaim SF, et al. Chlorhexidine diacetate and povidone-iodine cytotoxicity to canine embryonic fibroblasts and *Staphylococcus aureus*. *Vet Surg* 1988; 17: 182-5. [\[Crossref\]](#)
8. Gabriel A, Windle M, Schraga E. Wound irrigation. *Medscape*. 2011. Available From: URL: www.emedicine.medscape.com/article/1895071.
9. Iijima S, Kuramochi M. Investigation of irritant skin reaction by 10% povidone-iodine solution after surgery. *Dermatology* 2002; 204: 103-8. [\[Crossref\]](#)
10. Ferretti GA, Brown AT, Raybould TP, et al. Oral antimicrobial agents--chlorhexidine. *NCI Monogr* 1990; 9: 51-5.
11. Winter J, Ilbert M, Graf PCF, et al. Bleach activates a redox-regulated chaperone by oxidative protein unfolding. *Cell* 2008; 135: 691-701. [\[Crossref\]](#)
12. Russell AD. Antibiotic and biocide resistance in bacteria: introduction. *J Appl Microbiol* 2002; 92(Suppl): 1S-3S. [\[Crossref\]](#)
13. Walker JT, Dickinson J, Sutton JM, et al. Cleanability of dental instruments--implications of residual protein and risks from Creutzfeldt-Jakob disease. *Br Dent J* 2007; 203: 395-401. [\[Crossref\]](#)
14. Hulsmann M, Hahn W. Complications during root canal irrigation--literature review and case reports. *Int Endod J* 2000; 33: 186-93. [\[Crossref\]](#)
15. Wong DT, Cheung GS. Extension of bactericidal effect of sodium hypochlorite into dentinal tubules. *J Endod* 2014; 40: 825-9. [\[Crossref\]](#)
16. Zan R, Kutlu G, Hubbezoglu I, et al. Bactericidal effects of various irrigation solutions against *staphylococcus aureus* in human root canal. *J Istanbul Univ Fac Dent* 2015; 49: 19-26. [\[Crossref\]](#)
17. Cornwell P, Arnold-Long M, Barss SB, et al. The use of Dakin's solution in chronic wounds: a clinical perspective case series. *J Wound Ostomy Continence Nurs* 2010; 37: 94-104. [\[Crossref\]](#)
18. Duarte B, Cabete J, Formiga A, et al. Dakin's solution: is there a place for it in the 21st century? *Int Wound J* 2017; 14: 918-20. [\[Crossref\]](#)
19. Fokkens WJ, Lund VJ, Mullol J, et al. European position paper on rhinosinusitis and nasal polyps 2012. *Rhinol Suppl* 2012; 23: 1-298.
20. Raza T, Elsherif HS, Zulianello L, et al. Nasal lavage with sodium hypochlorite solution in *Staphylococcus aureus* persistent rhinosinusitis. *Rhinology* 2008; 46: 15-22.
21. Institute for Laboratory Animal Research, Guide for the Care and Use of Laboratory Animals Eight Edition. Washington D. C.: National Academies Press; 2011.
22. Tiemann A, Hofmann GO, Krukemeyer MG, et al. Histopathological osteomyelitis evaluation score (HOES) - an innovative approach to histopathological diagnostics and scoring of osteomyelitis. *GMS Interdiscip Plast Reconstr Surg DGPW* 2014; 3: DOI: 10.3205/ijprs000049.
23. Aytekin K, Erhan SŞ, Erişgin Z, et al. Intra-articular injection of hydrogen sulfide decreased the progression of gonarthrosis. *Can J Physiol Pharmacol* 2018; 97: 47-54. [\[Crossref\]](#)
24. Pashley EL, Birdsong NL, Bowman K, et al. Cytotoxic effects of NaOCl on vital tissue. *J Endod* 1985; 11: 525-8. [\[Crossref\]](#)
25. Aslan B, Kalaycı A, Ilgaz C, et al. Farklı konsantrasyonlarda hazırlanmış sodyum hipoklorit solüsyonlarının kobay cilt altı bağ doku reaksiyonları. *Türkiye Klinikleri Journal of Dental Sciences* 1997; 3: 47-50.
26. Heling I, Rotstein I, Dinur T, et al. Bactericidal and cytotoxic effects of sodium hypochlorite and sodium dichloroisocyanurate solutions in vitro. *J Endod* 2001; 27: 278-80. [\[Crossref\]](#)
27. Augustin G, Davila S, Mihoci K, et al. Thermal osteonecrosis and bone drilling parameters revisited. *Arch Orthop Trauma Surg* 2008; 128: 71-7. [\[Crossref\]](#)
28. Chiamonti AM, Robertson AD, Nguyen TP, et al. Pulsatile lavage of musculoskeletal wounds causes muscle necrosis and dystrophic calcification in a rat model. *J Bone Joint Surg Am* 2017; 99: 1851-8. [\[Crossref\]](#)
29. Hidalgo E, Bartolome R, Dominguez C. Cytotoxicity mechanisms of sodium hypochlorite in cultured human dermal fibroblasts and its bactericidal effectiveness. *Chem Biol Interact* 2002; 139: 265-82. [\[Crossref\]](#)
30. Sawada K, Caballe-Serrano J, Bosshardt DD, et al. Antiseptic solutions modulate the paracrine-like activity of bone chips: differential impact of chlorhexidine and sodium hypochlorite. *J Clin Periodontol* 2015; 42: 883-91. [\[Crossref\]](#)
31. Willy C, Scheuermann-Poley C, Stichling M, et al. [Importance of wound irrigation solutions and fluids with antiseptic effects in therapy and prophylaxis: Update 2017]. *Unfallchirurg* 2017; 120: 549-60. [\[Crossref\]](#)
32. Kerbl FM, DeVilliers P, Litaker M, et al. Physical effects of sodium hypochlorite on bone: an ex vivo study. *J Endod* 2012; 38: 357-9. [\[Crossref\]](#)
33. Aboltins CA, Page MA, Busing KL, et al. Treatment of staphylococcal prosthetic joint infections with debridement, prosthesis retention and oral rifampicin and fusidic acid. *Clin Microbiol Infect* 2007; 13: 586-91. [\[Crossref\]](#)
34. Meehan AM, Osmon DR, Duffy MC, et al. Outcome of penicillin-susceptible streptococcal prosthetic joint infection treated with debridement and retention of the prosthesis. *Clin Infect Dis* 2003; 36: 845-9. [\[Crossref\]](#)
35. Azzam KA, Seeley M, Ghanem E, et al. Irrigation and debridement in the management of prosthetic joint infection: traditional indications revisited. *J Arthroplasty* 2010; 25: 1022-7. [\[Crossref\]](#)