

The Protective Effects of *Momordica Charantia* Fruit Extract in Methotrexate Induced Liver Damage in Rats

✉ Dilek Özbeyli¹, ✉ Ali Şen², ✉ Özge Çevik³, ✉ Ömer Erdoğan³, ✉ Özlem Tuğçe Çilingir Kaya⁴, ✉ Seren Ede⁵, ✉ Göksel Şener⁵

¹Department of Pathology Laboratory Techniques, Marmara University Vocational School of Health Services, İstanbul, Turkey

²Department of Pharmacognosy, Marmara University Faculty of Pharmacy, İstanbul, Turkey

³Department of Biochemistry, Aydın Adnan Menderes University Faculty of Medicine, Aydın, Turkey

⁴Department of Histology and Embryology, Marmara University Faculty of Medicine, İstanbul, Turkey

⁵Department of Pharmacology, Fenerbahçe University Faculty of Pharmacy, İstanbul, Turkey

Abstract

BACKGROUND/AIMS: Methotrexate (MTX), a cytotoxic therapeutic agent, is used for the cure of malignancies and rheumatologic disorders. However, the significant side effects of MTX limits its use. In this study, we aim to assess the hepatoprotective properties of *Momordica charantia* (MC) against MTX-induced liver damaged in rats.

MATERIALS AND METHODS: Following one dose of MTX (20 mg/kg), the rats were given either distilled water or MC extract (300 mg/kg, po) for 5 days. After the dissection of the rats, the liver was removed to analyse tumour necrosis factor- α (TNF- α), interleukin-1 β (IL-1 β), transforming growth factor β (TGF- β) and 8-hydroxy-2'-deoxy-guanosine (8-OhdG) levels and superoxide dismutase (SOD), catalase (CAT), and caspase-3 activities. The tissues were also examined histopathologically.

RESULTS: The hepatic TNF- α , IL-1 β , TGF- β , 8-OhdG levels, and Caspase-3 activity in the MTX group were found to be significantly increased compared to the control group. However, MC extract was able to significantly decrease TNF- α , TGF- β , 8-OhdG levels, and Caspase-3 activity. Also, both the SOD and CAT activity of the MTX group decreased compared to the control group. Although only the SOD levels elevated significantly with MC treatment, the SOD and CAT activities of the MC treated group were similar to the control group. Supporting these biochemical parameters, MTX-induced histologic alterations in the liver were also ameliorated via MC treatment.

CONCLUSION: Our results demonstrated that MC has a protective role against MTX-induced hepatic tissue injury by reducing apoptosis, oxidative damage, and the expression of pro-inflammatory cytokines.

Keywords: Methotrexate, liver, *Momordica charantia*, oxidative stress, inflammation

To cite this article: Özbeyli D, Şen A, Çevik Ö, Erdoğan Ö, Çilingir Kaya ÖT, Ede S, Şener G. The Protective Effects of *Momordica Charantia* Fruit Extract in Methotrexate Induced Liver Damage in Rats. Cyprus J Med Sci 2022;7(6):787-793

ORCID IDs of the authors: D.Ö. 0000-0002-4141-6913; A.Ş. 0000-0002-2144-5741; Ö.Ç. 0000-0002-9325-3757; Ö.E. 0000-0002-8327-7077; Ö.T.Ç.K. 0000-0002-2591-9174; S.E. 0000-0002-3195-4064; G.Ş. 0000-0001-7444-6193.



Address for Correspondence: Dilek Özbeyli
E-mail: dilekcozbeyli@yahoo.com; dilekcozbeyli@marmara.edu.tr
ORCID ID: orcid.org/0000-0002-4141-6913

Received: 19.07.2020
Accepted: 23.12.2020



©Copyright 2022 by the Cyprus Turkish Medical Association / Cyprus Journal of Medical Sciences published by Galenos Publishing House.
Content of this journal is licensed under a Creative Commons Attribution 4.0 International License

INTRODUCTION

Methotrexate (MTX) is a folate antagonist chemotherapeutic drug used for the cure of various types of cancer (for instance acute osteosarcoma, leukaemia, breast, lung, and stomach cancers) and also rheumatologic disorders.^{1,2} The cytotoxic effect of MTX is based on the inhibition of the dihydrofolate reductase enzyme and thus inhibition of the purines and pyrimidines necessary for RNA and DNA synthesis. However, this cytotoxic effect is not only seen in the tumour cell but also in various organs such as the liver, kidney, ileum, and heart. Therefore, the side effects which occur in these organs limit the use of this drug.^{2,3}

As mentioned in the introduction section, MTX causes cellular arrest by inhibiting RNA and DNA synthesis. This effect is the direct cytotoxic effect of MTX. On the other hand, it has been demonstrated that MTX induced hepatotoxicity is related to oxidative stress caused by the generation of reactive oxygen species (ROS).⁴ ROS leads to mitochondria-related apoptosis^{2,5,6} and fibrosis⁷ in the liver cells. In MTX treated rats, mitochondrial dysfunction and the ROS induce cytokines to be released, such as tumour necrosis factor-alpha (TNF- α)^{6,8} and interleukin-1 β (IL-1 β).^{6,9}

Plants have been used for decades to treat various diseases and to prevent side effects of drugs. *Momordica charantia* (MC) fruits, widely grown in Asia and the Mediterranean region, have several bioactive compounds such as proteins, flavonoids, polysaccharides, triterpenoids, ascorbic acid, and steroids.¹⁰⁻¹² These compounds are known to have numerous biological impacts, for instance immunomodulators, antioxidants,¹²⁻¹⁴ antidiabetic,¹⁵ hepatoprotective,^{14,16} anti-apoptotic,¹⁷ and anti-inflammatory.^{10,18} Qader et al.¹³ demonstrated that MC extracts displayed no toxic effects in a 64 human lung cell fibroblast line. In CCl₄ treated rats, the MC Ucche variety has been shown to decrease lipid peroxidation, protein oxidation, nitric oxide production, and increased reduced glutathione (GSH) content and catalase (CAT) activity in liver tissues and plasma.¹⁴ Moreover, the amelioration of inflammation and tissue fibrosis by the Ucche variety was also shown histologically in these CCl₄ treated rat liver tissues.¹⁴ However, the protective effects of MC against the hepatotoxic effects of MTX on the liver is unknown.

In light of these data, we aimed to investigate whether aqueous MC extract is protective against MTX-induced liver damage by using biochemical and histological analysis.

MATERIALS AND METHODS

Materials

MC liquid aqueous extract was purchased from a local producer (Turkey).

Total Phenolic Compounds of the *Momordica Charantia* Extract

The whole phenolic compounds of the MC extract were determined as detailed by Gao et al.¹⁹ with minor alterations described by Yıldırım et al.²⁰

Activity Analysis of the *Momordica Charantia* Extract

In Vitro Antioxidant Activity

The 2,2-diphenyl-1-picrylhydrazyl (DPPH) and 2,2-azino-bis-3-ethylbenzothiazoline-6-sulfonic acid (ABTS) radical scavenging activities of the MC extract were determined similarly to Zou et al.²¹

In Vitro Anti-inflammatory Activity

The anti-inflammatory activity was measured similarly to Phosrithong and Nuchtavorn²² with minor alterations detailed by Yıldırım et al.²⁰.

Animals

Twenty-four Wistar albino rats (male, 200-250 g) were used in this study. The rats were housed under standard conditions (22 \pm 2 °C, 60-63% humidity) with a 12 hour light-12 hour dark period. The rats were kept ad libitum. The study procedures were approved by the Marmara University, Animal Experiments Local Ethics Commission, Istanbul-Turkey (approval number: 66. 2019.mar). This study was performed in Marmara University Experimental Animals Implementations and Researches Centre (DEHAMER, Istanbul-Turkey).

Experimental Design

The rats were assigned into 3 groups (n=24) as the control group (C), the MTX group (MTX), and the MTX + MC group. Each group was comprised of 8 rats. Liver toxicity was performed with one dose of MTX injection (20 mg/kg/ip; pharmaceuticals),⁹ while the MTX + MC group received MC extract at a dose of 300 mg/kg/po for the 5 following days. The control and MTX groups were given distilled water for 5 days by oral gavage at the same volume (Figure 1).

Biochemical Analyses of the Liver Tissue

Pro-inflammatory Cytokine Levels

The liver tissues were homogenized with 0.9% NaCl (Ultra Turrax homogenizer) and centrifuged at 1,500 xg at 4 °C for 10 min. The supernatants were collected and the TNF- α and IL-1 β levels were evaluated with enzyme-linked immunosorbent assay (ELISA) kit (Abbkine Rat TNF- α ELISA Kit, Cat. number: KET9007, China); Abbkine Rat IL-1 β ELISA Kit, Cat. number: KET9001, China).

Superoxide Dismutase and Catalase Activities

The Superoxide dismutase (SOD) and CAT activities of the liver were measured for anti-oxidative status evaluation. The tissues were homogenized with 0.9% NaCl and centrifuged at 1,500 xg at 4 °C for 10 minutes. The supernatants were collected and SOD and CAT level measurements were performed using the ELISA method in accordance with the manufacturer's prospectus using commercial kit (Abbkine Rat SOD ELISA Kit, Cat. No: KTE62765; Abbkine Rat Catalase ELISA Kit, Cat. number: KTE100847, China).

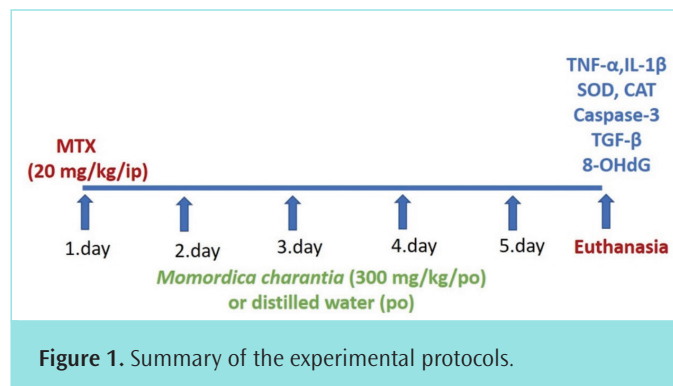


Figure 1. Summary of the experimental protocols.

Caspase-3 Activity and 8-hydroxy-2'-Deoxy-Guanosine (8-OhdG) Levels

The liver tissues were homogenized with 0.9% NaCl and centrifuged at 1,500 xg at 4 °C for 10 min. Caspase-3 activities in the collected supernatants were measured using a commercial kit via the manufacturer's procedure (Abbkine Rat Caspase-3 ELISA Kit, Cat. number: KTE100992, China).

The 8-OhdG levels were analysed as an indicator of oxidant DNA damage. DNA isolation was performed from the samples first (Invitrogen K182001). 8-OhdG levels were assessed with the aid of the DNA samples using the ELISA kit (8-OHDG ELISA Kit-Abbkine, Cat number: KTE100312, China).

Transforming Growth Factor-β Levels

TGF-β was measured as an indicator of fibrotic activity. Tissues were homogenized with 0.9% NaCl and centrifuged at 1,500 xg at 4 °C for 10 minutes. The upper phase was collected and the TGF-β levels in the samples were analysed using a commercial kit following the manufacturer's procedure using the ELISA method (Bioassay Technology Laboratory, Rat TGF-β ELISA Kit, Cat. number: E0778Ra, China).

Histological Procedure

The collected liver tissues were kept in 10% formaldehyde solution and they then underwent histologic preparation for light microscopic investigations. Concisely, the tissues were dehydrated by a series of alcohol solutions of increasing alcoholic concentrations (70%, 90%, 96%, and 100%) and cleared in xylene solution before being embedded in paraffin. The paraffin tissue blocks were sectioned to 5 μm in thickness by a rotary microtome (Leica RM2125RT) and mounted on glass slides. The hematoxylin and eosin dyed sections were analysed under a light microscope (Olympus BX51) and these sections were photographed using a digital camera system attached to the photomicroscope (Olympus DP72) for the evaluation of histopathological alterations.

Statistical Analysis

Statistical analysis was performed using Graphpad Prism 6.0 (Graphpad Software, San Diego, CA, USA). The biochemical data of groups were analysed by variance analysis (ANOVA) followed by Tukey multiple comparison tests. All data were expressed as mean ± standard error. Any variances were considered significant if $p < 0.05$.

RESULTS

In Vitro Anti-Inflammatory/Antioxidant Activities and Total Compounds of MC

Low IC₅₀ values (concentrations which eliminate 50% of the radical or stops the activity of the enzyme by 50%) indicate high activity. When Table 1 is examined, MC showed moderate antioxidant activities against

DPPH and ABTS radicals with IC₅₀ values of 3,132 and 2,463 mg/mL, respectively. In the anti-inflammatory activity experiment, MC exhibited good anti-lipoxygenase activity with an IC₅₀ value of 0.045 mg/mL. In addition, the activities of the extract were lower than the standards in all activity experiments. Also, the total phenol ingredient of the MC extract was found to be 3,440 mg/g as gallic acid equivalent (Table 1).

Pro-Inflammatory Cytokine Levels

The TNF-α and IL-1β levels of the MTX group were found to be significantly higher than in the control group ($p < 0.001$, $p < 0.05$, respectively). MC treatment decreased TNF-α elevation ($p < 0.05$) (Figure 2a). Although the IL-1β levels tended to decrease in the MTX + MC group, this was not statistically significant (Figure 2b).

SOD and CAT Activities

Both the SOD and CAT activities of the MTX group decreased compared to the control group ($p < 0.001$). Although the SOD levels were significantly elevated with MC treatment ($p < 0.05$), both were still lower than the control group (Figure 3a, b).

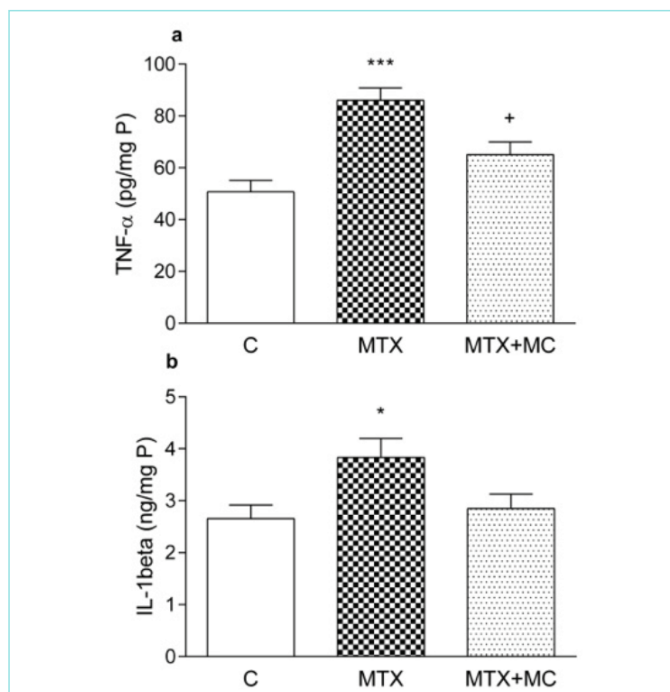


Figure 2. Tumour necrosis factor-α (TNF-α), and interleukin-1β (IL-1β) levels of the groups. Each group consisted of 8 animals. * $p < 0.05$, *** $p < 0.001$: versus the control group, + $p < 0.05$: versus the MTX group. C: Control group, MTX: Methotrexate group, MC: *Momordica charantia* extract group.

Table 1. Anti-inflammatory/antioxidant activities and total compound content of MC

Assays	MC*	Ascorbic acid	Trolox	Indomethacin
DPPH activity (IC ₅₀ , mg/mL)	3.132±0.004 ^b	0.018±0.000 ^a	-	-
ABTS activity (IC ₅₀ , mg/mL)	2.463±0.006 ^b		0.080±0.001 ^a	-
Anti-lipoxygenase activity (IC ₅₀ , mg/mL)	0.045±0.001 ^b		-	0.022±0.001 ^a
Total phenolic content** (mg GAE/g extract)	3.440±0.080		-	-

*MC: *Momordica charantia* extract; **Total phenolic content was expressed as 4 (GAE); ***Each value in the table is represented as mean ± standard deviation (n=3). Different letter superscripts in the same line indicate significant differences ($p < 0.05$). DPPH: 2,2-diphenyl-1-picrylhydrazyl.

Caspase-3 Activity and 8-OHdG Levels

Although Caspase-3 activity and 8-OHdG levels were increased with MTX ($p < 0.01$; $p < 0.001$, respectively), MC treatment reduced both of these levels ($p < 0.05$) (Figure 4a, b).

TGF- β Levels

While TGF- β levels increased with MTX ($p < 0.05$), MC treatments reduced these levels ($p < 0.01$) (Figure 5).

Histopathologic Evaluation

After examination of the stained liver sections, the control group was seen to have regular liver parenchyma (Figure 6a). The MTX-treated group had an increased number of Kupffer cells, dilated sinusoidal spaces, irregularly organized hepatocytes with cytoplasmic degeneration, and congestive central vein surrounded by inflammatory connective tissue (Figure 6b, c). These findings showed a prominent regeneration with MC treatment. Hepatocytes with normal cytoplasmic appearance, well-organized in regular liver parenchyma were observed in the MTX + MC group, however, in some regions, dilated sinusoids were seen (Figure 6d, e).

DISCUSSION

The results of the current study revealed that MTX leads to liver damage, as assessed by increased pro-inflammatory cytokines TNF- α and IL-1 β , pro-apoptotic Caspase-3, fibrotic activity indicator TGF- β , oxidative DNA marker 8-OHdG levels, and decreased antioxidant enzyme SOD and CAT activities. Moreover, histopathologic alterations indicated prominent

hepatic injury. However, MC extract showed significant beneficial effects in the MTX-induced hepatotoxicity model as was shown biochemically and histologically.

TNF- α and IL-1 β pro-inflammatory cytokines are immediately released after tissue injury and both of them play essential roles in the inflammatory reaction.²³ It has been reported that there are increased hepatic TNF- α ^{24,25} and IL-1 β levels²⁴ with MTX administration. In agreement with earlier studies, in our study, MTX caused a significant increase in the pro-inflammatory cytokines TNF- α and IL-1 β . However, increased TNF- α levels in the liver tissue following MTX administration were reversed by MC treatment, and IL-1 β levels also tended to decrease. In the neuropathic pain model, Jain et al.²⁶ demonstrated that MC reduced inflammation and pain in the sciatic nerve tissue by lowering TNF- α levels. Raish²⁷ also demonstrated that MC decreased TNF- α levels in cardiac tissue in a myocardial infarction model. Our results support these previous studies.

MTX application has previously been shown to cause oxidative DNA damage in liver cells.²⁸ Consistent with this report, our data showed that MTX increased 8-OHdG levels in liver tissue. However, in a previous study, it was reported that plasma 8-OHdG levels decreased with MC treatment.²⁹ The decreased 8-OHdG levels with the MC treatment which we found in our study supports this previous study. This decrease in 8-OHdG levels may be due to the moderate free radical scavenging activity of MC and an increase in SOD enzyme activity.

MTX administration leads to triggers of Caspase-3 mediated apoptosis.^{17,24} Kim et al.³⁰ reported that MC reduces pro-apoptotic protein Caspase-3

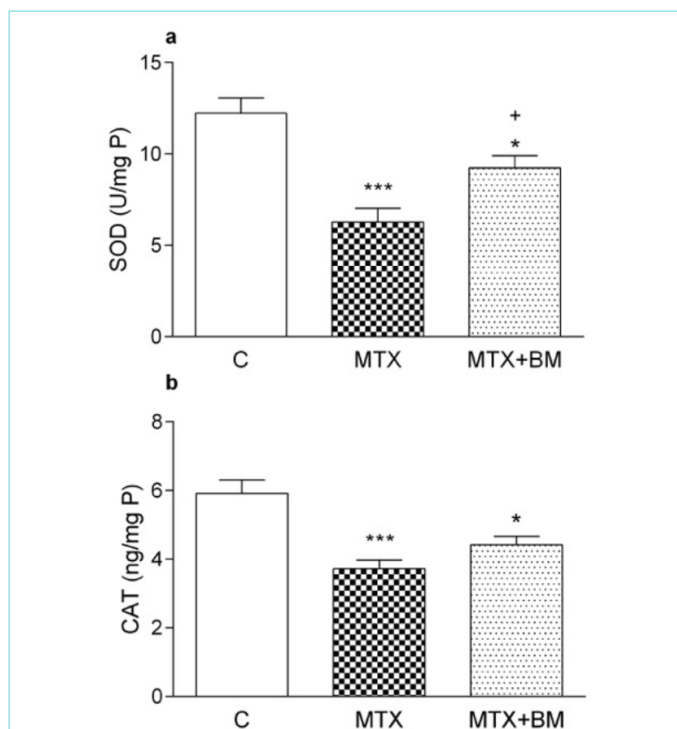


Figure 3. Superoxide dismutase (SOD), catalase (CAT) activities of the groups. Each group consisted of 8 animals. * $p < 0.05$, *** $p < 0.001$: versus the control group, + $p < 0.05$: versus the MTX group. C: Control group, MTX: Methotrexate group, MC: *Momordica charantia* extract group.

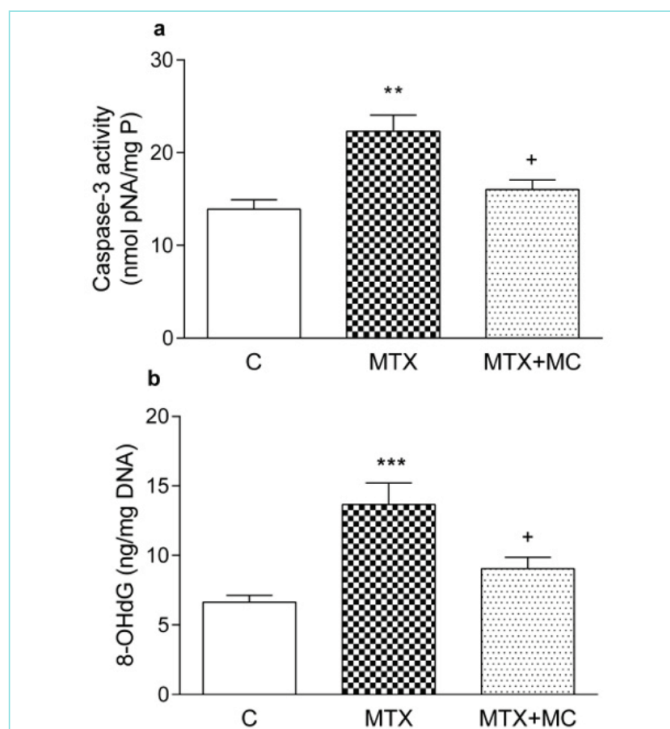


Figure 4. Caspase-3 and 8-hydroxy-2'-deoxy-guanosine (8-OHdG) activities of the groups. Each group consisted of 8 animals. ** $p < 0.01$, *** $p < 0.001$: versus the control group, + $p < 0.05$: versus the MTX group. C: Control group, MTX: Methotrexate group, MC: *Momordica charantia* extract group.

in human neuroblastoma SK-N-MC cells, liver cells,^{5,31} and brain cells.³² This decrease in Caspase-3 with MC therapy supports previous studies showing the anti-apoptotic effects of MC.

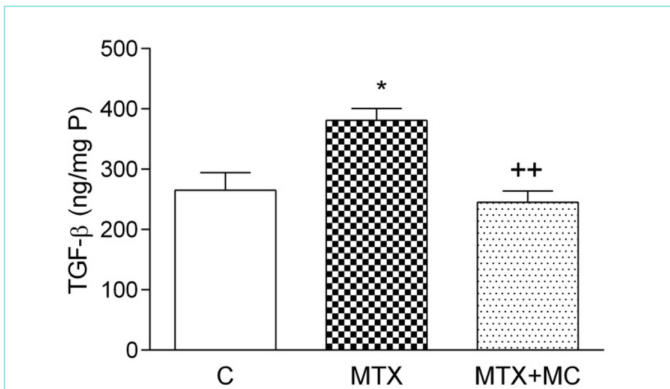


Figure 5. Transforming growth factor- β (TGF- β) levels of the groups. Each group consisted of 8 animals. * $p < 0.05$: versus the control group, ** $p < 0.01$: versus the MTX group C: Control group, MTX: Methotrexate group, MC: *Momordica charantia* extract group.

MTX is stored in the form of polyglutamate in the cell, however, in the long-term, MTX-polyglutamates accumulate and cause a decrease in folate levels. It has been understood that high levels of MTX polyglutamates are responsible for toxicities in the liver. In addition, by inhibiting dihydrofolate reductase, thymidylate synthesis and thus DNA synthesis is suppressed by MTX. Furthermore, MTX causes inhibition of nicotinamide adenosine diphosphate [NAD (P)]-dependent dehydrogenases and lowers NADPH levels in the cell. Since the maintenance of GSH in the cell in reduced form takes place via NADPH with the enzyme GSH-reductase, in the case of decreased NADPH, lower levels of reduced GSH increases susceptibility to oxidant damage.³³ It has been reported that MTX triggers oxidative stress both by raising free radicals and also by suppressing the antioxidant system.^{24,34} Cetin et al.³⁴ demonstrated that MTX causes decreased SOD and CAT enzyme activities in the liver tissue. In the present study, MTX administration considerably decreased SOD and CAT activities in the liver tissues. SOD activity was partially reversed by MC treatment, and CAT enzyme activity tended to increase. According to the literature, it was shown that MC has an elevating effect on SOD and CAT activity in the alcoholic fatty liver in mice.³⁵ Additionally, aqueous and ethanol extracts of MC have been shown to decrease SOD activity in mice in a high-fat diet model.³⁶

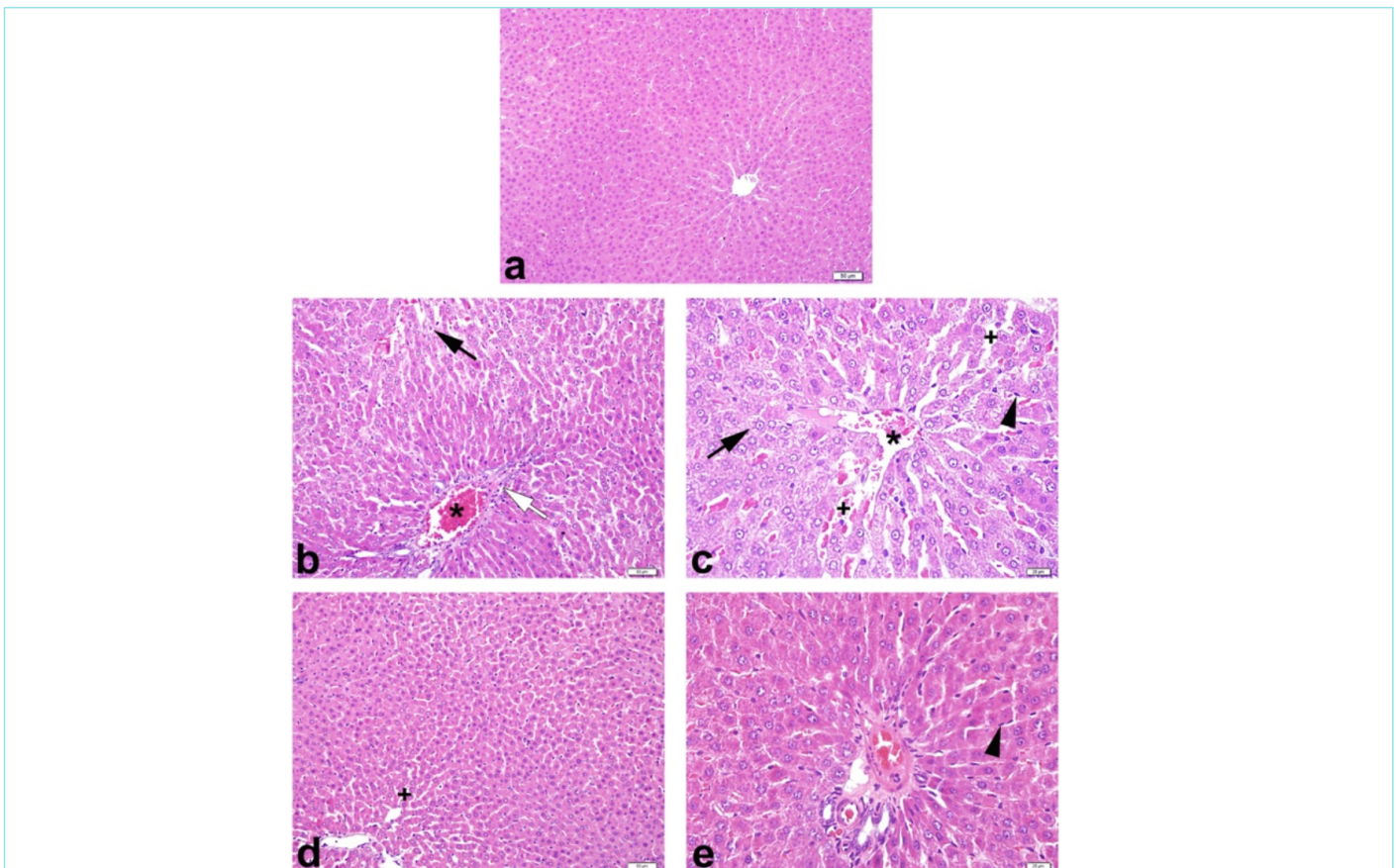


Figure 6. Demonstrative micrographs of liver tissues from the experimental groups. (a) The Control group: Regular hepatocyte organization, intact sinusoids, and Kupffer cells in normal numbers were seen. (b, c) The MTX group: Hepatocytes, which have cytoplasmic loss (arrow), irregularly organized in the liver parenchyma, dilated sinusoids (+), congestive central vein (*) surrounded by fibrotic connective tissue (white arrow) and an increased number of Kupffer cells (arrowhead) were observed. (d, e) The MTX + MC group: Hepatocytes showing regular cytoplasmic morphology in well-ordered liver parenchyma and reorganized normal sinusoidal arrays were noticed. Each group consisted of 8 animals. C: Control group, MTX: Methotrexate group, MC: *Momordica charantia* extract group.

MC has been shown to reduced inflammation and tissue fibrosis in a CCl₄ induced liver injury.¹⁴ Similarly, in our study, an MTX-induced increase in TGF- β was decreased with MC therapy, which demonstrated its antifibrotic activity. Furthermore, histopathological evaluations confirmed the hepatoprotective effect of MC against liver damage induced by MTX. Deng et al.¹⁶ histopathologically determined that MC extract had a significant protective effect on the liver structure in restraint-stressed mice.

The results obtained from the *in vitro* activity studies conducted in our current study also confirm the antioxidant and anti-inflammatory activity of MC. In this study, MC was found to have moderate antioxidant and strong anti-lipoxygenase activity. Previous phytochemical studies have shown that MC contains triterpene compounds, especially cucurbitane-type triterpenes, as their main compounds.³⁷⁻³⁹ In addition, some of these triterpene compounds have been reported to have significant antioxidant and anti-inflammatory activity.^{37,39} Therefore, these cucurbitane-type triterpenes together with other ingredients in MC may be responsible for the antioxidant and anti-inflammatory activity of MC. Also, in our current study, the total phenolic ingredient of MC extract was found to be low. The fact that MC is rich in triterpene compounds overlaps with this result.

CONCLUSION

This study proved that MC has a protective role in MTX-induced inflammation, apoptosis, oxidative DNA damage, and fibrotic activity by reducing the levels of TNF- α , Caspase-3, 8-OHdG, and TGF- β respectively in rat liver. Thus, MC may reduce hepatic damage. Further experiments are required to understand the molecular mechanisms of the protective effects that MC has in MTX-induced liver injury.

MAIN POINTS

- *Momordica charantia* displays good anti-lipoxygenase activity.
- *Momordica charantia* ameliorates methotrexate-induced inflammation, apoptosis, and oxidative DNA damage.
- *Momordica charantia* may reduce hepatic fibrotic activity.

ETHICS

Ethics Committee Approval: The study procedures were approved by the Marmara University, Animal Experiments Local Ethics Commission, İstanbul-Turkey (approval number: 66. 2019.mar). This study was performed in Marmara University Experimental Animals Implementations and Researches Centre (DEHAMER, İstanbul-Turkey).

Informed Consent: Patient approval has not been obtained as it is performed on animals.

Peer-review: Externally peer-reviewed.

Authorship Contributions

Concept: D.Ö., G.Ş., Design: D.Ö., G.Ş., Supervision: G.Ş., Fundings: D.Ö., G.Ş., Materials: D.Ö., G.Ş., Data Collection and/or Processing: D.Ö., A.Ş., Ö.Ç., S.E., G.Ş., Analysis and/or Interpretation: A.Ş., Ö.Ç., Ö.T.Ç.K., G.Ş., Literature Search: D.Ö., A.Ş., Ö.E., Writing: D.Ö., A.Ş., Ö.Ç., Ö.T.Ç.K., G.Ş., Critical Review: G.Ş.

DISCLOSURES

Conflict of Interest: No conflict of interest was declared by the authors

Financial Disclosure: The authors declared that this study had received no financial support.

REFERENCES

1. Malaviya AN. Landmark papers on the discovery of methotrexate for the treatment of rheumatoid arthritis and other systemic inflammatory rheumatic diseases: a fascinating story. *Int J Rheum Dis*. 2016; 19(9): 844-51.
2. Ali N, Rashid S, Nafees S, Hasan SK, Shahid A, Majed F, et al. Protective effect of Chlorogenic acid against methotrexate induced oxidative stress, inflammation and apoptosis in rat liver: An experimental approach. *Chem Biol Interact*. 2017; 25(272): 80-91.
3. Visser K, van der Heijde DM. Risk and management of liver toxicity during methotrexate treatment in rheumatoid and psoriatic arthritis: a systematic review of the literature. *Clin Exp Rheumatol*. 2009; 27(6): 1017-25.
4. Sener G, Kabasakal L, Yüksel M, Gedik N, Alican Y. Hepatic fibrosis in biliary-obstructed rats is prevented by Ginkgo biloba treatment. *World J Gastroenterol*. 2005; 11(35): 5444-9.
5. Lee HJ, Cui R, Choi SE, Jeon JY, Kim HJ, Kim TH, et al. Bitter melon extract ameliorates palmitate-induced apoptosis via inhibition of endoplasmic reticulum stress in HepG2 cells and high-fat/high-fructose-diet-induced fatty liver. *Food Nutr Res*. 2018; 62.
6. Ebrahimi R, Sepand MR, Seyednejad SA, Omidi A, Akbariani M, Gholami M, et al. Ellagic acid reduces methotrexate-induced apoptosis and mitochondrial dysfunction via up-regulating Nrf2 expression and inhibiting the I κ B α /NF κ B in rats. *Daru*. 2019; 27(2): 721-33.
7. Cao Y, Shi H, Sun Z, Wu J, Xia Y, Wang Y, et al. Protective effects of magnesium glycyrrhizinate on methotrexate-induced hepatotoxicity and intestinal toxicity may be by reducing COX-2. *Front Pharmacol*. 2019; 25(10): 119.
8. Abdelaziz RM, Abdelazem AZ, Hashem KS, Attia YA. Protective effects of hesperidin against MTX-induced hepatotoxicity in male albino rats. *Naunyn Schmiedebergs Arch Pharmacol*. 2020; 393(8): 1405-17.
9. Çakır T, Baştürk A, Polat C, Aslaner A, Durgut H, Şehirli AÖ, et al. Does alpha lipoic acid prevent liver from methotrexate induced oxidative injury in rats? *Acta Cir Bras*. 2015; 30(4): 247-52.
10. Jia S, Shen M, Zhang F, Xie J. Recent advances in momordica charantia: functional components and biological activities. *Int J Mol Sci*. 2017; 18(12): 2555.
11. Liu JQ, Chen JC, Wang CF, Qiu MH. New cucurbitane triterpenoids and steroidal glycoside from *Momordica charantia*. *Molecules*. 2009; 14(12): 4804-13.
12. Baldemir A, Ekinci K, İlğün S, Dalda A, Yetişir H. Evaluation of total phenolic contents and antioxidant capacities of *Momordica charantia* L. (Bitter gourd) Fruits. *Derim*. 2018; 35(1): 45-50.
13. Qader SW, Abdulla MA, Chua LS, Najim N, Zain MM, Hamdan S. Antioxidant, total phenolic content and cytotoxicity evaluation of selected Malaysian plants. *Molecules*. 2011; 16(4): 3433-43.
14. Sagor AT, Chowdhury MR, Tabassum N, Hossain H, Rahman MM, Alam MA. Supplementation of fresh ucche (*Momordica charantia* L. var. *muricata* Willd) prevented oxidative stress, fibrosis and hepatic damage in CCl₄ treated rats. *BMC Complement Altern Med*. 2015; 15: 115.
15. Xu X, Shan B, Liao CH, Xie JH, Wen PW, Shi JY. Anti-diabetic properties of *Momordica charantia* L. polysaccharide in alloxan-induced diabetic mice. *Int J Biol Macromol*. 2015; 81: 538-43.

16. Deng Y, Tang Q, Zhang Y, Zhang R, Wei Z, Tang X, et al. Protective effect of *Momordica charantia* water extract against liver injury in restraint-stressed mice and the underlying mechanism. *Food Nutr Res.* 2017; 61(1): 1348864.
17. Raish M, Ahmad A, Ansari MA, Alkharfy KM, Aljenuobi FI, Jan BL, et al. *Momordica charantia* polysaccharides ameliorate oxidative stress, inflammation, and apoptosis in ethanol-induced gastritis in mucosa through NF- κ B signaling pathway inhibition. *Int J Biol Macromol.* 2018; 111: 193-9.
18. Zeng Y, Guan M, Li C, Xu L, Zheng Z, Li J, et al. Bitter melon (*Momordica charantia*) attenuates atherosclerosis in apo-E knock-out mice possibly through reducing triglyceride and anti-inflammation. *Lipids Health Dis.* 2018; 17(1): 251.
19. Gao X, Ohlander M, Jeppsson N, Björk L, Trajkovski V. Changes in antioxidant effects and their relationship to phytonutrients in fruits of sea buckthorn (*Hippophae rhamnoides* L.) during maturation. *J Agric Food Chem.* 2000; 48(5): 1485-90.
20. Yıldırım A, Şen A, Doğan A, Bitis L. Antioxidant and anti-inflammatory activity of capitula, leaf and stem extracts of *Tanacetum ciliatum* (Boiss.) Grierson. *Int J Sec Metabolite.* 2019; 6(2): 211-22.
21. Zou YH, Liu WT, Zhang JX, Xiang DC. Triterpenoids from the bark of *Dysoxylum hainanense* and their anti-inflammatory and radical scavenging activity. *Fitoterapia.* 2017; 121: 159-63.
22. Phosrithong N, Nuchtavorn N. Antioxidant and anti-inflammatory activities of *Clerodendrum* leaf extracts collected in Thailand. *European Journal of Integrative Medicine.* 2016; 8(3): 281-5.
23. Trunkey D. *Current Therapy of Trauma and Surgical Critical Care 2nd Edition* Imprint: Elsevier; 2015.
24. Al Kury LT, Dayyan F, Ali Shah F, Malik Z, Khalil AAK, Alattar A, et al. ginkgo biloba extract protects against methotrexate-induced hepatotoxicity: a computational and pharmacological approach. *Molecules.* 2020; 25(11): E2540.
25. Owumi SE, Ajiola IJ, Agbeti OM. Hepatorenal protective effects of protocatechuic acid in rats administered with anticancer drug methotrexate. *Hum Exp Toxicol.* 2019; 38(11): 1254-65.
26. Jain V, Pareek A, Paliwal N, Ratan Y, Jaggi AS, Singh N. Antinociceptive and antiallodynic effects of *Momordica charantia* L. in tibial and sural nerve transection-induced neuropathic pain in rats. *Nutr Neurosci.* 2014; 17(2): 88-96.
27. Raish M. *Momordica charantia* polysaccharides ameliorate oxidative stress, hyperlipidemia, inflammation, and apoptosis during myocardial infarction by inhibiting the NF- κ B signaling pathway. *Int J Biol Macromol.* 2017; 97: 544-51.
28. Ekinci-Akdemir FN, Yıldırım S, Kandemir FM, Gülçin İ, Küçükler S, Sağlam YS, et al. The effects of casticin and myricetin on liver damage induced by methotrexate in rats. *Iran J Basic Med Sci.* 2018; 21(12): 1281-8.
29. Cevik O, Akpınar H, Oba R, Cilingir OT, Ozdemir ZN, Cetinel S, Yoldemir T. The effect of *Momordica charantia* intake on the estrogen receptors ESR α /ESR β gene levels and apoptosis on uterine tissue in ovariectomy rats. *Mol Biol Rep.* 2015; 42(1): 67-177.
30. Kim KB, Lee S, Kang I, Kim JH. *Momordica charantia* Ethanol Extract Attenuates H₂O₂-Induced Cell Death by Its Antioxidant and Anti-Apoptotic Properties in Human Neuroblastoma SK-N-MC Cells. *Nutrients.* 2018; 10(10): 1368.
31. Saad DY, Soliman MM, Baiomy AA, Yassin MH, El-Sawy HB. Effects of Karela (Bitter Melon; *Momordica charantia*) on genes of lipids and carbohydrates metabolism in experimental hypercholesterolemia: biochemical, molecular and histopathological study. *BMC Complement Altern Med.* 2017; 17(1): 319.
32. Duan ZZ, Zhou XL, Li YH, Zhang F, Li FY, Su-Hua Q. Protection of *Momordica charantia* polysaccharide against intracerebral hemorrhage-induced brain injury through JNK3 signaling pathway. *J Recept Signal Transduct Res.* 2015; 35(6): 523-9.
33. Friedman B, Cronstein B. Methotrexate mechanism in treatment of rheumatoid arthritis. *Joint Bone Spine.* 2019; 86(3): 301-7.
34. Cetin A, Kaynar L, Kocyigit I, Hacioglu SK, Saraymen R, Ozturk A, et al. Role of grape seed extract on methotrexate induced oxidative stress in rat liver. *Am J Chin Med.* 2008; 36(5): 861-72.
35. Lu KH, Tseng HC, Liu CT, Huang CJ, Chyuan JH, Sheen LY. Wild bitter gourd protects against alcoholic fatty liver in mice by attenuating oxidative stress and inflammatory responses. *Food Funct.* 2014; 5(5): 1027-37.
36. Wang J, Ryu HK. The effects of *Momordica charantia* on obesity and lipid profiles of mice fed a high-fat diet. *Nutr Res Pract.* 2015; 9(5): 489-95.
37. Lin KW, Yang SC, Lin CN. Antioxidant constituents from the stems and fruits of *Momordica charantia*. *Food Chem.* 2011; 127(2): 609-14.
38. Chiy-Rong C, Yun-Wen L, Yueh-Hsiung K, Jue-Liang H, Chi-I C. Cucurbitane-Type Triterpenoids from *Momordica charantia*, Natural Product Communications. 2017; 12(6): 889-92.
39. Shivanagoudra SR, Perera WH, Perez JL, Athrey G, Sun Y, Jayaprakasha GK, et al. Cucurbitane-type compounds from *Momordica charantia*: Isolation, in vitro antidiabetic, anti-inflammatory activities and in silico modeling approaches. *Bioorg Chem.* 2019; 87: 31-42.