

## Letter and Reply

### Preservation of renal function: the spectrum of effects by calcium channel blockers

Sir,

I read with interest the article 'Preservation of renal function: the spectrum of effects by calcium channel blockers' [1]. Five years ago, I published a paper on follow-up of residual renal function in continuous ambulatory peritoneal dialysis (CAPD) patients [2] which obtained very similar results to those summarized in the review by Tarif and Bakris. Since that paper was published in Spanish, I would like to take this opportunity to present a brief summary of the results to corroborate the idea that dihydropyridine calcium channel blockers (DHPCCBs) do not confer protection to the kidney in diabetic nephropathy. On the contrary, these agents could accelerate the loss of renal function especially in diabetic patients on peritoneal dialysis.

In the study we performed [2], 38 patients for whom CAPD was the first dialytic therapy, maintained on peritoneal dialysis for at least 3 years and with an initial diuresis > 100 ml/day were selected. After 2 years on CAPD, residual creatinine clearance (RCC) significantly declined from  $4.0 \pm 2.6$  to  $1.6 \pm 1.8$  ml/min ( $P < 0.01$ ). At this time, only 50% of the patients showed RCC values > 1 ml/min. Diabetic patients had a higher RCC than non-diabetics ( $5.8 \pm 3$  vs  $3.1 \pm 1.8$ ,  $P < 0.01$ ) when starting CAPD. After 1 and 2 years on CAPD, diabetic patients showed a more severe decline in RCC than non-diabetics ( $-1.8 \pm 3.1$  vs  $-0.8 \pm 1.5$  ml/min/year for the first year, and  $-4.9 \pm 3.2$  vs  $-0.9 \pm 2.0$  ml/min/year, for the second year, both  $P < 0.01$ ). Gender, daily protein intake estimated by nPCR, weight, blood pressure, incidence of peritonitis, administration of nephrotoxic antibiotics, serum biochemistry and peritoneal function data did not show any influence in the slope of RCC loss. However, the patients receiving calcium channel blockers (nifedipine), showed a more significant decrease in RCC than those not receiving these drugs ( $-3.1 \pm 3.1$  vs  $-1.0 \pm 2.2$  ml/min/year,  $P < 0.05$ ). This difference was more impressive in diabetics albeit with a similar control of blood pressure. The decrease in RCC in this particular group between the first and the second year on CAPD was  $-2.5 \pm 1.8$  (for those not receiving DHPCCBs) vs  $-4.2 \pm 2.3$  ml/min/year (for those receiving DHPCCBs) ( $P < 0.01$ ). Angiotensin-converting enzyme inhibitors and  $\beta$ -blockers showed no influence on these parameters.

Although our results were obtained in patients on dialysis, it is recognized that preservation of renal function is a characteristic of peritoneal dialysis for reasons not well clarified at the present. Our data support the contention that pharmacological agents may play an important role in determining the residual renal function outcome. The coincidence with the data of Tarif and Bakris [1] reinforce the existence of a particular action of DHPCCBs on glomerular permeability independent of their effects on blood pressure. The vasodilation of afferent arterioles induced by these agents could cause an increase in glomerular membrane permeability to plasma proteins which are able to accelerate mesangial sclerosis. In the case of spontaneous outcome of diabetic nephropathy, this has been recognized as particularly relevant.

Once this concept is generally accepted by the international scientific community, DHPCCBs should be withdrawn from use in patients with advanced renal disease, especially in cases of diabetic nephropathy. It should be investigated whether or not earlier stages of this nephropathy are also affected negatively by these agents.

Hospital Universitario de la Princesa  
Servicio de Nefrología  
c/ Diego de León, 62  
E-28006 Madrid, Spain

R. Selgas

1. Tarif N, Bakris GL. Preservation of renal function: the spectrum of effects by calcium-channel blockers. *Nephrol Dial Transplant* 1997; 12: 2244–2250
2. Borrego F, Selgas R, de Alvaro F *et al.* Seguimiento de la función renal residual en pacientes en diálisis peritoneal continua ambulatoria

### Reply

Sir,

We read with interest the letter by Dr Selgas. We were not aware that data on renal function decline with dihydropyridine calcium antagonists (DHPCAs) were available from patients with end-stage renal disease. While the author's data corroborate our own, his plea for studies to evaluate these antihypertensive agents in earlier stages of diabetic nephropathy, while warranted, will never be met. This is true for two reasons: first, in order to evaluate fully the effects of DHPCAs on renal disease progression, i.e. time to dialysis, in patients with microalbuminuria whose serum creatinine is < 1.5 mg/dl, > 3000 patients followed for a minimum of 7 years would be required. Second, funding this type of project would be quite difficult. Consequently, the feasibility of such a study, especially in light of data from the recent ABCD and FACET trials, is remote [1,2]. I must also add that the recently completed clinical trial in hypertensive non-diabetic patients without nephropathy i.e. the Hypertension Optimal Treatment (HOT) trial utilized a DHPCA to lower blood pressure and was not stopped earlier due to cardiovascular events. Also, the ongoing 40 000 patient ALLHAT trial has not been stopped, thus far, due to abnormally high cardiovascular events. Thus, it appears that the people who fail to be protected against renal or cardiovascular events are those with pre-existing diabetic nephropathy. Lastly, it should also be noted that fixed dose combinations of an angiotensin-converting enzyme (ACE) inhibitor with a DHPCA have shown renal protection whereas the DHPCA alone, in spite of blood pressure reduction, has failed to show such protection [3]. This is not true for non-DHPCAs (verapamil or diltiazem) that potentiate antiproteinuric effects of ACE inhibitors as well as renal protection [4]. Thus, it appears that once renal disease is present, especially in the presence of diabetes, DHPCAs should either not be used or used with ACE inhibitor to lower blood pressure.

Department of Preventive Medicine  
Luke's Medical Center  
1725 W. Harrison Street  
Chicago, IL 60612, USA

George L. Bakris

1. Tatti P, Guarisco R, Pahor M, Strollo G, Byington RP, Strollo F, Di Mauro P. Outcome results of the fosinopril versus amlodipine cardiovascular events randomized trial (FACET) in patients with hypertension and NIDDM. *Diabetes Care* 1998; 21: 597–602
2. Estacio RO, Jeffers BW, Hiatt WR, Biggerstaff SL, Gifford N, Schrier RW. The effect of nisoldipine as compared with enalapril on cardiovascular outcomes in patients with non-insulin-dependent diabetes and hypertension. *N Engl J Med* 1998; 338: 645–652
3. Bakris GL, Griffin KA, Picken MM, Bidani AK. Combined effects of an angiotensin converting enzyme inhibitor and a calcium antagonist on renal injury. *J Hypertension* 1997; 15: 1181–1185
4. Bakris GL. Combination therapy for hypertension and renal disease in diabetes. In Mogensen CE, ed. *The Kidney and Hypertension in Diabetes Mellitus*. 3rd edn. Kluwer Academic, Boston: 1997: 561–568

## Letters

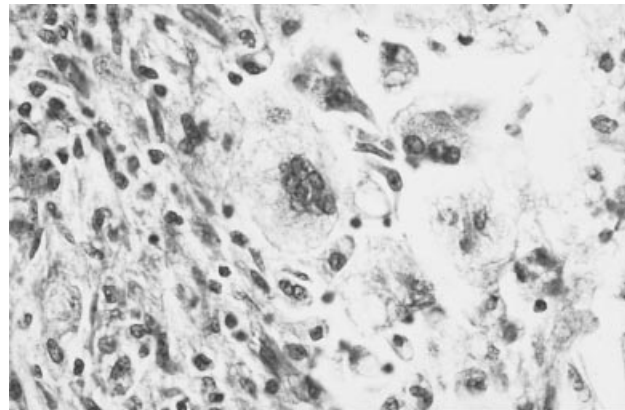
### Systemic amyloidosis secondary to xantogranulomatous pyelonephritis

Sir,

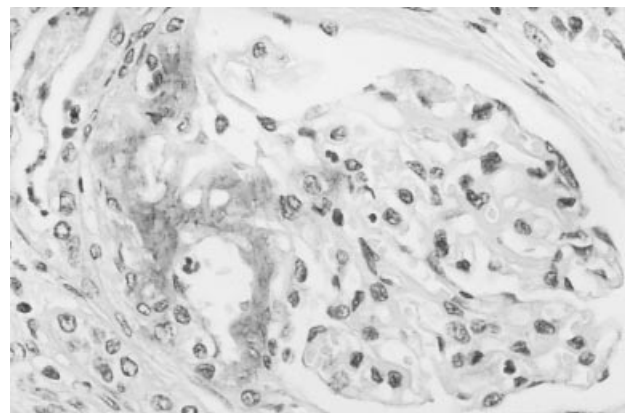
We have read the interesting paper of Mazuecos *et al.* about the association of secondary amyloidosis with chronic infections of the kidney [1]. In this report, the authors described four cases of amyloidosis associated with chronic infected kidneys and only one associated with xantogranulomatous pyelonephritis. This association is very infrequent and to our knowledge only seven patients with xantogranulomatous pyelonephritis and AA-amyloidosis have been described to date [1–5]. We report a new case of secondary amyloidosis associated with xantogranulomatous pyelonephritis.

A 74-year-old woman presented with a history of recurrent, bilateral renal colics and urinary tract infections, some years ago, with persistent positive urinary cultures by *E. coli* and others Gram-negative bacilli. Recently she had developed oedema and moderate arterial hypertension. She was admitted to our hospital because of fever, chills, hypotension and renal impairment (serum creatinine 4 mg/dl). Ultrasonography revealed a calculus in the right ureter, destructed parenchyma and multiple scattered abscesses on the right kidney. The left kidney was hydronephrotic due to high ureteral lithiasis. Urgent surgery was performed, i.e. nephrectomy of the right kidney and double-J catheter drainage of the left ureter. Septic symptoms and renal function improved soon after nephrectomy and antibiotic therapy. However she presented massive proteinuria and hypoalbuminemia. The nephrectomy piece showed diffuse infiltration with foamy, lipid-filled macrophages typical of a xantogranulomatous pyelonephritis (Figure 1). We looked for amyloid deposits because of nephrotic proteinuria. After Congo Red staining, reddish pink deposits were found in glomeruli, vessels and interstitium; furthermore with immunohistochemical stain using antiserum against AA amyloid protein combined with immunoperoxidase, protein AA was found in the above structures (Figure 2). During follow-up, she was treated with ACE inhibitors and diuretics. Renal function was stabilized and blood pressure controlled. Proteinuria decreased, and 6 months later the nephrotic syndrome remitted (proteinuria 1 g/day). Moreover, she developed overt hypercalcaemia (11–12 mg/dl) with elevated serum levels of parathyroid hormone, suggesting primary hyperparathyroidism.

The appearance of significant proteinuria in patients with persistently obstructed and infected kidneys should alert the clinician to the possibility of secondary amyloidosis, as noted in our patient [1]. It is necessary to look for amyloid deposits in nephrectomy specimens, using adequate techniques [2]. Alternatively, amyloid may be documented in subcutaneous



**Fig. 1.** Xantogranulomatous pyelonephritis. Inflammatory infiltration of the kidney, with foam cells and multinucleate giant cell. (H & E  $\times 20$ ).



**Fig. 2.** Glomerulus with deposition of AA protein (monoclonal antihuman amyloid A component, combined with immunoperoxidase staining, Dako Diagnostics,  $\times 40$ ).

fat or rectal biopsy [1,2,4]. The patients with this particular form of secondary amyloidosis have the following features: (i) history of lithiasis and recurrent urinary tract infection [1,3]; (ii) development of nephrotic range proteinuria with renal impairment, with a more aggressive evolution than in classic systemic amyloidosis [1]; (iii) coexistence of pyelonephritis and amyloid deposition in nephrectomy specimens [1,2,4], and (iv) improvement of proteinuria and renal insufficiency after removal of the infective focus by nephrectomy in almost all cases [1,2,4]. Our patient had all these

features, and probably nephrotic syndrome had remained undiagnosed before nephrectomy.

Servicio de Nefrología y Anatomía Patológica  
Hospital General  
Alicante  
Spain

F. Rivera  
J. J. Egea  
C. M. Gil  
M. Trigueros  
J. Olivares

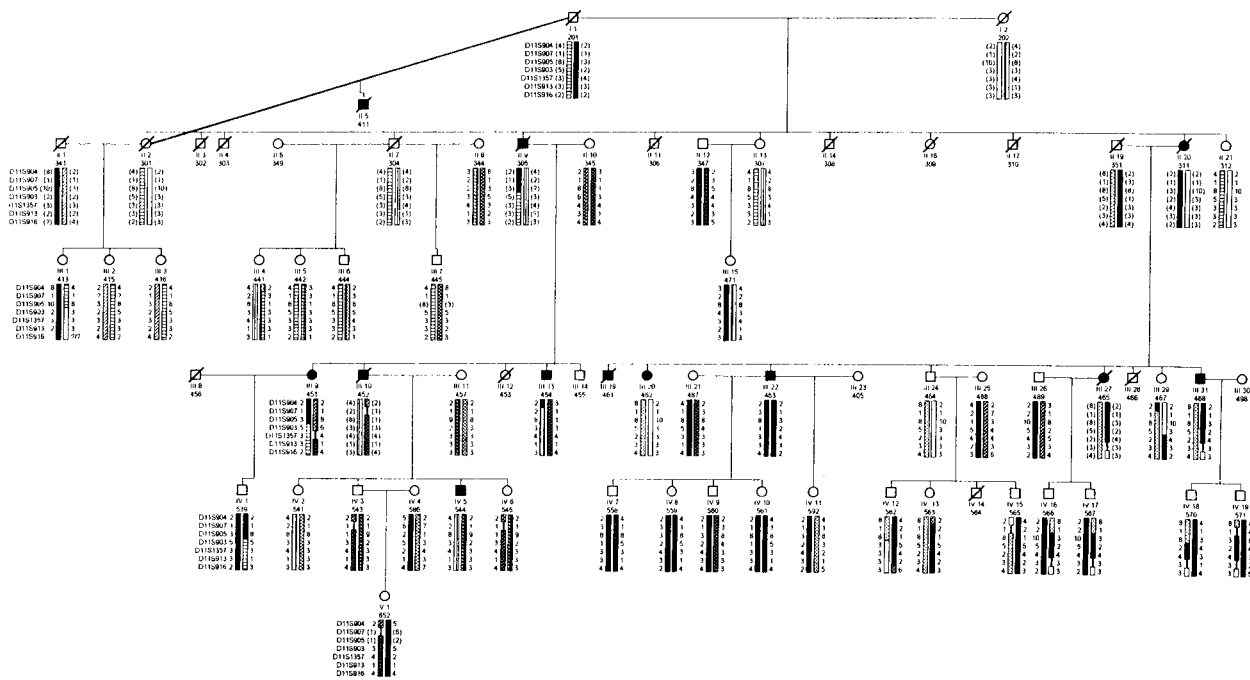
1. Mazuecos A, Araque A, Sánchez R *et al*. Systemic amyloidosis secondary to pyonephrosis. Resolution after nephrectomy. *Nephrol Dial Transplant* 1996; 11: 875–878
2. Querfeld U, Walderr R, Twittenhoff W, Möhring K, Schärer K. Generalized amyloidosis secondary to xantogranulomatous pyelonephritis. *Eur J Pediatr* 1986; 145: 565–568
3. Garber BB, Cendron M, Cohen R, Whitmore KE. Xantogranulomatous pyelonephritis and amyloidosis: a rare association. *J Urol* 1989; 142: 114–116
4. Lauzurica R, Felip A, Serra A *et al*. Xantogranulomatous pyelonephritis and systemic amyloidosis: report of 2 new cases and the natural history of this association. *J Urol* 1991; 146: 1603–1606
5. Bromsoms JM, Vallés H, Mas H, Sant F, Llobet M. Amiloidosis y pielonefritis xantogranulomatosa. *Nefrología* 1995; 15: 371

**Exclusion of the uteroglobin gene as a candidate for fibronectin glomerulopathy (GFND)**

Sir,  
Fibronectin glomerulopathy (GFND), a newly recognized autosomal dominant renal disease, is characterized by microalbuminuria, microscopic haematuria, hypertension, and renal tubular acidosis type IV [1]. End-stage renal disease arises in the second to fourth decades of life. Glomerular basement membranes show subendothelial deposits consisting predominantly of fibronectin deposits

visible by immunological and electronmicroscopic techniques. A recently described knock-out mouse model for the uteroglobin gene is very similar to the human GFND phenotype. In this animal model, lack of uteroglobin resulted in massive fibronectin and collagen deposits in the glomerulus. Uteroglobin was shown to exert both, a direct and an indirect effect on fibronectin–matrix assembly by formation of fibronectin–uteroglobin heteromers and by inhibition of phospholipase A2, with subsequent integrin activation [2]. These observations were in contrast to an earlier knock-out mouse model where mice homozygous for the null allele of the gene did not show gross physiological abnormalities [3].

This prompted us to examine the role of the human uteroglobin gene (*UGB*) [4], as a candidate gene for human GFND. In our study we performed haplotype analyses in a large Swiss pedigree [5,6] containing 12 affected individuals with GFND. Forty-three individuals were haplotyped by using seven consecutive polymorphic microsatellite DNA markers that span the genetic region of *UGB* in an interval of 44 cM on the sex-averaged map on human chromosome 11q11–q13. The microsatellite markers used [7] are localized in the following order pter-*D11S904*, *D11S907*, *D11S905*, *D11S903*, *D11S1357*, *D11S913*, and *D11S916*-qter, with the first and last markers flanking the *UGB* locus. Since the penetrance of the disease cannot be excluded with certainty in the younger generations, data were evaluated on the basis of an ‘affecteds-only’ strategy, in which affected individuals were examined for cosegregation of haplotypes. Haplotype analysis in this pedigree (Figure 1) revealed that none of the haplotypes identified cosegregated with the disease. If unaffected individuals were also taken into account, the absence of cosegregation was even more striking. Therefore the complete absence of cosegregation between GFND and haplotypes extending over a 44 cM interval on human



**Fig. 1.** Haplotype analyses with seven consecutive microsatellite markers of the *UGB* region of a large GFND pedigree. Siblings are depicted from left to the right with decreasing age. Affected individuals are indicated by black, solid symbols. Males are shown as squares, females as circles. Haplotype data were obtained for markers *D11S904*, *D11S907*, *D11S905*, *D11S903*, *D11S1357*, *D11S913*, and *D11S916*. Inferred haplotypes are shown in parenthesis. The paternal haplotype of every individual is represented by the left bar, the maternal haplotype by the right bar. There is no haplotype segment shared by all affected individuals, thereby excluding linkage to the *UGB* genetic region.

chromosome 11 excludes the uteroglobin gene from being the candidate gene for GFND in this kindred. Recently a high-affinity uteroglobin-binding protein on several cell types has been characterized [8]. Whether a defect in this putative receptor is responsible for GFND remains a possibility.

<sup>1</sup>University Children's Hospital  
Freiburg, Germany

Martin Vollmer<sup>1</sup>

Reto Krapf<sup>2</sup>

<sup>2</sup>Kantonsspital Bruderholz  
Switzerland

Friedhelm Hildebrandt<sup>1</sup>

1. Ström EH, Banfi G, Krapf R *et al.* Glomerulopathy associated with predominant fibronectin deposits. A newly recognized hereditary disease. *Kidney Int* 1995; 48: 163–170
2. Zhang Z, Kundu GC, Yuan C-J *et al.* Severe fibronectin-deposit renal glomerular disease in mice lacking uteroglobin. *Science* 1997; 276: 1408–1412
3. Stripp BP, Lund J, Mango GW *et al.* Clara cell secretory protein: a determinant of PCB bioaccumulation in mammals. *Am J Physiol* 1996; 271: L656–64
4. Zhang Z, Zimonjic DB, Popescu NC *et al.* Human uteroglobin gene. Structure, subchromosomal localization and polyphormism. *DNA and Cell Biol* 1997; 16: 73–83
5. Bürgin M, Hofmann E, Reutter FW *et al.* Familial glomerulopathy with giant fibrillar deposits. *Virchows Archiv [A]* 1980; 338: 313–326
6. Gemperle O, Neuweiler J, Reutter FW, Hildebrandt F, Krapf R. Familial fibrillary glomerulopathy. 15 year follow-up in a large kindred. *Am J Kidney Dis* 1996; 28: 668–675
7. Dib C, Faure S, Fizames C *et al.* A comprehensive map of the human genome based on 5264 microsatellites. *Nature* 1996; 380: iii–v
8. Kundu GC, Mantile G, Miele L, Cordella-Miele E, Mukherjee AB. Recombinant human uteroglobin suppresses cellular invasiveness via a novel class of high-affinity cell surface binding site. *Proc Natl Acad Sci USA* 1996; 93: 2915–2919

### Nephrotic syndrome associated with chronic lymphocytic leukaemia

Sir,

Whilst the association of nephrotic syndrome with neoplastic diseases, particularly carcinomas and lymphomas is well known [1], nephrotic syndrome associated with chronic lymphocytic leukaemia (CLL) is less common with an estimated incidence of 1–2% [2]. About 60 cases of glomerular lesions have been reported up until 1997 [1–5]. The most common glomerular lesion is membranoproliferative glomerulonephritis (MPGN) which accounts for approximately 45% of reported cases [2,3]. We report a case of CLL presenting with nephrotic syndrome in whom percutaneous renal biopsy not only revealed membranoproliferative glomerulonephritis (MPGN) type I but also focal areas of lymphocyte infiltration. Clinical manifestations of CLL and nephrotic syndrome resolved with chemotherapy consisting of cyclophosphamide, vincristine and prednisolone (CVP).

A 63-year-old woman presented to the outpatient clinic in July 1995 complaining of fatigue, anorexia, weight loss of 15 kg over the previous 8 months, and easy bruising. On physical examination the patient was pale and had bilaterally palpable rubbery axillary and inguinal lymph nodes, spleen enlargement, and moderate bilateral pretibial and ankle oedema.

Investigations revealed a haemoglobin of 8.6 g/dl, a white blood cell (WBC) count of  $92 \times 10^9/l$  with 95% mature lymphocytes, and a platelet count of  $324 \times 10^9/l$ . She also had renal impairment with a blood urea nitrogen (BUN) of 65 mg/dl, a serum creatinine of 2 mg/dl, and a serum albumin of 3 g/dl. The urinary sediment contained many red blood

cells, and 5–6 WBC per HPF, with fine granular casts. The urinary protein excretion was 6 g/24 h. Bone marrow aspiration and biopsy, a positive mouse erythrocyte rosette test and immunophenotyping confirmed the diagnosis of B-cell CLL. Diffuse bone marrow infiltration, a low reticulocyte count (0.2%), negative anti-globulin tests and a normal serum haptoglobin level were consistent with Rai stage III CLL.

Serum protein electrophoresis and immunoglobulin bands in immunoelectrophoresis were normal. Plasma complement levels were within normal limits and cryoglobulins and circulating immune complexes were not detected. Plasma levels of IgA and IgM were within normal limits whilst the level of IgG (6.42 g/l) was slightly depressed. Urinary light-chain excretion was negative.

A percutaneous renal biopsy was performed. Light microscopy revealed sclerosis in 30% of the glomeruli and a hypercellular mesangium, a thickened periodic acid–Schiff positive mesangial matrix and a moderately thickened glomerular basement membrane in the remaining glomeruli. No glomeruli existed in the sections for immunofluorescence microscopy. Histological evidence of amyloidosis was not found. Nodular interstitial infiltration by lymphocytes and focal interstitial fibrosis was observed. A diagnosis of MPGN was made. Electron microscopy was typical of nephrotic syndrome with lipid cells visible in the cytoplasm of the tubular cells and the interstitial space. Glomeruli were sclerotic with thickening of the basement membrane. In some areas of the basement membrane a subendothelial amorphous electron dense material was noted. At higher magnifications this material was observed to be non-fibrillar in appearance.

The patient was given oral cyclophosphamide 400 mg/m<sup>2</sup>/day and prednisolone 100 mg/m<sup>2</sup>/day for 5 days and intravenous vincristine at a dose of 1.4 mg/m<sup>2</sup> as a single dose on the first day of treatment. Following the first course of CVP, she had complete remission with disappearance of splenomegaly and lymphadenopathies and with an absolute lymphocyte count below  $5 \times 10^9/l$ . An accompanying improvement in renal function and disappearance of the nephrotic syndrome was also observed with a BUN of 22 mg/dl, a serum creatinine of 1.4 mg/dl, and negligible proteinuria (Table 1).

In comparison to other B-cell lymphoproliferative disorders, clinical glomerular pathology has been less frequently described in CLL but an autopsy series has shown that the incidence of extraglomerular renal lesions such as subclinical interstitial lymphocytic infiltration and tubular atrophy is 60–70% in patients with CLL [1–3]. A variety of glomerular lesions have been described in CLL, including type I and II MPGN, focal and diffuse proliferative glomerulonephritis, membranous glomerulonephritis, light-chain nephropathy, minimal-change disease, fibrillar glomerulopathy, and amyloidosis [1–5]. Unlike other malignancies which are mostly associated with membranous glomerulopathies, CLL is mainly associated with MPGN type I and II [2], although the reason for this remains unexplained and immune complex disease may underlie the lesion. Some of the glomerulonephritis in CLL has been suggested to be related with glomerular involvement by deposition of the processed cryoprecipitating or non-cryoprecipitating M-component [2–4].

Though in our patient with MPGN, neither circulating immune complexes or cryoglobulin were detected, electron microscopy revealed presence of non-fibrillar material beneath the endothelium of the basement membrane. The electron microscopic appearance of the deposits in kidneys of patients with CLL and cryoglobulinaemia has been reported to be fibrillar [6]; however, due to failure in

**Table 1.** Clinical course

Date	Hb (g/dl)	WBC ( $\times 10^9/l$ )	ESR (mm/h)	BUN (mg/dl)	Creatinine (mg/dl)	Uric acid (mg/dl)	LDH (IU/dl)	Proteinuria (g/24 h)	Treatment
07.95	8.6	91.9	100	67	2	9	507	6	–
08.95	9.43	139	NA	66	1.6	12.7	640	NA	CVP treatment 5 days
09.95	6.0	5.6	138	24	1.6	13	766	1	Fever + neutropenia 8 day neutropenia G-CSF for 11 days
10.95	7.4	12.9	93	47	1.5	11.9	1201	0.65	Blood transfusion total 11 pack RBC
11.95	11.7	14	42	47	1.4	11.9	501	0.13	–
12.95	11.2	4.8	27	22	1.4	5.0	365	0	–

NA, not available.

immunofluorescence visualizing, the nature of the material in our patient remains speculative.

Remission of the nephrotic syndrome occurring with CVP treatment may be a result of the effects of cyclophosphamide and prednisolone directly on the kidney or alternatively improvement in renal function may have occurred as a result of remission of the CLL. That the latter is more likely is supported by data from Moulin *et al.* [3], where treatment of four patients with CLL and MPGN with chlorambucil alone in the absence of steroids resulted in complete remission of nephrotic syndrome in all patients with a parallel improvement in their CLL. This improvement occurred despite the fact that MPGN normally has a poor prognosis, and chlorambucil is rarely used in the treatment.

Departments of Haematology  
Nephrology, Histology  
and Embryology  
Marmara University Hospital  
Istanbul, Turkey

Tülin Budak-Alpdoğan  
Önder Alpdoğan  
İmer Okar  
Emel Akoğlu

1. Eagen JW, Lewis EJ. Glomerulopathies of neoplasia. *Kidney Int* 1977; 11: 297–306
2. Seney FD Jr, Federgreen WR, Stein H, Kashgarian M. A review of nephrotic syndrome associated with chronic lymphocytic leukaemia. *Arch Intern Med* 1986; 146: 137–141
3. Moulin B, Ronco PM, Mougnot B *et al.* Glomerulonephritis in chronic lymphocytic leukemia and related B-cell lymphomas. *Kidney Int* 1992; 42: 127–135
4. McLigeyo SO, Notghi A, Thomson D, Anderton JL. Nephrotic syndrome associated with chronic lymphocytic leukaemia. *Nephrol Dial Transplant* 1993; 8: 461–463
5. Dussol B, Brunet P, Vacher-Coponat H *et al.* Crescentic glomerulonephritis with antineutrophil cytoplasmic antibodies associated with chronic lymphocytic leukaemia. *Nephrol Dial Transplant* 1997; 12: 785–786
6. Gouet D, Marchaud R, Touchard G *et al.* Nephrotic syndrome associated with chronic lymphoid leukaemia. *Presse Med* 1982; 16: 3047–3049

### Recurrent ventricular tachycardia complicating atypical haemolytic–uraemic syndrome

Sir,

Thrombotic microangiopathy is the underlying pathological lesions in haemolytic–uraemic syndrome [1]. The cardiac manifestation in the form of congestive heart failure and arrhythmia have been reported in thrombotic thrombocytopenic purpura [2]. Thrombi and haemorrhage in the conducting tissue may account for cardiac arrest and rhythm

disturbance in such patients [3]. We observed a case of adult HUS, with fatal ventricular tachycardia.

### Case report

An 18-year-old male patient was admitted to Nephrology Unit of our hospital with acute onset progressive swelling preceded by upper respiratory tract infection for 6 weeks, oligoanuria, haematuria, anorexia, nausea, and vomiting for 4 weeks and impaired sensorium of 3 days duration. The patient had been well and asymptomatic until 8 weeks before, when he developed cough, running nose, and mild fever, for which he did not seek medical consultation. However, he denied any history of diarrhoea. Over the next 5–6 days, he noticed swelling over face and feet, which gradually increased in severity in a week's period. Subsequently he developed decreased urine output (progressing to anuria) and haematuria. He sought medical advice at this stage of illness and was prescribed some medication, the nature of which was not known. He developed anuria (urine volume 100 ml/day) and uraemia with weakness, anorexia, breathing difficulties, vomiting, impaired sensorium, and subsequently generalized convulsion and coma. Family and personal history was unremarkable. The physical examination revealed facial puffiness, pedal oedema, grade III coma, pallor + + +, pulse 96/min regular, resp. rate 26/min, temperature 99°F, BP 160/100 mmHg. There was no cyanosis, icterus, clubbing, or lymphadenopathy. Systemic examination was unremarkable. Urinalysis revealed acidic urine, proteinuria + + + +, RBC 8-10/HPF, WBC 15-20/HPF and few granular casts.

Peritoneal dialysis (P.D.) was started. The patient improved symptomatically with two sessions (36 h each) of PD. He became conscious, convulsions did not recur and urine volume increased to 500–600 ml/day. He was given 2 units of blood transfusion because of anaemia, and subsequently transferred to haemodialysis and became dialysis dependent. He was doing well on dialysis when one night he developed sudden palpitations, nervousness and breathlessness. He was transferred to coronary care unit, when ECG showed ventricular tachycardia (Figures 1 and 2). DC cardioversion with 160 joules was attempted and rhythm reverted back to normal. There was no evidence of electrolyte imbalance. He was put on oral mexiletine therapy 150 mg thrice a day. Twelve hours following the first episode, he developed ventricular tachycardia again and sinus rhythm was restored with DC defibrillation. In the following day, he again had similar episode which reverted back to normal with DC cardioversion. Intravenous lignocaine infusion was started. Same day he had another episode of ventricular

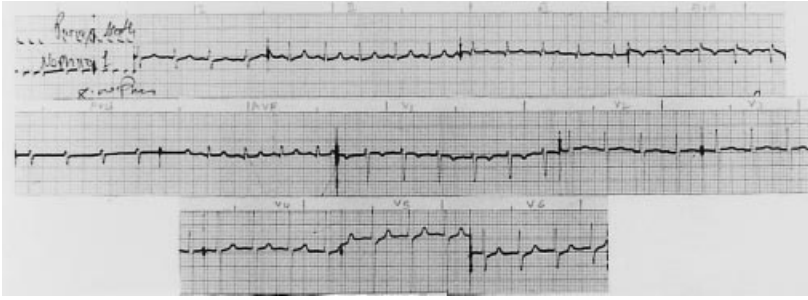


Fig. 1. Interval baseline ECG.

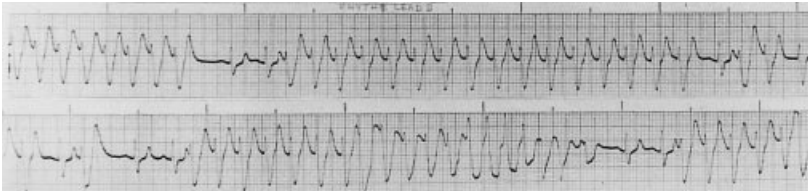

Fig. 2. Rhythm lead II, showing fast ventricular tachycardia with torsades and multiple capture beats.

tachycardia 2 h later, when sinus rhythm could not be restored and he succumbed to the ventricular tachycardia.

Laboratory investigations revealed Hb 6.2 g/dl, TLC 11 900/mm<sup>3</sup>, neutrophils 69%, lymphocytes 28%, monocyte 3%, platelet counts 94 000/mm<sup>3</sup>, blood smears showed thrombocytopenia, schistocytes, Burr cells, and helmet cells. Reticulocyte count was 16%, Prothrombin time 13.7 s (control 12.7 s), serum bilirubin 1.7 mg/dl, serum amylase 110 IU/l, SGOT 62 IU/l, SGPT 74 IU/l, blood urea 248 mg/dl, serum creatinine 12.3 mg/dl, serum sodium 129 mmol/l, potassium 4.2 mmol/l, chloride 98 mmol/l, blood glucose 120 mg/dl, 24 h urinary protein 3.3 g.

Renal biopsy showed enlarged glomeruli with segmental mesangial proliferation, focal glomerular basement membrane thickening and thrombi in capillary loops. Blood vessels showed mucoid degeneration of intima, fragmented endothelial lining, mural thrombus with fibrinoid necrosis of intertubular capillaries. Acid fuchsin orange G (AFOG) staining showed focal fibrinoid deposits and thrombi in glomerular capillary loops. Thus, the renal histology was consistent with haemolytic-uraemic syndrome.

#### Comment

Thrombotic microangiopathy is the characteristic vascular lesion in HUS and consists of disseminated microthrombi involving microvasculature of kidneys, brain, heart, pancreas and adrenal gland [1]. Brain and renal involvement are associated with obvious clinical sequelae. The consequence of cardiac involvement is less clear, although microthrombi in the heart are a striking feature [1,2]. Despite the widespread presence of thrombi in the microcirculation of the heart, frank necrosis of myocardial tissue is rare. Autopsy studies of 17 patients had shown microthrombi and haemorrhage in the AV node, His bundle, and main bundle portion of conducting tissue in 8 of 17 patients [2]. Such lesion may account for cardiac arrest or transient rhythm disturbances. However, thrombi and haemorrhagic foci were not identified in the sinoatrial node, or in the bundle-branch part of the conducting tissue. In addition to cardiac arrhythmias, myocarditis, and cardiomyopathy have also been reported in haemolytic-uraemic syndrome [4,5]. ECG evidence of bradycardia

with AV dissociation had been reported suggesting pathology in the conducting tissue. Our patient had ECG evidence of recurrent ventricular tachycardia. Because cardiac monitoring was not done in most of these patients, transient arrhythmia would have gone undetected. Since thrombi and haemorrhage are common findings in the conducting tissue of heart, it may account for cardiac arrest, arrhythmia or even sudden death [2,3]. Therefore ECG monitoring seems to be essential in patients with haemolytic-uraemic syndrome.

In conclusion, beware of fatal cardiac arrhythmia in patients with haemolytic-uraemic syndrome.

Department of Nephrology  
Institute of Medical Sciences  
Banaras Hindu University  
Varanasi-221 005  
India

Jai Prakash  
S. Gupta  
H. Kumar  
Usha  
Bharat Rawat

1. Symmers WSTC. Thrombotic microangiopathic haemolytic anaemia (thrombotic microangiopathy) *Br Med J* 1952; 2: 897-903
2. Ridolfi RI, Hutchins GM, Bell WR. The heart and conduction system in thrombotic thrombocytopenic purpura. *Ann Intern Med* 1979; 91: 357-363
3. JAMSTN, Monio RW. Pathology of the cardiac conduction system in Thrombotic thrombocytopenic purpura. *Ann Intern Med* 1966; 65: 37-43
4. Abu Arafah I, Gray E, Youngson G, Auchterlonic I, Russels G. Myocarditis and HUS. *Arch Dis Child* 1995, Jan 22 (1); 46-47
5. Walker AM, Benson LN, Wilson GJ, Arbus Gs. Cardiomyopathy: a late complication of hemolytic uremic syndrome. *Pediatr Nephrol* 1997; 11(2): 221-222

#### Systemic lupus erythematosus and thrombocytopenic purpura in two members of the same family following hepatitis B vaccine

Sir,

On the recommendation of the WHO, most countries opted for the universal vaccination against hepatitis B. Cases of different immune diseases following vaccination (mainly against flu and hepatitis B) are increasingly reported:

polyarthritis, vasculitis, erythema nodosum, uveitis, autoimmune thrombopenia, Guillain Barré syndrome, multiple sclerosis. However these published observations (although underestimated) have limited significance because no causality has been demonstrated, only a chronological link with the vaccination.

We report here an observation of two different autoimmune diseases occurring in two members of a family vaccinated against hepatitis B.

Mrs O., aged 24, in good health, is the mother of three children. No previous history has been noted in this family. In February 1995, Mrs O. and her three children began a course of intramuscular vaccination against hepatitis B (recombinant vaccine), three vaccinations every month and a booster in February 1996.

In December 1995, one of her daughters, aged 7, complained about subcutaneous haematomas and bleeding gums. Her platelet count was  $24 \times 10^6/l$ . A diagnosis of idiopathic thrombopenic purpura (ITP) was made in January 1996. In April 1996, Mrs O.'s general state of health changed, she exhibited marked loss of weight, and migratory arthralgia. Acute disseminated lupus erythematosus (SLE) was diagnosed in March 1997 with four criteria of the ARA (American Rheumatologists' Association).

Three cases of acute SLE following hepatitis B vaccine have been reported. Symptoms appeared 15 days after the first vaccination in two cases [1,2], and after the third injection in the latter [3]. Only two cases of ITP following hepatitis B vaccine (after second and third dose) have been reported [4]. In 1995, the WHO Collaborating Centre of International Drug Monitoring compiled 28 cases of thrombopenia occurring after vaccination against hepatitis B [5].

It is not possible to claim the causal link between these two observations and the vaccination, but the time link is impressive. These two autoimmune diseases can occur in the same subject, or in the same family [6], a genetic predisposition is likely. A viral infection often precedes ITP in children, as for acute SLE. Vaccination introduces an antigen together with adjuvants that may provoke an autoimmune type reaction on a genetically predisposed ground. This observation matches the concept that flares of autoimmune diseases could be induced by hepatitis B vaccine. Only a few of the most serious manifestations following hepatitis B vaccine have been reported, the rate of mild autoimmune manifestations being probably largely underestimated.

<sup>1</sup>Service de Néphrologie

<sup>2</sup>Service d'Hémo-Oncologie  
Centre Hospitalier Sud Réunion  
Saint-Pierre  
La Réunion  
France

Paul Finielz<sup>1</sup>  
Lam Foong Lam-  
Kam-Sang<sup>2</sup>  
José Guiserix<sup>1</sup>

1. Tudela P, Marti S, Bonal J. Systemic lupus erythematosus and vaccination against hepatitis B. *Nephron* 1992; 62: 236
2. Guiserix J. Systemic Lupus erythematosus following Hepatitis B vaccine. *Nephron* 1996; 74: 441
3. Mamoux V, Dumont C. Lupus érythémateux disséminé et vaccination contre l'hépatite B. *Arch Pédiatr* 1994; 1: 307-308
4. Poulin P, Gabriel B. Thrombocytopenic purpura after recombinant hepatitis B vaccine. *Lancet* 1994; 344: 1293
5. Meyboom RH, Fucik H, Edwards IR. Thrombocytopenia reported in association with hepatitis B and A vaccines. *Lancet* 1995; 345: 1638
6. Constans J, Le Herissier A, Vergnes C, Roudaut R, Durandet P, Gosse P, Dalocchio M. Circulating lupus coagulation inhibitor in two sisters, one with disseminated lupus erythematosus and the other with immunologic thrombocytopenic purpura. *Rev Med Interne* 1992; 13: 305-306

## Interstitial nephritis and retinitis pigmentosa

Sir,

We have read with great interest the new syndrome with familial interstitial nephritis and retinitis pigmentosa described by Farrell *et al.* [1]. Herein, we report a similar case of a girl who was born in 1980. In 1994 a cyst was removed from her left breast. In 1995, she was investigated because of a headache; fundoscopy and ERG revealed retinitis pigmentosa. That time she had 1 g/day proteinuria. In 1997, she was admitted to our nephrological centre to investigate her persistent proteinuria. Serological examination on admission included: serum creatinine 75  $\mu\text{mol/l}$ , urea 5.4 mmol/l,  $\text{Cl}_{\text{cr}}$  117 ml/min, potassium 3.7 mmol/l, haemoglobin 12.5 g/dl, albumin 36 g/l, normal urinary sediment, proteinuria 0.5-1.5 g/day. PAGE revealed a non-selective proteinuria: SI (MMW/HMW) 4.57. The acid-loading test with ammonium chloride was normal. The exogenous AVP test found impaired concentrating capacity: maximal urine osmolality 778 mosm/l, maximal specific gravity 1020. Immunological tests (immunoglobulins, rheumatoid factor, complement factors, CRP, cryoglobulin, ANA, ANCA) were normal. Ultrasound showed normal sized kidneys (115 mm) with an increase in the reflectivity. There was no evidence of calyceal cysts. Renal histology revealed chronic tubulointerstitial nephritis with a diffuse interstitial cellular infiltrate consisting mainly of lymphocytes. There were nine glomeruli, of which two were sclerosed. Immunofluorescence was negative. At the examination of HLA antigens, the HLA type was A1A9, B8B16, Dr3Dr9, where three HLA antigens (A1, B8, Dr3) match with the HLA type of the siblings referred by Farrell. In contrast with them, our patient is not obese (47 kg, 156 cm). Blood pressure with ABPM was normal with a preserved diurnal rhythm. Family history was negative for renal disease. She had normal secondary sexual characteristics and normal intelligence. Furthermore, there were no signs of the previously described renal-retinal syndromes: medullary cystic disease, Bardet-Biedl syndrome or Sensenbrenner's syndrome.

We believe that this patient suffers from the same new renal-retinal syndrome as Farrell's siblings. We think that the similarities and differences between the cases will help to know more about this syndrome.

Nephrological Center of  
Second Department of Medicine  
Medical University of Pécs and  
Fresenius Dialysis Center  
H-7624 Pécs,  
Hungary

Tamás Szelestei  
Tibor Kovács  
Tamás Magyarlaki  
Judit Nagy

1. Farrell J, Tormey V, Campbell E, Walshe JJ. Familial interstitial nephritis and retinitis pigmentosa. *Nephrol Dial Transplant* 1997; 12: 1468-1470

## Protein C administration in meningococcal septicaemia

Sir,

We read with great interest the recent case report by Kumar *et al.* [1] detailing plasma exchange and haemodiafiltration as an adjunct therapy for the treatment of meningococcal septicaemia.

Measurements of changes in protein C concentrations during this treatment, if performed, would be interesting. The role of protein C deficiency in the progression of this

devastating illness is now receiving much attention. Reduced or even negligible protein C concentrations may lead to rapid clinical deterioration in cases of purpura fulminans. Protein C infusions offer protection against the lethal effects of bacteria [2]. Elevation of protein C concentrations has been demonstrated to be of benefit in improving the clinical course of septicaemia [2–4]. Boldt *et al.* [3] found that use of pentoxifylline improved endothelial-related coagulation in critically ill patients, while Churchwell *et al.* [4] noted an increase in protein C concentrations after intensive plasma exchange.

More recently a group in Dublin (Ireland) have seen dramatic results of patient survival in cases of meningococcal septicaemia after protein C administration (unpublished data). Possibly in this present report use of plasma exchange may have produced a beneficial affect to this patient through improvement in protein C concentrations.

Use of protein C infusions may serve as another or alternative additional therapy in the effective treatment of meningococcal septicaemia.

Department of Physiology  
Worsley Medical & Dental Building  
University of Leeds  
Leeds  
UK

Sunil Bhandari

1. Kumar A, Kanagasundaram NS, Collyns TA, Davidson AM. Plasma exchange and haemodiafiltration in fulminant meningococcal sepsis. *Nephrol Dial Transplant* 1997; 13: 484–487
2. Fourier F, Jourdain M, Caron C, Goudemand J, Cuopin C. Coagulation inhibitor substitution during sepsis. *Intens Care Med* 1995; 21 [Suppl 2]: 5264–5268
3. Boldt J, Muller M, Heyn J, Wellers I, Hemplemann G. Influence of long-term continuous administration of pentoxifylline on endothelial-related coagulation in critically ill patients. *Crit Care Med* 1996; 24: 940–946
4. Churchwell KB, McManus ML, Kent P *et al.* Intensive blood and plasma exchange for treatment of coagulopathy in meningococemia. *J Clin Apheresis* 1995; 10: 171–177

### Autosomal dominant polycystic kidney disease presenting with prolonged macrohaematuria and perinephric haematoma

Sir,

Gross haematuria is the presenting symptom in 15–20% of patients with autosomal dominant polycystic kidney disease (ADPKD) [1]. Usually it is due to haemorrhage from cysts into pyelocalyceal system. More rarely, cyst rupture may occur into the perinephric space, giving rise to a perirenal haematoma [2]. We describe the case of a patient with prolonged macrohaematuria and perinephric haematoma as the presenting features of ADPKD.

A 56-year-old man was referred to us because of dark urine that had appeared in the previous hours; he had also presented left flank pain over the last 5 days, and had taken an unmeasured amount of diclofenac; he denied having abdominal trauma. Past personal history: arterial hypertension for 20 years treated with captopril, he was a heavy smoker. Family history: a 20-year-old daughter with renal cysts. On physical examination the patient's blood pressure was 160/90 mmHg; he was afebrile; the abdomen was not painful, but irregular surfaces could be felt on palpation; the rest of the physical examination was normal.

The most significant laboratory findings were: haemoglobin 10 g/dl, leukocytes 17400/ $\mu$ l (neutrophils 83%), the

platelet count and coagulation profile were normal; the urea was 170 mg/dl, creatinine 7.6 mg/dl, Na 125 mEq/l, K 4.6 mEq/l, Cl 106 mEq/l, HCO<sub>3</sub> 21 mEq/l, Ca 8.98 mg/dl, P 4.73 mg/dl. Urine: proteinuria 1.7 g in a 24-h specimen, Na 32 mEq/l, macrohaematuria; urine culture negative, Ziehl–Neelsen stains and Lowenstein ( $\times 3$ ) negatives.

ECG and X-ray of the chest were normal. Renal ultrasound showed bilaterally enlarged kidneys with multiple cysts, lithiasis in the lower pole of the left kidney and non-dilated urinary tract. The patient was diagnosed as having ADPKD. He was told to rest and was treated with intravenous fluids and antibiotics. After 2 weeks renal function improved and the blood pressure was controlled, but since the macrohaematuria persisted further examinations were done. Renal sonography and abdominal computed scan: left perirenal haematoma, neither calcifications nor lymph nodes were seen (Figure 1); cystoscopy and retrograde pyelography revealed bleeding from the left ureter; in intra-arterial digital subtraction angiography there was no neovascularity to suggest a tumour. The macrohaematuria lasted for 40 days, but the patient remained haemodynamically stable with no decline in the haemoglobin. A later renal ultrasound showed that the haematoma was decreasing in size. After follow-up for a year, the creatinine was 2.9 mg/dl and the haemoglobin 15 g/dl; sediment: microhaematuria. There has been no recurrence of macrohaematuria.

Perirenal haematoma is an infrequent complication of ADPKD, appearing in only 3% of the cases [3]. It has not been clearly related to the degree of physical activity, arterial hypertension or renal size. The most common clinical manifestations are flank or loin pain and haematuria. However, occasionally it may present with other complications such as haematoma infection or haemorrhagic shock. Computed tomography and magnetic resonance are the best methods for detection [3]. The treatment is usually conservative, aggressive procedures such as renal arterial embolization or nephrectomy are only indicated in complicated cases [1,4].

Recurrent episodes of haematuria have been associated with chronic progression of renal disease in ADPKD caused by iron deposition and interstitial fibrosis [2]. In our patient the acute worsening of the renal function was probably related to volume depletion and drug nephrotoxicity.

Another noteworthy aspect of the present case was the long duration of haematuria. Macrohaematuria in ADPKD is usually self limiting in a period of not more than 7–14 days. If bleeding is prolonged for more than 2 weeks or if it develops for the first time in a patient over 50, it is recom-

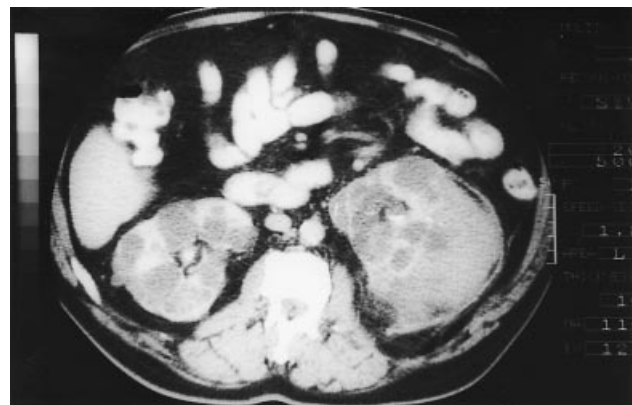

Fig. 1. CT abdominal scan. Enlarged kidneys with multiple cystic spaces and left perinephric haematoma.

mended that the possibility of malignancy should be eliminated [4], as we did. Moreover, in this case lithiasis may have played a role in the haematuria.

In conclusion, a perirenal haematoma is a rare complication of ADPKD, but it may appear even as the main form of presentation and it may be associated with prolonged macrohaematuria.

Nephrology Section and Diagnostic  
Radiology Service  
Hospital General de Elche  
Spain

A. E. Sirvent  
R. Enríquez  
J. B. Cabezuolo  
C. Ortí  
F. Amorós  
A. Reyes

1. Pirson Y, Chauveau D, Grünfeld JP. Autosomal dominant polycystic kidney disease. In: Davison AM, Cameron JS, Grünfeld JP, Kerr DNS, Ritz E, Winearls CG, ed. *Oxford Textbook of Clinical Nephrology*, 2nd edn. Oxford University Press, Oxford, 1998, 2393–2415
2. Gabow PA, Duley I, Johnson AM. Clinical profiles of gross hematuria in autosomal dominant polycystic kidney disease. *Am J Kidney Dis* 1992; 20: 140–143
3. Levine E, Grantham JJ. Perinephric hemorrhage in autosomal dominant polycystic kidney disease: CT and MR findings. *J Comput Assist Tomogr* 1987; 11: 108–111
4. Bennett WM, Elzinga LW. Clinical management of autosomal dominant polycystic kidney disease. *Kidney Int* 1993; 44 [Suppl 42]: S74–79

### Unmasking of thyrotoxicosis after initiation of regular haemodialysis treatment?

Sir,

In patients with end-stage renal disease (ESRD), the thyroid hormone profile corresponds to the 'sick euthyroid syndrome' which is similar to other non-thyroidal illnesses except for the absence of reverse T<sub>3</sub> elevation. Primary hypothyroidism is seen in up to 9.5% of the ESRD population compared with 1.1% of the general population. In contrast, thyrotoxicosis is rare [1,2]. We observed a woman with ESRD and toxic multinodular goitre in whom overt thyrotoxicosis became manifest after initiation of regular haemodialysis treatment.

A 55-year-old female patient was admitted to the hospital with nausea and vomiting for several days. Her blood pressure was 180/70 mmHg, and her heart rate 86 beats/min and regular. The heart examination showed grade 2/6 apical systolic murmur. The thyroid gland was not palpated on admission. Creatinine clearance was 6 ml/min. There was no history of administration of radiocontrast.

The patient underwent acute peritoneal dialysis therapy shortly after admission and was then switched to regular haemodialysis treatment. Two months after initiating haemodialysis, the laboratory values were Hb 9.0 g/dl; BUN 36 mg/dl; s-creatinine 3.4 mg/dl and albumin 3.7 g/dl. The pulse rate was regular at 118 beats/min. The patient was agitated, had a fine finger tremor and a history of recent weight loss (6 kg). Thyroid function tests documented T<sub>4</sub> toxicosis; free T<sub>3</sub> (fT<sub>3</sub>) 4.07 pg/ml, (normal 1.40–4.40), free T<sub>4</sub> (fT<sub>4</sub>) 3.39 ng/dl, (normal 0.80–2.0) and thyroid-stimulating hormone (TSH) 0.19 µIU/ml (normal 0.40–4.5). The TSH response to TRH (200 µg i.v., TRH Ares Serono, Milan) was blunted. Antimicrosomal and antithyroglobulin antibodies were negative. Thyroid ultrasonography revealed an enlarged multinodular thyroid gland. Thyroid scan, per-

formed with sodium pertechnetate Tc 99m, demonstrated a pattern of multinodular thyroid gland hyperplasia which is frequent in this endemic goitre region [3]. After treatment with propylthiouracil (200 mg per day) and propranolol (40 mg per day), her heart rate decreased (88 beats/min) and other physical signs disappeared within a few days.

ESRD is associated with a clinically euthyroid status. Although goitre and exophthalmus are well-recognized features of ESRD, the occurrence of thyrotoxicosis in ESRD is rare [1] and only 12 cases of hyperthyroidism, all female, have been reported in ESRD. Hyperthyroidism was due to Graves' disease in nine and to multinodular toxic goitre in three patients [2,5–13]. Both biochemical and clinical manifestations of hyperthyroidism may be masked by uraemia: interpretation of the thyroid hormones is rendered difficult because of its similarity to the sick euthyroid syndrome and apparently uraemia interferes with the development of thyrotoxicosis as postulated by others [2,4,6]. This is apparently also true in our case, although we cannot definitely exclude the possibility that thyrotoxicosis developed rapidly upon institution of haemodialysis treatment. Propylthiouracil, carbimazole and methimazole can be administered safely to thyrotoxic patients with ESRD who are on regular haemodialysis [5–8] and this was the case in our patient with thyrotoxicosis.

Departments of Nephrology and  
Endocrinology<sup>1</sup>  
Medical School of Erciyes  
University  
Kayseri  
Turkey

C. Utas  
C. Yalçındağ<sup>1</sup>  
K. Ünlühızarcı<sup>1</sup>  
A. Doğukan  
O. Oymak  
F. Keleştimur<sup>1</sup>

1. Kaptein EM. Thyroid hormone metabolism and thyroid disease in chronic renal failure. *Endocr Rev* 1996; 17: 45–63
2. Kaptein EM, Quinon Verde H, Chooljian CJ *et al.* The thyroid in end-stage renal disease. *Medicine* 1988; 67: 187–197
3. Özbakır Ö, Doğukan A, Keleştimur F. The prevalence of thyroid dysfunction among elderly subjects in an endemic goiter area of central Anatolia. *Endocr J* 1995; 42: 713–716
4. Lim VS. Renal failure and thyroid function. *Int J Artif Org* 1986; 9: 385–386
5. Miyasaka Y, Yoshimura M, Tabata S *et al.* Successful treatment of a patient with Graves' disease on hemodialysis complicated by antithyroid drug-induced granulocytopenia and angina pectoris. *Thyroid* 1997; 7: 621–624
6. McKillop JH, Leung ACT, Wilson R. Successful management of Graves' disease in a patient undergoing regular hemodialysis therapy. *Arch Intern Med* 1985; 145: 337–339
7. Absy M, Ng YC. Recurrence of thyrotoxicosis after correction of uremia in a patient with chronic renal failure (letter). *Nephron* 1993; 65: 326
8. Cooper DS, Steigerwalt S, Migdal S. Pharmacology of propylthiouracil in thyrotoxicosis and chronic renal failure. *Arch Intern Med* 1987; 147: 785–786
9. Soffer O, Chary KR, Dallas W. Clinical hyperthyroidism in a patient receiving long term hemodialysis. *Arch Int Med* 1980; 140: 708–709
10. Foley RJ, Hamner RW. Hyperthyroidism in end-stage renal disease. *Am J Nephrol* 1985; 5: 292–295
11. Alarcon RD, Groover AM, Jenkins-Ross CS. Organic anxiety disorder secondary to hyperthyroidism in a hemodialysis patient: a rare occurrence. *Psychosomatics* 1992; 33: 457–460
12. Nibhanupudy JR, Hamilton W, Sridhar R *et al.* Iodine-131 treatment of hyperthyroidism in a patient on dialysis for chronic renal failure. *Am J Nephrol* 1993; 13: 214–217
13. Lazzarin M, Benati F, Lupo A. Recurrence of thyrotoxicosis during hemodialytic treatment in a patient with chronic renal failure. *Nephron* 1996; 73: 119

### Importance of dry-weight assessment in well-being, appetite, nutritional status, and anaemia correction in haemodialysis patients

Sir,

There is nowadays a growing tendency to analyse dialysis adequacy only in terms of Kt/V, while dry weight (DW) assessment and normotension have been gradually omitted in the goals of dialysis. However, the well-documented link between blood pressure (BP) and patient survival [1] suggest the need to strictly normalize blood pressure in dialysis patients, and inadequate BP control most often is due to a failure in achieve and maintain dry weight [2]. When DW is overestimated, overhydration develops. We observed a negative influence of mild overhydration not only on blood pressure control, but also on well-being, appetite and other parameters, usually related to inadequate dialysis, like anaemia correction and nutritional status. To confirm this observation, we selected a small group of haemodialysis patients with suspicion of mild overhydration and prospectively evaluated the effect of dry weight reduction on BP control, anaemia correction and nutritional parameters.

Fifteen stable HD patients were included. Overhydration was suspected by an unexplained increase in BP level, although more obvious signs of overhydration like dyspnoea or oedema were absent. Overhydration was confirmed only if DW reduction was well tolerated. DW could be reduced ( $3.9 \pm 1.2\%$  of the basal DW) in the next  $3.3 \pm 0.9$  months until cramps or hypotension developed. Clinical (BP level, antihypertensive therapy, interdialytic weight gain) and biochemical (haemoglobin levels, serum albumin, transferrin and n-PCR) parameters were compared before (state 1) and after (state 2) DW reduction.

All patients were maintained with their usual haemodialysis prescription, adjusted to deliver a minimum Kt/V of 1 and remained unchanged during the study period. Erythropoietin doses, ferritin levels, and transferrin saturation were included in the database in the two steady states. After the initial DW reduction, we observed that DW had to be progressively increased in every patient, as cramps or intradialytic hypotension continued in a high percentage of dialysis sessions. All the patients reported improvement in appetite and, in  $3.8 \pm 0.9$  months, all the patients achieved a DW similar to the estimated basal DW. In a second part of the study, we compared the same parameters at this steady state (state 3) with state 2 and with the basal overhydrated state, in which the estimated DW was the same.

Both mean predialysis systolic and diastolic BP values were reduced ( $P < 0.05$ ) in state 2 and were maintained in state 3. Antihypertensive therapy could be reduced or eliminated in 38% of the patients. All the patients complained of anorexia in state 1. Appetite improved in all cases after DW reduction, as did interdialytic weight gain (IDWG), which was significantly higher in states 2 and 3 ( $2252 \pm 722$  ml in state 2 and  $2403 \pm 790$  in state 3;  $P < 0.001$  vs IDWG in state 1). Haemoglobin level also increased in state 2 ( $11.7 \pm 1.03$  vs  $9.6 \pm 0.9$  g/dl in state 1;  $P < 0.001$ ) and was maintained unchanged ( $12.2 \pm 0.83$  g/dl) in state 3, without changes in the dose of erythropoietin, or iron stores. Dialysis schedule remained unchanged (similar Kt/V) but appetite improved in all cases, n-PCR increased ( $P < 0.001$ ) in states 2 and 3, as did serum albumin ( $P < 0.001$ ) and s-transferrin concentration ( $P < 0.005$  vs state 1).

In summary, correction of DW in our patients was followed by a reduction in BP, increase in appetite and biochemical signs of improved nutrition. Anaemia was also

attenuated. In a third period, DW had to be increased due to improved appetite, but all positive effects of period 2 were maintained.

Our results suggest that a correct DW assessment is a very important factor to achieve optimal dialysis. Hypertension, anorexia and other parameters usually related to inadequate dialysis in term of Kt/V, like anaemia and malnutrition, can be corrected by maintaining an optimal DW. Higher than usual BP levels or lower IDWG can be clinical signs of mild overhydration in HD patients, when more obvious signs of fluid overload as dyspnoea or oedema are absent. Unexplained anaemia is often secondary to haemodilution and can induce a misdiagnosis of Epo resistance.

Insufficient ultrafiltration may contribute to anorexia in dialysis patients [3] due to bowel-wall oedema. Our results are in concordance with this point of view, as appetite increased only with DW reduction in all cases.

Careful and continued clinical observation must constitute the only way to achieve and maintain DW in haemodialysis patients.

Servicio de Nefrología  
Hospital Severo Ochoa  
Leganes  
Madrid, Spain

O. Ortega Marcos  
I. Rodriguez  
P. Gallar  
A. Oliet  
A. Vigil

1. Ritz E, Koch M. Hypertension as a risk factor of renal patients. Morbidity and mortality due to hypertension in patients with renal failure. *Am J Kidney Dis* 1993; 21: 113–118
2. Charra B, Laurent G, Chazot C *et al.* Clinical assessment of dry weight. *Nephrol Dial Transplant* 1996; 11 [Suppl 2]: 16–19
3. Cherton GM, Bullard A, Lazarus JM. Nutrition and dialysis prescription. *Am J Nephrol* 1996; 16: 79–89

### Tissue factor pathway inhibitor and tissue factor in HD and CAPD

Sir,

The prevalence of cardiovascular disease is high in the dialysis population. It has been reported that increased fibrinogen, elevated fVIIa, deranged fibrinolytic system (increased plasma levels of PAI-inhibitor of tissue plasminogen activator) may contribute to the development of atherosclerosis or cardiovascular disease [1]. Haemostatic disturbances are reported to occur in haemodialysed patients and in CAPD patients [2,3]. It has been suggested by Tomura *et al.* [1] that CAPD patients may have a greater risk of cardiovascular disease than HD patients, and they are more susceptible to thrombosis and atherosclerosis compared with HD subjects. Tissue factor plays a central role in the initiation of blood coagulation at the site of injury. TFPI (tissue factor pathway inhibitor) appears to play a primary role in the regulation of TF-induced coagulation [4]. It is primarily synthesized by the endothelium under normal physiological conditions [4]. Two, recently, published reports about TFPI [5,6] levels in haemodialysed patients yielded conflicting results. Considering all these data, we aimed to assess TF and TFPI levels and activities in patients maintained on HD and CAPD. Thrombomodulin as a marker of endothelial cell injury was also studied in these groups of patients.

The studies were performed on 20 chronically haemodialysed patients (12 men, 8 women, age range 31–65) undergoing 4–5 h of haemodialysis three times a week for over 6 months and 9 CAPD subjects (6 men, 3 women, age range 20–53). CAPD patients were on 4 × 21 exchanges

**Table 1.** TF and TFPI in patients treated by means of haemodialyses (HD) and CAPD, and in healthy volunteers

	Control group	HD	CAPD
TF activity (nM)	0.29 ± 0.05	0.15 ± 0.05***#	0.35 ± 0.21
TF:Ag (pg/ml)	71 ± 40	212 ± 141***#	323 ± 136***
TFPI activity (IU/ml)	1.72 ± 0.35	2.01 ± 0.07*	1.99 ± 0.31*
TFPI:Ag (ng/ml)	131 ± 35	146 ± 50	150 ± 32
Thrombomodulin (ng/ml)	3.35 ± 1.78	15.2 ± 4.35***	15.44 ± 3.44***

Data given are means ± SD. \* $P < 0.05$ , \*\* $P < 0.01$ , \*\*\* $P < 0.001$  vs control; # $P < 0.05$ , ## $P < 0.01$ , ### $P < 0.001$  HD vs CAPD.

(Baxter Twin bag system or Andy Plus, Fresenius system). Dwell times were generally 4–6 h during the day and 8 h overnight. The osmotic pressure of CAPD fluid was adjusted in accordance with the extent of ultrafiltration in each patient. Peritonitis has not occurred in any of the patients during the 3 month period before the study. Ten volunteers without any apparent disease or abnormalities on routine laboratory tests served as a control group. Blood samples from haemodialysed patients were collected into 3.8% trisodium citrate (9 vol of blood to 1 vol of 0.13 M of trisodium citrate solution) from the arterial side of the a-v fistula before the onset of haemodialysis and heparin administration. To avoid the influence of circadian variation all the samples were taken in the morning between 8 and 9 a.m. Samples were then centrifuged at 3000 *g* for 20 min at room temperature within 1 h of collection to yield platelet poor plasma. Then plasma was subsequently aliquotted and stored in plastic tubes at  $-40^{\circ}\text{C}$  until assayed. TF, TFPI activities and antigens, thrombomodulin concentration were performed using commercially available kits from American Diagnostica, USA. Analysis of variance was used for comparison of mean values between groups studied. A  $P < 0.05$  was taken to indicate statistical significance.

The results are shown in Table 1. TF activity was significantly higher in CAPD patients when compared to haemodialysed patients but similar to the healthy volunteers. TF levels were higher in both groups of dialysed patients relative to control group. TFPI activity was significantly higher in both groups of dialysed patients, whereas TFPI levels, although higher, did not reach statistical significance when compared to healthy subjects. Thrombomodulin concentrations were significantly higher in CAPD and haemodialysed patients when compared to healthy subjects.

So far there have been no data concerning TF and TFPI in CAPD patients. Concerning haemodialysed patients, our data are in contrast to those of Cella *et al.* [5] who did not observe any differences in TFPI activity between chronically haemodialysed patients and healthy subjects. Similar data to ours were published by Kario *et al.* [6] who reported an increased plasma TFPI activity before dialysis. In our study we found that not only TFPI activity but also TFPI antigen was increased in haemodialysed patients. This could be due to a reduced kidney catabolism or to endothelial cell damage. Renal replacement therapy in the form of haemodialysis with heparin as an anticoagulant, may mobilize TFPI from vascular endothelium and platelets and increase its synthesis rate leading to TFPI accumulation particularly together with decreased renal function. High TFPI levels in uremia may also reflect endothelial cell injury due to haemodialysis treatment with heparin. However, increased TFPI levels before dialysis session in haemodialysed patients seems unlikely to be due to the effect of residual heparin from the previous dialysis session. Moreover, in CAPD patients there are no systemic anticoagulation. It has been suggested that

FVIIa may also be generated by endothelial cell injury in uremic patients [7]. The increased levels of other markers of endothelial cell damage as vWF, thrombomodulin, tissue plasminogen activator/plasminogen activator inhibitor 1 complexes found in uraemia in previous studies [8] are in keeping with this concept. TFPI is a potent inhibitor of the factor VIIa/TF complex in the presence of factor Xa, as well as being a direct inhibitor of FXa [4]. This high level of TFPI might thus counterbalance the increased levels of FVIIa in uraemia and may be seen as a defence mechanism against a hypercoagulable state, particularly in CAPD. We have also found an increased TF activity in both groups of dialysed patients. Recently, plasma TF levels have been found to be increased in chronically haemodialysed patients [9], whereas in non-dialysed patients results are conflicting [7,9]. Since it is unclear how closely TF antigen corresponds to TF procoagulant activity, we decided to measure TF activity in CAPD and haemodialysed patients. TF activity was significantly higher in CAPD patients when compared to haemodialysed patients but similar to the healthy volunteers. Plasma TF has been reported to have FVII-dependent procoagulant activity *in vitro* [10]. However, it is not clear whether plasma fraction of TF with procoagulant activity or TF locally expressed on the injured renal endothelium might mediate FVIIa generation.

Concluding, our data further suggest the evidence of endothelial injury in uraemic patients treated by means of CAPD or haemodialyses. Further insights into the impacts of perturbed endothelium *in vivo* will undoubtedly help to improve our knowledge about pathophysiology of thrombotic events and their complications in uraemia as well as their prevention and therapy.

Department of Nephrology  
and Internal Medicine  
University School of Medicine  
Bialystok  
Poland

Jolanta Małyszko  
Jacek S. Małyszko  
Michał Myśliwiec

- Tomura S, Nakamura Y, Doi M *et al.* Fibrinogen, coagulation factor VII, tissue plasminogen activator, plasminogen activator inhibitor-1, and lipid as cardiovascular risk factor in chronic hemodialysis and continuous ambulatory peritoneal dialysis patients. *Am J Kidney Dis* 1996; 27: 848–854
- Kobayashi M, Yorioka N, Yamakido M. Hypercoagulability and secondary hyperfibrinolysis may be related to abnormal lipid metabolism in patients treated with continuous ambulatory peritoneal dialysis. *Nephron* 1997; 76: 56–61
- Małyszko J, Małyszko JS, Pawlak D, *et al.* Platelet function, hemostasis and serotonin in acute and chronic renal failure. *Thromb Res* 1996; 83: 351–361
- Broze GJ, Jr. Tissue factor pathway inhibitor. *Thromb Haemostas* 1995; 74: 90–93
- Cella G, Vertoli U, Naso A *et al.* Tissue factor pathway inhibitor (TFPI) activity in uremic patients during haemodialysis. *Thromb Res* 1996; 81: 671–677
- Kario K, Matsuo T, Yamada T, Matsuo M. Increased tissue

factor pathway inhibitor levels in uremic patients on regular haemodialysis. *Thromb Haemostas* 1994; 71: 275-279

7. Kario K, Matsuo T, Matsuo M *et al.* Marked increase of activated factor VII in uremic patients. *Thromb Haemostas* 1995; 73: 763-767
8. Sagripanti A, Barsotti G. Bleeding and thrombosis in chronic uremia. *Nephron* 1997; 75: 125-139
9. Koyama T, Nishida K, Ohdama S *et al.* Determination of plasma tissue factor antigen and clinical significance. *Br J Haematol* 1994; 87: 343-347
10. Fukuda C, Iijima K, Nakamura K. Measuring tissue factor (factor III) activity in plasma. *Clin Chem* 1989; 35: 1897-1900

**Audit of quality of hospital haemodialysis in Scotland. The Scottish Renal Registry**

Sir,

The Scottish Renal Registry, established in 1991 to collect registry data and facilitate audit of renal replacement therapy in Scotland, published an audit of quality of hospital haemodialysis in Scotland in *Nephrology Dialysis Transplantation* in 1997 [1]. A simple measure of quality of dialysis, the percentage urea reduction across a single haemodialysis treatment, was used to anonymously compare the quality of dialysis provided in the 11 adult dialysis units in Scotland. At that time the Renal Association of the UK recommended a minimum standard for percentage urea reduction of >55 [2]. By the end of the audit cycles all units except for one, Unit 4, had more than 80% of their patients achieving the minimum standard. The question was raised as to how assistance could be offered to this unit while retaining the anonymity incorporated into audit.

When the audit cycle was repeated in April 1997, 89% of the 653 patients on hospital haemodialysis in Scotland achieved a urea reduction >55% (Figure 1). Again >80% of patients in each unit, apart from one, achieved the required minimum standard but on this occasion Unit 4 had reached this level and a different unit had fallen below the 80% level (Figure 2). Regular audit, therefore, does appear to have helped to improve the quality of hospital haemodialysis being provided without a breach of anonymity.

The Scottish Renal Registry suggested that the minimum standard of a percentage urea reduction value of >55 might

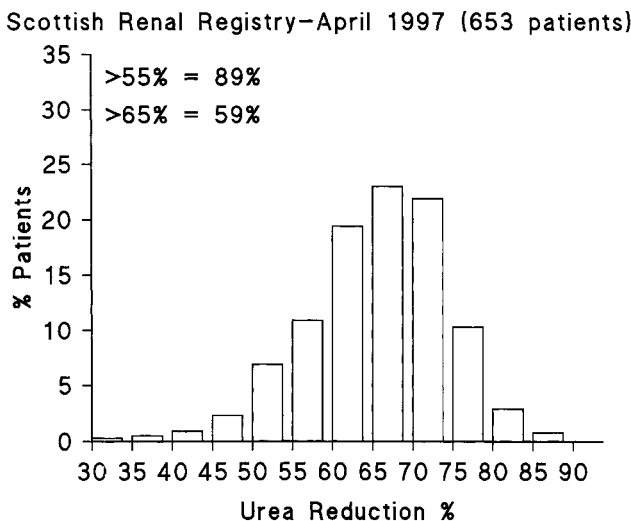


Fig. 1. Percentage urea reduction across single haemodialysis treatment sessions.

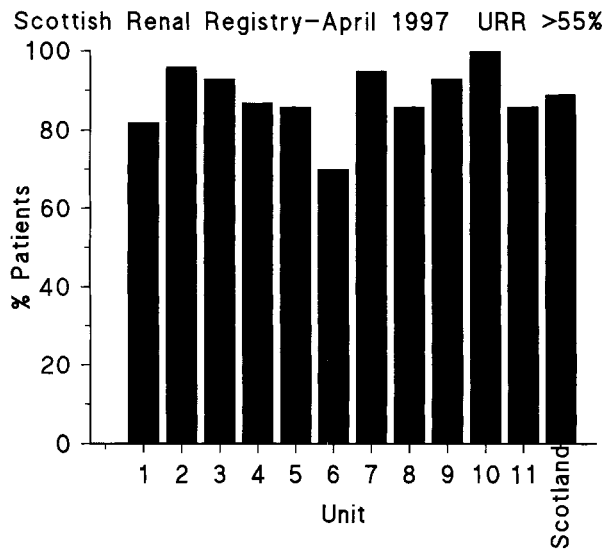


Fig. 2. Proportion of patients achieving percentage urea reduction of >55 in the 11 adult dialysis units in Scotland.

be too low and that a >60% urea reduction rate might be more appropriate [1]. In November 1997 the Renal Association reviewed and revised the recommended standards and audit measures for treatment of adult patients with renal failure in the UK [3]. For patients on thrice weekly haemodialysis a minimum standard percentage urea reduction of >65% was recommended. On reviewing the data from the audit cycle of April 1997 only 59% of the 653 patients on hospital haemodialysis in Scotland reached a >65% urea reduction. No unit managed to achieve a level of 80% patients reaching a urea reduction of >65% and in three units only around one-third of patients achieved this level (Figure 3). The degree of shortfall in the levels of urea reduction achieved suggests that the only effective way of ensuring that >80% of patients achieve the minimum standard will be by significantly lengthening dialysis times, consequently affecting dialysis shift patterns. Repeated audit

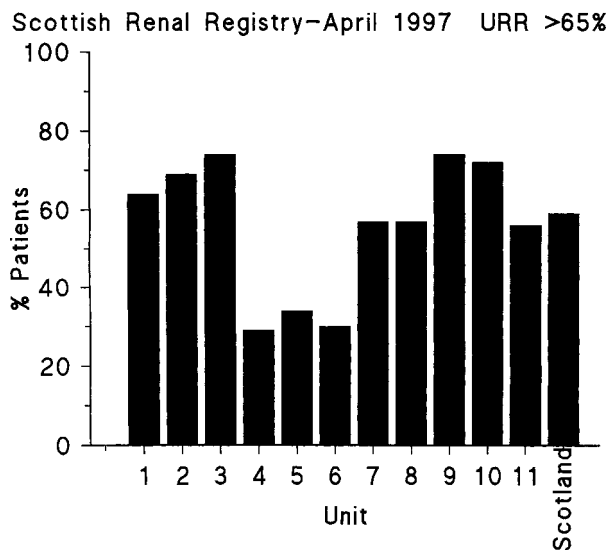


Fig. 3. Proportion of patients achieving percentage urea reduction of >65 in the 11 adult dialysis units in Scotland.

cycles will clearly be necessary to ensure achievement of the revised quality standard in urea reduction.

Renal Unit  
Western Infirmary  
Glasgow  
UK

B. J. R. Junor

1. The Scottish Renal Registry. Audit of quality of hospital haemodialysis in Scotland. *Nephrol Dial Transplant* 1997; 12: 29–32
2. *Treatment of adult patients with renal failure. Recommended standards and audit measures.* The Renal Association, April 1995
3. *Treatment of adult patients with renal failure. Recommended standards and audit measures,* 2nd edn. Renal Association, November 1997

### Delayed renal function and allograft survival: does the type of post transplant dialysis influence outcome?

Sir,

Delayed graft function (DGF) following renal transplantation is a source of increased patient morbidity, cost [1] and possibly a detrimental effect on graft survival [2]. Whilst studies have highlighted perioperative factors in the pathogenesis of DGF [2,3] little attention has been given to the effect of the inevitable postoperative dialysis on graft survival. It has been demonstrated that recovery from acute renal failure (ARF) is enhanced by dialysing with biocompatible haemodialysis (HD) membranes [4]. We therefore investigated whether a similar improvement was shown with DGF maintained on either peritoneal dialysis (PD), the ultimate biocompatible membrane, or HD over a non-biocompatible, cuprophane membrane.

Data was collected retrospectively on a consecutive series of 327 allografts with 74 cases of DGF (23%), (after excluding primary non-function) and 253 initial function (IF). Both locally procured and shipped organs were transplanted with Mannitol and methylprednisolone given perioperatively. The immunosuppressive regimen was dual therapy cyclosporin and prednisolone. DGF was defined as a requirement for dialysis in the first 7 days after transplantation (except for a single dialysis for hyperkalaemia within the first 24 h) and these patients were dialysed according their preoperative regimen.

Fifty-five percent ( $n=41$ ) of the DGF group received PD and 45% ( $n=33$ ) HD postoperatively. There was no significant difference in the duration of postoperative dialysis between these two groups or between the mean age of the two groups. Graft survival was significantly improved (Figure 1) in those patients receiving HD as compared to both the PD ( $P=0.03$ ) and IF ( $P=0.03$ ). There was no significant difference in graft survival between the IF and PD groups. The 6-year graft survival for the HD, PD and IF groups were 83, 72 and 71% respectively.

The reason why HD should improve graft survival compared to PD let alone IF grafts is unclear. One possible mechanism lies in the reduction by HD of dimethylarginine [5], an endogenous inhibitor of nitric oxide (NO) synthetase. The increased NO may both improve renal perfusion and inhibit intimal hyperplasia [6] and chronic vascular rejection [7]. This however remains speculative. These results are from a relatively small, non-randomized, retrospective study and it is thus important not to over-emphasize their relevance. If these results are confirmed in a larger cohort of patients the conclusion must be that DGF should be treated with haemodialysis regardless of the pre-transplant dialysis status. Furthermore, it would be informative to assess the effect of dialysis over cuprophane or biocompatible membranes in DGF, as well as to investigate whether graft survival improves in patients normally maintained with PD who are treated with HD postoperatively.

Departments of Surgery<sup>1</sup> and  
Nephrology<sup>2</sup>  
Leicester General Hospital  
Leicester  
LE5 4PW  
UK

S. C. Weight<sup>1</sup>  
T. Horsburgh<sup>1</sup>  
K. P. G. Harris<sup>2</sup>  
M. Khurshid<sup>1</sup>  
P. R. F. Bell<sup>1</sup>  
M. L. Nicholson<sup>1</sup>

1. Rosenthal JT, Danovitch GM, Wilkinson A, Ettenger RB. The high cost of delayed graft function in cadaveric renal transplantation. *Transplantation* 1991; 51: 1115–1118
2. Troppmann C, Gillingham KJ, Benedetti E. *et al.* Delayed graft function, acute rejection, and outcome after cadaver renal transplantation. *Transplantation* 1995; 59: 962–968
3. Gulanikar AC, MacDonald AS, Sungurtekin U, Belitsky P. The incidence and impact of early rejection episodes on graft outcome in recipients of first cadaver kidney transplants. *Transplantation* 1992; 53: 323–328
4. Hakim RM, Wingard RL, Parker RA. Effect of the dialysis

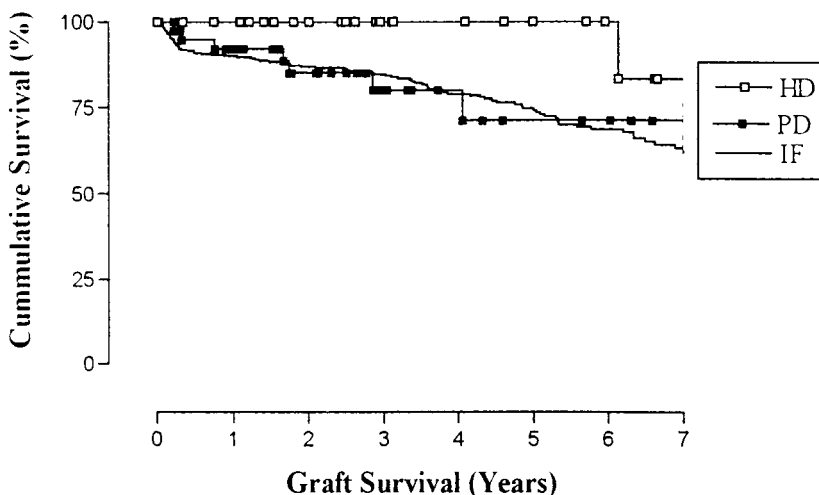


Fig. 1. Renal allograft survival following initial function (IF) or delayed graft function (DGF) maintained with haemo (HD) or peritoneal (PD) dialysis.

membrane in the treatment of patients with acute renal failure. *N Engl J Med* 1994; 331: 1338–1342

5. Vallance P, Leone A, Calver A *et al.* Accumulation of an endogenous inhibitor of nitric oxide synthesis in chronic renal failure. *Lancet* 1992; 339: 572–575
6. Tarry WC, Makhoul RG. Nitric oxide precursor speeds recovery of endothelial-dependent vasorelaxation and reduces intimal hyperplasia after endothelial injury. *Surg Forum XLIV*: 384–387
7. Salomon RN, Hughes CCW, Schoen FJ *et al.* Human coronary transplantation-associated arteriosclerosis. *Am J Pathol* 1991; 138: 791–798

### Discontinuing trimethoprim-sulfamethoxazole prophylaxis does not lead to increased risk of rejection in renal transplant patients with stable graft function

Sir,

Trimethoprim-Sulfamethoxazole (T-S) prophylaxis is used in many transplant programmes to reduce the risk of *Pneumocystis carinii* pneumonia (PCP) following transplantation [1]. In addition to antibacterial and antiprotozoal activity, there is evidence that T-S has immunosuppressive effects including inhibition of lymphocyte activation [2]. In the clinical setting, patients with Wegener's granulomatosis receiving prophylactic T-S have fewer relapses and it may be effective as monotherapy in mild disease [3]. In renal transplant patients, reducing or switching immunosuppression may be associated with an increased risk of rejection and there is a concern, therefore, that discontinuing T-S in renal transplant recipients may reduce their overall immunosuppression and lead to an increased risk of rejection [4]. To address this concern we carried out a study to evaluate the risk of rejection in patients with stable graft function upon discontinuing T-S.

In our unit we adopted a policy of PCP prophylaxis in January 1995, whereby all patients receive 960 mg of T-S three times a week for 12 months. To assess the effect of discontinuing this treatment we identified all patients with stable graft function at 12 months who were considered to be at low risk of rejection. All patients had a stable serum creatinine of 150  $\mu\text{mol/l}$  or less, had not required antilymphocyte preparation (either for induction or rejection), had not suffered a rejection episode in the previous 3 months and had been taking the same doses of antirejection treatment during the 3 months before discontinuing T-S. Rejection was diagnosed on biopsy, or clinically if there was an unexplained elevation in serum creatinine with a rapid response to methylprednisolone. Patients transplanted between January 1995 and June 1996 formed the study group while a group of patients fulfilling the same criteria from the period between January 1992 and December 1994 formed a control group. All patients with case sheets available were considered for analysis. Chi-square and Kruskal Wallis tests were used for comparisons between groups.

One hundred and sixty-eight patients were studied of which 111 were excluded after review of the case sheets because of follow-up elsewhere or failure to meet the inclusion criteria. Eighteen patients fulfilled the inclusion criteria with a control group of 39 patients. Comparing the study group and controls there was no difference in: male to female ratio (1.6:1 vs 2:1); age (median (range)) at transplantation (46 years (23–65) vs 41 years (19–70)); and serum creatinine at 12 months (119  $\mu\text{mol/l}$  (92–150) and 122  $\mu\text{mol/l}$  (74–146)) ( $P > 0.5$  for all). In the first nine months post-transplantation, 11% of the study patients had a single rejection episode while 6% had more than one rejection. Corresponding figures for

the controls were 26 and 5%, respectively ( $P = 0.2$ ). Eleven percent of the study group were receiving triple therapy at one year (azathioprine, cyclosporin and prednisone) while 83% were taking prednisone and cyclosporin and 6% FK506 and prednisone. Corresponding figures for the controls were 36, 62 and 3%, respectively ( $P = 0.05$  for comparison between proportion of patients receiving triple therapy). During the 6 month period after stopping T-S, there were no episodes of rejection in the study group and no episodes observed over the same time period for the control group. There was no difference in the serum creatinine at 18 months post-transplantation (6 months after stopping T-S) between the study group (119  $\mu\text{mol/l}$  (99–191)) and controls (120  $\mu\text{mol/l}$  (85–157)), ( $P > 0.5$ ).

The results of this study would suggest that discontinuing low dose T-S prophylaxis in renal transplant recipients with stable graft function and low risk of rejection is not associated with an increase risk of rejection in the subsequent 6 month period.

Transplant Unit  
London Health Sciences Centre  
London  
Ontario  
Canada

K. McLaughlin  
A. Jevnikar  
A. Lazarovits  
D. Hollomby  
N. Muirhead

1. Branten AJ, Beckers PJ, Tiggeler RG, Hoitsma AJ. *Pneumocystis carinii* pneumonia in renal transplant recipients. *Nephrol Dialysis Transplant* 1995; 10: 1194–1197
2. Leeder JS, Nakhoda A, Spielberg SP, Dosch HM. Cellular toxicity of sulfamethoxazole reactive metabolites. II. Inhibition of natural killer activity in human peripheral blood mononuclear cells. *Biochem Pharmacol* 1991; 41: 575–583
3. Stegeman CA, Cohen Tervaert JW, de Jong PE, Kallenberg CGM, for the Dutch Co-trimoxazole Wegener's Study Group. Trimethoprim-sulfamethoxazole for the prevention of relapses of Wegener's granulomatosis. *N Engl J Med* 1996; 335: 16–20
4. Ingulli E, Sharma V, Singh A, Suthanthiran M, Tejani A. Steroid withdrawal, rejection and the mixed lymphocyte reaction in children after renal transplantation. *Kidney Int* 1993; 43: S36–39

### Transient hyperphosphatasaemia in a 7-year-old boy following renal transplantation

Sir,

Transient hyperphosphatasaemia in children and adults has been well documented in the literature [1,2]. The hallmark of this condition is a marked increase in alkaline phosphatase (ALP) activity, up to ten times the upper limit of normal, lasting 2–3 months with no evidence of liver or bone disease. It has been associated with viral infection [3] and drugs [4].

However, few cases of transient hyperphosphatasaemia in the transplanted population have been reported so far. It has been described in a liver transplant patient [5] and in a youngster with renal transplant [6]. The interesting aspect of these cases is the follow-up pre- and post-transplantation revealing the transitory nature of this syndrome.

The paucity of reported cases of this condition prompted us to share a similar occurrence of transient hyperphosphatasaemia in a young boy with renal transplantation followed at our institution.

A 7-year-old boy with ESRD secondary to posterior urethral valves underwent successful cadaveric renal transplantation after 2 years on peritoneal dialysis. At the time of transplantation, serum calcium (2.42 mmol/l), ionized calcium (1.26 mmol/l), inorganic phosphate and ALP levels (177 U/l) were normal. Intact parathyroid hormone was

normal (5 ng/ml) as were the liver enzymes, ALT (<5 U/l) and AST (16 U/l).

One month post-transplantation, earlier than the case presented by Dr Schwab's team, we noticed a 6-fold increase in the alkaline phosphatase levels to a maximum of 3355 U/l.

At that time, the boy was asymptomatic. He showed no clinical signs of liver or bone disease nor any sign of infection. Further evaluation showed a normal and stable serum calcium (2.32 mmol/l) and phosphorus (1.1 mmol/l). PTH (7.7 ng/ml) was within normal limit. Liver function tests, AST (18 U/l), ALT (14 U/l) and gamma GT (11 U/l) were normal. GFR as estimated by the Schwartz formula was normal (95 cc/min 1.73 m<sup>2</sup>).

No infectious causes could be found. He did not suffer any fever, anaemia or thrombocytopenia and a CMV urine culture was negative. Bone scan did not show abnormal activity. We completed the work-up by measuring ALP isoenzymes which showed an elevated fraction of the bone fraction (2081.6 U/l; normal 15–40 U/l) and a low liver fraction (6.4; normal 12–66 U/l).

Immunosuppression as well as other medication were unremarkable. After transplantation he did not receive any vitamin D analogues. Triple immunotherapy was administered with prednisone (0.8 mg/kg/day), mycophenolate mofetil (20 mg/kg/day) and cyclosporin microemulsion (12 mg/kg/day). Cyclosporin has been implicated as a cause of transient increase in ALP [7], but reported levels of ALP were much lower. Cyclosporin levels were around 240 ng/ml by monoclonal assay. There was no episode of rejection at the time of this transient hyperphosphatasaemia.

ALP levels returned to normal (333 U/l) within 10 weeks, without any change in medication. The boy is presently 12 months post-transplantation and ALP remains within normal limits.

In conclusion, we attributed the rise of ALP to the benign transient hyperphosphatasaemia syndrome. This entity has not been reported often in the organ transplant literature. In

this case, the boy presented in the early post-transplant period (1 month). We could not find any causative factors. It is an entity that deserves a special attention and needs to be further examined. Some questions remained unanswered. Does the prevalence in the transplant population differ from the general population? Will it reoccur? We support Dr Schwab's team conclusions regarding the need to avoid unnecessary extensive investigations due to transitory nature of this apparently benign condition. Simple awareness of this condition will make its diagnosis and investigation easier.

Department of Paediatric  
Nephrology  
Hôpital Ste Justine  
Montreal  
Quebec  
Canada

Veronique Phan  
Marie José Clermont

1. Stein P, Rosalki SB, Foo AY, Hjelm M. Transient hyperphosphatasaemia of infancy and early childhood: clinical and biochemical features of 21 cases and literature review. *Clin Chem* 1987; 33: 313–318
2. Onica D, Tossander J, Waldenlind L. Recurrent transient hyperphosphatasaemia of infancy in an adult. *Clin Chem* 1992; 38: 1913–1915
3. Ng PC, Cheung CK, Tam JS, Li CK. Benign transient hyperphosphatasaemia associated with adenovirus infection. *J Paed Child Health* 1995; 31: 561–562
4. De Vito GA, Concord NH. Transient elevation in alkaline phosphatase possibly related to trimethoprim-sulfamethoxazole therapy. *J Pediatr* 1982; 100: 998–999
5. Lachaux A, Chambon M, Boillot O *et al.* Transient hyperphosphatasaemia after liver transplantation in infancy. *Transplant Proc* 1996; 28(5): 2847
6. Schwab M, Schmidt-Gayk H, Ruder H. Transient hyperphosphatasaemia in a 4 year boy after successful kidney transplantation. *Nephrol Dial Transplant* 1997; 12: 1745–1749
7. Briner VA, Landmann J, Brunner FP, Thiel G. Cyclosporine A induced transient rise in alkaline phosphatase in kidney transplant patients. *Transplant Int* 1993; 6(2): 99–107