



Case Report

Two Different Primary Tumors in the Same Brain-A Case Report and Review of the Literature

Murat Şakir EKŞİ¹, Teyyub HASANOV², Suheyla UYAR BOZKURT³, Yaşar BAYRİ²,
Mustafa İbrahim ZİYAL²

¹University of California, San Francisco, Orthopedic Surgery-Spine Center, California, ABD

²Marmara University Medical Faculty, Neurosurgery, Istanbul, Türkiye ³Marmara University
Medical Faculty, Pathology, Istanbul, Türkiye

Summary

Double primary brain tumors are very rare. A 77-year-old man admitted to our clinic due to headache and urinary incontinence. After radiological evaluation, double tumors in different lobes were observed. Stereotactic biopsy from the frontal lesion was managed, because of the patient's age and poor medical status. Histopathological diagnosis was glioblastoma. The other unresected parietal tumor was benign meningioma depending on MR images. Post-operative radiotherapy and chemotherapy were given. In this case report, a rare entity of coexistent double tumors is discussed with thorough literature review.

Key words: Primary brain tumor, double tumor, meningioma, glioblastoma, stereotactic biopsy

İki Farklı Primer Tümör Aynı Beyinde: Bir Olgu Sunumu ve Literatürün Gözden Geçirilmesi

Özet

Beyinde 2 farklı primer tümör görülme oranı düşüktür. Kliniğimize, 77 yaşında yetişkin bir erkek hasta baş ağrısı ve idrar kaçırma şikayetleri ile başvurdu. Radyolojik incelemelerde, farklı beyin loblarında yerleşimli 2 tümör tespit edildi. Hastanın genel sağlık durumu ve yaşından ötürü frontal lob yerleşimli kitleden stereotaktik biyopsi yapıldı. Histopatolojik tanı glioblastomla uyumlu geldi. Diğer rezeke edilmeyen, parietal lob yerleşimli kitlenin MR görüntüsüne dayalı tanısı benign meningiomaydı. Biyopsi sonrası hastaya radyo-kemoterapi tedavileri uygulandı. Bu yazıda, nadir çift primer beyin tümörünün klinik prezantasyonu mevcut literatür eşliğinde incelendi.

Anahtar Kelimeler: Primer beyin tümörü, çift tümör, meningioma, glioblastoma, stereotaktik biyopsi

INTRODUCTION

Glial tumors compose 58% and meningiomas are 20% of primary brain tumors⁽⁶⁾. They are completely different in origin, and from each other. Glial tumors

originate intraaxially from glial cells in the brain. High grade glial tumors have aggressive clinical outcomes. Meningiomas are extraaxial tumors and originate from leptomeninges. They are usually benign in nature. Simultaneous

occurrence of primary brain tumors is rare^(4,6,8). There are some predisposing factors such as phacomatosis, tuberous sclerosis and radiation; but etiology sometimes can be completely idiopathic^(4,6,11). The most common double tumor presentation is of meningioma and glial tumor. The first case of meningioma with glial tumor coexistence was reported by Cushing and Eisenhardt in 1938⁽⁶⁾.

We described a case of glioblastoma concomitant with remote meningioma. We also reviewed clinical presentations, radiological assessments and therapeutic approaches with thorough literature review.

CASE PRESENTATION

A 77-year-old man was admitted to our hospital for headache, urinary incontinence and incapability of daily activities. After MRI, a heterogenous mass lesion, isointense on both T1- and T2-weighted scans, was detected in bilateral frontal lobe and it was also infiltrating genu of corpus callosum (Figure 1A, B). There was profound edema around the lesion (Figure 1A, B). There was also a right parietal, well demarcated, extraaxial mass lesion; homogeneously

isointense to cerebrum (Figure 1D, E). After IV contrast administration, frontal lesion enhanced with a peripheral rim and a necrotic area was present in the center of it (Figure 1C); parietal lesion enhanced homogeneously and a dural attachment was detected over the side on falx cerebri (Figure 1F). Pre-operative diagnosis was double tumor coexistence of frontal high grade glial tumor and parietal meningioma (Figure 2). Congestive heart failure was present in his medical history. Due to his age and poor general medical situation, only stereotactic biopsy was planned for the frontal lesion. The biopsy procedure was uneventful, and the patient was discharged without any additional deficit on post-operative 2nd day. The histopathological diagnosis was glioblastoma (Grade IV glial tumor according to 2007 WHO-Classification). Whole brain radiotherapy composed of total dose of 60 Gy was given during post-operative 6 weeks. Adjuvant temozolomide (75 mg/m²/day, from the first to the last day of radiotherapy) was also administered. After 6 weeks of therapy, the patient suddenly deteriorated because of pneumonia and died.

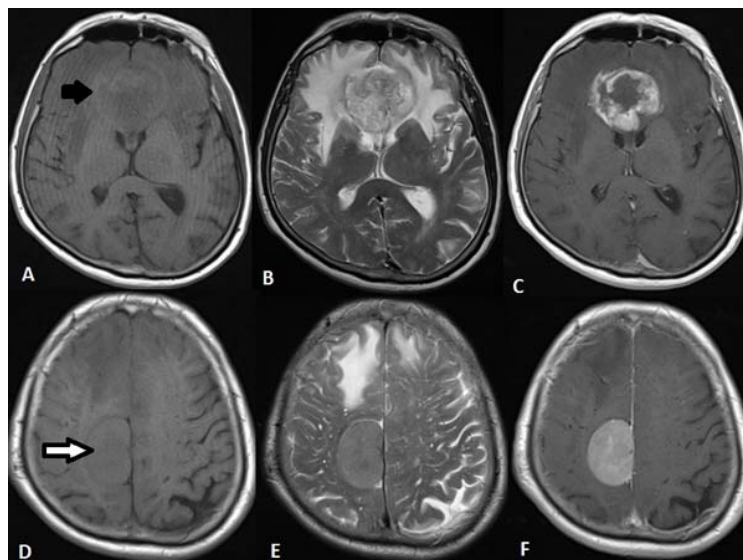


Figure 1: On axial plane T1- and T2-weighted brain MR, an isointense lesion is seen in both frontal lobes, infiltrating genu of corpus callosum (A-black arrow, B). Profound edema around it is seen (B). After IV contrast material, its rim enhances and a central necrotic area appears (C). Right parietal parasagittal dural based mass lesion is seen as isointense to cerebrum on T1- and T2-weighted scans (D-white arrow, E). It enhances homogeneously with IV contrast material (F).

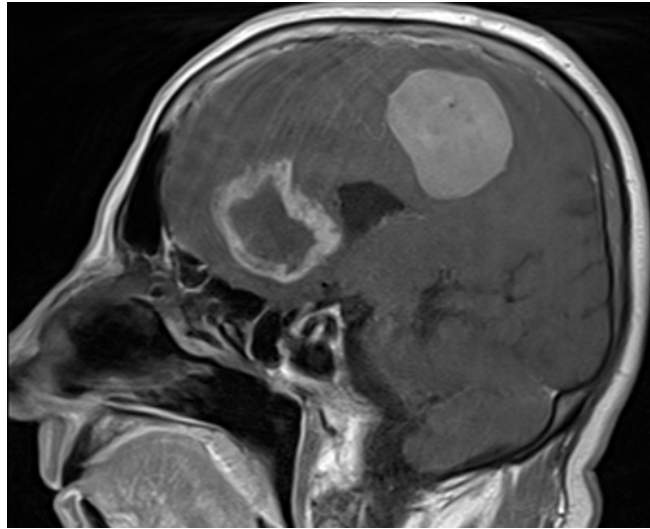


Figure 2: On brain MRI, two different mass lesions are detected; one in the frontal lobe and the other one in the parietal lobe.

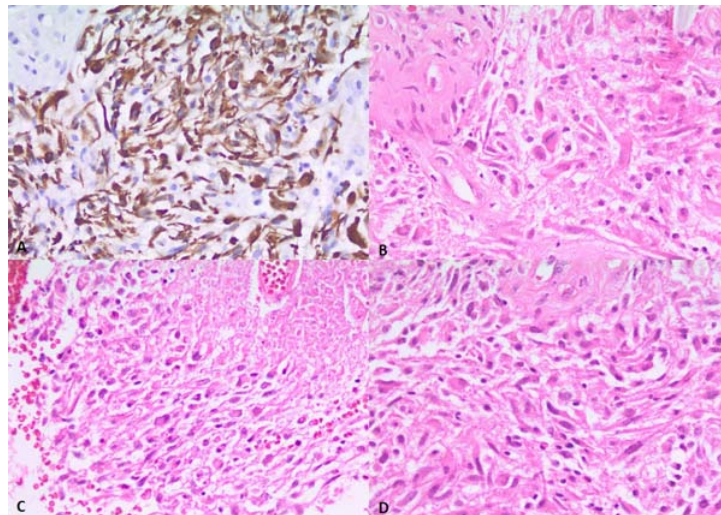


Figure 3: Light microscopic view of frontal glioblastoma (A: GFAP staining X40, B, C, D: H&E x40).

DISCUSSION

Multiple primary brain tumor occurrence in the same patient without secondary reasons is very rare⁽⁴⁾. The mostly detected community is composed of meningioma and glial tumor^(4,11). Co-occurrence of meningioma is 1-2 cases in every 100 glioblastoma cases⁽⁸⁾. There have been 41

cases of concurrent or later occurred double tumors in the literature till 1995^(4,11). Since then, 16 more cases (including ours) have been added (Table 1)^(1,12).

Table 1: Double tumor cases reported after 1995

Authors	Patient age(years)/gender	Presentation	Tumor locations	Treatment
Miyagi et al. (1995)	77/F	Left hemiparesis, vomiting	Right frontal glioblastoma, left sphenoidal wing and cerebellar convexity transitional meningiomas	Only glioblastoma resected
Lee et al. (2002)	70/F	Headache, dysarthria, right hemiparesis	Right frontal meningioma, left temporo-occipital glioblastoma	DSO, RT
Prayson et al. (2002)	87/F	Difficulty in ambulation, urinary incontinence, left hemiparesis	Right frontal meningothelial meningioma and grade III astrocytoma	SSO
Goyal et al. (2003)	34/M	Headache, seizure, left hemiparesis	Right frontal anaplastic astrocytoma, posterior fossa transitional meningioma	DSO, RT
	72/M	Headache, temporal fitting	Right temporal glioblastoma, right sphenoid wing fibroblastic meningioma	SSO, RT
Drlicek et al. (2004)	51/M	Headache, facial nerve paresis, contraction of visual field	Left clinoidal meningothelial meningioma, left frontal glioblastoma	SSO
Rieske et al. (2005)	40/M	Retroauricular mass	Posterior fossa atypical meningioma, left frontal glioblastoma	DSO
Tugcu et al. (2006)	42/M	Right hemiparesis, disturbed speech	Left parietal transitional meningioma and glioblastoma	SSO
Fortuniak et al. (2007)	64/F	Aphasia, agraphia, alexia	Left parietal glioblastoma, left parasagittal occipital fibrous meningioma	SSO, RT
Nestler et al. (2007)	68/F	Headache, gait ataxia, vomiting	Left occipital falx meningioma, left cerebellar glioblastoma	Only glioblastoma resected, RT
	72/F	Right leg paresis	Left parasagittal transitional meningioma and glioblastoma	SSO
	49/M	Altered mental status, disorientation	Left frontal falx fibrous meningioma and glioblastoma	SSO, RT, CT
Iyer et al. (2009)	55/M	Headache, drowsiness, decreased speech output, seizure	Olfactory groove transitional meningioma, left temporal glioblastoma and brainstem grade III glial tumor	SSO, brainstem glial tumor not biopsied, RT
Chen et al. (2010)	63/F	N/A	Left frontal fibroblastic meningioma and glioblastoma	SSO
Suzuki et al. (2010)	75/F	Headache	Left temporal glioblastoma and meningothelial meningioma	SSO, RT, CT
Present case	77/M	Headache, urinary incontinence, incapability of daily activities	Frontal glioblastoma, right parietal parasagittal meningioma	Biopsy from glioblastoma, RT, CT

Abbreviations: F: Female, M: Male, N/A: Not available, DSO: Double staged operations for each tumor, SSO: Single session operation for both tumors, RT: Post-operative radiotherapy, CT: Post-operative chemotherapy

Although histological diagnosis is very important for appropriate approach to different tumors, today neuroradiological diagnostic tools are very useful. Computed tomography and MRI are the first line radiology modalities. Magnetic resonance is more superior to CT; because high definition of both intraaxial and extraaxial tumors; even better with contrast material use. Sometimes, it is impossible to differentiate two tumors in conventional (unenhanced) CT scans^(4,6).

There are some proposed theories about nature of double tumors in the same patient^(4,6,8). One is related with local oncogenic effect of each tumor type over other. Which starts the process is not clear yet; but both may be the first to initiate it^(4,6). Signaling pathways of receptor tyrosine kinase was found as one of responsible pathogenic source of disease⁽¹¹⁾. The p53, Wnt, RTKs, and Notch are some common signal transduction pathways that include abnormalities in both meningioma and glial tumors⁽¹¹⁾. In the case reported by Suzuki et al.⁽¹¹⁾, they expressed that EGFR was very high in meningioma cells than glioblastoma cells. So, meningioma cells may have paracrine effect over glioblastoma. For paracrine or juxtacrine effect, tumors should be in contact, side by side. But, this cannot be supported in our case; because the tumors were not in neighborhood. Some authors proposed that the process is just only coincidence^(4,6,8,11). So, the main idea supporting this coincidence is that both meningiomas and glial tumors are very common in public. Also, genetic basis is a question about the etiology⁽⁴⁾. Such as monosomy 22 in the meningioma cells, loss of entire chromosome 10 and gain of chromosome 1 in the glioblastoma cells were present in the cases reported by Nestler et al.⁽⁸⁾.

In our case, the patient was admitted to our clinic with headache, urinary incontinence and incapability of daily activities. After MRI examination, two distinct tumors (the

intraaxial one in the genu of corpus callosum, penetrating to the opposite hemisphere, the other one extraaxial and in the parafalcine area) were detected. The intraaxial tumor was heterogenous in intensity with profound peripheral edema. The other tumor was homogenously enhanced and had dural attachment at falx cerebri. The pre-operative diagnosis was combination of glioblastoma and meningioma. In double tumor cases, treatment approach is a debate topic. In the literature, the glial tumor usually had been the first target^(4,6). Our patient's complaints were related with the frontal glial tumor; meningioma was totally incidental. The glial tumor was seated in deep structures and had passed to the opposite hemisphere under falx cerebri. Stereotactic biopsy was planned and histopathological diagnosis was glioblastoma (Grade IV, 2007 WHO Classification). He was asymptomatic for meningioma; his general medical status was not suitable and grade IV glial tumors have short life expectancy. Additional surgeries add risks to these kind of patients⁽⁶⁾. So he was referred to radio- and chemotherapy for the glial tumor; put on regular follow-ups for both tumors.

CONCLUSION

In a case of discordance between the clinical presentation and the radiological findings (especially on an unenhanced CT), a second tumor should be searched thoroughly on contrast enhanced MRI. Treatment approach should be decided upon the prognosis of the lesions and their locations in brain. In double tumor cases, further analysis of chromosomes should be conducted to understand the etiopathogenesis thoroughly.

Correspondence to:

Murat Şakir Ekşi

E-mail: muratsakireksi@gmail.com

Received by: 02 January 2014

Revised by: 10 June 2014

Accepted: 12 June 2014

The Online Journal of Neurological Sciences (Turkish) 1984-2014

This e-journal is run by Ege University
Faculty of Medicine,
Dept. of Neurological Surgery, Bornova,
Izmir-35100TR
as part of the Ege Neurological Surgery
World Wide Web service.
Comments and feedback:
E-mail: editor@jns.dergisi.org
URL: <http://www.jns.dergisi.org>
Journal of Neurological Sciences (Turkish)
Abbr: J. Neurol. Sci.[Turk]
ISSNe 1302-1664

malignant astrocytoma. Ann Diagn Pathol 2002; 6: 44-48.

10. Rieszke P, Zakrzewska M, Biernat W, Bartkowiak J, Zimmermann A, Liberski PP: Atypical molecular background of glioblastoma and meningioma developed in a patient with Li-Fraumeni syndrome. *J Neurooncol* 2005; 71: 27-30.
11. Suzuki K, Momota H, Tonooka A, Noguchi H, Yamamoto K, Wanibuchi M, et al.: Glioblastoma simultaneously present with adjacent meningioma: case report and review of the literature. *J Neurooncol* 2010; 99: 147-153.
12. Tugcu B, Kepoglu U, Gunal M, Gunaldi O, Karakaya B, Demirgil BT: Two distinct primary brain tumors, in same region of the same patient: a case report. *J Neurooncol* 2006; 79: 219-220.

REFERENCES

1. Chen G, Gao X, Liao Y, Xu B: A glioblastoma adjacent to a meningioma. *Br J Neurosurg* 2010; 24: 718-719.
2. Drlicek M, Aichholzer M, Wurm G, Bodenteich A, Fischer J: [Collisiontumour composed of glioblastoma and meningioma-a case report]. *Pathologie* 2004; 25: 402-405.
3. Fortuniak J, Jaskolski DJ, Zawirski M, Tybor K: Glioblastoma multiforme and meningioma in the same patient - a case report. *Neurol Neurochir Pol* 2007; 41: 272-275.
4. Goyal A, Singh AK, Sinha S, Tatke M, Singh D, Gupta V: Simultaneous occurrence of meningioma and glioma in brain: report of two cases. *J Clin Neurosci* 2003; 10: 252-254.
5. Iyer VR, Sanghvi DA, Shenoy A, Goel A: Three distinct co-existent primary brain tumors in a patient. *J Cancer Res Ther* 2009; 5: 293-296.
6. Lee EJ, Chang CH, Wang LC, Hung YC, Chen HH: Two primary brain tumors, meningioma and glioblastoma multiforme, in opposite hemispheres of the same patient. *J Clin Neurosci* 2002; 9: 589-591.
7. Miyagi A, Maeda K, Sugawara T, Sawada T, Tsubokawa T: [Triple primary intracranial tumors of different cell types: a case report]. *No Shinkei Geka* 1995; 23: 531-536.
8. Nestler U, Schmidinger A, Schulz C, Huegens-Penzel M, Gamerding UA, Koehler A, et al.: Glioblastoma simultaneously present with meningioma--report of three cases. *Zentralbl Neurochir* 2007; 68: 145-150.
9. Prayson RA, Chowdhary S, Woodhouse S, Hanson M, Nair S: Collision of a syncytial meningioma and