

## CASE REPORT

DOI: 10.5336/caserep.2020-74041

## Primary Cutaneous Adenoid Cystic Carcinoma

<sup>id</sup> Caner KAYA<sup>a</sup>, <sup>id</sup> F. Nihal DURMUŞ KOCAASLAN<sup>a</sup>, <sup>id</sup> Zeliha Leyla CİNEL<sup>b</sup>,  
<sup>id</sup> Beyza KESKİN<sup>b</sup>, <sup>id</sup> Özhan ÇELEBİLER<sup>a</sup>

<sup>a</sup>Marmara University Faculty of Medicine, Department of Plastic, Reconstructive and Aesthetic Surgery, İstanbul, TURKEY

<sup>b</sup>Marmara University Faculty of Medicine, Department of Pathology, İstanbul, TURKEY

**ABSTRACT** Adenoid cystic carcinoma is a malignant tumor usually localized in the salivary glands. It can also develop in serous glands such as the breast, main bronchi, uterine cervix, Bartholin's gland of the vulva, prostate gland, and external auditory canal. It is more common in the white race. Most of the primary cutaneous adenoid cystic carcinoma cases occur on the scalp. Despite the high rate of metastasis, long-term survival can be observed because the progression of the disease is slow. Distant organ metastases such as lungs, bone, liver and brain have also been reported in the literature at 40%. Its treatment is wide excision of the lesion and demonstration of tumor negative margin in pathological sampling. In this case report, we wanted to present surgical and oncological treatment to a 65-year-old female patient with lung metastasis diagnosed with adenoid cystic carcinoma on the scalp.

**Keywords:** Adenoid cystic carcinoma; skin cancer; salivary gland tumor

Adenoid cystic carcinoma is a malignant tumor usually localized in the salivary glands.<sup>1</sup> It can also develop in serous glands such as the breast, main bronchi, uterine cervix, Bartholin's gland of the vulva, prostate gland, and external auditory canal.<sup>2</sup> Primary cutaneous adenoid cystic carcinoma (PCACC) is a very rare adnexal tumor.<sup>3</sup> Its prevalence is 2.3/10,000,000. It is more common in the white race.<sup>4</sup> 41% of PCACC cases occur on the scalp. Chest, abdomen, back, eyelid, perineum, and extremity skin are other localizations of PCACC reported in the literature.<sup>5</sup> In this case presentation, the aim is to review the literature and present a case diagnosed with PCACC in the scalp.

### CASE REPORT

A 65-year-old woman applied to our clinic with a painful mass in the left temporoparietal scalp area (Figure 1). Patient anamnesis revealed that the mass had

appeared about 3 years ago, the patient had been operated twice in an external center for the existing complaint, and the size of the mass had increased in the last 4 months. Pathological examination in the previous operation reported the specimen as 'syringoma'. Due to frequent recurrence, the preparations were sent to the pathology clinic of our hospital for re-evaluation.

Family history was normal and the only comorbidity of the patient was hypertension.

Physical examination revealed a painful mass of approximately 5x4 cm in the scalp of the left temporoparietal region, with regular borders, expanding the skin, immobile, hard, and bright red colored. Peripheral lymphadenopathy was not found. Systematic examination revealed no pathology in the salivary glands, breast, and external auditory canal. Contrast-enhanced computed tomography showed that the mass in the left temporoparietal region did not result in calvarial bone destruction (Figure 2).

**Correspondence:** Caner KAYA

Marmara University Faculty of Medicine, Department of Plastic, Reconstructive and Aesthetic Surgery, İstanbul, TURKEY

**E-mail:** drcanerkaya@gmail.com



Peer review under responsibility of Türkiye Klinikleri Journal of Case Reports.

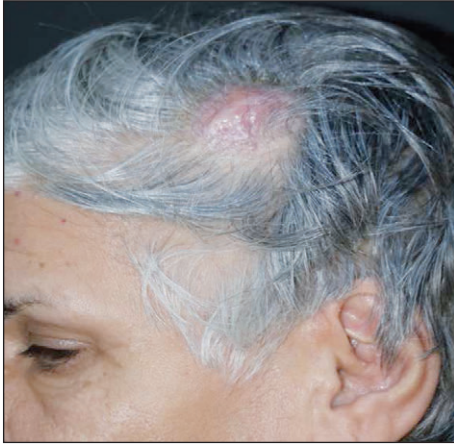**Received:** 01 Feb 2020

**Received in revised form:** 03 Jun 2020

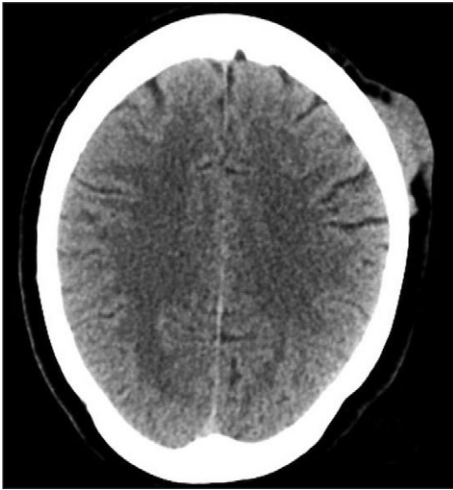
**Accepted:** 04 Jun 2020

**Available online:** 21 Aug 2020

2147-9291 / Copyright © 2020 by Türkiye Klinikleri. This is an open access article under the CC BY-NC-ND license (<http://creativecommons.org/licenses/by-nc-nd/4.0/>).



**FIGURE 1:** A mass in the scalp of the left temporoparietal region, with regular borders, expanding the skin, immobile, hard, and bright red colored.

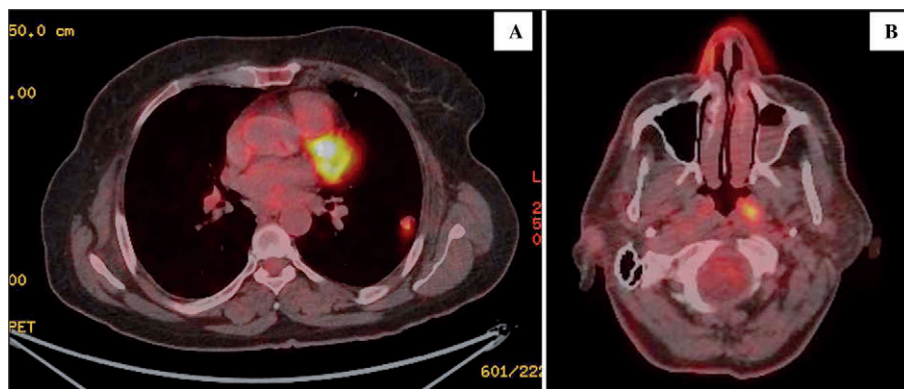


**FIGURE 2:** The appearance of the lesion which in the left temporoparietal region, that does not perform calvarial bone invasion in axial plan CT.

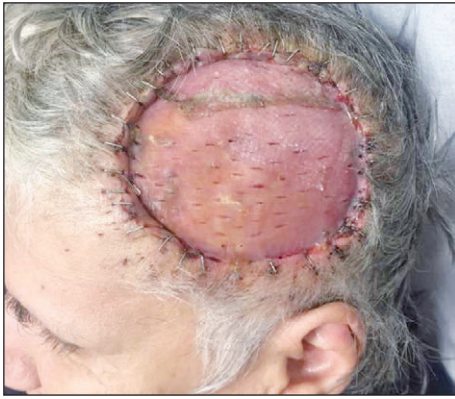Immunohistochemical examination was performed on the preparations in the pathology clinic of

our hospital. Immunoeexpression was observed in the EMA, S100, CD34, SOX10, CK7, and P63 panels, whereas no immunoeexpression was observed in the ER, PR, and CK20 panels. The patient was diagnosed as PCACC since there were no lesions in the salivary gland and mucosa. Positron emission tomography (PET) was performed for systemic screening. PET scan showed abnormally increased multiple fluoro-2-deoxy-glucose (F18 FDG) involvement marked by F-18 isotope in the bilateral lung lower lobe parenchyma (SUVmax 2.43) and the nasopharyngeal left wall (SUVmax 2.18) compared to the symmetrical structure (Figure 3). Endoscopic examination of the nasopharynx was performed to detect the suspicious lesion in the nasopharynx. No pathological formation was detected in the endoscopic examination. Thoracic computed tomography (CT) revealed nodules of approximately 17 mm in size in the bilateral lung lower lobes, with the largest in the lower lobe superior segment of the left lung. Based on these findings, surgical resection of the mass and referral of the patient to the oncology clinic for further chemotherapy (in order to eradicate the existing lesions in the lung parenchyma after the operation, which were considered as metastases) was planned.

After total excision of the lesion on the scalp under general anesthesia, defect repair was performed with a partial-thickness skin graft taken from the left femur lateral (Figure 4). The patient did not have any problems in the early postoperative period, and the pathology result was reported as: “Adenoid cystic carcinoma showing perineural invasion” (Figure 5). Microscopic proximity (1 mm) was detected in the deep



**FIGURE 3:** A) Increased F18 FDG uptake in the left lung lower lobe parenchyma. B) Increased F18 FDG nasopharyngeal left wall compared to the symmetrical structure.



**FIGURE 4:** The lesion was repaired with partial thickness skin graft after wide excision.

surgical margin, and surgical margins in other directions were over 2.5 cm. Immunohistochemical examination showed that EMA, S100, CD34, SOX10, CK7, and P63 panels were immunopositive, whereas CK20, ER, and PR panels were immunonegative.

The patient was given 6 cycles of combined chemotherapy including docetaxel, cisplatin and 5-fluorouracil, and 12 and 20 sessions of 36 and 200 Gray (Gy) radiotherapy to the surgical site and metastatic involvements in the lung, respectively, and continued oncological follow-up at an external center after the surgery. No local recurrence was detected in the patient one year after surgery. Regression was observed in the metastatic masses in the lung.

Necessary permissions for the study were obtained from the patient.

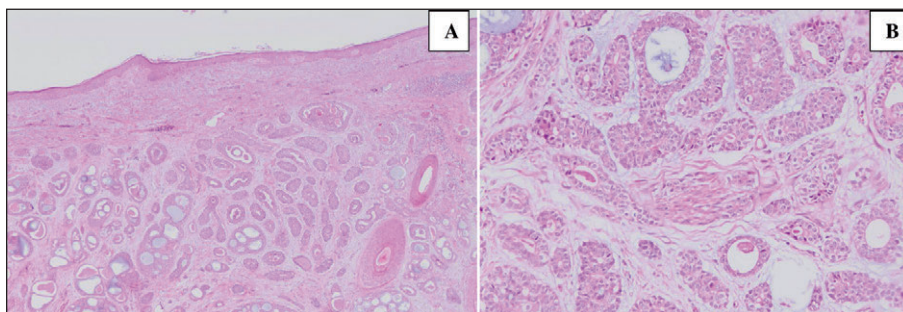
## DISCUSSION

Primary cutaneous adenoid cystic carcinoma is a very rare malignancy. It was first described by Boggio in 1975.<sup>6</sup> It is mostly seen on the scalp and the average

age of onset is 59. It is seen equally in males and females.<sup>4,5,7</sup> The rate of local recurrence and perineural invasion is high, and some studies have reported the rate of perineural invasion as 59-76%.<sup>5,8</sup> Distant organ metastases such as lung, bone, liver and brain have also been reported in the literature at a rate of 40%.<sup>9,10</sup> Early diagnosis is important in preventing lymph node and lung metastasis.

PCACC treatment includes wide excision of the lesion and demonstration of tumor negative margin in pathological sampling.<sup>11</sup> Histopathologically, PCACC consists of cytologically malignant basophilic cells that form a cribriform, tubular and solid pattern localized to the middle and reticular dermis. The cribriform pattern was predominant in our case (Figure 3).

Adenoid variant of basal cell carcinoma, mucinous carcinoma of the skin, skin metastasis of adenoid cystic carcinoma of other regions, and benign skin tumors are included in the differential diagnosis of primary cutaneous adenoid cystic carcinoma and should be excluded.<sup>12</sup> Adenoid BCC shares the cribriform pattern, basaloid cells, and stroma rich in hyaluronic acid. The presence of basaloid islands with palisading borders, sulfated acid mucin, and connection with the epidermis helps to distinguish from ACC. Mucinous carcinoma (primary or metastatic) can be morphologically identical to ACC and might be difficult to distinguish. This tumor is often positive for sialomucins and invariably shows strong and diffuse positivity for low-molecular weight cytokeratins. Metastatic adenocarcinoma particularly ductal/lobular breast carcinoma can look similar. The presence of true glandular lumina and the lack of basement membrane reduplication in ad-



**FIGURE 5:** A) Adenoid cystic carcinoma infiltration in the dermis (x4, H&E section). B) Adenoid cystic carcinoma, perineural invasion site (x40, H&E section).

dition to the strong cytokeratin positivity help in making the distinction.<sup>7</sup> In differential diagnosis, immunohistochemical examination is also performed. While EMA, Cytokeratin, S100, and CD117 are positive in PCACC, Bcl-2 is positive in adenoid type basal cell carcinoma, P63 and CK7 are positive in cutaneous mucinous carcinoma, and PAS is positive in skin metastasis of adenoid cystic carcinoma (Table 1).

Ramakrishnan et al. examined 27 cases and reported the 5-year survival rates of patients with tubular, cribriform and solid growth patterns as 39%, 26%, and 5%, respectively. High-grade transformation in ACC (previously referred to as dedifferentiation) is a rare phenomenon that does not fit into the traditional ACC grading schemes. Histologically, ACC with high-grade transformation was distinguished from conventional ACC by nuclear enlargement and irregularity, higher mitotic counts, and the loss of the biphasic ductal-myoeepithelial differentiation. Other features include comedonecrosis and fibrocellular desmoplasia. Poorly differentiated, sarcomatoid, or undifferentiated areas are extremely rare and not described, as yet, in cutaneous ACC.<sup>7</sup> Our case did not show these features.

Mohs surgical method has been used in the literature in recurrent adenoid cystic carcinoma cases.<sup>13</sup> In PCACC, chemotherapy is recommended in metastatic, symptomatic, recurrent or progressive cases. Chemotherapy can be applied in the form of single agent or combination therapy. There are no phase 3 studies on PCACC due to the low prevalence of the disease. Some case reports have shown that combined treatments such as cisplatin + 5 fluorouracil or cisplatin + doxorubicin provide regression in PCACC cases with lung metastasis.<sup>14</sup> Radiotherapy is used in adenoid cystic carcinoma cases with

salivary gland origin, and there is no literature data for radiotherapy in PCACC cases.

Despite the high rate of metastasis, long-term survival can be observed since disease progression is slow.<sup>14</sup>

## CONCLUSION

Scalp is one of the localization of many skin lesions. Lesions are generally benign and malignant formations are seen very rare. PCACC is also a rare malignancy and is clinically similar to benign skin lesions. For this reason, it is important to send every specimen excised from the scalp for pathological examination. In cases with unexpected frequent recurrence, a second pathological opinion is vital in terms of confirming the diagnosis and revising the treatment plan.

### Source of Finance

*During this study, no financial or spiritual support was received neither from any pharmaceutical company that has a direct connection with the research subject, nor from a company that provides or produces medical instruments and materials which may negatively affect the evaluation process of this study.*

### Conflict of Interest

*No conflicts of interest between the authors and / or family members of the scientific and medical committee members or members of the potential conflicts of interest, counseling, expertise, working conditions, share holding and similar situations in any firm.*

### Authorship Contributions

**Idea/Concept:** F. Nihal Durmuş Kocaaslan; **Design:** F. Nihal Durmuş Kocaaslan; **Control/Supervision:** Özhan Çelebiler; **Data Collection and/or Processing:** Caner Kaya; **Analysis and/or Interpretation:** F. Nihal Durmuş Kocaaslan; **Literature Review:** Caner Kaya; **Writing the Article:** Caner Kaya; **Critical Review:** F. Nihal Durmuş Kocaaslan; **References and Fundings:** Beyza Keskin; **Materials:** Zeliha Leyla Cinel.

**TABLE 1:** Differential diagnosis of primary adenoid cystic carcinoma of the skin.

|   |  |
|---|--|
| Primary Cutaneous Adenoid Cystic Carcinoma  | EMA, cytokeratin, S100, CD117 positive                                     |
| Adenoid type basal cell carcinoma           | Bcl 2 positive, S100, EMA, CEA, CK-7 negative                              |
| Cutaneous mucinous carcinoma                | P63 and CK7 positive   |
| Skin metastasis of adenoid cystic carcinoma | Similar immunohistochemical findings to PCACC and PAS (+) epithelial mucin |

## REFERENCES

1. Sumpio BE, Jennings TA, Merino MJ, Sullivan PD. Adenoid cystic carcinoma of the breast. Data from the connecticut tumor registry and a review of the literature. *Ann Surg.* 1987;205(3):295-301. [[Crossref](#)] [[PubMed](#)] [[PMC](#)]
2. Markel SF, Abell MR, Haight C, French AJ. Neoplasms of bronchus commonly designated as adenomas. *Cancer.* 1964;17:590-608. [[Crossref](#)] [[PubMed](#)]
3. Salzman MJ, Eades E. Primary cutaneous adenoid cystic carcinoma: a case report and review of the literature. *Plast Reconstr Surg.* 1991;88(1):140-4. [[Crossref](#)] [[PubMed](#)]
4. Dores GM, Huycke MM, Devesa SS, Garcia CA. Primary cutaneous adenoid cystic carcinoma in the United States: incidence, survival, and associated cancers, 1976 to 2005. *J Am Acad Dermatol.* 2010;63(1):71-8. [[Crossref](#)] [[PubMed](#)] [[PMC](#)]
5. Naylor E, Sarkar P, Perlis CS, Giri D, Gnepp DR, Robinson-Bostom L. Primary cutaneous adenoid cystic carcinoma. *J Am Acad Dermatol.* 2008;58(4):636-41. [[Crossref](#)] [[PubMed](#)]
6. Boggio R. Letter: Adenoid cystic carcinoma of the scalp. *Arch Dermatol.* 1975;111(6):793-4. [[Crossref](#)] [[PubMed](#)]
7. Ramakrishnan R, Chaudhry IH, Ramdial P, Lazar AJ, McMenamin ME, Kazakov D. Primary cutaneous adenoid cystic carcinoma: a clinicopathologic and immunohistochemical study of 27 cases. *Am J Surg Pathol.* 2013;37(10):1603-11. [[Crossref](#)] [[PubMed](#)]
8. An J, Park S, Sung SH, Cho MS, Kim SC. Unusual expression of thyroid transcription factor 1 and napsin A in metastatic adenoid cystic carcinoma of extrapulmonary origin in the lung. *Am J Clin Pathol.* 2014;141(5):712-7. [[Crossref](#)] [[PubMed](#)]
9. Conley J, Dingman DL. Adenoid cystic carcinoma in the head and neck (cylindroma). *Arch Otolaryngol.* 1974;100(2):81-90. [[Crossref](#)] [[PubMed](#)]
10. Spiro RH, Koss LG, Hajdu SI, Strong EW. Tumors of minor salivary origin. A clinicopathologic study of 492 cases. *Cancer.* 1973;31(1):117-29. [[Crossref](#)] [[PubMed](#)]
11. Allen MS, Marsh WL. Lymph node involvement by direct extension in adenoid cystic carcinoma: absence of classic embolic lymph node metastasis. *Cancer.* 1976;38(5):2017-21. [[Crossref](#)] [[PubMed](#)]
12. Jetley S, Jairajpuri ZS, Rana S, Talikoti MA. Adenoid basal cell carcinoma and its mimics. *Indian J Dermatol.* 2013;58(3):244. [[Crossref](#)] [[PubMed](#)] [[PMC](#)]
13. Lang PG, Metcalf JS, Maize JC. Recurrent adenoid cystic carcinoma of the skin managed by microscopically controlled surgery (Mohs surgery). *J Dermal Surg Oncol.* 1986;12(4):395-8. [[Crossref](#)] [[PubMed](#)]
14. Singh A, Ramesh V. Primary cutaneous adenoid cystic carcinoma with distant metastasis: a case report and brief literature review. *Indian J Dermatol Venereol Leprol.* 2010;76(2):176-9. [[Crossref](#)] [[PubMed](#)]