

## Long-term results of surgically assisted maxillary protraction vs regular facemask

Şirin Nevzatoğlu<sup>a</sup>; Nazan Küçükkeleş<sup>b</sup>

### ABSTRACT

**Objective:** To evaluate the short- and long-term treatment results of rapid maxillary expansion (RME) and surgical assistance during maxillary protraction with a facemask (FM).

**Materials and Methods:** This study was carried out in 28 patients (12 male, 16 female) with maxillary retrognathism, anterior crossbite, and Class III skeletal and dental malocclusion characteristics. Seventeen patients (9 male, 8 female) with mild maxillary retrognathism were treated by RME and FM. The other 11 patients (8 female, 3 male), who had moderate to severe maxillary retrognathism, were treated with surgically assisted FM treatment. Patients treated with RME and FM were recalled after 5.64 years, and the surgically assisted FM group was recalled after 6.08 years. Cephalometric films taken before treatment (T<sub>0</sub>), right after maxillary protraction (T<sub>1</sub>), and at recall (T<sub>2</sub>) were used to evaluate and compare the results.

**Results:** In the short term, good maxillary advancement and a shorter treatment period were achieved with surgically assisted FM therapy. However, in the long term, maxillary advancement and some soft tissue improvements were lost. On the other hand, in the RME and FM protraction group, maxillary advancement and soft tissue improvement were well maintained.

**Conclusion:** In the short term, statistically significant maxillary advancement was achieved with surgically assisted maxillary protraction. However, in the long term, these sagittal changes were not stable, whereas RME and FM provided stability. (*Angle Orthod.* 2014;84:1002–1009.)

**KEY WORDS:** Corticotomy; Facemask; Long-term; Class III; Stability

### INTRODUCTION

Orthodontic treatment of Class III malocclusion remains demanding. Studies have shown that the majority of Class III malocclusions have maxillary retrusion in addition to the mandibular prognathism, which is treatable if the patient is still growing and cooperative.<sup>1–3</sup> Generally, the use of a facemask (FM) is considered to be a common treatment protocol in growing maxillary retrognathic Class III cases.<sup>4</sup> Short-term treatment results achieved with the FM are

actually well documented in the orthodontic literature, and they can be summarized as a combination of forward movement of the maxilla, clockwise rotation of the mandible, proclination of the upper incisors, and retroclination of the lower incisors.<sup>5,6</sup> Although the main goal of this approach is to obtain forward movement of the maxilla, the reported mean values are no more than 2 mm in 6 to 12 months of treatment.<sup>4,7,8</sup>

On the other hand, it is impossible to achieve any advancement in patients who have completed their growth. Nowadays, distraction osteogenesis (DO) of the maxilla has become an accepted alternative for this group of patients. Several studies<sup>9–13</sup> have shown that it is possible to lengthen the maxilla and midface by 7 to 11 mm with DO. In many of these studies, rigid intraoral and extraoral devices were used, all of which are expensive and sophisticated. FM was also used during surgically assisted maxillary protraction in several studies.<sup>14,15</sup> Molina et al.<sup>14</sup> and Rachmiel et al.<sup>15–19</sup> achieved 3 to 12 mm of maxillary advancement with FM following LeFort I osteotomy in very short-term studies. However, short-term improvement does not always result in significant long-term improvement. For patients who receive orthopedic or

<sup>a</sup> Assistant Professor, Department of Orthodontics, School of Dentistry, University of Marmara, İstanbul, Turkey.

<sup>b</sup> Professor, Department of Orthodontics, School of Dentistry, University of Marmara, İstanbul, Turkey.

Corresponding author: Dr Şirin Nevzatoğlu, Marmara Üniversitesi, Diş Hekimliği Fakültesi, Ortodonti AD, Teşvikiye mah. Büyükciftlik sok. No. 6 k.3, 34365, Nişantaşı, Şişli, İstanbul, Türkiye  
(e-mail: sirin2288@hotmail.com, sirin.nevzatoglu@marmara.edu.tr)

Accepted: February 2014. Submitted: December 2013.

Published Online: March 21, 2014

© 2014 by The EH Angle Education and Research Foundation, Inc.

**Table 1.** Evaluation of General Properties of Groups

	Surgery-Assisted FM		RME and FM	<i>P</i> <sup>a</sup>
	Mean ± SD	Mean ± SD		
Chronological age (y)	12.54 ± 2.24	11.26 ± 1.89		ns
Skeletal age (y)	5.45 ± 2.02	3.00 ± 2.37		**
Force (g)	1872.73 ± 201.70	947.06 ± 369.32		**
Protraction time (mo)	5.58 ± 1.13	8.26 ± 3.32		*
Recall time (y)	5.64 ± 1.49	6.08 ± 0.61		ns

<sup>a</sup> Student's *t*-test: \* *P* < .05; \*\* *P* < .01.

surgical correction early, growth during adolescence is a critical indicator for long-term outcomes. It is therefore essential to evaluate the success of orthodontic treatment in the long term.

Some studies have reported on the long-term stability of DO<sup>20,21</sup>; however, few studies have reported on the long-term results and stability of rapid maxillary expansion (RME) and FM protocols.<sup>22,23</sup> On the other hand, no data are available with regard to the outcomes of surgical assistance during maxillary protraction with FM therapy when active craniofacial growth is complete. This information is very important for patients being treated with these protocols, because a significant tendency toward reestablishment of the Class III growth pattern has been widely demonstrated after active protraction therapy,<sup>24,25</sup> and pubertal growth tends to last longer in Class III subjects compared to Class I subjects.<sup>26</sup> In this study, therefore, we aimed to evaluate the short- and long-term treatment results of RME and surgical assistance during maxillary protraction with FM.

## MATERIALS AND METHODS

This retrospective study was carried out in 28 patients (12 male, 16 female), all of whom had maxillary retrognathism, anterior crossbite, Class III skeletal and dental malocclusion characteristics, and a concave profile (Table 1). To eliminate any pseudo-Class III patients, the initial discrepancy between centric occlusion and centric relation was evaluated. The study was approved by the Ethical Committee of the Medical Faculty of Marmara University, İstanbul, Turkey.

Cases with comparatively mild maxillary retrognathism (maxillary depth angle: 87.03 ± 3.44; Nper-A: -3.44 ± 3.05; Table 2) were treated by RME and FM; this group comprised 17 patients (9 male, 8 female) with a mean age of 11.26 ± 1.89 years (Table 1). According to a hand and wrist evaluation, these patients were in their prepeak growth period (3.00 ± 2.37, Table 1).

The other 11 patients (8 female, 3 male) with a mean age of 12.54 ± 2.24 years (Table 1) who had

moderate to severe maxillary retrognathism (maxillary depth angle: 83.32 ± 7.11; Nper-A: -6.68 ± 6.08; Table 2) were treated with a surgically assisted FM approach. According to a hand and wrist evaluation, these patients were at the age of peak growth (5.45 ± 2.02, Table 1).

Inclusion criteria were as follows: skeletal and dental Class III malocclusion, maxillary retrognathism (more than 6 mm deficiency in surgically assisted patients or more than 3 mm in the RME group), no mandibular prognathism, no pseudo Class III, no open bite, negative overjet, growth not complete, low/normal vertical growth pattern, adequate oral hygiene, and no caries.

## Treatment Protocol in Surgically Assisted Group

An acrylic cap appliance, without RME, according to the protocol of a previous study, was used in all patients.<sup>27</sup> Under general anesthesia, an incomplete LeFort I osteotomy was performed in each patient by the same surgeon. The osteotomy involved the lateral walls of the maxilla, starting from the aperture piriformis and extending to the tuberosity, without separation of the pterygomaxillary suture. FM was applied on the fifth to seventh day after surgery, with a mean total force value of 1872.73 ± 201.7 g. The elastics were oriented at a 30° angle to the occlusal plane. Patients were told to wear the FM 24 hours a day until Class II dental relationships were achieved, which took approximately 6 to 8 weeks. For retention and stability, patients were told to use the FM, without changing the amount of force, only at nighttime for another 3 months. Total mean treatment time was 5.58 ± 1.13 months. Following the retention period, treatment continued with a multibracket system in all patients. At the end of the treatment, fixed retainers were placed. Patients in this group were treated by the same orthodontist (ŞN) and recalled at 5.64 ± 1.49 years after the active protraction period, at which time the records were renewed.

## Treatment Protocol in RME Group

In the RME group, all patients underwent RME with an acrylic-covered hyrax appliance, according to the protocol of a previous study, regardless of whether they had posterior crossbite.<sup>27</sup> Patients were told to activate the hyrax screw twice a day, and FM was applied with a mean total force of 947.06 ± 369.32 g following the occurrence of median diastema. Elastics were oriented at a 30° angle to the occlusal plane. Patients were told to wear the FM nearly 16 hours a day until Class II dental relationships were achieved. Total mean treatment time was 8.26 ± 3.32 months. Following protraction, treatment continued with a multibracket system. Fixed retainers were placed.

**Table 2.** Evaluation of Sagittal Changes in Surgery-Assisted and RME and FM Protraction Groups at T<sub>0</sub>, T<sub>1</sub>, and T<sub>2</sub>

		T <sub>0</sub>	T <sub>1</sub>	T <sub>2</sub>	P <sup>a</sup>	T <sub>0</sub> -T <sub>1</sub> P <sup>b</sup>	T <sub>0</sub> -T <sub>2</sub> P <sup>b</sup>	T <sub>1</sub> -T <sub>2</sub> P <sup>b</sup>
		Mean ± SD	Mean ± SD	Mean ± SD				
SNA (°)	Surgery-assisted FM	75.14 ± 5.77	79.41 ± 3.47	75.32 ± 4.93	**	**	ns	**
	RME and FM	79.21 ± 2.27	81.24 ± 2.78	81.94 ± 3.19	**	**	**	ns
	P <sup>c</sup>	*	ns	**				
SNB (°)	Surgery-assisted FM	79.05 ± 4.19	77.45 ± 3.57	77.59 ± 6.52	ns	ns	ns	ns
	RME and FM	79.50 ± 2.39	78.56 ± 2.57	82.18 ± 3.27	**	*	**	**
	P <sup>c</sup>	ns	ns	*				
ANB (°)	Surgery-assisted FM	-3.18 ± 2.48	1.95 ± 2.09	-2.27 ± 3.83	**	**	ns	**
	RME and FM	-0.29 ± 1.87	2.68 ± 1.45	-0.24 ± 1.61	**	**	ns	**
	P <sup>c</sup>	**	ns	ns				
Maxillary depth angle (°)	Surgery-assisted FM	83.32 ± 7.11	87.68 ± 4.88	84.55 ± 3.01	**	**	ns	**
	RME and FM	87.03 ± 3.44	88.82 ± 3.51	88.29 ± 3.93	**	**	ns	ns
	P <sup>c</sup>	ns	ns	*				
Nper-A (mm)	Surgery-assisted FM	-6.68 ± 6.08	-2.59 ± 5.03	-6.18 ± 6.93	**	**	ns	*
	RME and FM	-3.44 ± 3.05	-1.18 ± 3.54	-1.68 ± 4.22	**	**	*	ns
	P <sup>c</sup>	ns	ns	*				
R2-A (mm)	Surgery-assisted FM	61.09 ± 4.80	65.95 ± 4.14	62.27 ± 5.04	**	**	ns	**
	RME and FM	66.41 ± 3.95	68.88 ± 4.66	69.03 ± 4.25	**	**	**	ns
	P <sup>c</sup>	**	ns	**				
R2-ANS (mm)	Surgery-assisted FM	65.55 ± 4.70	71.09 ± 4.19	66.73 ± 4.31	**	**	ns	**
	RME and FM	71.68 ± 4.39	73.59 ± 5.40	73.24 ± 4.42	**	**	*	ns
	P <sup>c</sup>	**	ns	**				
R2-PNS (mm)	Surgery-assisted FM	18.95 ± 4.06	21.73 ± 4.59	18.82 ± 5.02	**	*	ns	**
	RME and FM	22.38 ± 2.29	22.94 ± 3.30	24.62 ± 3.02	**	ns	*	ns
	P <sup>c</sup>	**	ns	**				
R2-UI (mm)	Surgery-assisted FM	62.55 ± 7.31	68.77 ± 5.75	68.68 ± 7.21	**	**	**	ns
	RME and FM	66.85 ± 4.37	70.62 ± 4.67	74.74 ± 4.47	**	**	**	**
	P <sup>c</sup>	ns	ns	*				
SN-UI (°)	Surgery-assisted FM	100.68 ± 9.47	103.18 ± 6.72	107.82 ± 8.85	**	ns	**	*
	RME and FM	98.41 ± 4.30	100.06 ± 2.77	111.26 ± 4.20	**	ns	**	*
	P <sup>c</sup>	ns	ns	ns				
R2-UM (mm)	Surgery-assisted FM	35.36 ± 5.27	42.14 ± 6.47	40.05 ± 6.69	**	**	**	ns
	RME and FM	38.56 ± 5.41	42.38 ± 5.71	44.74 ± 5.01	**	**	**	*
	P <sup>c</sup>	ns	ns	*				
R2-B (mm)	Surgery-assisted FM	63.41 ± 6.55	60.68 ± 6.37	61.27 ± 10.91	*	*	ns	ns
	RME and FM	65.26 ± 5.65	63.50 ± 5.86	60.26 ± 6.31	**	*	**	**
	P <sup>c</sup>	ns	ns	*				
IMPA (°)	Surgery-assisted FM	79.50 ± 6.97	78.27 ± 7.18	82.55 ± 7.70	*	ns	ns	*
	RME and FM	84.00 ± 4.30	80.79 ± 4.85	85.24 ± 5.83	**	*	ns	**
	P <sup>c</sup>	*	ns	ns				
R2-LI tip (mm)	Surgery-assisted FM	66.27 ± 5.10	64.05 ± 4.81	66.50 ± 7.88	ns	ns	ns	ns
	RME and FM	69.38 ± 4.14	67.09 ± 4.59	72.68 ± 4.40	**	**	**	**
	P <sup>c</sup>	ns	ns	*				

<sup>a</sup> Variance analysis; <sup>b</sup> Bonferroni test; <sup>c</sup> Student's *t*-test.

\* *P* < .05; \*\* *P* < .01.

The protraction of this group was done by the same orthodontist (ŞN). Patients in this group were recalled at a mean of 6.08 ± 0.61 years after the end of active protraction, at which time the records were renewed.

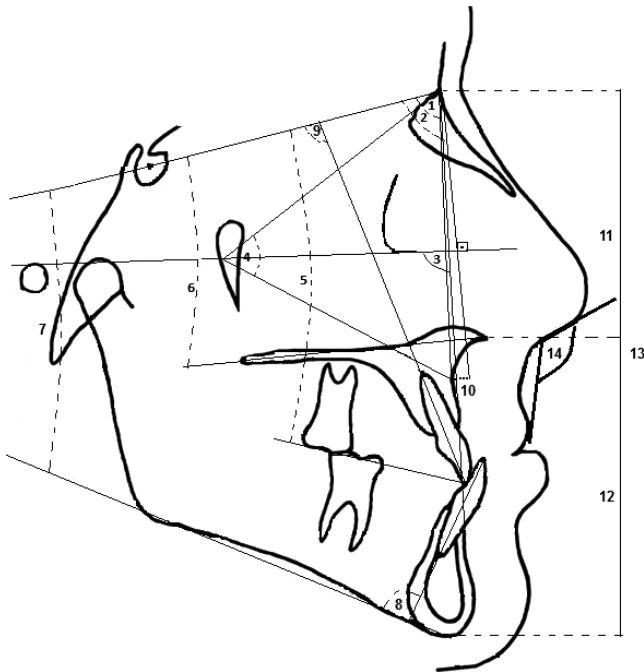
### Cephalometric Method

The study was carried out on lateral cephalometric films taken before treatment (T<sub>0</sub>), after protraction (T<sub>1</sub>), and at recall (T<sub>2</sub>). All phases of cephalometric analysis were conducted by the same orthodontist (ŞN) and the magnification of enlargement for all radiographs was calculated. On the initial (T<sub>0</sub>) cephalogram, a horizontal

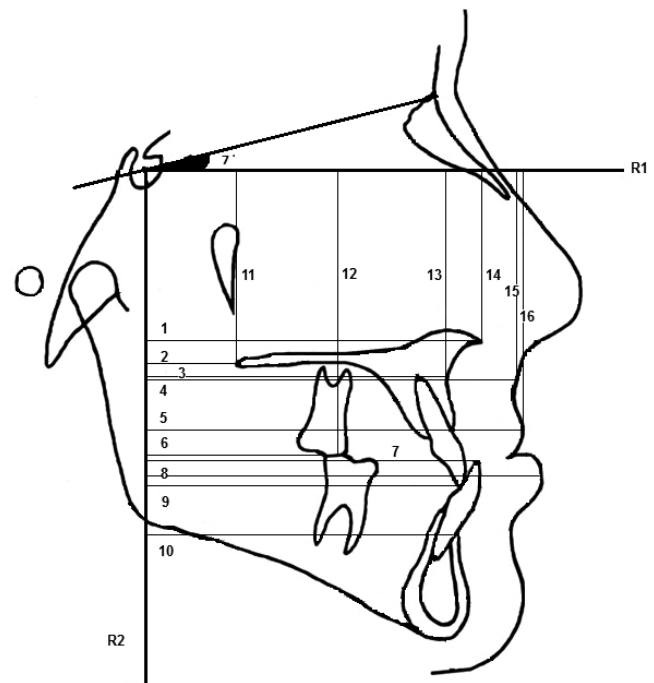
reference plane was drawn at an angle of 7° from SN plane at point S in a clockwise direction (R<sub>1</sub>). Then a vertical reference plane (R<sub>2</sub>) was formed by drawing a perpendicular line from S point to the horizontal reference plane. These horizontal (R<sub>1</sub>) and vertical (R<sub>2</sub>) reference planes were transferred to the postprotraction (T<sub>1</sub>) and recall (T<sub>2</sub>) cephalograms. Twenty-two linear and 11 angular parameters were measured (Figures 1 and 2).

### Statistical Evaluation

During the assessment of the data, the Statistical Package for the Social Sciences (SPSS for Windows



**Figure 1.** Skeletal, dental, and soft tissue variables used in this study. 1 indicates SNA ( $^{\circ}$ ); 2, SNB ( $^{\circ}$ ); 3, maxillary depth ( $^{\circ}$ ); 4, maxillary height ( $^{\circ}$ ); 5, SN-UOP ( $^{\circ}$ ); 6, SN-PP( $^{\circ}$ ); 7, SN-MP ( $^{\circ}$ ); 8, IMPA ( $^{\circ}$ ); 9, SN-UI ( $^{\circ}$ ); 10, Nper-A (mm); 11, N-ANS; 12, ANS-Me (mm); 13, N-Me (mm); and 14, NLA ( $^{\circ}$ ).



**Figure 2.** Linear variables according to reference planes used in this study: 1 indicates R2-ANS; 2, R2-PNS; 3, R2-A; 4, R2-A'; 5, R2-Ls; 6, R2-UM; 7, R2-LI; 8, R2-Li; 9, R2-UI; 10, R2-B; 11, R1-PNS; 12, R1-UM; 13, R1-A; 14, R1-ANS; 15, R1-A'; and 16, R1-Ls.

15.0, Chicago, Ill) was used. During the evaluation of the study data, with respect to the comparison of quantitative data as well as descriptive statistical methods (means, standard deviations), Student *t*-test was used for intergroup comparisons of parameters with normal distribution. Variance analysis and Bonferroni test were used for repeated measurements for in-group comparisons. Significance was evaluated at a level of  $P < .05$ .

To determine the method error, 12 randomly selected cephalograms were retraced and remeasured by the same investigator after an interval of 3 weeks. Intraclass correlation coefficients (ICCs) were calculated to assess the reliability of the measurements.

**RESULTS**

**Sagittal Measurements**

Sagittal measurements are shown in Table 2.

*Evaluation of sagittal parameters based on study groups.* Statistically significant differences were found between the groups in  $T_0$  and  $T_2$  for SNA, R2-A, R2-ANS, and R2-PNS measurements; however, at  $T_1$ , no significant difference was recorded.

At  $T_0$  and  $T_1$ , SNB, maxillary depth angle, Nper-A, and R2-B measurements revealed no significant differences between groups, while the differences for these parameters were significant at  $T_2$ .

At  $T_0$  and  $T_1$  there were no significant differences between groups for dental changes, represented by R2-UI, R2-UM, and R2-LI measurements, but at  $T_2$  they showed significant differences. Changes in SN-UI were not found to be statistically significant at any time between groups ( $P > .05$ ).

*Evaluation of sagittal changes in surgically-assisted group.* SNA, ANB, maxillary depth angle, Nper-A, R2-A, R2-ANS, and R2-PNS were found to be statistically significantly different between  $T_0$  and  $T_1$  and between  $T_1$  and  $T_2$ . There was no significant difference between  $T_0$  and  $T_2$ .

R2-UI and R2-UM were significantly different between  $T_0$  and  $T_1$  and between  $T_0$  and  $T_2$ , while there was no difference between  $T_1$  and  $T_2$ .

Changes in SNB and R2-LI were not found to be significant at any time ( $P > .05$ ).

*Evaluation of sagittal changes in RME group.* SNA, Nper-A, R2-A, and R2-ANS were found to be significantly between  $T_0$  and  $T_1$  and between  $T_0$  and  $T_2$ . There was no significant difference between  $T_1$  and  $T_2$ . R2-UI, R2-UM, SNB, R2-B, and R2-LI were significantly different between all periods.

**Vertical Measurements**

Vertical measurements are shown in Table 3.

*Evaluation of vertical parameters based on study groups.* Statistically significant differences were found

**Table 3.** Evaluation of Vertical Changes in Surgery-Assisted and RME and FM Protraction Groups at T<sub>0</sub>, T<sub>1</sub>, and T<sub>2</sub>

		T <sub>0</sub>	T <sub>1</sub>	T <sub>2</sub>	P <sup>a</sup>	T <sub>0</sub> -T <sub>1</sub> P <sup>b</sup>	T <sub>0</sub> -T <sub>2</sub> P <sup>b</sup>	T <sub>1</sub> -T <sub>2</sub> P <sup>b</sup>
		Mean ± SD	Mean ± SD	Mean ± SD				
SN-PP (°)	Surgery-assisted FM	10.05 ± 5.59	8.14 ± 3.69	9.86 ± 4.80	ns	ns	ns	ns
	RME and FM	10.29 ± 3.62	9.21 ± 3.85	8.03 ± 4.29	*	ns	*	ns
	P <sup>c</sup>	ns	ns	ns				
SN-UOP (°)	Surgery-assisted FM	21.05 ± 5.87	17.36 ± 7.67	18.64 ± 6.39	*	ns	*	ns
	RME and FM	21.62 ± 2.99	20.18 ± 3.17	12.44 ± 4.75	**	ns	**	**
	P <sup>c</sup>	ns	ns	**				
SN-MP (°)	Surgery-assisted FM	36.27 ± 3.74	38.64 ± 2.98	38.41 ± 7.19	*	*	ns	ns
	RME and FM	35.50 ± 4.64	36.97 ± 4.62	31.56 ± 4.61	**	**	**	**
	P <sup>c</sup>	ns	ns	**				
Maxillary height angle (°)	Surgery-assisted FM	63.32 ± 3.89	61.82 ± 3.06	64.55 ± 4.89	*	ns	ns	*
	RME and FM	61.38 ± 2.48	60.71 ± 3.28	60.53 ± 2.96	ns	ns	ns	ns
	P <sup>c</sup>	ns	ns	*				
R1-A (mm)	Surgery-assisted FM	50.41 ± 3.11	52.27 ± 3.36	52.00 ± 4.29	ns	ns	ns	ns
	RME and FM	51.24 ± 3.89	51.74 ± 4.02	51.65 ± 3.28	ns	ns	ns	ns
	P <sup>c</sup>	ns	ns	ns				
R1-ANS (mm)	Surgery-assisted FM	45.14 ± 2.81	46.00 ± 2.48	46.73 ± 4.00	ns	ns	ns	ns
	RME and FM	44.91 ± 3.93	45.44 ± 3.80	45.26 ± 3.50	ns	ns	ns	ns
	P <sup>c</sup>	ns	ns	ns				
R1-PNS (mm)	Surgery-assisted FM	43.32 ± 2.88	45.55 ± 3.57	45.14 ± 3.09	*	*	*	ns
	RME and FM	42.29 ± 4.66	44.24 ± 5.05	43.91 ± 4.55	**	**	*	ns
	P <sup>c</sup>	ns	ns	ns				
N-ANS (mm)	Surgery-assisted FM	54.50 ± 2.84	54.77 ± 3.20	56.00 ± 4.31	ns	ns	ns	ns
	RME and FM	53.88 ± 4.08	54.65 ± 3.94	52.38 ± 5.33	ns	ns	ns	ns
	P <sup>c</sup>	ns	ns	ns				
ANS-Me (mm)	Surgery-assisted FM	64.18 ± 7.02	68.68 ± 7.29	71.00 ± 7.13	**	**	**	ns
	RME and FM	62.79 ± 4.67	66.50 ± 5.21	67.94 ± 4.85	**	**	**	*
	P <sup>c</sup>	ns	ns	ns				
N-Me (mm)	Surgery-assisted FM	118.59 ± 7.02	123.77 ± 9.30	126.45 ± 8.76	**	**	**	ns
	RME and FM	116.71 ± 7.27	120.91 ± 8.01	121.71 ± 6.34	**	**	**	ns
	P <sup>c</sup>	ns	ns	ns				
ANS-Me/N-Me (ratio)	Surgery-assisted FM	54.09 ± 3.09	55.36 ± 2.11	56.09 ± 3.14	ns	ns	ns	ns
	RME and FM	54.00 ± 2.35	55.00 ± 1.90	56.06 ± 2.41	**	*	**	*
	P <sup>c</sup>	ns	ns	ns				
R1-U1 (mm)	Surgery-assisted FM	71.36 ± 4.47	74.77 ± 4.11	75.77 ± 7.54	**	**	ns	ns
	RME and FM	71.32 ± 5.01	73.21 ± 4.79	72.00 ± 3.93	**	**	ns	ns
	P <sup>c</sup>	ns	ns	ns				
R1-UM (mm)	Surgery-assisted FM	64.68 ± 4.73	69.23 ± 5.09	70.27 ± 6.49	**	**	**	ns
	RME and FM	63.59 ± 5.67	66.47 ± 5.78	66.79 ± 7.41	**	**	**	ns
	P <sup>c</sup>	ns	ns	ns				

<sup>a</sup> Variance analysis; <sup>b</sup> Bonferroni test; <sup>c</sup> Student's *t*-test.

\* *P* < .05; \*\* *P* < .01.

at T<sub>2</sub> between groups for SN-UOP, SN-MP, and maxillary height angle measurements (*P* > .05). No statistically significant changes were noted for all other vertical parameters (*P* > .05).

*Evaluation of vertical changes in surgically-assisted group.* SN-MP, R1-PNS, ANS-Me, N-Me, R1-U1, and R1-UM were found to be significantly different between T<sub>0</sub> and T<sub>1</sub>, while SN-UOP, R1-PNS, ANS-Me, N-Me, and R1-UM were significantly different between T<sub>0</sub> and T<sub>2</sub>. Except for maxillary height angle, there were no significant differences between T<sub>1</sub> and T<sub>2</sub> for other parameters.

*Evaluation of vertical changes in RME group.* SN-MP, R1-PNS, ANS-Me, N-Me, ANS-Me/N-Me, R1-U1, and R1-UM were found to be significantly different

between T<sub>0</sub> and T<sub>1</sub>, whereas SN-UOP, SN-MP, R1-PNS, ANS-Me, N-Me, ANS-Me/N-Me, and R1-UM were significantly different between T<sub>0</sub> and T<sub>2</sub>. SN-UOP, SN-MP, ANS-Me, and ANS-Me/N-Me were significant during the T<sub>1</sub>-T<sub>2</sub> period.

### Soft Tissue Measurements

Soft tissue measurements are shown in Table 4.

*Evaluation of soft tissue changes based on study groups.* Statistically significant differences were found between the groups at T<sub>0</sub> and T<sub>2</sub> for R2-A'. At T<sub>0</sub> and T<sub>1</sub>, R2-Ls and R2-Li revealed no significant difference between groups, while the differences for these parameters were significant at T<sub>2</sub>.

**Table 4.** Evaluation of Soft Tissue Changes in Surgery-Assisted and RME and FM Protraction Groups at T<sub>0</sub>, T<sub>1</sub>, and T<sub>2</sub>

		T <sub>0</sub>	T <sub>1</sub>	T <sub>2</sub>	P <sup>a</sup>	T <sub>0</sub> -T <sub>1</sub> P <sup>b</sup>	T <sub>0</sub> -T <sub>2</sub> P <sup>b</sup>	T <sub>1</sub> -T <sub>2</sub> P <sup>b</sup>
		Mean ± SD	Mean ± SD	Mean ± SD				
R2-A' (mm)	Surgery-assisted FM	61.09 ± 4.80	65.95 ± 4.14	62.27 ± 5.04	**	**	*	ns
	RME and FM	64.41 ± 3.95	68.88 ± 4.66	69.03 ± 4.25	**	**	**	ns
	P <sup>c</sup>	**	ns	**				
R2-Ls (mm)	Surgery-assisted FM	78.73 ± 6.59	83.73 ± 6.45	81.73 ± 7.42	**	**	ns	ns
	RME and FM	82.76 ± 4.85	85.12 ± 5.27	88.41 ± 5.36	**	**	**	**
	P <sup>c</sup>	ns	ns	*				
R1-A' (mm)	Surgery-assisted FM	53.50 ± 3.50	54.32 ± 4.44	53.59 ± 4.74	ns	ns	ns	ns
	RME and FM	53.09 ± 4.11	54.68 ± 3.97	52.00 ± 4.20	**	**	ns	**
	P <sup>c</sup>	ns	ns	ns				
R1-Ls (mm)	Surgery-assisted FM	63.95 ± 4.05	66.50 ± 5.32	66.41 ± 5.83	ns	ns	ns	ns
	RME and FM	63.24 ± 5.04	65.24 ± 4.68	63.35 ± 4.27	**	**	ns	*
	P <sup>c</sup>	ns	ns	ns				
NLA (°)	Surgery-assisted FM	94.23 ± 15.14	108.09 ± 14.61	98.18 ± 12.60	*	*	ns	*
	RME and FM	107.85 ± 14.77	110.41 ± 12.76	100.53 ± 9.65	**	ns	*	**
	P <sup>c</sup>	*	ns	ns				
R2-Li (mm)	Surgery-assisted FM	81.36 ± 5.69	81.23 ± 5.72	78.68 ± 6.31	ns	ns	ns	ns
	RME and FM	83.44 ± 5.51	82.44 ± 5.75	87.47 ± 5.56	**	ns	**	**
	P <sup>c</sup>	ns	ns	**				

<sup>a</sup> Variance analysis; <sup>b</sup> Bonferroni test; <sup>c</sup> Student's *t*-test.

\*  $P < .05$ ; \*\*  $P < .01$ .

At T<sub>0</sub> there was a significant difference between groups for NLA, but at T<sub>1</sub> and T<sub>2</sub> there were no significant differences. Changes in R1-A' and R1-Ls were not found to be statistically significant at any time between groups ( $P > .05$ ).

*Evaluation of soft tissue changes in surgically-assisted group.* R2-A', R2-Ls, and NLA measurements were found to be significantly different between T<sub>0</sub> and T<sub>1</sub>. R2-A' was also significantly different between T<sub>0</sub> and T<sub>2</sub> and NLA between T<sub>1</sub> and T<sub>2</sub>.

*Evaluation of soft tissue changes in RME group.* R2-A', R2-Ls, R1-A', and R1-Ls measurements were found to be significantly different between T<sub>0</sub> and T<sub>1</sub>. R2-A', R1-Ls, NLA, and R2-Li were also significantly different between T<sub>0</sub> and T<sub>2</sub>, and all parameters except R2-A' were found to be significantly different between T<sub>1</sub> and T<sub>2</sub>.

### Reliability of the Measurements

Reliability of the measurements was calculated for each parameter separately. In all samples, the ICC was found to be close to 1.00. The results of method error analysis showed that all measurements could be reproduced with nonfatal errors.

### DISCUSSION

The long-term outcomes following protraction therapies evaluated at the end of active craniofacial growth are very important for patients with Class III malocclusion.

In the surgically-assisted protraction group, despite the high values achieved for maxillary advancement and the shorter treatment time, after 5.64 years, the

cephalometric examination revealed a loss of sagittal maxillary advancement, together with the loss of some soft tissue improvement. The stable mandible, the decrease in SNB angle, and R2-B distance remained unchanged after treatment. Although surgically-assisted FM therapy is described as a DO protocol in the literature, its long-term stability rates are, surprisingly, not comparable with those of other published DO cases.<sup>20,21,28,29</sup> Kanno et al.<sup>30</sup> showed that DO of the maxilla ensures a very stable midface, offering a promising treatment alternative for patients with maxillary hypoplasia, while Gürsoy et al.<sup>31</sup> stated that although the overall treatment results were stable, the dentoskeletal treatment outcome relapsed over time.

On the other hand, in the RME group, during treatment, significant protraction was noted in the short term; however, after 6.08 years, the cephalometric examination revealed well-maintained maxillary advancement, with no relapse in the sagittal position and soft tissue with the forward-positioned mandible. This finding is in agreement with other orthodontic studies reporting long-term maxillary stability of traditional FM cases.<sup>22-25,32</sup> Williams et al.<sup>33</sup> concluded that the relapse to a Class III pattern was primarily a result of mandibular growth rather than a relapse of treatment in the maxilla.

To explain the sagittal relapse observed in the surgically-assisted protraction group, we should refer to the retention protocol used in this treatment modality. In our method, we aimed to make an overcorrection by advancing the maxilla until the canines were in a Class II relationship. Patients changed their full-time FM wear to nighttime only,

without changing the force magnitude, for another 3 months. Because reorganization of a newly formed bone takes time after DO, it would probably be wiser to simply decrease the force value and to continue FM use full-time throughout the retention period.

In both groups, in both the short and the long term, there was significant proclination of the upper and lower incisors, ie, dental camouflage. During protraction, the upper molars moved forward in both groups. In the long term, in the surgically-assisted group, the molars maintained their position, whereas in the RME group, forward movement of the molars continued. This meant that, in the short term, molars followed the skeletal forward movement of the upper jaw, while in the long term, because of the growth of the mandible, the upper dentition underwent continued mesialization.

A statistically significant decrease was found during the follow-up period between groups for SN-MP and SN-UOP measurements, which can be explained by the sagittal late mandibular growth and proclination of the upper incisors. Values for lower facial height (ANS-Me) and total facial height (N-Me) increased during and after treatment in both groups by the same amount.

The advancement of soft tissue achieved during protraction in both groups was similar; however, during the follow-up period, changes in the RME group were found to be more stable than those in the surgically-assisted group. The initial treatment results regarding the sagittal relationship of the lower lip showed no difference between groups; however, during the follow-up period, the lower lip of the RME patients was positioned more forward, indicating late mandibular growth in this group.

## CONCLUSIONS

- In the short term, statistically significant maxillary advancement was achieved. Although these sagittal changes were not stable in the surgically assisted maxillary FM protraction group, they were stable in the RME and FM protraction group.
- Patients who will be treated with surgically assisted maxillary protraction should be selected very carefully. Low-angle Class III patients with severe maxillary retrognathism that could not be treated with the conventional orthopedic correction alone, patients who have completed growth and missed their chance for orthopedic correction, and patients who are unwilling to have orthognathic surgery can be treated successfully with this method.

## REFERENCES

1. Jacobson A, Evans WG, Preston LB, Sadowsky PW. Mandibular prognathism. *Am J Orthod.* 1974;66:140–171.

2. Kapust AJ, Sinclair PM, Turley PK. Cephalometric effects of face mask/expansion therapy in Class III children: a comparison of three age groups. *Am J Orthod Dentofacial Orthop.* 1998;113:204–212.
3. Sue G, Chanoca SJ, Turley PK, Itoh J. Indicators of skeletal Class III growth. *J Dent Res.* 1987;66:343.
4. Bacetti T, McGill JS, McNamara JA Jr, Tollaro I. Skeletal effects of early treatment of Class III malocclusion with maxillary expansion and face-mask therapy. *Am J Orthod Dentofacial Orthop.* 1998;113:333–343.
5. McNamara JA Jr. An orthopedic approach to the treatment of Class III malocclusion in young patients. *J Clin Orthod.* 1987;21:598–608.
6. Turley PK. Orthopedic correction of Class III malocclusion with palatal expansion and custom protraction headgear. *J Clin Orthod.* 1988;22:314–325.
7. Da Silva Filho OG, Magro AC, Capelozza Filho L. Early treatment of the Class III malocclusion with rapid maxillary expansion and maxillary protraction. *Am J Orthod Dentofacial Orthop.* 1998;113:196–203.
8. Alcan T, Keles A, Erverdi N. The effect of a modified protraction headgear on maxilla. *Am J Orthod Dentofacial Orthop.* 2000;117:27–38.
9. Cohen SR. Craniofacial distraction with a modular internal distraction system: evolution of design and surgical techniques. *Plast Reconstr Surg.* 1999;103:1592–1607.
10. Kessler P, Wiltfang J, Schultze-Mosgau S, Hirschfelder U, Neukam FW. Distraction osteogenesis of the maxilla and midface using a subcutaneous device: report of four cases. *Br J Oral Maxillofac Surg.* 2001;39:13–21.
11. Hierl T, Hemprich A. A novel modular retention system for midfacial distraction osteogenesis. *Br J Oral Maxillofac Surg.* 2000;38:623–626.
12. Polley JW, Figueroa AA. Rigid external distraction: its application in cleft maxillary deformities. *Plast Reconstr Surg.* 1998;102:1360–1372.
13. Figueroa AA, Polley JW. Management of severe cleft maxillary deficiency with distraction osteogenesis: procedure and results. *Am J Orthod Dentofacial Orthop.* 1999;115:1–12.
14. Molina F, Ortiz Monasterio F, de la Paz Aguilar M, Barrera J. Maxillary distraction: aesthetic and functional benefits in cleft lip-palate and prognathic patients during mixed dentition. *Plast Reconstr Surg.* 1998;101:951–963.
15. Rachmiel A, Aizenbud D, Ardekian L, Peled M, Laufer D. Surgically-assisted orthopedic protraction of the maxilla in cleft lip and palate patients. *Int J Oral Maxillofac Surg.* 1999;28:9–14.
16. Rachmiel A, Potparic Z, Jackson IT, et al. Midface advancement by gradual distraction. *Br J Plast Surg.* 1993;46:201–207.
17. Rachmiel A, Levy M, Laufer D, Clayman L, Jackson IT. Multiple segmental gradual distraction of facial skeleton: an experimental study. *Ann Plastic Surg.* 1996;36:52–59.
18. Rachmiel A, Lewinson D, Eizenbud D, Rosen D, Laufer D. Distraction osteogenesis for hypoplastic facial bones. *Harefuah.* 1997;132:833–836.
19. Rachmiel A, Aizenbud D, Peled M. Application of Ilizarov method in maxillofacial treatment. *Harefuah.* 2003;142:359–363.
20. Wiltfang J, Hirschfelder U, Neukam FW, Kessler P. Long-term results of distraction osteogenesis of the maxilla and midface. *Br J Oral Maxillofac Surg.* 2002;40:473–479.
21. Rachmiel A, Aizenbud D, Peled M. Long-term results in maxillary deficiency using intraoral devices. *Int J Oral Maxillofac Surg.* 2005;34:473–479.

22. Masucci C, Franchi L, Defraia E, Mucedero M, Cozza P, Bacetti T. Stability of rapid maxillary expansion and facemask therapy: a long-term controlled study. *Am J Orthod Dentofacial Orthop*. 2011;140:493–500. doi: 10.1016/j.ajodo.2010.09.031.
23. Pangrazio-Kulbersh V, Berger JL, Janisse FN, Bayırlı B. Long-term stability of Class III treatment: rapid palatal expansion and protraction facemask vs LeFort I maxillary advancement osteotomy. *Am J Orthod Dentofacial Orthop*. 2007;131:7.e9–19.
24. Ngan PW, Hagg U, Yiu C, Wei SH. Treatment response and long-term dentofacial adaptations to maxillary expansion and protraction. *Semin Orthod*. 1997;3:255–264.
25. Westwood PV, McNamara JA Jr, Baccetti T, Franchi L, Sarver DM. Long-term effects of Class III treatment with rapid maxillary expansion and facemask therapy followed by fixed appliances. *Am J Orthod Dentofacial Orthop*. 2003;123:306–320.
26. Kuc-Michalska M, Baccetti T. Duration of the pubertal peak in skeletal Class I and Class III subjects. *Angle Orthod*. 2010;80:54–57.
27. Küçükkeleş N, Nevzatoğlu S, Koldaş T. Rapid maxillary expansion compared to surgery for assistance in maxillary face mask protraction. *Angle Orthod*. 2011;81(1):42–49.
28. Figueroa AA, Polley JW, Friede H, Ko EW. Long-term skeletal stability after maxillary advancement with distraction osteogenesis using a rigid external distraction device in cleft maxillary deformities. *Plast Reconstr Surg*. 2004;114:1382–1392.
29. Harada K, Sato M, Omura K. Long-term skeletal and dental changes in patients with cleft lip and palate after maxillary distraction: a report of three cases treated with a rigid external distraction device. *Cranio*. 2005;23:152–157.
30. Kanno T, Mitsugi M, Hosoe M, Sukegawa S, Yamauchi K, Furuki Y. Long-term skeletal stability after maxillary advancement with distraction osteogenesis in nongrowing patients. *J Oral Maxillofac Surg*. 2008;66:1833–1846.
31. Gürsoy S, Hukki J, Hurmerinta K. Five-year follow-up of maxillary distraction osteogenesis on the dentofacial structures of children with cleft lip and palate. *J Oral Maxillofac Surg*. 2010;68:744–750. Epub 2010 Jan 15.
32. Chen L, Chen R, Yang Y, Ji G, Shen G. The effects of maxillary protraction and its long-term stability—a clinical trial in Chinese adolescents. *Eur J Orthod*. 2012;34:88–95. Epub 2011 Feb 16.
33. Williams MD, Sarver DM, Sadowsky PL, Bradley E. Combined rapid maxillary expansion and protraction facemask in the treatment of Class III malocclusions in growing children: a prospective long-term study. *Semin Orthod*. 1997;3:265–274.