

## Research Article

# Mid-term results of intralesional extended curettage, cauterization, and polymethylmethacrylate cementation in the treatment of giant cell tumor of bone: A retrospective case series

Evrım Şirin , Ahmet Hamdi Akgülle , Osman Mert Topkar , Ömer Sofulu , Said Erkam Baykan , Bülent Erol

Department of Orthopaedic Surgery and Traumatology, Marmara University, School of Medicine, İstanbul, Turkey

## ARTICLE INFO

## Article history:

Submitted 20 July 2019  
Received in revised form  
25 November 2019  
Last revision received  
29 March 2019  
Accepted 16 April 2020

## Keywords:

Giant cell tumor of bone  
Curettage  
Polymethylmethacrylate  
Recurrence  
Local adjuvant

## ORCID iDs of the authors:

E.Ş. 0000-0002-4752-2725;  
A.H.A. 0000-0002-1216-9589;  
O.M.T. 0000-0003-2452-1954;  
Ö.S. 0000-0002-5210-224X;  
S.E.B. 0000-0002-5064-4475;  
B.E. 0000-0001-7099-6374.

## ABSTRACT

**Objective:** The aim of this study was to present the mid-term functional outcomes and recurrence rate in patients with giant cell tumor of bone (GCTB) treated by intralesional extended curettage, electrocauterization, and polymethylmethacrylate (PMMA) cementation.

**Methods:** In this retrospective observational study, 79 consecutive patients (41 females, 38 males; mean age=39 years; age range=19-62 years) who were diagnosed and treated for GCTB between 2005 and 2017 were identified from hospital medical records. All patients were treated by intralesional extended curettage using high-speed burr, electrocauterization of the cavity, and filling the defect with PMMA. No additional local adjuvants were used. The mean follow-up period was 47 months (range=24-96). The tumors were graded according to the radiological classification system described by Campanacci. Functional outcomes were evaluated using the Musculoskeletal Tumor Society Score (MSTS) preoperatively, one year postoperatively, and at the final follow-up. Postoperative complications and recurrence rates were recorded.

**Results:** Twenty-nine tumors were located in the distal femur, 23 in the proximal tibia, nine in the distal radius, five in the proximal humerus, five in the pelvis, three in the proximal fibula, two in the distal ulna, two in the distal tibia, and one in the second metatarsal. According to Campanacci classification, 37 tumors were grade III, 32 grade II, and 10 grade I. The mean MSTS score was 46.1% (range 40.2 to 71.4%) preoperatively, 91.7% (range 73.3% to 100%) one year postoperatively, and 86.3% (range 66.2% to 96.1%) at the final follow-up. The overall complication rate was 7.6%; which included local tumor recurrence in four patients, superficial wound infection in one, and deep wound infection in another. The recurrence rate was 5.1% (4 patients). Recurrent tumors were located at the distal femur in three patients and proximal tibia in one.

**Conclusion:** With satisfactory functional results and low recurrence rates at the mid-term follow-up, GCTB can be treated effectively with intralesional extended curettage, electrocauterization, and PMMA cementation.

**Level of Evidence:** Level IV, Therapeutic study

## Introduction

Giant cell tumor of bone (GCTB) is a primary benign disease that accounts for approximately 5% of all primary bone tumors (1). They are mainly located at the metaphysis and metaepiphyseal parts of the long bones, causing a localized osteolytic lesion. The two most commonly involved regions are distal femur and proximal tibia; however, any part of the human skeleton can be affected (2, 3). The peak incidence of the disease is usually in the third decade of life with a slight female predominance (4). It is a tumor of mesenchymal origin, and the tumor cells are primarily composed of stromal cells and multinucleated giant cells (5). The best treatment method should cover both the assurance of local control and maintenance of local function (6).

Intralesional extended curettage is the standard treatment method but it has been associated with local recurrence rates ranging from 10% to 40% (7). As a result, in order to decrease these high recurrence rates, the use of some physical and chemical adjuvants have been advocated by most authors (8). Local agents such

as alcohol, phenol, and hydrogen peroxide are widely used as chemical adjuvants. Other local agents like liquid nitrogen, standard cauterization, and argon plasma coagulation, iodine, cyclophosphamide and local radiation can be applied as well (9). However, they have been used heterogeneously, and their effect on recurrence-free survival has never been proven. On the other hand, polymethylmethacrylate (PMMA) is an important adjuvant used in the treatment of GCTB. It has a strong structural property and decreases the recurrence rates by its thermal cytotoxic effect (10, 11).

The aim of our study is to report mid-term functional results and recurrence rates in patients with GCTB who were treated with intralesional extended curettage using high-speed burr, cauterization of the bone cavity, and PMMA cementation without adding any other chemical or physical adjuvant to the procedure. The main hypothesis of the study is that satisfactory functional results can be achieved in the treatment of GCTB with the abovementioned set of surgical techniques, and low recurrence rates can still be obtained without adding any other additional chemical or physical local adjuvants to the procedure.

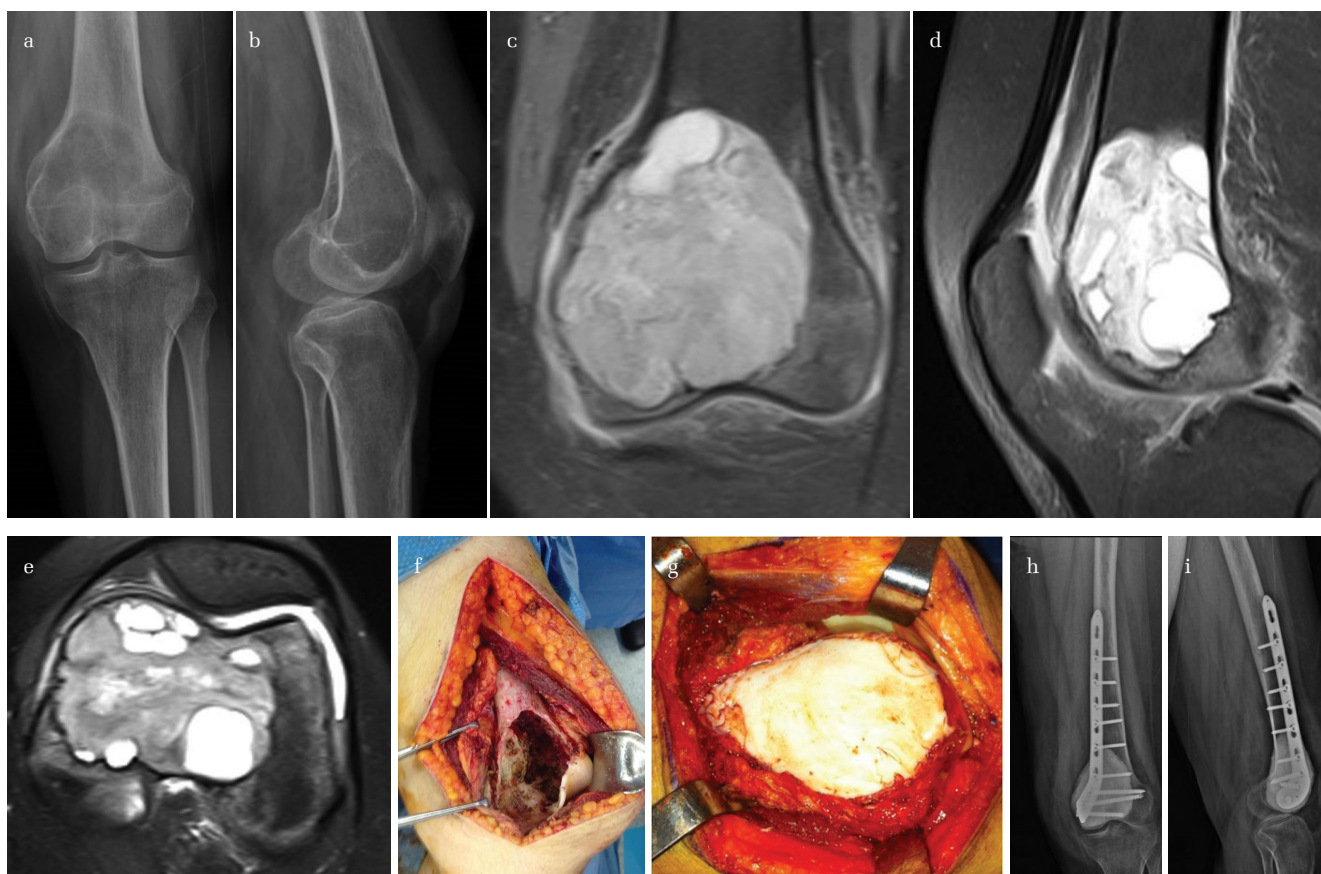
## Corresponding Author:

Evrım Şirin  
evrimsirin@yahoo.com



Content of this journal is licensed under a Creative Commons Attribution-NonCommercial 4.0 International License.

Cite this article as: Şirin E, Akgülle AH, Topkar OM, Sofulu Ö, Baykan SE, Erol B. Mid-term results of intralesional extended curettage, cauterization, and polymethylmethacrylate cementation in the treatment of giant cell tumor of bone: A retrospective case series. Acta Orthop Traumatol Turc 2020; 54(5): 524-9



**Figure 1.** a-i. Giant cell tumor of distal femur (a-e). Initially a cortical window is opened, this window is enlarged, the whole cavity is visualized, and the gross lesion is curetted. The technique of curettage is based on using curettes of different sizes and a high-speed burr. After the standard cauterization procedure, the cavity is filled with PMMA (f, g). Depending on the size, location, and remaining bone stock following extended curettage, PMMA can be augmented with plate and/or screw fixation (h, i)

## Materials and Methods

We conducted a retrospective study based on the review of patient records and imaging data. We identified 103 patients with a histologically confirmed diagnosis of GCTB between 2005 and 2017. Patients in whom the native joint adjacent to GCTB was preserved by performing intralesional extended curettage with a high-speed burr, cauterization of the bone cavity, and PMMA cementation without adding any other local adjuvant to the procedure were included in the study. Twenty four of the 103 patients in whom primary en-bloc resection and endoprosthesis replacement was performed due to intraarticular breach of the tumor were excluded from the study, leaving 79 patients in the study cohort. Medical records, plain ra-

diographs, computerized tomography (CT), and magnetic resonance imaging (MRI) scans were all reviewed. All biopsy and surgical curettage materials were reviewed and confirmed by the Department of Pathology of Marmara University İstanbul Pendik Training and Research Hospital.

The tumors were graded according to a radiological classification system described by Campanacci (12). According to this classification, lesions with a well-defined, non-sclerotic medullary margins that do not cause cortical disruption are graded as grade I. Grade II lesions also have well-defined, non-sclerotic medullary margins; however, they cause cortical erosion and thinning of the bony cortex; the margins of grade III lesions are unclear, the bony cortex is completely destroyed, and there is soft tissue and even joint invasion.

Preoperatively, all patients underwent a closed biopsy procedure using a percutaneous Jam-Shidi needle for a definitive diagnosis. Intralesional extended curettage was the main surgical procedure. The technique of curettage was based on using curettes and high-speed burrs. Initially, a large window was opened on the bony cortex for grade I and grade II lesions. This window was enlarged to visualize the whole cavity, and the gross lesion was curetted. As the next step, the inner cortical wall of the cavity was burred down with a high-speed burr device and then cauterized (Figure 1. a-f). This procedure was repeated several times. While using the high-speed burr, care was taken to avoid further cortical breakdown or any soft tissue damage. The cavity was washed off by a pulsatile lavage to clean debris.

## HIGHLIGHTS

- Due to the periarticular location and extremely high recurrence rates of GCTB, the ideal treatment still remains controversial.
- Many physical and chemical agents have been introduced to prevent recurrence, however they have both beneficial and harmful effects and their comparative action on tumor cells is not well described.
- Surgical treatment of GCTB with intralesional extended curettage using a high-speed burr and electrocauterization followed by cementation with PMMA without adding another physical or chemical adjuvant is a sufficient, safe, and effective method.

Great care was also taken to avoid damaging the underlying cartilage during the management of periarticular lesions. For grade III lesions that had already destroyed a cortical wall, the same procedure was performed after removal of the tumor from the cavity and surrounding soft tissue.

Finally, the cavity was filled with PMMA (Figure 1g). We augmented the fixation with metallic implants in 11 patients. In these patients, the remaining bone stock was very limited following the extended curettage, and subjectively, we assumed that a postoperative fracture was very likely. We used only screws for eight patients and plate and screw fixation for the remaining three patients (Figure 1. h-i). All these lesions were grade II and grade III lesions. In these patients, when the burring procedure was completed, PMMA was applied after inserting the implant. No other local adjuvants such as liquid nitrogen, hydrogen peroxide, phenol, or alcohol were used in any case as we believed that they had no additional beneficial action other than their side effects.

In the postoperative period, the patients were allowed to rapidly advance motion and gradual weightbearing as soon as the soft tissue healing occurred depending on the location and size of the tumor. For lesions around the knee joint, passive and active range of motion (ROM) exercises were started immediately after surgery. For all lower extremity lesions, gradual weightbearing was started during the immediate postoperative period; patients were given a pair of crutches for the first six weeks. For the following two weeks, they were allowed to walk with a single crutch, and full weightbearing was allowed two months after surgery. For all upper extremity lesions, patients were given a sling for one week for pain relief. Passive ROM exercises were started and conducted to the extent of patients' pain threshold. Active exercises were started two weeks later. Lifting heavy objects was prohibited for at least two months for all patients with grade II and III upper extremity lesions.

The patients were followed up every three months in the first year. Between the first and third year after surgery, they were seen twice a year. After the third year, follow-up examinations were performed annually.

Routine follow-up examinations included functional and radiological evaluations. Conventional radiographs of the extremity in two planes and a chest radiograph were considered for the radiological follow-up. If there was a suspicion of local recurrence, additional imaging, including MRI and CT, was performed. A radiolucent line seen around the cement border on conventional roentgenograms was considered a probable sign for recurrence. In case of radiological suspicion for recurrence, closed biopsy was performed before any definitive surgical intervention and histopathological detection of stromal cells with multinucleated giant cells confirmed the diagnosis.

Functional evaluation was performed with Musculoskeletal Tumor Society Scoring System (MSTS) (13). Routine MSTS evaluations were made preoperatively and at the end of first year. According to MSTS, pain, function, limping, and walking distance for the lower extremity as well as position of the hand and elevation of the upper extremity were taken into consideration (7). In addition, any surgical complications during the postoperative period were evaluated. Correlation between the tumor recurrence and grade, location, and pathological fracture was analyzed. This study was approved by the ethical committee of the Marmara University, School of Medicine (no. 09.2019/589). Written informed consent was obtained from patients and/or patients' family members who participated in this study.

### Statistical analysis

We used the Chi-squared test for statistical analysis. A p value of <0.05 was considered significant.

### Results

Of the remaining 79 patients, 41 were female and 38 were male with a mean age of 39 (range 19 to 62) years. Twenty-seven of the patients were referred from other institutions due to recurrent disease following their initial surgeries. Follow-up was conducted for all patients, and all data were retrieved from complete medical records. The involved bones were distal femur (n=29) followed by proximal tibia (n=23). The other locations were distal radius (n=9), proximal humerus (n=5), pelvis (n=5), proximal fibula (n=3), distal ulna (n=2), distal tibia (n=2), and second metatarsal bone (n=1). The mean follow-up period was 47 months (range 24 to 96 months). In the current series, most lesions were grade III (n=37) followed by grade II (n=32) and grade I (n=10). Complete clinical recovery was achieved in 92% of the patients within three to six months postoperatively. The mean MSTS score before the operation was 46.1% (range 40.2% to 71.4%). The mean MSTS scores obtained one year after surgery and at final follow-up visits were 91.7% (range 73.3% to 100%) and 86.3% (range 66.2% to 96.1%), respectively. None of the patients had complications due to the biopsy procedure. No complications such as limping, osteoarthritis, postoperative fracture, or malignant transformation were observed at 6, 12, 24 months, and the final follow-up visits post surgery.

The overall complication rate was 7.6%, as local tumor recurrence was observed in four patients and wound infection was observed in two. The wound infection was superficial in one patient and in the other one, it was deep, and they both occurred at the distal femoral region following surgical treatment of grade III lesions. The patient with the deep infection who also had plate and screws at the surgical site underwent a rough debridement procedure without any implant removal followed by parenteral first generation cephalosporin (1 g, 4 times a day) treatment for two weeks. The superficial infection was eradicated with an oral first generation cephalosporin (500 mg, 3 times a day) treatment for ten days and wound care. Tumor recurrence was detected in four patients (5.1%) in whom recurrent lesions were located in the distal femur in three patients and in the proximal tibia in one. All these recurrences occurred within 36 months after the surgery. In these patients, the remaining bone stock was too limited for further curettage and fixation, so we did not insist on repeating intralesional surgery and decided to perform resection and endoprosthetic replacement.

The recurrence was diagnosed by clinical findings including pain and swelling and by visualization of a radiolucent line around the cement border. MRI supported this radiographic finding and demonstrated extension of the tumor. The patients with recurrent disease did not have any pathological fracture before, thus we could not find any significant correlation between pathologic fracture and recurrence. Even though all recurrences occurred around the knee joint, there was no statistical correlation between the tumor location and recurrence ( $p = 0.648$ ). As all recurrences were grade III lesions, we found a statistically significant correlation between the grade of the tumor and the recurrence ( $p = 0.032$ ).

One of the patients with recurrent disease also had pulmonary metastases in the second postoperative year. He was referred to the department of medical oncology and started denosumab treatment. When denosumab treatment was stopped, the patient underwent metastasectomy operation for pulmonary lesions followed by endoprosthetic replacement operation for recurrent GCTB.

## Discussion

The mainstay of treatment for GCTB is surgery, and surgical management includes either simple curettage, extended intralesional curettage with or without the use of local adjuvant agents, or wide resection (14, 15). However, due to the periarticular location of the tumor and extremely high recurrence rates, the ideal treatment still remains controversial (16). The recurrence rate of GCTB treated with simple curettage has been reported between 30% and 50% (17). However, the introduction of extended intralesional curettage with a high-speed burr device has dramatically dropped the recurrence rates in these local aggressive lesions (18). In a study performed Blackley et al., the recurrence rate in GCTB following extended curettage, and allograft packing was reported as only 12% without the use of any adjuvant (19). Although the recurrence rate can be minimized by en-bloc resection of the tumor, resection with wide margins requires complex reconstruction procedures with large segmental allografts or endoprosthetic implants which increase the rate of surgical complications and disabilities (20). Several complications are inevitable at long-term follow-up, therefore the functional results of en-bloc resection of these periarticular tumors are poor, particularly when their benign nature is taken into consideration. On the other hand, curettage alone is not sufficient for complete eradication of GCTB because of its highly aggressive behavior. Therefore, adjuvant measures are absolutely advised as standard procedure (21-23).

The recurrence is much more likely when there is soft tissue invasion and a lack of integrity of the bony envelope (24). Treatment of a recurrent GCTB is also a challenging issue. Intralesional surgery can still be considered in recurrent cases unless there is a marked soft tissue extension or a complicated pathological fracture where structural integrity cannot be regained after a reconstruction attempt (24). In the current series, 24 out of our 103 patients were excluded and underwent en-bloc resection and endoprosthetic replacement. One of the reasons for our low recurrence rates (5.1%) probably relies on the right patient choice for the right treatment method.

Many authors advocate a combined approach in the management of GCTB, including curettage, electrocauterization, burring, phenol irrigation, hydrogen peroxide use, and PMMA. However, the beneficial and harmful effects of these local cytotoxic agents is controversial (25). Besides, the comparative effect of these compounds on the tumor cells is not well known (25).

In the current study, we noted the benefit from the adjuvant effect of electrocautery and PMMA after extended intralesional curettage only. Heat application is an important technique to decrease recurrence in local aggressive bone lesions. The use of cauterization in the treatment of bone tumors is preferred by many authors and is used worldwide. Aydin et al. reported that tumor cells beyond a distance of 6 mm can be destroyed in a single subject, and safe margins can be achieved by using electrocautery (26). We used standard cauterization in every patient after completing the curettage. We did not add any other special chemical or physical adjuvants to widen the surgical margins. We also did not use bone graft to fill the bone defects; instead, we used PMMA as a chemical adjuvant for its additional benefit of thermal cytotoxicity. Besides, PMMA provides structural support and allows early motion and weightbearing (27, 28). However, PMMA has adverse effects like thermal damage to the subchondral bone and articular cartilage that leads to early degenerative changes in the adjacent joints (29). Nonetheless, Errani et al. emphasized the positive role of PMMA as a local adjuvant, mechanical support, and also early detector of local recurrence on their series with 349 patients (6).

Phenol is another commonly used local adjuvant. It's a corrosive compound and can cause chemical burns on contact with skin and soft tissues. Therefore, it should be handled with great care (30). The greatest tissue penetration can be achieved when 6% phenol solution is applied for 3 minutes or more (31). Use of higher concentrations might result in bone necrosis and systemic intoxication (32). However, in a study published by Trieb et al., local recurrence rate of GCTB treated with or without phenol was reported to be similar (33). In another study performed by Gortzak et al., the local effect of ethanol, phenol, hydrogen peroxide, and zinc chloride were studied in vitro with a limited number of patients (25). Their results suggested that the use of these chemical compounds could improve local control in the treatment of GCTB, and the short half-life of hydrogen peroxide would make it particularly more feasible to use. We did not use phenol, ethanol, or hydrogen peroxide in our series.

In another study performed by Arbeitsgemeinschaft Knochentumoren, the recurrence rate of GCTB was analyzed following different treatment methods on 384 consecutive surgical procedures (34). This large heterogenous study yielded a 98% recurrence-free outcome for wide resection procedures. This rate was 78% for the group that was treated only with adjuvant PMMA, 73% for a combination of phenol and PMMA, and 85% for those treated with other local agents. As a whole, the group treated with adjuvant therapy had significantly lower recurrence rates when compared with the group that did not receive any adjuvant treatment. However, there was no significant difference among the type of local agents regarding the rate of local recurrence. In another article published by Ruggieri et al., the effect of local adjuvants on sacral GCT was analyzed (35). Their results indicated that the likelihood of local recurrence was not changed with the use of any adjuvant in this location, and the complication rate was extremely high.

Another important adjuvant agent in the treatment of GCTB is denosumab. It's a fully humanized monoclonal antibody that inhibits osteoclast-mediated bone destruction. At the beginning of its discovery, this agent generated great hope, particularly regarding the medical treatment of recurrent disease, because of its rapid and consistent effect in halting the progression of the tumor (36). Besides, it was found to stimulate the formation of an osseous rim around the lesion and make the tumor much more suitable for surgical resection (37). However, the exact use of denosumab is still controversial in orthopedic oncology. Traub et al. reported that good clinical and radiological responses can be obtained with neoadjuvant denosumab that facilitates joint preserving surgery in particular; however, it has no effect on the local recurrence rate of GCTB following resection and hence remains a concern (38). According to Tsukamoto et al., denosumab treatment should be reserved for patients having tumor with a large soft tissue component close to neurovascular structures or where en-bloc resection is impossible due to complex anatomic location and extensive blood loss is likely or in cases where pulmonary metastases are present (39). They emphasized the need for more definitive and randomized studies for its exact use. We used denosumab only in one patient who had local recurrence associated with pulmonary metastases.

Finally, Tsukamoto et al. published an article very recently in which they compared experienced and less experienced surgeons who treated GCTB. In this study, PMMA was considered the only important univariate and multivariate predictor of local recurrence after completing intralesional curettage (40).

Previously, it was thought that pathologic fracture is also a risk factor for local recurrence; however, recent studies do not confirm this

relation (41, 42). Chen et al. emphasized that the probability of local recurrence increases especially when the tumor exhibits soft tissue extension (43). This fact was also a valid argument for our series.

Recent studies focus on the biomolecular background of GCT and underline the importance and overexpression of CD44, VEGF (an important factor for tumor angiogenesis), and ezrin for the occurrence, biological invasion, recurrence, and distant metastasis of the disease (44). These parameters can be used as significant predictors for the prognosis of these patients in the future.

There are some limitations of the current study. It has a retrospective structure, and more importantly lacks a control group. Besides, the different locations and grades of the lesions make the group heterogeneous. However, at the end of the first year, most of our patients showed remarkable improvement in their limb functions. We think that surgical treatment of GCTB with intralesional extended curettage using high-speed burr and electrocauterization followed by cementation with PMMA is a sufficient, safe, and effective method.

In conclusion, despite its local aggressive behavior, GCTB can be effectively treated with intralesional extended curettage with high-speed burr and electrocauterization followed by cementation without adding any chemical or physical local adjuvant to the procedure, and satisfactory functional results with low recurrence rates can be obtained.

**Ethics Committee Approval:** Ethics committee approval was received for this study from the Ethical Committee of the Marmara University, School of Medicine (no. 09.2019/589).

**Informed Consent:** Written informed consent was obtained from patients and/or patients' family members who participated in this study.

**Author Contributions:** Concept - E.Ş., B.E.; Design - E.Ş., A.H.A., O.M.T.; Supervision - E.Ş., B.E.; Materials - E.Ş., Ö.S., A.H.A., B.E.; Data Collection and/or Processing - S.E.B., E.Ş.; Analysis and/or Interpretation - A.H.A., O.M.T., E.Ş., Ö.S.; Literature Search - E.Ş., S.E.B.; Writing Manuscript - E.Ş., B.E.; Critical Review - A.H.A., B.E., E.Ş.

**Conflict of Interest:** The authors have no conflicts of interest to declare.

**Financial Disclosure:** The authors declared that this study has received no financial support.

## References

- Klenke FM, Wenger DE, Inwards CY, Rose PS, Sim FH. Recurrent giant cell tumor of long bones: analysis of surgical management. *Clin Orthop Relat Res* 2011; 469: 1181-7. [\[Crossref\]](#)
- Dahlin DC, Cupps RE, Johnson EW Jr. Giant-cell tumor: A study of 195 cases. *Cancer* 1970; 25: 1061-70.
- Deveci MA, Paydas S, Gonlusen G, Ozkan C, Bicer OS, Tekin M. Clinical and pathological results of denosumab treatment for giant cell tumors of bone: Prospective study of 14 cases. *Acta Orthop Traumatol Turc* 2017; 51: 1-6. [\[Crossref\]](#)
- Teixeira LE, Vilela JC, Miranda RH, Gomes AH, Costa FA, de Faria VC. Giant cell tumors of bone: nonsurgical factors associated with local recurrence. *Acta Orthop Traumatol Turc* 2014; 48: 136-40. [\[Crossref\]](#)
- Gao ZH, Yin JQ, Xie XB, et al. Local control of giant cell tumors of the long bone after aggressive curettage with and without bone cement. *BMC Musculoskelet Disord* 2014; 15: doi: 10.1186/1471-2474-15-330. [\[Crossref\]](#)
- Errani C, Ruggieri P, Asenzio MAN, et al. Giant cell tumor of the extremity: A review of 349 cases from a single institution. *Cancer Treat Rev* 2010; 36: 1-7. [\[Crossref\]](#)
- Fraquet N, Faizon G, Rosset P, Philippeau JM, Waast D, Gouin F. Long bones giant cells tumors: treatment by curettage and cavity filling cementation. *Orthop Traumatol Surg Res* 2009; 95: 402-6. [\[Crossref\]](#)
- Moon MS, Kim SS, Moon JL, Kim SS, Moon H. Treating giant cell tumours with curettage, electrocautery, burring, phenol irrigation, and cementation. *J Orthop Surg* 2013; 21: 209-12. [\[Crossref\]](#)
- Omlor GW, Lange L, Streit M, et al. Retrospective analysis of 51 intralesionally treated cases with progressed giant cell tumor of the bone: Local adjuvant use of hydrogen peroxide reduces the risk for tumor recurrence. *World J Surg Oncol* 2019; 17: 73. doi: 10.1186/s12957-019-1613-9. [\[Crossref\]](#)
- Algawahmed H, Turcotte R, Farrokhyar F, Ghert M. High-Speed Burring with and without the use of surgical adjuvants in the intralesional management of giant cell tumor of bone: A systematic review and meta-analysis. *Sarcoma* 2010; doi: 10.1155/2010/586090. Epub 2010 Jul 27. [\[Crossref\]](#)
- Zuo D, Zheng L, Sun W, Fu D, Hua Y, Cai Z. Contemporary adjuvant polymethyl methacrylate cementation optimally limits recurrence in primary giant cell tumor of bone patients compared to bone grafting: a systematic review and meta-analysis. *World J Surg Oncol* 2013; 11: 156. doi: 10.1186/1477-7819-11-156. [\[Crossref\]](#)
- Campanacci M. Giant-cell tumor and chondrosarcomas: grading, treatment and results (studies of 209 and 131 cases). *Recent Results Cancer Res* 1976; 54: 257-61. [\[Crossref\]](#)
- Enneking WF, Dunham W, Gebhardt MC, Malawar M, Pritchard DJ. A system for the functional evaluation of reconstructive procedures after surgical treatment of tumors of the musculoskeletal system. *Clin Orthop Relat Res* 1993; 286: 241-6. [\[Crossref\]](#)
- O'Donnell RJ, Springfield DS, Motwani HK, Ready JE, Gebhardt MC, Mankin HJ. Recurrence of giant-cell tumors of the long bones after curettage and packing with cement. *J Bone Joint Surg Am* 1994; 76: 1827-33. [\[Crossref\]](#)
- Hasan O, Ali M, Mustafa M, Ali A, Umer M. Treatment and recurrence of giant cell tumors of bone - A retrospective cohort from a developing country. *Ann Med Surg (Lond)* 2019; 48: 29-34. [\[Crossref\]](#)
- Niu X, Zhang Q, Hao L, et al. Giant cell tumor of the extremity: Retrospective analysis of 621 Chinese patients from one institution. *J Bone Joint Surg Am* 2012; 94: 461-7. [\[Crossref\]](#)
- Sakamoto A. Joint preserved reconstruction after curettage in giant cell tumor of bone arising in the distal radius: Case report. *Int J Surg Case Rep* 2015; 16: 181-3. [\[Crossref\]](#)
- Raskin KA, Schwab JH, Mankin HJ, Springfield DS, Hornicek FJ. Giant cell tumor of bone. *Am Acad Orthop Surg* 2013; 21: 118-26. [\[Crossref\]](#)
- Blackley HR, Wunder JS, Davis AM, White LM, Kandel R, Bell RS. Treatment of giant-cell tumors of long bones with curettage and bone-grafting. *J Bone Joint Surg Am* 1999; 81: 811-20. [\[Crossref\]](#)
- Sobti A, Agrawal P, Agarwala S, Agarwal M. Giant cell tumor of bone - An overview. *Arch Bone Jt Surg* 2016; 4: 2-9.
- Van der Heijden L, van de Sande MA, Dijkstra PD. Soft tissue extension increases the risk of local recurrence after curettage with adjuvants for giant-cell tumor of the long bones. *Acta Orthop* 2012; 83: 401-5. [\[Crossref\]](#)
- Yu X, Xu M, Xu S, Su Q. Clinical outcomes of giant cell tumor of bone treated with bone cement filling and internal fixation, and oral bisphosphonates. *Oncol Lett* 2013; 5: 447-51. [\[Crossref\]](#)
- Balke M, Schremper L, Gebert C, et al. Giant cell tumor of bone: treatment and outcome of 214 cases. *J Cancer Res Clin Oncol* 2008; 134: 969-78. [\[Crossref\]](#)
- Van der Heijden L, Dijkstra PD, Campanacci DA, Gibbons CL, van de Sande MA. Giant cell tumor with pathologic fracture: should we curette or resect? *Clin Orthop Relat Res* 2013; 471: 820-9. [\[Crossref\]](#)
- Gortzak Y, Kandel R, Dehesi B, et al. The efficacy of chemical adjuvants on giant-cell tumour of bone. An in vitro study. *J Bone Joint Surg Br* 2010; 92: 1475-9. [\[Crossref\]](#)
- Aydin M, Basarir K, Armangil M, et al. Thermal necrosis induced by electrocauterization as a local adjuvant therapy in local aggressive bone tumors, what is the safe limit for surgical margins? An experimental study. *Arch Orthop Trauma Surg* 2015; 135: 1071-6. [\[Crossref\]](#)
- Gaston CL, Bhumbra R, Watanuki M, et al. Does the addition of cement improve the rate of local recurrence after curettage of giant cell tumours in bone? *J Bone Joint Surg Br* 2011; 93: 1665-9. [\[Crossref\]](#)
- Radev BR, Kase JA, Askew MJ, Weiner SD. Potential for thermal damage to articular cartilage by PMMA reconstruction of a bone cavity following tumor excision: A finite element study. *J Biomech* 2009; 42: 1120-6. [\[Crossref\]](#)
- Lin WH, Lan TY, Chen CY, Wu K, Yang RS. Similar local control between phenol- and ethanol-treated giant cell tumors of bone. *Clin Orthop Relat Res* 2011; 469: 3200-8. [\[Crossref\]](#)
- Mittag F, Leichte C, Kieckbusch I, et al. Cytotoxic effect and tissue penetration of phenol for adjuvant treatment of giant cell tumours. *Oncol Lett* 2013; 5: 1595-8. [\[Crossref\]](#)
- Quint U, Müller RT, Müller G. Characteristics of phenol. Instillation in intralesional tumor excision of chondroblastoma, osteoclastoma and enchondroma. *Arch Orthop Trauma Surg* 1998; 117: 43-6. [\[Crossref\]](#)
- Trieb K, Bitzan P, Lang S, Dominikus M, Kotz R. Recurrence of curetted and bone-grafted giant-cell tumours with and without adjuvant phenol therapy. *Eur J Surg Oncol* 2001; 27: 200-2. [\[Crossref\]](#)
- Knochenentumoren A, Becker WT, Dohle J, et al. Local recurrence of giant cell tumor of bone after intralesional treatment with and without adjuvant therapy. *J Bone Joint Surg Am* 2008; 90: 1060-7. [\[Crossref\]](#)
- Ruggieri P, Mavrogenis AF, Ussia G, Angelini A, Papagelopoulos PJ, Mercuri M. Recurrence after and complications associated with adjuvant treatments for sacral giant cell tumor. *Clin Orthop Relat Res* 2010; 468: 2954-61. [\[Crossref\]](#)
- Agarwal MG, Gundavda MK, Gupta R, Reddy R. Does denosumab change the giant cell tumor treatment strategy? Lessons learned from early experience. *Clin Orthop Relat Res* 2018; 476: 1773-82. [\[Crossref\]](#)
- Campanacci L, Sambri A, Medellin MR, Cimatti P, Errani C, Donati DM. A new computerized tomography classification to evaluate response to Denosumab in giant cell tumors in the extremities. *Acta Orthop Traumatol Turc* 2019; 53: 376-80. [\[Crossref\]](#)

38. Traub F, Singh J, Dickson BC, et al. Efficacy of denosumab in joint preservation for patients with giant cell tumour of the bone. *Eur J Cancer* 2016; 59: 1-12. [\[Crossref\]](#)
39. Tsukamoto S, Tanaka Y, Mavrogenis AF, Kido A, Kawaguchi M, Errani C. Is treatment with denosumab associated with local recurrence in patients with giant cell tumor of bone treated with curettage? A Systematic Review. *Clin Orthop Relat Res* 2020; 478: 1076-85. [\[Crossref\]](#)
40. Tsukamoto S, Mavrogenis AF, Tanzi P, et al. Curettage as first surgery for bone giant cell tumor: adequate surgery is more important than oncology training or surgical management by high volume specialized teams. *Eur J Orthop Surg Traumatol* 2020; 30: 3-9. [\[Crossref\]](#)
41. Biscaglia R, Bacchini P, Bertoni F. Giant cell tumor of the bones of the hand and foot. *Cancer* 2000; 88: 2022-32.
42. Van der Heijden L, Dijkstra PDS, van de Sande MAJ, et al. The clinical approach toward giant cell tumor of bone. *Oncologist* 2014; 19: 550-61. [\[Crossref\]](#)
43. Chen L, Ding XY, Wang CS, et al. In-depth analysis of local recurrence of giant cell tumour of bone with soft tissue extension after intralesional curettage. *Radiol Med* 2014; 119: 861-70. [\[Crossref\]](#)
44. Zhang J, Dong J, Yang Z, et al. Expression of ezrin, CD44, and VEGF in giant cell tumor of bone and its significance. *World J Surg Oncol* 2015; 13: 168. [\[Crossref\]](#)