

The Importance of Clinical, Histopathologic and Direct Immunofluorescent Examinations in Differential Diagnosis Of Lichen Planus and Desquamative Gingivitis: Report of Two Cases

Liken Planus ve Deskuamatif Gingivitis Ayırıcı Tanısında Klinik, Histopatolojik ve Direkt İmmünfloresan İncelemelerin Önemi: İki Olgu Sunumu

*Filiz NAMDAR PEKİNER DDS, PhD, **Rıfkiye KÜÇÜKOĞLU MD,
***Vakur OLGAC DDS PhD, *Emre AYTUĞAR

*Marmara University, Faculty of Dentistry, Department of Oral Diagnosis and Radiology

**Istanbul University, School of Medicine, Department of Dermatology

***Istanbul University, Institute of Oncology, Department of Oncologic Cytology and Tumor Pathology

ABSTRACT

The aim of this study was to state the importance of clinical, histopathologic and direct immunofluorescent examinations in differential diagnosis of lichen planus and desquamative gingivitis. In this study, two cases of lichen planus affecting the attached gingivae were presented. Desquamative gingivitis was considered as differential diagnosis in both cases. Incisional biopsy was performed in both cases. The specimens were evaluated by histopathologic and direct immunofluorescent examinations. Histopathologic and direct immunofluorescent examinations supported the diagnosis of bullous lichen planus in both cases. As a conclusion; using the combination of clinical, histopathologic and direct immunofluorescent examinations is necessary for the diagnosis of lichen planus affecting the attached gingiva and differential diagnosis of desquamative gingivitis.

KEYWORDS

Bullous lichen planus, Desquamative gingivitis,
Histopathology, Direct immunofluorescence

ÖZET

Bu çalışmanın amacı, liken planus ve deskuamatif gingivitisin ayırıcı tanısında klinik, histopatolojik ve direkt immünfloresan incelemelerin önemini belirtmektir. Bu çalışmada, yapışık dişetini etkileyen iki liken planus olgusu sunulmuştur. Her iki olguda da ayırıcı tanı olarak deskuamatif gingivitis düşünülmüştür. Olguların her ikisine de insizyonel biyopsi yapıp, alınan parçalar histopatolojik ve direkt immünfloresan incelemeler ile değerlendirilmiştir. Olgularda yapılan histopatolojik ve direkt immünfloresan incelemeler büllöz liken planusu desteklemiştir. Sonuç olarak; klinik, histopatolojik ve direkt immünfloresan incelemelerin kombinasyonunun kullanılması yapışık dişetini etkileyen liken planusun tanısında ve deskuamatif gingivitisin ayırıcı tanısında önemlidir.

ANAHTAR KELİMELER

Büllöz liken planus, Deskuamatif gingivitis,
Histopatoloji, Direkt immünfloresan

INTRODUCTION

Lichen planus is a skin disease common within the oral cavity, where it appears as either white reticular, plaque or erosive lesions with a prominent T-lymphocyte response in the immediate underlying connective tissue^{1-10,11,12}.

Although the reason, etiology unknown, it is generally considered to be an immunological hypersensitivity reaction. It is characterized by an intensive T-cell infiltrate localized in the epithelium-connective tissue interface^{1-10,13}. Most patients with lichen planus are middle-aged or elder adults. Women predominate in most series of cases, usually by a 3:2 ratio over men^{1-3,5}.

Several types of lichen planus within the oral cavity have been described. The oral lesions are reticular, papular, bullous, plaque-like, atrophic, erosive and/or ulcerating¹⁻¹¹. Of the many types of lichen planus described in the literature, papular and reticular lichen planus are the most common. A rarely encountered form of lichen planus is the bullous variant. The bullae range from a few millimeters to centimeters in diameter. Such bullae are generally short lived and leave a painful ulcer on rupturing^{2,7,8,14,15}.

Lesions are usually seen on the buccal mucosa and less common on the tongue, inner aspect of the lips and gingiva^{2,14,15}. Gingival manifestations of lichen planus are relatively rare. If bullous or erosive forms are present at the attached gingivae, the clinician will note a high degree of similarity with desquamative gingivitis⁴.

When mucous membrane pemphigoid is limited to the gingiva, desquamative gingivitis is the clinic term to describe red, painful, glazed and friable gingivae which may be a manifestation of some mucocutaneous conditions such as lichen planus or the vesiculobullous disorders^{5,6,9,10,16,17}.

The microscopic criteria for lichen planus include hyperkeratosis and basal layer vacuolization¹⁻¹⁰. Destruction of the basal cell layer of the epithelium (hydropic degeneration) is also evident. This is accompanied by an intense, band-

like infiltrate of predominantly T-lymphocytes immediately subjacent to the epithelium¹⁻¹⁰. Within the epithelium, rounded or ovoid amorphous eosinophilic bodies, referred to as Civatte bodies, are sometimes present. Direct immunofluorescent examination for lichen planus, demonstrates deposit of fibrinogen along the basement membrane, with vertical extensions into the immediate underlying connective tissue^{1-3,5,9,17-19}. Although immunoglobulins and complement factors may be found as well, they are far less common than fibrinogen deposits.

In desquamative gingivitis, the microscopic findings consist of a thinned epithelium that exhibits some attenuation of the rete pegs. Separation occurs at the basement membrane and leaves a connective tissue that is diffusely infiltrated with lymphocytes, some plasma cells and occasional eosinophils. Direct immunofluorescence stains reveal a deposit of IgG antibody and C3 that follows the basement membrane in a smooth and linear pattern^{1,2,9,10,20}.

In this paper, the importance of clinical, histopathologic and direct immunofluorescence examinations in the differential diagnosis of lichen planus and bullous diseases are presented in two female patients.

CASE REPORT

Two female patients at the age of 39 and 60 were referred to Marmara University, Faculty of Dentistry, Department of Oral Diagnosis and Radiology, with the complaints of prolonged burn and pain with hot, cold, spicy foods and toothbrushing at their gingivae. Our provisional diagnosis was lichen planus on the basis of the history and clinical examinations of the patients and desquamative gingivitis was considered for the differential diagnosis (Figure 1,2).

After the patients were informed about the disease and getting their approval, incisional biopsy was performed in both cases at Department of Oral Diagnosis and Radiology. The

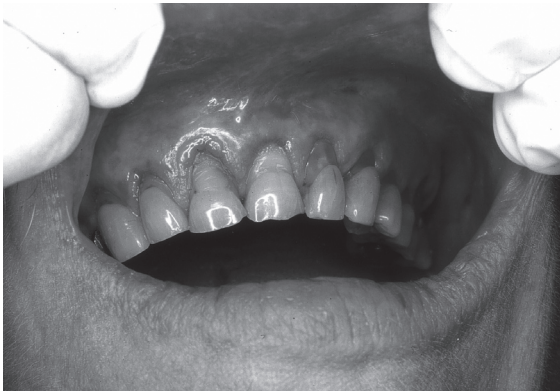
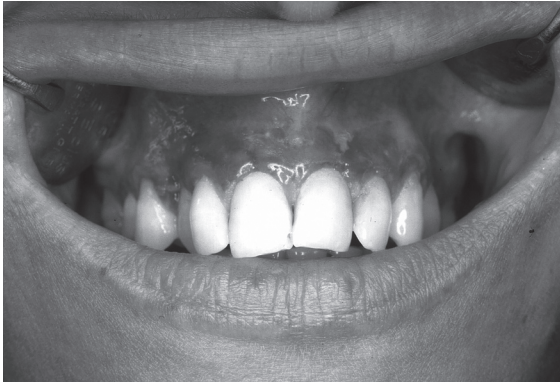
FIGURE 1&2

Intra oral clinical appearance of the cases, lesions on the attached gingiva of maxilla

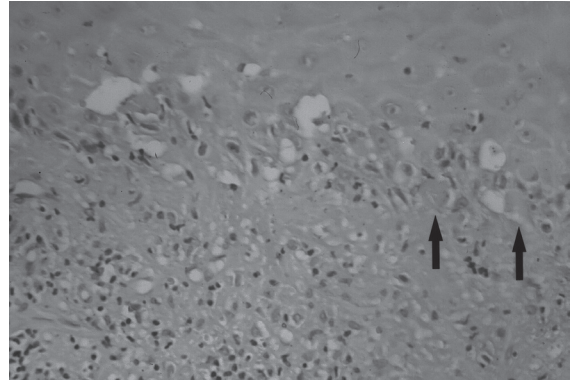


FIGURE 3

Disorder in the basal layer of the epithelium, hydropic degeneration and civatte bodies (↑) (H&E X250)

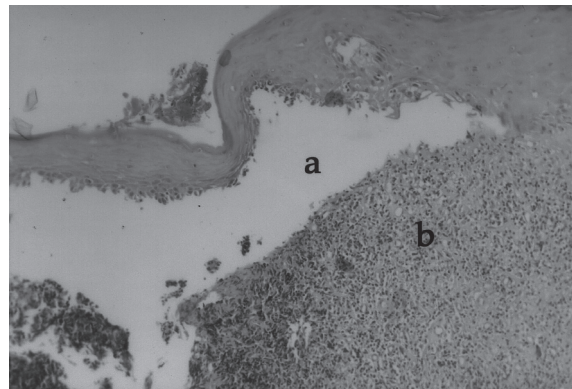


FIGURE 4

Separation of the epithelium (a) and band-like T-lymphocyte infiltration (b) (H&E X100)

specimens were evaluated by histopathologic examination at Istanbul University, Institute of Oncology, Department of Oncologic Cytology and Tumor Pathology and direct immunofluorescent examination was performed at Istanbul University, School of Medicine, Department of Dermatology. According to the hydropic degeneration, bandlike infiltrate of T-lymphocytes, Civatte bodies and separation of epithelium, the histopathologic diagnosis supported the bullous variant of lichen planus in both cases (Figure 3,4).

However, for the precise result, direct immunofluorescent examination was suggested. In direct immunofluorescent examinations, linear deposit of fibrinogen seen in lichen planus was established at the basement membrane in both cases (Figure 5).

Histopathologic and direct immunofluorescent examinations led to our final diagnosis of bullous lichen planus and the treatment was started in both cases.

DISCUSSION

Oral lichen planus is a relatively common inflammatory disease affecting between 0.5 % and 2.2 % of the population¹⁻¹¹. Most patients who experience this disorder are middle-aged or elderly, and 60 % are female¹⁻¹⁰. In this study, both patients of lichen planus were female. One of the patient was middle-aged and the other was elderly.

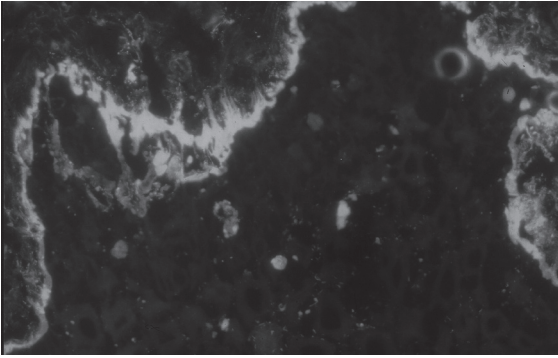


FIGURE 5

Photomicrograph of direct immunofluorescent pattern of linear deposit of fibrinogen at the basement membrane

The buccal mucosa is the most common site for lichen planus but lesions may involve the gingivae, tongue, lips, palate, and the floor of the mouth^{1-11,13}. In this paper, both of the cases with lichen planus were localized at the attached gingivae.

Lichen planus is often diagnosed based on clinical information only, but erosive and bullous variants of lichen planus always require laboratory evaluation^{1,2,15}. Furthermore laboratory evaluation is also important for the differential diagnosis of erosive and bullous variants of lichen planus affecting the attached gingivae and desquamative gingivitis. Histological examination, immunohistology, particularly immunofluorescence, is increasingly being used to more accurately diagnose such diseases. Direct immunofluorescence analysis is not only proving very useful for differential diagnosis, but also adds insight into possible pathogenic mechanisms of desquamative gingivitis and it is essential for diagnosis of lichen planus. Early recognition of lichen planus or the vesiculobullous disorders may prevent delayed diagnosis and inappropriate treatment of potentially serious dermatological diseases^{15,19,20,21}. In this study, the specimens taken by incisional biopsy were sent for histopathologic and direct immunofluorescent examinations. The microscopic criteria for erosive or

bullous lichen planus include hydropic degeneration, bandlike T-lymphocyte infiltration, disorder on the basal layer of the epithelium and presence of Civatte bodies. Appearance of direct immunofluorescent pattern of linear deposit of fibrinogen at the basement membrane supports the former diagnosis of lichen planus in both cases.

Although lichen planus can not generally be cured, some drugs can provide satisfactory control. Gingival lichen planus is the most difficult to treat. The first essential is to maintain rigorous oral hygiene. Corticosteroids are the single most useful group of drugs in the management of lichen planus. The rationale for their use is their ability to modulate inflammation and the immune response. In milder forms of lichen planus, topical application of a fluorinated steroid such as fluocinonide, clobetasol, or halobetasol applied three to four times a day may be effective. In more resistant cases, a combination of a systemic steroid and a locally administered topical may be used. Some investigators have recommended compounding corticosteroid ointments with an adhesive methylcellulose base, but patient compliance may be reduced because this material is difficult to apply¹⁻³. Topical application and local injection of steroids have been successfully used in controlling but not curing this disease. The use of agents such as topical cyclosporine has occasionally been advocated for recalcitrant cases of erosive lichen planus. Because of their antikeratinizing and immunomodulating effects, systemic and topical vitamin A analogs (retinoids) have been used in the management of lichen planus. Triamcinolone dental paste (Kenacort-A orabase) may be useful as it can readily be applied to the affected gingivae^{1-11,14,15}. In this study, topical application of triamcinolone dental paste (Kenacort-A orabase) is used for the treatment of both cases.

REFERENCES

1. Sapp JP, Eversole LR, Wysocki GP: Contemporary Oral and Maxillofacial Pathology, Second Edition, Mosby, St.Louis,2004.
2. Regezi JA, Sciubba JJ, Jordan RCK: Oral Pathology Clinical Pathologic Correlations, Fourth Edition, Saunders, St. Louis, 2003.
3. Neville BW, Damm DD, Allen CM, Bouquot JE: Oral & Maxillofacial Pathology, Second Edition, Saunders, Philadelphia, 2002.
4. Reichart PA, Philipsen HP: Color Atlas of Dental Medicine Oral Pathology, First Edition, Thieme, Berlin, 2000.
5. Özbayrak S: Ağız Hastalıkları Atlası, Tanı Kriterleri, Ayırıcı Tanı ve Tedavi Yaklaşımları, First Edition, Quintessence, İstanbul, 2003.
6. Langlais RP, Miller CS: Color Atlas of Common Oral Diseases, Third Edition, LWW, Philadelphia, 2003.
7. Scully C, Flint SR, Porter SR: Oral Diseases, Second Edition, Dunitz, London, 1996.
8. Scully C, Flint SR, Porte SR, Moos KF: Oral and Maxillofacial Diseases, Third Edition, Taylor&Francis, New York, 2004.
9. Cawson RA, Odell EW, Porter S: Essentials of Oral Pathology and Oral Medicine, Seventh Edition. Churchill Livingstone, London, 2002.
10. Cawson RA, Binnie WH, Eveson JW: Oral Disease, Clinical and Pathologic Correlations, Second Edition, Mosby-Wolfe, London, 1994.
11. Mignogna MD, Lo Russo L, Fedele S: Gingival involvement of oral lichen planus in a series of 700 patients. J Clin Periodontol.2005;32 (10):1029-1033.
12. Raghu AR, Rao NN: Immunofluorescence in oral lichen planus and oral lichenoid reaction. A review Indian.J Dent Res. 2001;12 (1):29-34.
13. Lozada-Nur F, Miranda C: Oral lichen planus: epidemiology. Clinical characteristics, and associated diseases. Semin Cutan Med Surg. 1997;16 (4):273-7.
14. Silverman S Jr: The bullous desquamative lesions of oral mucosa. J Calif Dent Assoc. 2000;28 (12):928-32.
15. Allen CM, Camisa C, Grimwood R: Lichen planus Pemphigoides: report of a case with oral lesions. Oral Surg Oral Med Oral Pathol 1987;63 (2):184-8.
16. Robinson NA, Wrav D: Desquamative gingivitis: a sign of mucocutaneous disorders—a review. Aust Dent J 2003;48 (4):206-11.
17. Markopoulos AK, Antoniadis D, Papanayotou P, Trigonidis G: DesQuamative gingivitis: a clinical, histopathologic, and immunologic study. Quintessence Int 1996;27 (11):763-7.
18. Raghu AR, Nirmala NR, Sreekumaran N: Direct immunofluorescence in oral lichen planus and oral lichenoid reactions. Quintessence Int. 2002;33 (3):234-9.
19. Yih WY, Maier T, Kratochvil FJ, Zieper MB: Analysis of desquamative gingivitis using direct immunofluorescence in conjunction with histology. J Periodontol 1998;69 (6):678-85.
20. Gombos F, Serpico R, Gaeta GM, Budetta F, De Luca P: The importance of direct immunofluorescence in the diagnosis of oral lichen planus. A clinical study and proposal of new diagnostic criteria. Minerva Stomatol. 1992;41 (9):363-72.
21. Stoopler ET, Sollecito TP, DeRossi SS: Desquamative gingivitis: early presenting symptom of mucocutaneous disease. Quintessence Int 2003;34 (8):582-6.

CORRESPONDING ADDRESS

Filiz NAMDAR PEKİNER, DDS, PhD

Marmara University, Faculty of Dentistry, Department of Oral Diagnosis and Radiology Güzelbahçe Büyükciftlik sok. No: 6 34365 Nişantaşı/İstanbul
Tel. : 0-212-2319120 / 120 Fax :0-212-2465247 e-mail :fpekiner@yahoo.com