

# The influence of coccygeal dynamic patterns on ganglion impar block treatment results in chronic coccygodynia

Savas Sencan<sup>1</sup>, Isa Cuce<sup>2</sup>, Ozgur Karabiyik<sup>3</sup>, Fatmagul U Demir<sup>4</sup>,  
Tulay Ercalik<sup>5</sup> and Osman H Gunduz<sup>6</sup>

## Abstract

**Objective:** Ganglion impar block (GIB) can be performed in patients with chronic coccygodynia who do not respond to conservative treatments. We investigated the effect of coccygeal dynamic patterns on the treatment outcome in patients with chronic coccygodynia treated with GIB.

**Materials and methods:** We retrospectively analyzed the data for patients diagnosed with chronic coccygodynia who underwent GIB only once by a transsacrococcygeal method under fluoroscopy guidance in our Pain Medicine Clinic. Patients were assessed with standard and dynamic coccyx radiographs and classified according to coccygeal mobility. Pain scores were assessed with a numerical rating scale (NRS) before and after the intervention (at 1 hour and 4, 12 and 24 weeks). A 50% or more reduction in the NRS score was accepted as significant pain relief.

**Results:** Of the 37 patients included in the study, 14 had normal coccyx (Group I) and 23 had immobile coccyx (Group II) based on the radiological evaluation. The NRS scores were significantly reduced in both groups on each follow-up visit but there was no significant difference between the two groups in terms of pre- and post-intervention NRS scores. Significant pain relief was achieved in 42.9% and 61.9% of patients in Group I and II at the last examination, respectively.

**Conclusion:** GIB administered by transsacrococcygeal method in patients with chronic coccygodynia is a safe and alternative treatment approach with reduced pain scores and low complication rates. In patients with chronic coccygodynia, having a normal or immobile coccyx does not appear to affect treatment outcomes.

## Keywords

Dynamic coccyx X-ray films, coccygodynia, coccydynia, pain management, ganglion impar block

Received 22 April 2018; accepted 16 May 2018

## Introduction

The ganglion impar (also known as Walther's ganglion) is a sympathetic ganglion formed by the midline convergence of the caudal ends of two paravertebral sympathetic chains. It is found at a variable position and size on the ventral surface of the coccyx, and in different shapes, but the classically defined position is at the level of the sacrococcygeal joint (Figure 1).<sup>1,2</sup> The ganglion contributes to somatic innervation as well as sympathetic innervation of the perineal and anal region. It also provides sympathetic innervation of the internal pelvic organs.<sup>3</sup>

Chronic coccygodynia or coccydynia is a disorder characterized by intractable pain in the coccygeal region and is difficult to diagnose and treat.<sup>4</sup> In recent years, trials suggest that ganglion impar block (GIB) can be used as a treatment option for chronic refractory coccygodynia and pelvic pain, including pain caused by malignant neoplasms.<sup>5–9</sup> The most important

<sup>1</sup>Department of Physical Medicine and Rehabilitation, Division of Pain Medicine, Marmara University Pendik Training and Research Hospital, Istanbul, Turkey

<sup>2</sup>Department of Physical Medicine and Rehabilitation, Adiyaman University Training and Research Hospital, Adiyaman, Turkey

<sup>3</sup>Department of Radiology, Kayseri Training and Research Hospital, Kayseri, Turkey

<sup>4</sup>Department of Physical Medicine and Rehabilitation, Kayseri Training and Research Hospital, Kayseri, Turkey

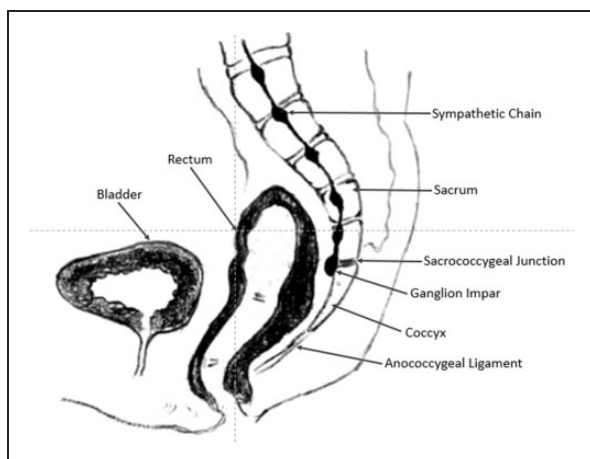
<sup>5</sup>Department of Physical Medicine and Rehabilitation, Division of Pain Medicine, Sisli Hamidiye Etfal Training and Research Hospital, Istanbul, Turkey

<sup>6</sup>Department of Physical Medicine and Rehabilitation, Division of Pain Medicine, Faculty of Medicine, Marmara University, Istanbul, Turkey

### Corresponding author:

Savas Sencan, Marmara University Pendik Training and Research Hospital, Fevzi Çakmak Mahallesi Muhsin Yazıcıoğlu Caddesi No: 10 Üst Kaynarca, Pendik, Istanbul.

Email: savas-44@hotmail.com



**Figure 1.** Schematic showing the sagittal view of the ganglion impar at the level of sacrococcygeal junction.

advantages of this technique are that it can be implemented at a wide range of ages, from adolescent to elderly patients, can improve quality of life, can provide an opportunity to apply recurrent injections in patients with partial pain relief, and can provide additional beneficial effect.<sup>8,10–12</sup> Unfortunately, an acceptable symptomatic improvement cannot be achieved in approximately 18–25% of patients treated with GIB.

Detailed assessment of the clinical status, including pain symptom, and the pathoanatomy of the coccyx in patients with coccygodynia may improve the success of planned treatments.<sup>13</sup> Different dynamic patterns of the coccyx have been defined by the introduction of standard and dynamic radiographs in the evaluation of patients with coccygodynia.<sup>14</sup> However, these patterns are unlikely to consider every coccygeal morphology as the cause of the pain detected in patients with coccydynia. Coccygeal instability may be defined as more than 25% subluxation, or more than 25–30° flexion, or rarely extension (hypermobility) which is pathological. On the other hand, the normal pattern of the coccyx, which is commonly seen in patients with a painful coccyx, may also be seen in asymptomatic individuals. Similarly, in patients with an immobile coccyx, if there is a small bony spicule at the tip of the coccyx, it is also associated with pain.<sup>15,16</sup>

Some coccygeal dynamic patterns in patients with coccydynia may not affect the therapeutic success of GIB alone. However, there is not enough data in the literature about which factors affect the treatment success. Therefore, the aim of this study was to investigate the effects of coccygeal dynamic patterns and potential individual characteristics on the treatment results in patients with chronic coccydynia treated with GIB using the transsacrococcygeal method who were resistant to conservative treatment.

## Materials and methods

This protocol was reviewed and approved by the Institutional Review Board at Erciyes University School of Medicine (reference number: 2017/596). As it is routine practice for ganglion impar procedures in our clinic, all patients were asked to fill out and sign the standard patient consent form prior to the procedure. The ethics committee waived the requirement for informed patient consent because no patient re-contact was established for this study.

## Patients

The clinical data of patients who had been diagnosed with chronic coccygodynia resistant to conservative treatment, who had been referred to our Pain Medicine Clinic providing tertiary medical care and who had undergone GIB by transsacrococcygeal method under fluoroscopy between January 2016 and May 2017 were analyzed retrospectively. Diagnoses were based on clinical and laboratory evaluations, physical examinations, and standard and/or dynamic coccyx radiographs or magnetic resonance imaging (MRI) scans.

Inclusion criteria were as follows: age 18 years or over, having coccyx pain for at least 3 months unresponsive to oral medication and conservative treatments, those who underwent transsacrococcygeal GIB under fluoroscopy, and having standard and dynamic coccyx radiographs available before the procedure. Exclusion criteria were as follows: having coccygodynia associated with cancer metastasis or coccygeal fracture, having accompanying chronic painful illnesses or psychiatric disorders such as fibromyalgia, history of surgery in the lumbar or coccygeal region, those who underwent recurrent GIB, and missing follow-up visits.

## Imaging technique and analysis

For each patient, firstly standard lateral coccygeal radiographs were taken after standing for 10 minutes, according to Maigne's lateral dynamic X-ray protocol.<sup>14,17</sup> Then, the digital dynamic lateral coccygeal graphs were taken in order to evaluate the coccygeal mobility at the sitting position (painful position) on a hard tabouret with the vertebrae in extension and hips in flexion. Both films were superimposed by an expert radiologist. The angle between the tips of the coccygeal segments formed on the superimposed radiographs by sagittal movement (forward or backward) of the coccyx when the patient was sitting in the painful position (the angle of mobility) was noted. The patients were categorized as normal (mobility between 5 and 25°), subluxed (luxation of more than 25%), immobile (with and without spicule, mobility between 0 and <5°), or hypermobile (mobility of more than 25°) based on the mobility of the coccyx.

### Procedure

One experienced pain medicine specialist has performed the GIBs under fluoroscopic guidance. With the patient prone, the intergluteal area was sterilized and a small amount of local anesthetic (3 mL of 2% prilocain) was given at achieving blockade of cutaneous and subcutaneous tissues. The sacrococcygeal joint was visualized via a digital subtraction angiography machine (Philips, Infinix-i Core). A 22-gauge spinal needle was used to reach the ganglion impar by passing through the sacrococcygeal joint (Figure 2(a)). After a 1 mL injection of non-ionic contrast and spreading of the dye gave a “reverse comma” appearance in the lateral view, 3 mL of 0.5% bupivacaine, 2 mL of saline and 1 mL (40 mg) of methylprednisolone were injected in the area (Figure 2(b)).

### Data collection

Forty-five patients received treatment during the time period spanned by this study, 37 (82%) of whom met the inclusion criteria. Eight (18%) patients were excluded due to the exclusion criteria listed above. For each patient, the relevant information for the study was extracted from the standardized patient chart form which was filled out before the intervention and contained the demographic data, trauma history, duration of illness, severity of pain and previous treatment history. The severity of pain was evaluated and ranked on a 10-point numerical rating scale (NRS) before the intervention. The patients were visited at 1 hour and 4, 12 and 24 weeks after the intervention, and the NRS score was recorded on each visit. Significant

pain relief was defined as a 50% or more reduction in the NRS score at the follow-up visits except at the 1 hour time point.

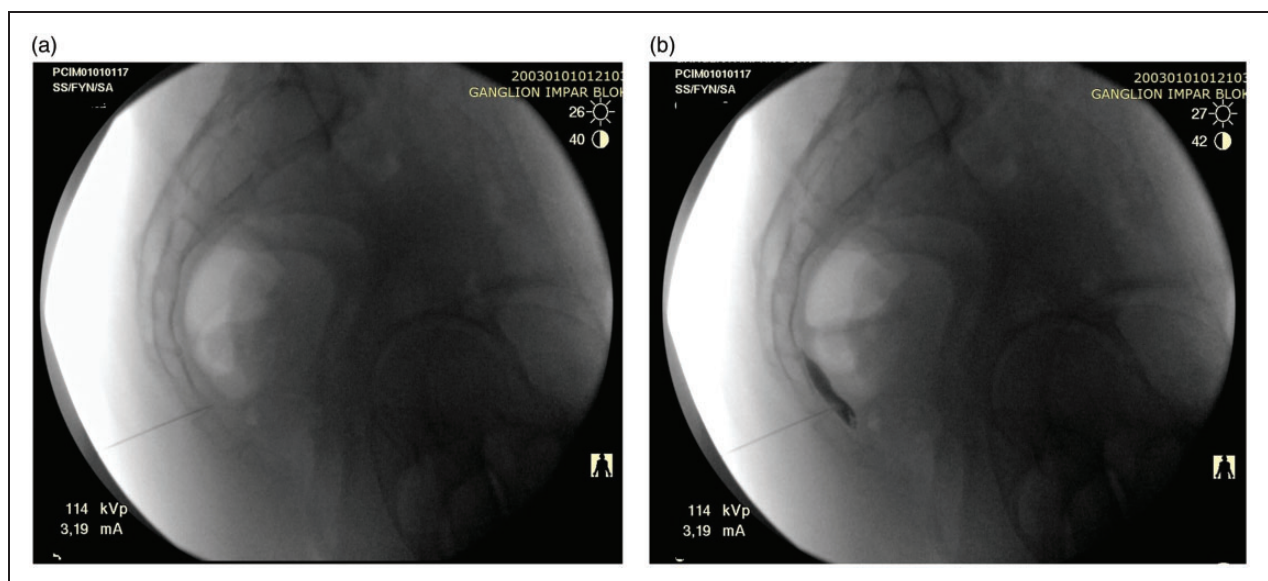
### Statistical analysis

All statistical analyzes were performed using the Statistical Package for Social Sciences (SPSS Inc., Illinois, USA) version 22.0 for Windows. Numerical data are presented as mean  $\pm$  SD or percentages as appropriate. If the data did not have normal distribution, we used the Mann–Whitney *U* test in the examination of differences between groups and the Wilcoxon signed-rank test to compare the NRS scores before and after the intervention. Fisher’s exact test or Yates’s correction for continuity was used as appropriate. The correlations between continuous variables were examined with Spearman’s correlation analysis. A *p* value of  $<0.05$  was accepted as statistically significant.

### Results

All of the patients underwent GIB only once. None of the patients had any post-procedural complication. Of the 37 patients included in the study, 14 had normal coccyx mobility (Group I) and 23 had immobile coccyx (Group II) based on the radiological evaluation.

The average age of the patients was not significantly different between the two groups (Group I,  $40.6 \pm 13.1$  years versus Group II,  $45.4 \pm 13.5$  years:  $p=0.302$ ). The two groups were also similar in terms of clinical characteristics such as sex, body mass index (BMI), etiology (idiopathic or traumatic) and duration of illness (Table 1).



**Figure 2.** Fluoroscopic view of ganglion impar block, transsacrococcygeal approach. (a) A proper position of the needle to lie at the retroperitoneal space, passing through the sacrococcygeal disc. (b) A “reverse comma sign” after the administration of contrast material in the lateral view.

**Table 1.** Demographic data of patients with chronic coccygodynia having normally mobile (Group I) or immobile (Group II) coccyx treated with ganglion impar blocks.

	All patients ( <i>n</i> = 37)	Group I ( <i>n</i> = 14)	Group II ( <i>n</i> = 23)	<i>p</i> value
Age, years	43.6 ± 13.4	40.6 ± 13.1	45.4 ± 13.5	0.302
Female	30 (81.1)	12 (85.7)	18 (78.3)	
Male	7 (18.9)	2 (14.3)	5 (21.7)	0.687
BMI, kg/cm <sup>2</sup>	28.6 ± 4.5	28.14 ± 5.19	28.84 ± 4.21	0.656
Disease duration, months	25.3 ± 23.4	31.5 ± 30.2	21.5 ± 17.1	0.603
Idiopathic	16 (43.2)	6 (42.9)	10 (43.5)	
Trauma (minor)	21 (56.8)	8 (57.1)	13 (56.5)	0.970

Values are presented as mean ± SD or number (%).

BMI: body mass index.

**Table 2.** NRS scores at baseline and at 1 hour and 4, 12 and 24 weeks post-intervention in patients with chronic coccygodynia having normally mobile (Group I) or immobile (Group II) coccyx.

	Group I	Group II	<i>p</i> value
Pre-GIB	7.9 ± 1.8 (8.0; 3.3)	7.9 ± 1.5 (8.0; 2.0)	0.885
1 hour	2.7 ± 3.6 (1.0; 5.0)	2.1 ± 2.9 (1.0; 4.0)	0.743
4 weeks	3.1 ± 2.3 (3.0; 2.5)	2.8 ± 2.5 (2.0; 3.3)	0.521
12 weeks	4.1 ± 2.8 (3.0; 4.3)	2.9 ± 2.5 (3.0; 4.3)	0.279
24 weeks	5.6 ± 3.1 (5.5; 4.5)	3.6 ± 3.3 (3.0; 7.5)	0.089

Values are presented as mean ± SD (median; interquartile range).

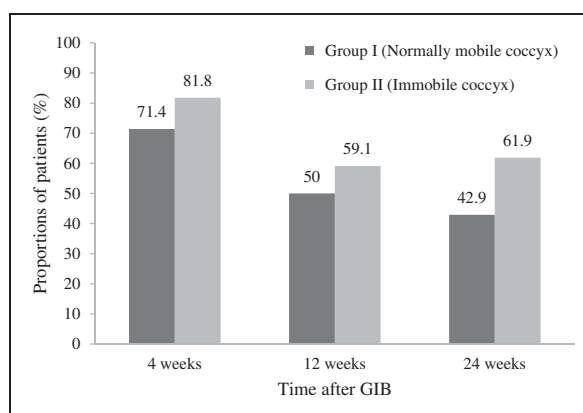
NRS: numerical rating scale; GIB: ganglion impar block.

The pre-intervention mean NRS was 7.9 ± 1.8 points in Group I, which decreased after intervention. The mean NRS in Group I was 2.7 ± 3.6 at 1 hour, 3.1 ± 2.3 at 4 weeks, 4.1 ± 2.8 at 12 weeks, and 5.6 ± 3.1 at 24 weeks. In Group II, the mean NRS decreased from pre-intervention 7.9 ± 1.5 points to 2.1 ± 2.9 at 1 hour, 2.8 ± 2.5 at 4 weeks, 2.9 ± 2.5 at 12 weeks, and 3.6 ± 3.3 at 24 weeks.

The NRS scores at 1 hour immediately after the procedure showed that the intervention relieved pain dramatically. In both groups, the scores at each evolution time point were significantly decreased compared with the pre-procedure NRS (In Group I and II, 1 hour: *p* = 0.002 versus *p* = 0.000, 4 weeks: *p* = 0.001 versus *p* = 0.000, 12 weeks: *p* = 0.004 versus *p* = 0.000, and 24 weeks: *p* = 0.034 versus *p* = 0.000, respectively). However, there was no statistically significant difference between Group I and II at 1 hour and 4, 12 and 24 weeks after the procedure (Table 2).

The proportion of patients with ≥50% improvement in NRS score at 4, 12 and 24 weeks was not significantly different between the two groups at each visit as illustrated in Figure 3 (4 weeks: *p* = 0.683, 12 weeks: *p* = 0.848, and 24 weeks: *p* = 0.446).

We separately divided all the patients (*n* = 37) into two groups based on sex (male: *n* = 7 versus female: *n* = 30) or underlying causes (traumatic: *n* = 21 versus

**Figure 3.** Illustration of significant pain relief (≥50% reduction in numerical rating scale from baseline). *p* > 0.05, there was no significant difference from baseline values between the two groups at each time point.

GIB: ganglion impar block.

idiopathic: *n* = 16) and compared their NRS scores before and after the intervention. The differences between the changes in mean NRS scores after intervention in male and female or trauma and idiopathic groups were not statistically significant. In correlation analyses, there was no significant relationship between the reduction in NRS after treatment and age, BMI and the duration of symptoms (*p* > 0.05, for all).

## Discussion

In our study, the standard and dynamic radiographs of 37 patients with chronic coccygodynia who were resistant to conservative treatment and who underwent GIB under fluoroscopy were evaluated for coccyx mobility. Accordingly, the patients were categorized into normally mobile and immobile coccyx, and their NRS scores were compared. The NRS scores were significantly decreased in both groups at each follow-up visit but there was no significant difference between the two groups in terms of pre- and post-intervention

NRS scores. Significant pain relief was achieved in 42.9% and 61.9% of patients with a normally mobile and immobile coccyx, respectively, at the last follow-up. Possible influencing factors such as age, sex, BMI, duration of disease and presence of trauma had no effect on results.

In their study of 248 patients with coccygodynia, Maigne et al.<sup>15</sup> suggested that the culprit lesion could be detected in 69.2% of the cases with lateral dynamic radiography protocol. The authors suggested association of sublaxation, hypermobility and immobility (in the presence of a spicule) with the cause of pain in patients with coccydynia. In the case of coccygeal hypermobility and sublaxation, chronic inflammation occurs due to coccygeal instability and the patient feels pain in the sitting position. If there is a spicule, it leads to irritation and inflammation in the coccygeal region when the patient sits. It is emphasized that other lesions, including normal mobility and immobility without a spicule, are weakly associated with coccygeal pain. This may explain the absence of significant differences between the treatment outcomes of the normal and immobile groups in our study.

Postacchini and Massobrio compared the lateral radiographs of patients who underwent partial or total coccygectomy with those of asymptomatic individuals, and described four types of coccygeal configuration.<sup>16</sup> They showed that type I (curved slightly forward) was more frequent in asymptomatic individuals while other forms, including sublaxation, were more common in patients with coccydynia. However, they did not find any relationship between the pre-operative coccygeal morphology and the treatment outcomes in patients treated with partial or total coccygectomy. Similarly, there appears to be no definite relationship between the outcomes of GIB treatment and normal or immobile pattern of coccyx.

Kodumuri et al.<sup>18</sup> investigated the factors influencing the treatment success after injection, manipulation or coccygectomy in a retrospective study. They reported high BMI and trauma history as independent risk factors for coccydynia. We could not perform subgroup analysis for the two groups separately due to the relatively small sample size of our study. We could examine the effects of the potential individual characteristics on GIB treatment results only in the whole study population. There was no relationship between treatment outcomes and age, BMI, symptom duration, sex and trauma history. This difference may also be related to the fact that the treatment modality in our study is different from previous studies.

Nowadays, it is a common opinion that chronic coccygodynia pain is multifactorial. In their provocative discography study, Maigne et al.<sup>17</sup> suggested that the pain was discogenic in about 70% of patients. Other causes of pain were strain in the pelvic floor muscles, chronic inflammation in the coccygeal bursa, arachnoiditis of the lower sacral nerve roots, myofascial trigger

points and referred pain.<sup>19–22</sup> In addition, psychogenic factors such as somatization and depression may also be associated with pain.<sup>23</sup> For this reason, standard radiographs may not provide sufficient information to determine the cause of pain in patients with normal or immobile coccyx. Inflammation detected in the disc or pericoccygeal soft tissue and bone marrow edema on MRI imaging of the coccyx in this patient group support this opinion.<sup>24</sup>

In our study, a reduction in pain beginning at 1 hour and sustained for up to 6 months was provided by the GIB in both groups. This is consistent with the study by Gonnade et al.<sup>6</sup> which reported a dramatic relief in pain starting at 1 hour after GIB and continuing for up to 6 months in 31 patients with chronic coccygodynia resistant to conservative treatment. Our study is different from theirs in terms of being retrospective and not assessing disability. In addition, unlike our previous study which reported that the duration of relief in pain was prolonged with repeated injections in long-term follow-ups, our study used a single injection therapy.<sup>5</sup> Nevertheless, with a high treatment success rate and without any complication, our study supports the reports suggesting GIB as a safe and alternative treatment option.<sup>8,11</sup>

There are some limitations to our study. We were not able to evaluate the effect of two other coccygeal lesions observed in patients with coccydynia, sublaxation and hypermobility, on the treatment outcomes. In our study, we could not identify these two types of lesions in any subjects, probably due to the low number of participants. Other limitations are retrospective study design and lack of assessment for sacrococcygeal or transsacrococcygeal disc degeneration. However, our study provides important data because it is the first study, to our knowledge, to investigate the effects of the radiological features of coccyx on GIB treatment results.

## Conclusion

GIB administered by the transsacrococcygeal method in patients with chronic coccygodynia resistant to conservative treatment is a safe and alternative treatment approach to reduce pain scores with low complication rates. Normal and immobile coccyges detected by standard and dynamic radiographs of patients with chronic coccydynia appear to be two different coccygeal dynamic patterns that do not affect the treatment outcome in GIB. In addition, various individual and clinical characteristics were also found to have no effect on the treatment outcome. Prospectively designed, controlled trials involving a larger group of patients are needed to clarify all potential factors determining the treatment success in GIB.

## Acknowledgments

The authors would like to thank Dr Samaya Mirzayeva for her help with Figure 1.

### Declaration of conflicting interests

The authors declared no potential conflicts of interest with respect to the research, authorship, and/or publication of this article.

### Funding

The authors received no financial support for the research, authorship, and/or publication of this article.

### References

1. Nebab EG and Florence IM. An alternative needle geometry for interruption of the ganglion impar. *Anesthesiology* 1997; 86: 1213–1214.
2. Oh CS, Chung IH, Ji HJ, et al. Clinical implications of topographic anatomy on the ganglion impar. *Anesthesiology* 2004; 101: 249–250.
3. Walters A, Muhleman M, Osiro S, et al. One is the loneliest number: a review of the ganglion impar and its relation to pelvic pain syndromes. *Clin Anat* 2013; 26: 855–861.
4. Lirette LS, Chaiban G, Tolba R, et al. Coccydynia: an overview of the anatomy, etiology, and treatment of coccyx pain. *Ochsner J* 2014; 14: 84–87.
5. Gunduz OH, Sencan S and Kenis-Coskun O. Pain relief due to transsacrococcygeal ganglion impar block in chronic coccygodynia: a pilot study. *Pain Med* 2015; 16: 1278–1281.
6. Gonnade N, Mehta N, Khera PS, et al. Ganglion impar block in patients with chronic coccydynia. *Indian J Radiol Imaging* 2017; 27: 324–328.
7. Toshniwal GR, Dureja GP and Prashanth SM. Transsacrococcygeal approach to ganglion impar block for management of chronic perineal pain: a prospective observational study. *Pain Physician* 2007; 10: 661–666.
8. Le Clerc QC, Riant T, Levesque A, et al. Repeated ganglion impar block in a cohort of 83 patients with chronic pelvic and perineal pain. *Pain Physician* 2017; 20: E823–E828.
9. Agarwal-Kozlowski K, Lorke DE, Habermann CR, et al. CT-guided blocks and neuroablation of the ganglion impar (Walther) in perineal pain: anatomy, technique, safety, and efficacy. *Clin J Pain* 2009; 25: 570–576.
10. Datir A and Connell D. CT-guided injection for ganglion impar blockade: a radiological approach to the management of coccydynia. *Clin Radiol* 2010; 65: 21–25.
11. Foye PM, Buttaci CJ, Stitik TP, et al. Successful injection for coccyx pain. *Am J Phys Med Rehabil* 2006; 85: 783–784.
12. Ellinas H and Sethna NF. Ganglion impar block for management of chronic coccydynia in an adolescent. *Paediatr Anaesth* 2009; 19: 1137–1138.
13. Nathan ST, Fisher BE and Roberts CS. Coccydynia: a review of pathoanatomy, aetiology, treatment and outcome. *J Bone Joint Surg Br* 2010; 92: 1622–1627.
14. Maigne JY and Tamalet B. Standardized radiologic protocol for the study of common coccygodynia and characteristics of the lesions observed in the sitting position. Clinical elements differentiating luxation, hypermobility, and normal mobility. *Spine* 1996; 21: 2588–2593.
15. Maigne JY, Doursounian L and Chatellier G. Causes and mechanisms of common coccydynia: role of body mass index and coccygeal trauma. *Spine* 2000; 25: 3072–3079.
16. Postacchini F and Massobrio M. Idiopathic coccygodynia. Analysis of fifty-one operative cases and a radiographic study of the normal coccyx. *J Bone Joint Surg Am* 1983; 65: 1116–1124.
17. Maigne JY, Guedj S and Straus C. Idiopathic coccygodynia. Lateral roentgenograms in the sitting position and coccygeal discography. *Spine* 1994; 19: 930–934.
18. Kodumuri P, Raghuvanshi S, Bommireddy R, et al. Coccydynia—could age, trauma and body mass index be independent prognostic factors for outcomes of intervention? *Ann R Coll Surg Engl* 2018; 100: 12–15.
19. Bayne O, Bateman JE and Cameron HU. The influence of etiology on the results of coccygectomy. *Clin Orthop Relat Res* 1984; 190: 266–272.
20. Wood KB and Mehbod AA. Operative treatment for coccygodynia. *J Spinal Disord Tech* 2004; 17: 511–515.
21. Mohanty P and Pattnaik M. Effect of stretching of piriformis and iliopsoas in coccydynia. *J Bodyw Mov Ther* 2017; 21: 743–746.
22. Dampc B and Słowiński K. Coccygodynia—pathogenesis, diagnostics and therapy. Review of the writing. *Pol Przegl Chir* 2017; 89: 34–41.
23. De Andrés J and Chaves S. Coccygodynia: a proposal for an algorithm for treatment. *J Pain* 2003; 4: 257–266.
24. Maigne JY, Pigeau I and Roger B. Magnetic resonance imaging findings in the painful adult coccyx. *Eur Spine J* 2012; 21: 2097–2104.