

## Case Report

### Successful endovascular repair of a subclavian artery pseudoaneurysm

Serdar Akgün<sup>1</sup>, Ali Civelek<sup>1</sup>, Feyyaz Baltacioglu<sup>2</sup> and Gazanfer Ekici<sup>2</sup>

<sup>1</sup>Department of Cardiovascular Surgery and <sup>2</sup>Department of Radiology, Marmara University School of Medicine, Istanbul, Turkey

**Key words:** complication of subclavian vein catheterization; endovascular repair of subclavian artery pseudoaneurysm

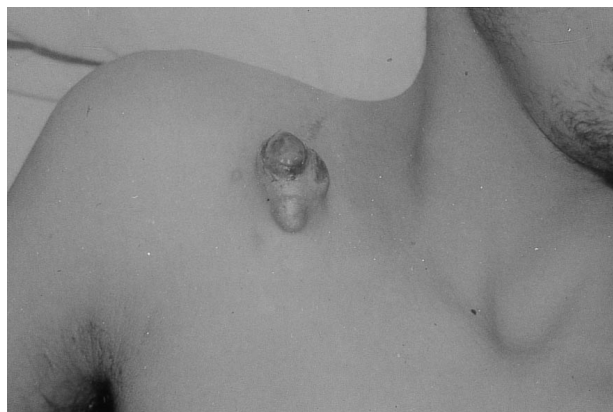
#### Introduction

Serious complications of central venous access occur in 0.4–9.9% of patients undergoing attempted central venepuncture [1]. Potential complications include failure to locate or cannulate the vein, puncture of the subclavian artery, misplacement of the catheter, pneumothorax, mediastinal haematoma, haemothorax and injury to adjacent nerves [2]. Pseudoaneurysm formation of the great vessels and the right subclavian artery is rare in patients undergoing central venepuncture [3]. The evolution of pseudoaneurysm is continued expansion and eventually rupture; therefore, pseudoaneurysms should be repaired to prevent inevitable rupture. Endovascular stent grafts offer an alternative approach to standard treatments for a variety of vascular pathologies including aneurysm.

We observed a case of a large subclavian artery pseudoaneurysm that caused pressure necrosis of the skin. The pseudoaneurysm occurred after subclavian vein catheterization for haemodialysis access and was successfully repaired using the endovascular approach.

#### Case

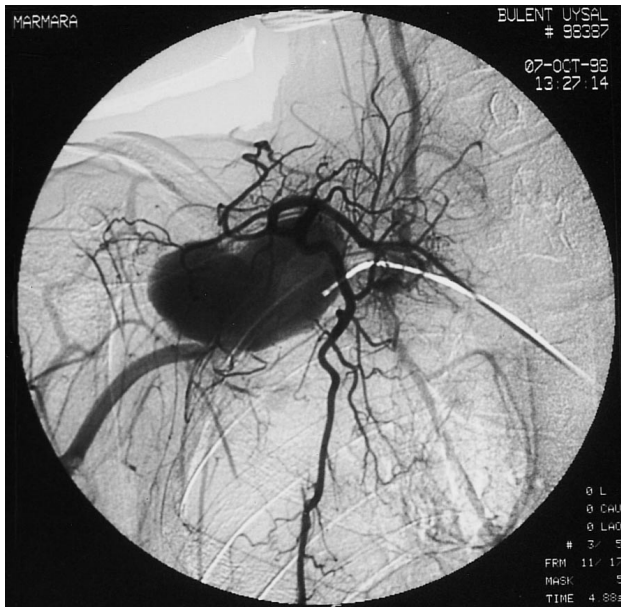
A 21-year-old male with a history of dialysis for 2 months via a right subclavian vein catheter was referred to our hospital because of a bleeding bullous lesion eroding the skin underneath the right clavicle (Figure 1). The patient was unable to walk because of sequela of polio at the age of 1 year. The catheter was removed 2 weeks after implantation because of thrombosis of the subclavian vein diagnosed by Doppler ultrasonography. The skin lesion appeared 1 week before admis-



**Fig. 1.** Bleeding bullous lesion eroding the skin under the right clavicle.

sion, it enlarged rapidly causing erosion of the skin and blood leakage. The auscultation of the lesion revealed a pansystolic murmur around the lesion radiating to the sternum. After initial thoracic aortography via the right common femoral artery, selective angiography of the right subclavian artery was performed which showed an aneurysm, approximately 4 × 5 cm in size, originating from the upper contour of the right subclavian artery and extending anteriorly and superiorly (Figure 2). The clavicle provoked a depression of the aneurysm resulting in a bilobulated shape. The aneurysm had a neck of ~1.5–2 cm. Total occlusion of the right subclavian vein was observed by venography. As the aneurysm was false, repair was obviously necessary and the surgical approach risky, since the aneurysm had eroded the skin and there was a high risk of aneurysm rupture during dissection, therefore an endovascular repair was chosen. At first a 0.035 in. hydrophilic exchange guidewire (Terumo Europe N.V., Belgium) was passed through the lesion. A 28 mm balloon expandable PTFE-covered Jostent Peripheral Stent Graft (Jomed Implantate GmbH, Rangendingen, Germany) was then loaded onto a 6 × 30 mm balloon and introduced over the guidewire to the right subclavian artery against the neck of the aneurysm. We inflated the balloon and deployed the stent graft. Arteriography revealed complete exclusion

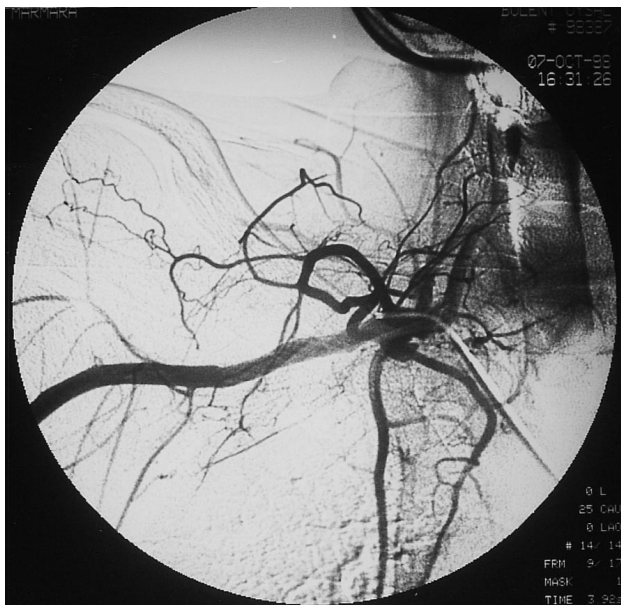Correspondence and offprint requests to: Yrd. Doç. Dr Serdar Akgün, Marmara Üniversitesi Hastanesi, Kalp Damar Cerrahisi ABD, Tophanelioglu Cad. 13–15, 81190 Altunizade, Istanbul, Turkey.



**Fig. 2.** Pre-operative arteriogram showing the false aneurysm of right subclavian artery.

of the lesion and normal flow through the subclavian artery and its branches (Figure 3).

The patient had an uncomplicated recovery and was discharged after 2 days. A duplex scan before discharge confirmed normal flow through the subclavian artery with complete exclusion of the thrombosed aneurysmal sac. The patient has been followed up for 6 months. Circulation to the right arm remains normal.



**Fig. 3.** Completion of angiography showing complete exclusion of the lesion and normal flow through the subclavian artery and its branches.

## Discussion

Pseudoaneurysm formation of the great vessels and the right subclavian artery is rare in patients undergoing central venepuncture [3]. Its complications include enlargement with resulting haemorrhage, arterial thrombosis, compression of adjacent neurovascular structures and erosion through the skin with external bleeding [4]. In some instances, urgent or emergency surgical intervention is necessary.

The treatment modalities are an open operation or endovascular repair. The subclavian artery may be approached through a supraclavicular incision with lateral extension or via retroclavicular subclavian exposure with or without a thoracotomy. Safe control of the proximal subclavian artery necessitates retroclavicular subclavian exposure with or without a thoracotomy, but care must be taken to protect the phrenic nerve and the thoracic duct [5]. Opening the lumen of a false aneurysm may provoke haemorrhage during dissection. Control of the aneurysm by temporary inflation of a balloon in the proximal part of the subclavian artery was contemplated as an adjunct to surgery to prevent excessive bleeding. There was concern, however, about the risk of embolization up the vertebral artery because of manipulation of its origin [6]. Therefore, endovascular repair of the pseudoaneurysm appeared to be the best option in this case.

The feasibility of transluminal endovascular grafting for the treatment of abdominal aortic aneurysms, subclavian artery aneurysms and arteriovenous fistulae, has been well documented [4,6–8]. Endovascular repair of a false aneurysm of the subclavian artery was first reported by May *et al.* [6]. Since then, progress in stent graft technique has been made. Reports on stent graft treatment of subclavian artery ‘aneurysms’ have dealt exclusively with pseudoaneurysms in the setting of iatrogenic or penetrating traumatic injuries and involving arteries originating from the aorta [6]. The advantages of this procedure include a minimally invasive approach, shortened hospitalization and cost effectiveness.

In conclusion, endovascular repair of false aneurysm of the subclavian artery by endovascular placement of a stented PTFE graft is an alternative surgical technique yielding satisfactory results even in emergency cases.

## References

1. Borja AR, Masri Z, Shruck L, Pefo S. Unusual and lethal complications of infraclavicular subclavian vein catheterization. *Int Surg* 1972; 57: 42–45
2. Mansfield PF, Hohn DC, Fornage BD, Gregurich MA, Ota DM. Complications and failures of subclavian-vein catheterization. *N Engl J Med* 1994; 331: 1735–1738
3. Shield CF, Richardson JD, Buckley CY, Hagood CO. Pseudoaneurysm of the brachiocephalic arteries: a complication of percutaneous internal jugular vein catheterization. *Surgery* 1975; 78: 190–194

4. Marin ML, Veit FJ, Panetta TF *et al.* Percutaneous transfemoral insertion of a stented graft to repair a traumatic femoral arteriovenous fistula. *J Vasc Surg* 1993; 18: 299–302
5. Ernst CB. Trans-sternal exposure of the great vessels of the aortic arch. In: Haimovici H, Ascer E, Hollier LH, Strandness DE, Towne JB, eds. *Haimovici's Vascular Surgery*, 4th edn. Blackwell Science Inc., New York, 1996; 365–372
6. May J, White G, Waugh R, Yu W, Harris J. Transluminal placement of a prosthetic graft-stent device for treatment of subclavian artery aneurysm. *J Vasc Surg* 1993; 18: 1056–1059
7. Davidian M, Kee S, Kato N *et al.* Aneurysm of an aberrant right subclavian artery: treatment with PTFE covered stentgraft. *J Vasc Surg* 1998; 28: 335–339
8. Parodi J, Palmaz J, Barone H. Transfemoral intraluminal graft implantation for abdominal aortic aneurysm. *Ann Vasc Surg* 1991; 5: 491–499

*Received for publication: 24.3.99*

*Accepted in revised form: 23.4.99*