



Evaluation of Permanent Tooth Development in Pediatric Cancer Survivors: A Single Center Experience

● Nurşah Eker¹, ● Orkun Dinç¹, ● Narmin Asadova², ● Ali Mentese², ● Dilek Gül³, ● Beste Atasoy³, ● Alican Sarısaltık⁴, ● Gülnur Tokuç¹

¹Marmara University Faculty of Medicine, Department of Pediatric Hematology Oncology, İstanbul, Turkey

²Marmara University Faculty of Dentistry, Department of Pediatric Dentistry, İstanbul, Turkey

³Marmara University Faculty of Medicine, Department of Radiation Oncology, İstanbul, Turkey

⁴Republic of Turkey Ministry of Health, Çayırova District Health Directorate, Kocaeli, Turkey

ABSTRACT

Aim: Childhood cancer survival has improved significantly with advances in multimodal treatment. However, treatment-related long-term side effects, including dental developmental abnormalities, remain a concern. The aim of this study was to investigate permanent tooth development and associated risk factors in childhood cancer survivors who were treated before the age of six years, focusing on non-leukemia cases.

Materials and Methods: This study was conducted on childhood cancer cases treated with chemotherapy and/or radiotherapy at a single center. Patients diagnosed before the age of six and who were twelve or above at the time of assessment were included. Dental examinations, including Decayed, Missing, Filled Teeth index and radiographic assessments, were performed. Statistical analyses were performed in order to identify associations between treatment modalities and dental findings.

Results: Of 914 patients, 90 met the inclusion criteria, with 35 participating in this study. The mean age at diagnosis was four years, with a mean follow-up duration of ten years. Root shortening, hypoplasia, and hypodontia were observed to be common dental anomalies. There was a significant association between alkylating agents, vinca alkaloid plus alkylating agents and root shortening ($p < 0.001$, $p < 0.001$). No significant differences in dental findings were found based on gender, tumor site, or other treatment modalities ($p < 0.05$). As the age at diagnosis increased, the risk of root shortening ($p = 0.026$) and the frequency of hypodontia significantly increased with the duration after diagnosis ($p = 0.048$).

Conclusion: Childhood cancer survivors treated during early dentition periods are at risk of dental developmental anomalies, with alkylating agents showing the most significant impact. This emphasizes the necessity of providing these patients and their families with information on the importance of maintaining oral and dental health during and after cancer treatment.

Keywords: Childhood, cancer, dental health

Introduction

Survival rates in childhood cancers are increasing due to evolving multimodal treatments, reaching up to 80% in 5-year survival rates. The significance of addressing

treatment-related secondary and long-term side effects is increasing due to their impact on the quality of life of these patients. The long-term effects of cancer treatment can vary depending on the specific cancer subtype and the type

Address for Correspondence

Nurşah Eker, Marmara University Faculty of Medicine, Department of Pediatric Hematology Oncology, İstanbul, Turkey

Phone: +90 505 689 14 84 **E-mail:** nursaheker@hotmail.com **ORCID:** orcid.org/0000-0002-7707-3035

Received: 22.04.2024 **Accepted:** 14.08.2024



of treatment received. These effects can include endocrine, cardiac, and neurocognitive impairments, as well as an increased risk of developing secondary malignancies (1). Furthermore, adverse effects on dental development can also occur in the long term in childhood cancer survivors (2). In addition to the adverse effects of both chemotherapy and radiotherapy, nutritional disorders during intensive treatment periods, decreased saliva secretion, recurrent oral mucositis, and gingivitis attacks can negatively impact oral and dental development (3,4). Dental agenesis and caries, enamel hypoplasia, root development anomalies, and microdontia are some of the developmental anomalies which have been observed in this population (5,6). The period of infancy, during which dental stem cell proliferation is most effective, appears to exhibit a more pronounced effect in those children who have undergone cancer treatment (7). A review of the literature reveals that cancer treatment has a negative impact on dental development, with the age at which the treatment is received being identified as the most important factor (8). The majority of studies conducted have focused on cases diagnosed with acute lymphoblastic leukemia, which is the most common cancers in childhood (9-12).

This study differs from the previous literature in that it aimed to eliminate the age factor and include non-leukemia childhood cancer survivors who were treated before the age of six. The objective was to ascertain the impact of cancer treatment on permanent tooth development and identify risk factors affecting dental development in these cases after the age of 12, with a single center approach.

Materials and Methods

A retrospective evaluation was conducted on cases diagnosed with non-leukemia childhood cancer and treated with chemotherapy and/or radiotherapy at our center from January 2010. Cases with a cancer diagnosis at an age of six years or below were selected. This study included cases where the patients were aged 12 or above at the time of the study. Prior to undergoing dental and radiographic examination, all patients and their parents or caregivers provided written informed consent. The oral examination entailed the assessment of the Decayed, Missing, Filled Teeth (DMFT) index, developmental enamel and/or dentin defects including hypoplasia, hypodontia, and dental crowding. The examinations were performed by a single pediatric dentist in a standard dental setting. Panoramic radiographs were taken to investigate the presence of agenesis, supernumerary or impacted teeth, pulp chamber enlargement, calcification, alterations in root morphology alterations (shortening

and dilaceration) and disturbances in tooth eruption. The demographic characteristics of the included cases, as well as their cancer diagnosis, chemotherapeutic drugs received, radiotherapy (if received), and radiotherapy site and dose were obtained from the data files. The potential impact of anticancer treatments on dental development was evaluated, with a focus on identifying any associated risk factors. Cases diagnosed at an age of six years or above, aged below 12 years during the study period, diagnosed with leukemia, or those who did not provide consent for participation were excluded from this study.

The study protocol was approved by the Marmara University Faculty of Medicine, Clinical Research Ethics Committee (date: 03.02.2023, number: 09.2023.333), and before the start of this study, the families of all participants signed an informed consent form.

Statistical Analysis

Data analysis of this study was performed by the IBM SPSS for Windows version 29 program. Associations between categorical independent and dependent variables (hypoplasia, hypodontia, short root anomaly, class, and number of caries >4) were evaluated with the chi-square and Fisher's exact tests. Univariate logistic regression analysis was used to examine the relationships between dental findings and continuous independent variables. Also, the continuous independent variables were categorized based on their median values as the cut-off point, and the Mann-Whitney U test was used to evaluate any relationships between individual and clinical characteristics and DMFT. The statistical significance level was accepted as $p < 0.05$.

Results

The records of 914 patients who had received treatment for non-leukemia childhood cancer at our center were retrospectively evaluated. There were 369 (40.3%) cases with a diagnosis age of six years or below. Among these cases, 32 (3.5%) did not attend regular follow-ups, 73 (7.9%) were lost to follow-up, and 32 (3.5%) only underwent surgical treatment without receiving chemotherapy or radiotherapy, so they were not included in this study. From the remaining 232 (25.3%) cases, those aged 12 or above and meeting the study criteria were planned for dental development evaluation, resulting in 90 (9.8%) eligible cases. Of these cases, 35 (3.8%) agreed to participate in this study and attended the appointment for examination.

The mean age at diagnosis was four years, with a mean current age of 13.5 years. The average duration from diagnosis to the present day was calculated as ten years.

Female cases constituted 37.1% of the total. Regarding diagnoses, brain tumors were the most common (31.4%), followed by lymphoma (20%) among the cases (Table I). Approximately half of the cases (51.4%) had involvement in the head and/or neck region. Treatment characteristics are summarized in Table II. Fifteen cases (42.9%) had a history of radiotherapy, and when evaluating the radiotherapy sites, 7 cases (46.6%) had received craniospinal radiotherapy, and 4 cases (26.7%) had received only cranial radiotherapy. The most commonly used chemotherapeutic agents were vinca alkaloids (88.6%), followed by alkylating agents (57.1%). Regarding chemotherapy combinations, approximately one-third of the cases (29.4%) consisted of alkylating agents, vinca alkaloids, and platinum group drugs. The average duration of treatment was six months.

When dental findings were evaluated, at least one dental pathology was present in all cases. Root shortening was detected in those case with the least findings, who had received a combination of alkylating agents. This case constituted the only case with a DMFT index of zero. While the average number of decays was four in all cases, the average DMFT score was found to be five. Hypoplasia was detected in twenty cases (57.1%), root shortening in 11 cases (31.4%) (Figure 1), hypodontia in eight cases (22.9%), and taurodontism was detected in only two cases (5.7%). Hypoplasia was mostly seen in the upper central incisors. Hypodontia was mostly seen in the lower second

	n (%)
Gender (Male/Female)	22 (62.9)/13 (37.1)
Diagnosis	
Brain tumor	11 (31.4)
Lymphoma	7 (20.0)
Wilms tumor	5 (14.3)
Langerhans cell histiocytosis	4 (11.4)
Germ cell tumor	3 (8.6)
Neuroblastoma	3 (8.6)
Ewing sarcoma	1 (2.9)
Rhabdomyosarcoma	1 (2.9)
Site of involvement	
Head and neck	18 (51.4)
Other	17 (48.6)
Primary disease status	
Complete remission (CR)	33 (94.3)
Stable disease (SD)	2 (5.7)

premolars followed by the upper lateral incisors. Root shortening was mostly in the lower central and lateral incisors. Figure 2 shows examples of normal panoramic radiographs alongside radiographs of dental development pathologies. The presence of hypodontia was observed in five cases along with hypoplasia. Among these cases, two had a diagnosis of brain tumors, two had Wilms' tumors, and one had a diagnosis of abdominal lymphoma.

The relationship between clinical characteristics and dental findings was analyzed. There was no statistically significant difference between gender, head-neck

Treatment	n (%)
Radiotherapy	15 (42.9)
Radiation therapy site	
- Craniospinal	7 (46.6)
- Cranial	4 (26.7)
- Other	4 (26.7)
Chemotherapy	34 (97.1)
- Alkylating agents	20 (57.1)
- Vinca alkaloids	31 (88.6)
- Platinum	17 (48.6)
- Anthracyclines	12 (34.3)
Chemotherapy combination (n=34)	
- Alkylating - Vincas - Anthracyclines - Platinum	3 (8.8)
- Alkylating - Vincas - Anthracyclines	7 (20.6)
- Alkylating - Vincas - Platinum	10 (29.4)
- Vincas - Anthracyclines	2 (5.9)
- Vincas - Platinum	1 (2.9)
- Platinum	3 (8.8)
- Vinca alkaloids	8 (23.5)
- Glucocorticoids	10 (28.6)

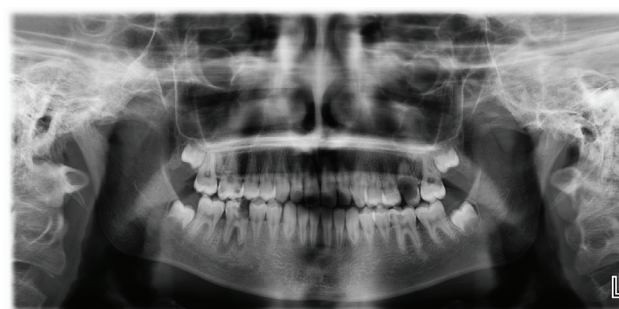

Figure 1. In the panoramic radiograph of a patient who received treatment for Ewing sarcoma, root shortening is present in all teeth

involvement, history of radiotherapy, history of receiving glucocorticoids, and hypoplasia, hypodontia and root shortening (Table III). Regarding chemotherapeutics, a statistically significant higher frequency of root shortening was found in the group who had received alkylating agents along with vinca alkaloids ($p < 0.001$). There was no statistically significant feature identified when comparing the DMFT index with the clinical characteristics, treatment

modalities and chemotherapeutic agents ($p > 0.05$). As the age at diagnosis increased, the risk of root shortening ($p = 0.026$) and the frequency of hypodontia significantly increased with the duration after diagnosis ($p = 0.048$) (Table IV). The patients' ages, DMFT scores, and teeth with dental anomalies are shown in Table V.

Table III. Dental findings based on individual and clinical characteristics							
Variables		Hypoplasia		Hypodontia		Root shortness	
		n (%)	p value	n (%)	p value	n (%)	p value
Gender							
	Female	8 (61.5)	0.686	3 (23.1)	0.999	3 (23.1)	0.478
	Male	12 (54.5)		5 (22.7)		8 (36.4)	
Head/neck involvement							
	Absent	11 (64.7)	0.380	4 (23.5)	0.999	6 (35.3)	0.632
	Present	9 (50.0)		4 (22.2)		5 (27.8)	
Radiotherapy							
	Absent	12 (60.0)	0.693	4 (20.0)	0.700	5 (25.0)	0.467
	Present	8 (53.3)		4 (26.7)		6 (40.0)	
Alkylating agents							
	Absent	7 (46.7)	0.278	3 (20.0)	0.999	0 (0.0)	<0.001
	Present	13 (65.0)		5 (25.0)		11 (35.5)	
Vinca alkaloids							
	Absent	2 (50.0)	0.999	0 (0.0)	0.553	0 (0.0)	0.285
	Present	18 (58.1)		8 (25.8)		11 (35.5)	
Platinum							
	Absent	10 (55.6)	0.845	5 (27.8)	0.691	8 (27.8)	0.632
	Present	10 (58.8)		3 (17.6)		6 (35.3)	
Anthracycline							
	Absent	11 (47.8)	0.123	5 (21.7)	0.999	6 (26.1)	0.451
	Present	9 (75.0)		3 (25.0)		5 (41.7)	
Alkylating agents and vinca alkaloids							
	Absent	7 (46.7)	0.278	3 (20.0)	0.999	0 (0.0)	<0.001
	Present	13 (65.0)		5 (25.0)		11 (35.5)	
Alkylating agents, vinca alkaloids and anthracycline							
	Absent	13 (52.0)	0.458	6 (24.0)	0.999	6 (24.0)	0.227
	Present	7 (70.0)		2 (20.0)		5 (50.0)	
Steroid							
	Absent	15 (60.0)	0.712	5 (20.0)	0.661	7 (28.0)	0.689
	Present	5 (50.0)		3 (30.0)		4 (40.0)	

Bold font indicates statistical significance

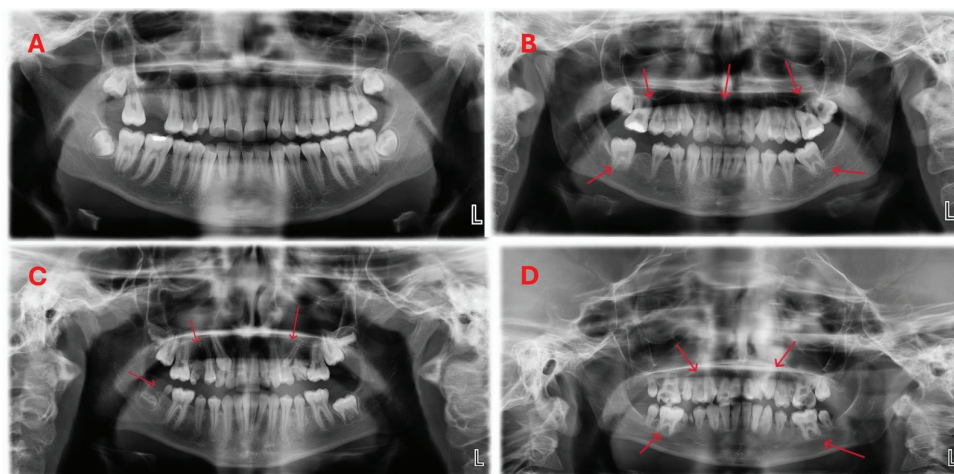


Figure 2. Panoramic radiographs of a normal child and the childhood cancer survivors. **A)** A 13-year-old girl with normal root lengths and tooth morphology. **B)** A 13-year-old girl with short, V-shaped deformed roots. **C)** A 12-year-old girl with undeveloped or hypoplastic teeth. **D)** A 12-year-old boy with short and malformed roots in all teeth

Table IV. Age characteristics and dental development findings, univariate logistic regression analysis

	Hypoplasia		Hypodontia		Root shortening	
	OR (95% CI)	p value	OR (95% CI)	p value	OR (95% CI)	p value
Age at initial diagnosis	0.666 (0.421-1.053)	0.082	0.803 (0.494-1.305)	0.375	1.968 (1.085-3.571)	0.026
Time since diagnosis (years)	1.158 (0.785-1.708)	0.460	1.985 (1.008-3.912)	0.048	0.719 (4.469-1.102)	0.130
Current age (years)	0.765 (0.492-1.190)	0.234	1.288 (0.778-2.131)	0.325	1.246 (0.789-1.969)	0.345
Treatment duration (months)	0.927 (0.839-1.023)	0.132	0.982 (0.887-1.086)	0.720	0.925 (0.809-1.058)	0.254

OR: Odds ratio, CI: Confidence interval

Table V. Age, DMFT^{*} scores and numbers of the teeth^{**} with dental anomalies of the patients

Patient	Age (year)	DMFT [*] score	Hypoplasia	Hypodontia	Root shortening
1	12	3	11,21	-	31,32,41,42
2	12	2	-	-	-
3	12	2	21	-	-
4	12	4	11,21	-	-
5	12	4	11,21	-	31,32,41,42,35
6	12	6	-	-	-
7	12	9	11,21	35,45	-
8	12	10	-	-	-
9	13	3	13,21	-	-
10	13	4	-	-	-
11	13	4	11,21	-	-
12	13	4	11,12,13,21,22,23	15	-
13	13	5	11,21	-	-
14	13	6	-	-	-
15	13	8	14	12,22	-
16	13	8	11	-	-

Table V. Continued

Patient	Age (year)	DMFT [*] score	Hypoplasia	Hypodontia	Root shortening
17	13	13	11,21	-	11,12,21,22,31,32,41,42
18	13	15	11,12,21,22	-	-
19	13	18	21	-	31,32,41,42
20	14	3	-	35,45	31,31,41,42,14,24,36,46
21	14	4	-	-	-
22	14	4	-	-	-
23	14	5	-	45	
24	14	6	-	-	-
25	15	0	-	-	32,41,42
26	15	4	34,44	-	31,32,41,42
27	15	4	-	-	-
28	15	9	11	23	31,32,33,34,35,41,42,43,44,45
29	15	11	11,21	-	31,32,33,34,35,41,42,43,44,45
30	16	8	21	-	-
31	16	10		-	-
32	16	13	11,21	26	-
33	16	15	-	-	31,32,41,42,44
34	17	2	-	22	32,42
35	17	6	11	-	-

^{*}DMFT: Decayed, Missing, Filled Teeth
^{**}Dental numbering system is used according to FDI WORLD DENTAL FEDERATION NOTATION (ISO 3950)

Discussion

Of the 90 patients meeting our study criteria, only 35 attended their appointments for oral examination. While oral and dental health is important for every child, it is especially crucial for those children undergoing cancer treatment. However, when facing a life-threatening cancer disease, both families and healthcare providers understandably prioritize preserving the patient's life and ensuring they lead a healthy life without compromising their quality of life. Unfortunately, oral and dental health does not rank high in terms of importance. In a study involving 4,856 childhood survivors, it was found that socioeconomic status and difficulty in accessing dental care, apart from cancer treatment, were significant risk factors in the development of dental anomalies (13). In our study, despite emphasizing the importance of oral and dental health and informing patients that they would be examined promptly by a pediatric dentistry specialist with knowledge of their past treatments, only 38.8% underwent examination. This result underscores the unfortunate reality that dental health still does not receive the attention it deserves from families and

patients, highlighting a significant need for education in this regard.

A study including 35 patients with a history of treatment due to solid tumors demonstrated that the number of malformed teeth was higher in those patients treated under the age of six (14). In another more comprehensive study involving 1,273 cases, it was shown that a treatment history at ages 5-6 was the most significant risk factor for dental caries development when combined with radiotherapy (15). Another study reviewed 93 pediatric cases receiving chemotherapy who were divided into two age groups for analysis. The first group consisted of cases treated between 9 months and 4 years of age, while the second group included cases treated between 5 and 7 years of age. A higher frequency of microdontia and hypodontia was observed in the first group (16). In our study, all cases consisted of patients treated under the age of six years, with the average age at diagnosis being four years. As the age at diagnosis increased, the rate of root shortening development significantly increased. If we consider that the highest age among our cases is six years, it is thought

that the reason is based on the continued increase in root development of permanent teeth during this period.

In our cases, while the average number of dental caries was four, the mean DMFT index was determined to be five. In a study involving 62 cases, where all age groups were included and only solid tumors were evaluated, although the average DMFT score was higher in those patients who had received cancer treatment compared to a control group of healthy individuals, this difference was not statistically significant (17). In a multicenter study comparing 50 cancer patients, mostly leukemia cases, with 51 healthy individuals, it was shown that dental caries was more common in cancer patients, but this difference was not statistically significant (18). Similar to the literature, in our study, there was no statistically significant difference between the DMFT scores and the patients' clinical characteristics and treatment modalities. Other studies have also shown, similar to our study results, that chemotherapy alone does not have an impact on the prevalence of dental caries development in the long term (19,20). In a study examining dental development anomalies which may occur due to treatment, it was stated that there was no statistically significant difference between the average DMFT score and the chemotherapeutic agents used (14). Similarly, in our study, there was no statistically significant difference between DMFT and chemotherapeutic agents.

In our study, hypoplasia was found in 57.1% of cases, root shortening was present in approximately one-third, and hypodontia was observed in 22.9%. In another study from the literature, it was reported that microdontia was observed in 19% and hypodontia in 9% of 150 patients who had received cancer treatment (21). A study conducted by the Childhood Cancer Survivors Study group indicated that abnormal dental roots were found in 5% of children who underwent cancer treatment compared to 3% in their siblings, suggesting that their treatment affected the root anomalies (22). In our study, root shortening was present in approximately one-third of cases, and taurodontism was observed in 5.7%. Another study conducted in Sweden also reported that short and V-shaped roots were observed in 94% of patients who had received chemotherapy and radiotherapy (23). In recent study, hypodontia was mostly seen in the lower second premolars followed by the upper lateral incisors. Root shortening was mostly in the lower central and lateral incisors. In another study in the literature, hypodontia, similar to our study, was most commonly observed in the second premolar teeth, whereas root anomalies, unlike in our study, were most frequently

found in the first and second premolars as well as the first molars (16).

When evaluating the relationship between treatment and dental findings in our study, no statistically significant difference was found between the history of steroid use and dental findings. Some of the effects of steroid use on dental tissues include a reduction in alveolar bone, osteoporosis due to decreased osteoblast count, and the formation of fibrosis in periodontal spaces (24). In a study examining the effects of steroid dose and treatment duration on dental development anomalies in 31 children with nephrotic syndrome, the negative effects of steroids on dental health were demonstrated, and it was indicated that long-term use was more influential than dosage (25). In our study, ten patients who had received steroids also had a history of receiving a chemotherapeutic agent. However, when comparing the dental findings of those patients who had received steroids with those who had not, no statistically significant difference was found. This lack of difference may be attributed to the generally short duration of steroid use in those patients with solid tumors.

In our study, a history of radiotherapy and the radiation therapy area did not show a statistically significant effect on dental development. In a recent study, the risk of agenesis and root changes was found to be significantly higher in those patients receiving chemotherapy and radiotherapy (26). In the study conducted by Kılınc et al. (16), root malformation was found to be statistically more frequent in those cases receiving both chemotherapy and radiotherapy compared to those cases receiving chemotherapy alone. Furthermore, the frequency of root malformation was observed to increase proportionally with the dosage of radiotherapy (16). In another study conducted by Proc et al. (27), similar to our study, it was found that radiotherapy did not influence the type and severity of dental abnormalities. However, regarding chemotherapy, a statistically significant higher frequency of root shortening was observed in the group receiving alkylating agents and the group receiving alkylating agents in combination with vinca alkaloids. Alkylating agents negatively affect odontoblasts due to their rapid proliferation during odontogenesis, which explains the root shortening observed in our study. Another recent study also showed that alkylating agents significantly influenced the formation of root shortening (26).

Study Limitations

The limitation of our study was that we lacked information regarding the dental status of the patients before undergoing their anticancer treatment.

Conclusion

In conclusion, undergoing cancer treatment during the primary dentition period leads to dental developmental anomalies. This study demonstrates that among the treatment modalities, alkylating agents have the most detrimental effect on dental development. Additionally, it is believed that these patients and their families should be supported with education emphasizing the importance of oral and dental health.

Ethics

Ethics Committee Approval: The study protocol was approved by the Marmara University Faculty of Medicine, Clinical Research Ethics Committee (date: 03.02.2023, number: 09.2023.333).

Informed Consent: Before the start of this study, the families of all participants signed an informed consent form.

Authorship Contributions

Surgical and Medical Practices: N.E., N.A., O.D., Concept: N.E., A.M., Design: N.E., B.A., D.G., Data Collection and/or Processing: N.E., A.M., N.A., O.D., Analysis and/or Interpretation: N.E., A.S., Literature Search: N.E., A.M., G.T., Writing: N.E., A.M.

Conflict of Interest: The authors declare that there is no conflict of interest regarding the publication of this article.

Financial Disclosure: The authors received no financial support for the research, authorship, and/or publication of this article.

References

- Zubowska M, Wyka K, Fendler W, Młynarski W, Zalewska-Szewczyk B. Interleukin 18 as a marker of chronic nephropathy in children after anticancer treatment. *Dis Markers*. 2013; 35:811-8.
- Valéra MC, Noirrit-Esclassan E, Pasquet M, Vaysse F. Oral complications and dental care in children with acute lymphoblastic leukaemia. *J Oral Pathol Med*. 2015; 44:483-9.
- Maguire A, Craft A, Evans RG, et al. The long-term effects of treatment on the dental condition of children surviving malignant disease. *Cancer*. 1987; 60:2570-5.
- Dens F, Boute P, Otten J, Vinckier F, Declerck D. Dental caries, gingival health, and oral hygiene of long term survivors of paediatric malignant diseases. *Arch Dis Child*. 1995; 72:129-32.
- Lauritano D, Petrucci M. Decayed, missing and filled teeth index and dental anomalies in long-term survivors leukaemic children: a prospective controlled study. *Med Oral Patol Oral Cir Bucal*. 2012; 17:e977-80.
- Nemeth O, Hermann P, Kivovics P, Garami M. Long-term effects of chemotherapy on dental status of children cancer survivors. *Pediatr Hematol Oncol*. 2013; 30:208-15.
- Bagattoni S, D'Alessandro G, Prete A, Piana G, Pession A. Oral health and dental late adverse effects in children in remission from malignant disease. A pilot case-control study in Italian children. *Eur J Paediatr Dent*. 2014; 15:45-50.
- Stolze J, Vlaanderen KCE, Holtbach FCED, et al. Long-Term Effects of Childhood Cancer Treatment on Dentition and Oral Health: A Dentist Survey Study from the DCCSS LATER 2 Study. *Cancers (Basel)*. 2021; 13:5264.
- Pajari U, Lanning M. Developmental defects of teeth in survivors of childhood ALL are related to the therapy and age at diagnosis. *Med Pediatr Oncol*. 1995; 24:310-4.
- Rosenberg SW, Kolodney H, Wong GY, Murphy ML. Altered dental root development in long-term survivors of pediatric acute lymphoblastic leukemia. A review of 17 cases. *Cancer*. 1987; 59:1640-8.
- Heimdahl A, Johnson G, Danielsson KH, Lönnqvist B, Sundelin P, Ringden O. Oral condition of patients with leukemia and severe aplastic anemia. Follow-up 1 year after bone marrow transplantation. *Oral Surg Oral Med Oral Pathol*. 1985; 60:498-504.
- Minicucci EM, Lopes LF, Crocci AJ. Dental abnormalities in children after chemotherapy treatment for acute lymphoid leukemia. *Leuk Res*. 2003; 27:45-50.
- Patni T, Lee CT, Li Y, et al. Factors for poor oral health in long-term childhood cancer survivors. *BMC Oral Health*. 2023; 23:73.
- Halperson E, Matalon V, Goldstein G, et al. The prevalence of dental developmental anomalies among childhood cancer survivors according to types of anticancer treatment. *Sci Rep*. 2022; 12:4485.
- Wogelius P, Dahllöf G, Gorst-Rasmussen A, Sørensen HT, Rosthøj S, Poulsen S. A population-based observational study of dental caries among survivors of childhood cancer. *Pediatr Blood Cancer*. 2008; 50:1221-6.
- Kılınc G, Bulut G, Ertuğrul F, et al. Long-term Dental Anomalies after Pediatric Cancer Treatment in Children. *Turk J Haematol*. 2019; 36:155-61.
- Cubukçu CE, Sevinir B. Dental health indices of long-term childhood cancer survivors who had oral supervision during treatment: a case-control study. *Pediatr Hematol Oncol*. 2008; 25:638-46.
- Kerbaçe C, Macari AT, Kerbaçe A, Chedid N. Comparison of oral health characteristics in pediatric cancer and cancer free patients: a multicenter study. *Pediatric Dental Journal*. 2023; 33:139-46.
- Uderzo C, Fraschini D, Balduzzi A, et al. Long-term effects of bone marrow transplantation on dental status in children with leukaemia. *Bone Marrow Transplant*. 1997; 20:865-9.
- Dahllöf G, Heimdahl A, Bolme P, Lönnqvist B, Ringdén O. Oral condition in children treated with bone marrow transplantation. *Bone Marrow Transplant*. 1988; 3:43-51.
- Pedersen LB, Clausen N, Schrøder H, Schmidt M, Poulsen S. Microdontia and hypodontia of premolars and permanent molars in childhood cancer survivors after chemotherapy. *Int J Paediatr Dent*. 2012; 22:239-43.
- Kaste SC, Goodman P, Leisenring W, et al. Impact of radiation and chemotherapy on risk of dental abnormalities: a report

- from the Childhood Cancer Survivor Study. *Cancer*. 2009; 115:5817-27.
23. Näsman M, Forsberg CM, Dahllöf G. Long-term dental development in children after treatment for malignant disease. *Eur J Orthod*. 1997; 19:151-9.
 24. Glickmann I, Stone IC, Chawla TN. Effect of cortisone acetate on the periodontal tissues of white mice. *J Dent Res*. 1951; 30:461.
 25. Piekoszewska-Ziętek P, Olczak-Kowalczyk D, Pańczyk-Tomaszewska M, Gozdowski D. Developmental Abnormalities of Teeth in Children With Nephrotic Syndrome. *Int Dent J*. 2022; 72:572-7.
 26. Rabassa-Blanco J, Brunet-Llobet L, Marcote-Sinclair P, Balsells-Mejía S, Correa-Llano MG, Miranda-Rius J. Prevalence of, and risk factors for, dental sequelae in adolescents who underwent cancer therapy during childhood. *Oral Dis*. 2024; 30:604-14.
 27. Proc P, Szczepańska J, Skiba A, Zubowska M, Fendler W, Młynarski W. Dental Anomalies as Late Adverse Effect among Young Children Treated for Cancer. *Cancer Res Treat*. 2016; 48:658-67.