

## Research Article

# The effect of topical and systemic tranexamic acid on fracture healing in rats

Hüseyin Bilgehan Çevik<sup>1</sup> , Engin Eceviz<sup>1</sup> , Özlem Tuğçe Çilingir Kaya<sup>2</sup> , Feriha Ercan<sup>2</sup> , Gültekin Sıtkı Çeçen<sup>1</sup>

<sup>1</sup>Department of Orthopaedics and Traumatology, University of Health Sciences, Kartal Dr. Lütfi Kırdar Research and Training Hospital, İstanbul, Turkey

<sup>2</sup>Department of Histology and Embryology, Marmara University, School of Medicine, İstanbul, Turkey

## ARTICLE INFO ABSTRACT

## Article history:

Submitted 22 January 2019

Received in revised form

8 April 2019

Last revision received

17 September 2019

Accepted 1 March 2020

## Keywords:

Tranexamic acid

Fracture healing

In vivo experiment

Fibrin

Hematoma

## ORCID IDs of the authors:

H.B.Ç. 0000-0003-1945-3715;

E.E. 0000-0003-2453-0869;

Ö.T.Ç. 0000-0002-2591-9174;

F.E. 0000-0003-2339-5669;

G.S.Ç. 0000-0002-5916-7820.

**Objective:** The aim of the present study was to determine the effect of topical and systemic tranexamic acid (TXA) on fracture healing in a rat surgical model.

**Methods:** We created standard, right-sided, open, diaphyseal femoral fractures with intramedullary Kirschner wire fixation in 48 male rats and divided them into three groups: a topical TXA (10 mg/kg) group, a systemic TXA (10 mg/kg) group, and a control group. Fracture healing was evaluated radiographically and histologically after early (week 2) and late (week 4) postoperative sacrifice.

**Results:** The radiological scores differed significantly among the all groups ( $p=0.001$ ), as did the week 2 and 4 scores ( $p=0.003$  and  $p=0.010$ , respectively). Radiologically, the topical TXA group exhibited better bone healing at both 2 ( $p=0.001$ ) and 4 ( $p=0.007$ ) weeks than the control group, and the systemic group showed better healing at both 2 ( $p=0.027$ ) and 4 ( $p=0.023$ ) weeks than the control TXA group. Moreover, bone healing was better in the group treated with topical rather than systemic TXA on radiological examinations performed at 2 ( $p=0.001$ ) and 4 ( $p=0.007$ ) weeks postoperatively ( $p=0.001$  and  $p=0.007$ , respectively). Histologically, the groups differed significantly ( $p=0.001$ ). The histological scores differed significantly among the all groups ( $p=0.001$ ). At 2 weeks, the topical TXA group exhibited significantly better bone healing than the control group ( $p=0.001$ ).

**Conclusion:** Our results suggested that topical application of TXA in fracture patients may accelerate healing, whereas systemic administration may adversely affect healing.

Fracture healing and its complications are important issues in orthopedics and traumatology. Most information on fracture healing comes from retrospective investigations. However, the inferences drawn have not been confirmed experimentally.

In recent years, tranexamic acid (TXA) has been widely used to reduce postoperative bleeding, transfusion requirements, length of the hospital stay, and morbidity (1-4), particularly during arthroplasty procedures (5-8). Both topical and systemic use of TXA have been reported (2, 5, 6) and were found to reduce bleeding to a similar extent (9). However, little information is available on the causes of thromboembolic complications developing after intravenous TXA administration (2, 4, 7, 10, 11). TXA is contraindicated in patients with a history of prior arterial or venous thrombosis, decreased creatinine clearance ( $<30$  mL/min), a history of epilepsy, and prior estrogen or progestone therapy (11).

Recently, TXA has been administered also to reduce postoperative bleeding, transfusion requirements, length of the hospital stay, and morbidity during fracture surgery in orthopedic and traumatology departments (10-12). The English-language literature lacks information on the efficacy of such treatment on fracture healing. Nevertheless, the effect of the fracture hematoma on fracture healing is known (13-16). The effects of TXA on fracture healing remain unclear. However, it is known that good healing requires robust blood flow to the fracture line (17).

What if TXA affect the fracture healing besides reducing bleeding and hematoma formation? A question remains as to whether the use of TXA to reduce blood loss during fracture surgery positively or negatively affects fracture healing. We explored the effects of TXA on fracture healing both radiologically and histologically in an animal model.

## Corresponding Author:

Hüseyin Bilgehan Çevik  
bilgehancevik@gmail.com



Content of this journal is licensed under a Creative Commons Attribution-NonCommercial 4.0 International License.

**Cite this article as:** Çevik HB, Eceviz E, Çilingir Kaya ÖT, Ercan F, Çeçen GS. The effect of topical and systemic tranexamic acid on fracture healing in rats. *Acta Orthop Traumatol Turc* 2020; 54(2): 207-12.

## Materials and Methods

This investigation was conducted using a protocol approved by the Animal Care Committee of Acibadem University.

We established a rat model of the effects of TXA on short- and long-term fracture healing. Forty-eight male Wistar albino rats (age: 3–3.5 months; weight 280–320 g) were used (18, 19) (Hipokrat®, İzmir, Turkey). All rats were intraperitoneally anesthetized with a mixture of 5–10 mg/kg xylazine (Rompun®, Bayer, Leverkusen, Germany) and 50–80 mg/kg ketamine (Ketalar®, Pfizer, NY, USA) (20). The right legs were shaved and disinfected. We used an open osteotomy model (21). This was preferred in order for TXA to be applied to the fracture line at a desired dose and without any loss of TXA. Transverse osteotomy was performed at the mid-diaphysis of the right femur using an electric saw (Electric Pen Drive; DePuy Synthes, Raynham, MA, USA) with a 0.38-mm-thick blade, and the fracture was stabilized via intramedullary insertion of a sterilized Kirschner wire, 1 mm in diameter (Hipokrat®, İzmir, Turkey) (22, 23). For the systemic TXA group, TXA was systemically administered at the therapeutic dose (intravenous administration via rat dorsal tail vein, 10 mg/kg). For the topical group, TXA was topically administered at the therapeutic dose (10 mg/kg) on the fracture line (24). All surgeries were performed by a single surgeon (HBC). No animal died and no complication was detected.

The rats were randomly chosen for sacrifice in a blinded manner. To simulate early and late fracture healing, animals were sacrificed at two times: 2 and 4 weeks after the operation (n=8 in all three groups; topical and systemic TXA, 10 mg/kg, and controls). The entire femur was removed without damaging callus tissues. Antero-posterior and lateral digital radiographs of each femur were obtained. Bridging of the fractured callus was assessed in a blinded manner by two independent orthopedic surgeons using the radiological scoring system of Lane and Sandhu (0–4 points) (22). This system evaluates union, spongy bone formation, and bone marrow organization.

Bone tissue specimens were fixed in 10% (v/v) neutral formalin and decalcified for 10–14 days in decalcification solution (Osteomoll®, Merck Millipore, Burlington, MA, USA) after washing with distilled water. Tissues were dehydrated in a graded series of alcohol baths and embedded in paraffin. Five-micron-thick sections were

obtained and stained with hematoxylin and eosin (H&E) to evaluate trabecular formation and Masson's trichrome (04-010802; Bio-Optica, Milan, Italy) to view fibrous connective tissue, calcification, and general appearance. Sections were examined microscopically (BX51; Olympus, Tokyo, Japan) and photographed (DP72; Olympus). We used the histological scoring system of Huo et al. to assess bone tissues from at least five random areas, under 20× magnification, for each group (25). The analysis was conducted in a blinded manner using validated, histologic scores ranging from 1 to 10.

### Statistical analysis

Statistical analysis was performed using the Number Cruncher Statistical System 2007 (NCSS Statistical Software, Kaysville, UT, USA). The Kruskal–Wallis test was used to compare radiological and histological scores that were not normally distributed, and the Bonferroni-corrected Mann–Whitney U test was employed to identify the group responsible for the observed differences. We also derived descriptive statistics (means, standard deviations, medians, frequencies, and ratios) and 95% confidence intervals;  $p < 0.05$  was considered to reflect statistical significance.

## Results

Callus formation was observed in the osteotomy lines of all rats (Figure 1). Overall, the radiological scores differed significantly among all the groups ( $p=0.001$ ), as did the week 2 ( $p=0.003$ ) and 4 ( $p=0.010$ ) scores. The group receiving topical TXA exhibited better bone healing at both 2 ( $p=0.001$ ) and 4 ( $p=0.007$ ) weeks relative to the systemic group, and the systemic group exhibited better healing than the control group at both 2 ( $p=0.027$ ) and 4 ( $p=0.023$ ) weeks.

Radiologically, bone healing was better in the topical versus the systemic TXA group at weeks 2 and 4 ( $p=0.001$  and  $p=0.007$ , respectively). Moreover, healing was better in the control group than in the systemic TXA group at weeks 2 and 4 ( $p=0.027$  and  $p=0.023$ , respectively). However, no significant differences in radiological scores were evident between the topical TXA group and the control group at 2 and 4 weeks (Table 1).

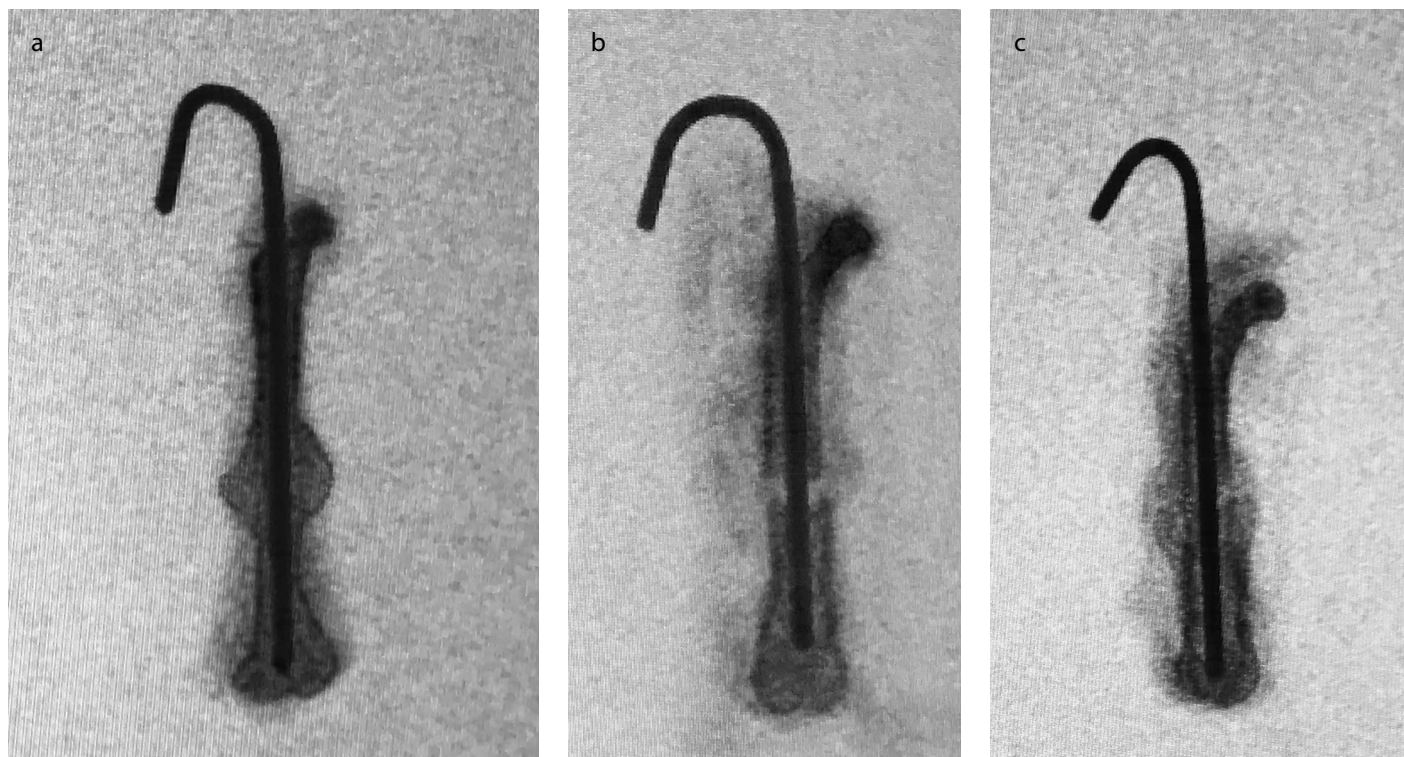
The histological results differed significantly among all groups ( $p=0.001$ ), as did the histological scores at week 2 ( $p=0.004$ ); no significant between-group difference in histological scores was evident at week 4 ( $p>0.05$ ). At both 2 and 4 weeks, the topical TXA group exhibited significantly better bone mineralization than the control group at week 2 ( $p=0.001$  and  $p=0.001$ , respectively; Table 2). Bone tissue specimens of week 2 are shown in Figure 2.

## Discussion

Fracture healing remains one of the most important research areas in orthopedics. Factors affecting fracture healing (either positively or negatively) are the subject of much research interest and investigating the effects of commonly used drugs on fracture healing is important in this context.

### MAIN POINTS

- Topical application of tranexamic acid in fracture patients may accelerate healing, whereas systemic administration may adversely affect healing.
- Tranexamic acid, an antifibrinolytic lysine analog, inhibits plasminogen activation and is thought to reduce blood loss by exhibiting antifibrinolytic activity, especially when fibrinolysis is present.
- It was stated that the primary component of the fracture hematoma is fibrin. Thus, the use of antifibrinolytic agents, such as tranexamic acid, to prolong the duration of fibrin clots at fracture sites may contribute to both fracture microstabilization and bleeding control.



**Figure 1. a-c.** (a) Plain radiograph taken at 4 weeks post fracture of topical TXA group. (b) Plain radiograph taken at 4 weeks post fracture of systemic TXA group. (c) Plain radiograph taken at 4 weeks post fracture of control group

**Table 1.** Evaluation of radiographic scores by group and time

	Average radiology score			
	Min-max	Mean	25 <sup>th</sup> percentile	75 <sup>th</sup> percentile
Topical group week 2 (n=8)	4 - 4	4	3.8	4
Topical group week 4 (n=8)	4 - 4	4	3.8	4
Systemic group week 2 (n=8)	3 - 4	3	3	3.6
Systemic group week 4 (n=8)	3 - 4	3.4	3.3	3.7
Control group week 2 (n=8)	4 - 4	4	3.3	4
Control group week 4 (n=8)	3 - 4	3.8	3.6	4
All groups p	0.001 <sup>a,**</sup>			
Week 2 p	0.003 <sup>a,**</sup>			
Week 4 p	0.010 <sup>a,*</sup>			
Topical week 2 - Systemic week 2	0.001 <sup>b,**</sup>			
Topical week 2 - Systemic week 4	0.007 <sup>b,**</sup>			
Topical week 2 - Control week 2	0.09 <sup>b</sup>			
Topical week 4 - Systemic week 2	0.001 <sup>b,**</sup>			
Topical week 4 - Systemic week 4	0.007 <sup>b,**</sup>			
Topical week 4 - Control week 4	0.331 <sup>b</sup>			
Systemic week 2 - Control week 2	0.027 <sup>b,*</sup>			
Systemic week 2 - Control week 4	0.004 <sup>b,**</sup>			
Systemic week 4 - Control week 4	0.023 <sup>b,*</sup>			

<sup>a</sup>Kruskal-Wallis test

<sup>b</sup>Mann-Whitney U test

\*p<0.05, \*\*p<0.01.

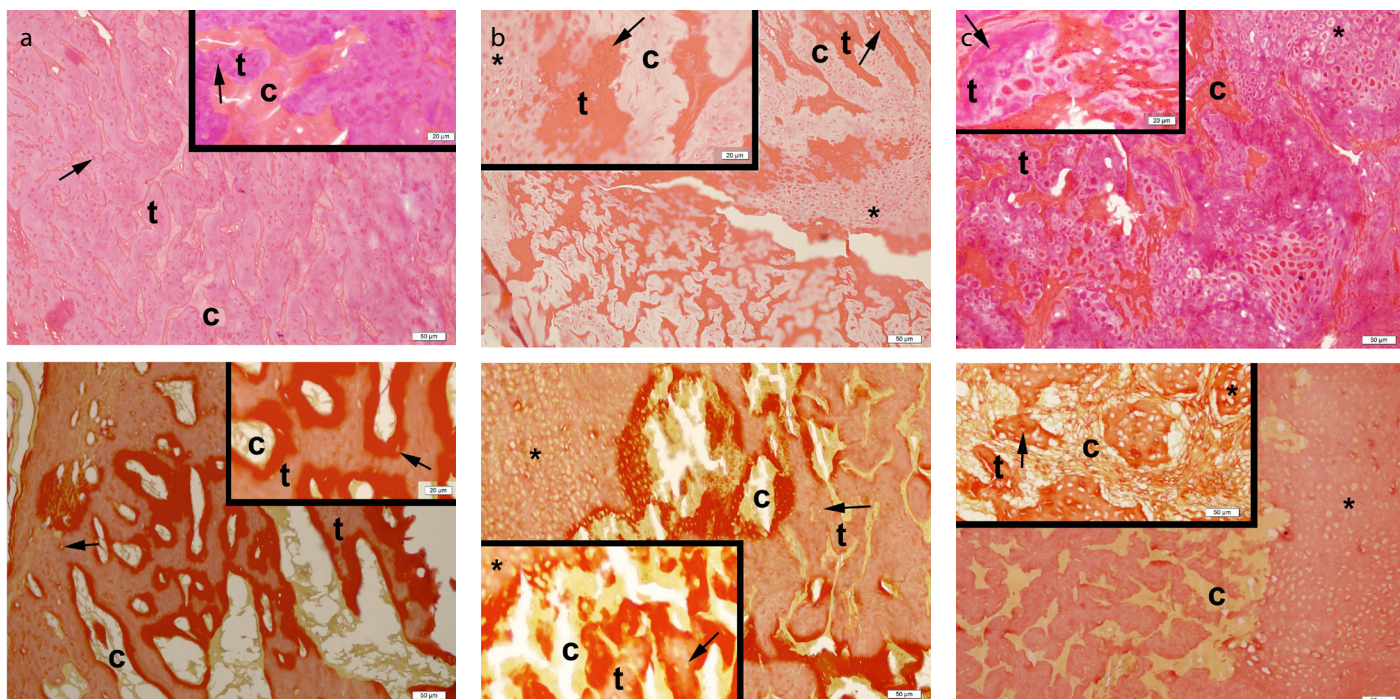
**Table 2.** Evaluation of histological scores by group and time

	Average histology scores			
	Min-Max	Mean	25 <sup>th</sup> percentile	75 <sup>th</sup> percentile
Topical week 2 (n=8)	8 - 9	9	9	9
Topical week 4 (n=8)	8 - 9.5	9	9	9.4
Systemic week 2 (n=8)	6.5 - 9	8	7	9
Systemic week 4 (n=8)	8 - 9.5	8	8	9.1
Control week 2 (n=8)	6 - 8	7.5	6.3	8
Control week 4 (n=8)	8 - 9	9	8.3	9
All groups p	0.003 <sup>a,**</sup>			
Week 2 p	0.004 <sup>b,**</sup>			
Week 4 p	0.158 <sup>b</sup>			
Topical week 2 - Systemic week 2	0.065			
Topical week 2 - Control week 2	0.001 <sup>**</sup>			
Topical week 4 - Systemic week 2	0.021 <sup>*</sup>			
Topical week 4 - Systemic week 4	0.092			
Topical week 4 - Control week 2	0.001 <sup>**</sup>			
Topical week 4 - Control week 4	0.199			
Systemic week 2 - Control week 2	0.234			
Systemic week 4 - Control week 2	0.038 <sup>*</sup>			
Systemic week 4 - Control week 4	0.328			
Control week 2 - Control week 4	0.002 <sup>**</sup>			

<sup>a</sup>Kruskal-Wallis test

<sup>b</sup>Mann-Whitney U test

\*p<0.05, \*\*p<0.01



**Figure 2. a-c.** (a) Showing immature bone trabeculae [t] and fibrous connective tissue [c] in fracture area of topical TXA group at the 2<sup>nd</sup> week (A: Hematoxylin and Eosin; B: Masson's trichrome). (b) Showing cartilaginous tissue (\*) and osteocytes (arrow) in immature bone formation and trabeculae [t] equally in fracture area of systemic TXA group at the 2<sup>nd</sup> week (A: Hematoxylin and Eosin; B: Masson's trichrome). (c) Showing massive cartilaginous tissue (\*), immature bone trabeculae [t], osteocytes (arrow), and connective tissue [c] formation in fracture area of control group at the 2<sup>nd</sup> week (A: Hematoxylin and Eosin; B: Masson's trichrome)

The English-language literature contains no study on the effect of TXA on fracture healing. We considered that TXA might either positively or negatively affect healing, despite the reduced surgical bleeding and prevention of fibrin degradation. TXA is currently used during orthopedic fracture surgery to reduce blood loss, the need for blood transfusion, and related complications, although the effects of topical and systemic TXA on fracture healing remain unknown (11, 12, 26-29).

Bleeding during and after surgery is believed to be attributable to increased fibrinolysis (30). TXA, an antifibrinolytic lysine analog, inhibits plasminogen activation and is thought to reduce blood loss by exhibiting antifibrinolytic activity, especially when fibrinolysis is present.

Postfracture healing begins immediately with hematoma formation, and remodeling continues for many years. Although the effect of a fracture hematoma on fracture healing is not fully understood, the hematoma is known to be important (13). Hematoma has been reported to be essential for the initiation of fracture healing (15, 31, 32). In rats, the removal of the fracture hematoma significantly reduced fracture healing (16). We found that systemic (compared with topical) TXA delayed fracture healing on the basis of radiological and histological data, perhaps by inhibiting fracture hematoma formation. This finding may be clarified in the future studies.

The major causes of postoperative blood loss after fracture surgery are the trauma that caused the fracture, and activation of the coagulation pathway and local fibrinolysis triggered by trauma caused by surgery. Tourniquet drainage after surgery further enhances local fibrinolysis (33). Wong et al. reported that fibrinolysis over the whole extremity was reduced by application of topical TXA after tourniquet deflation in patients undergoing total knee arthroplasty (10). The use of a tourniquet is common during limb fracture surgery. After tourniquet removal, increased fibrinolytic activity throughout the extremity may prevent the development of complications, such as deep vein thrombosis, and may suppress local hemostasis and fibrin plug formation. In our present study, topical TXA afforded better fracture healing than was seen in the control group, while the control group exhibited better histological and radiological healing than the systemic TXA group, both early and late after fracture.

Positive effects of fibrin clots on the early phases of bone healing have been shown in animal studies. The physical properties of bone callus improved when fibrin clots were present (34, 35). Echeverri et al. reported that although the fracture hematoma played a minor mechanical role, in terms of fracture immobilization, in the early stages of healing, it served as a fibrin scaffold and thus provided a microenvironment within which cell-mediated repair could proceed (14). It was found that the principal component of the fracture hematoma was fibrin. When growth factors are released from the fibrin clot, mesenchymal cells are attracted to the fracture site, differentiate into fibroblasts, adhere

to the clot, and synthesize the collagen extracellular matrix that forms the early fibrous callus. Furthermore, the fact that post-fracture fibrin clots are common may indicate that they stabilize early fibrous callus tissue (14). Thus, the use of antifibrinolytic agents, such as TXA, to prolong the duration of fibrin clots at fracture sites may contribute to both fracture microstabilization and bleeding control. Our study suggests that this explains the earlier callus formation seen in the topical TXA relative to the control group, as evident both radiologically and histologically.

Our study had certain limitations. First, we did not measure postoperative bleeding and volume of hematoma. Second, our study has been conducted with limited number of animals, and therefore, the possibility of making definite inferences is limited. All radiological findings were not able to support the histological findings. Lastly, we did not evaluate fracture healing with micro-CT.

We found that application of topical TXA during orthopedic fracture surgery may accelerate fracture healing and that systemic use may delay healing. This topic should be further investigated in animal experiments with different parameters for mechanism of action of TXA and clinical studies.

**Ethics Committee Approval:** Ethics committee approval was received for this study from the Animal Care Committee of Acibadem University, Laboratory Animal Application and Research Center (Protocol No: ACU-HADYK 2017/12).

**Informed Consent:** N/A.

**Author Contributions:** Concept - H.B.Ç., E.E., Ö.T.Ç.K., F.E., G.S.Ç.; Design - H.B.Ç., E.E., Ö.T.Ç.K., F.E., G.S.Ç.; Supervision - H.B.Ç., E.E., Ö.T.Ç.K., F.E., G.S.Ç.; Resources - H.B.Ç., E.E., Ö.T.Ç.K., F.E., G.S.Ç.; Materials - H.B.Ç., E.E., Ö.T.Ç.K., F.E., G.S.Ç.; Data Collection and/or Processing - H.B.Ç., E.E., Ö.T.Ç.K., F.E., G.S.Ç.; Analysis and/or Interpretation - H.B.Ç., E.E., Ö.T.Ç.K., F.E., G.S.Ç.; Literature Search - H.B.Ç., E.E., Ö.T.Ç.K., F.E., G.S.Ç.; Writing Manuscript - H.B.Ç., E.E., Ö.T.Ç.K., F.E., G.S.Ç.; Critical Review - H.B.Ç., E.E., Ö.T.Ç.K., F.E., G.S.Ç.

**Conflict of Interest:** The authors have no conflicts of interest to declare.

**Financial Disclosure:** The authors declared that this study has received no financial support.

## References

1. Collaborators C-. The importance of early treatment with tranexamic acid in bleeding trauma patients: an exploratory analysis of the CRASH-2 randomised controlled trial. 2011; 377: 1096-101. [\[CrossRef\]](#)
2. Dunn CJ, Goa KL. Tranexamic acid. *Drugs* 1999; 57: 1005-32. [\[CrossRef\]](#)
3. Gausden EB, Garner MR, Warner SJ, et al. Tranexamic acid in hip fracture patients: a protocol for a randomised, placebo controlled trial on the efficacy of tranexamic acid in reducing blood loss in hip fracture patients. *BMJ Open* 2016; 6: e010676. [\[CrossRef\]](#)

4. Ker K, Edwards P, Perel P, Shakur H, Roberts I. Effect of tranexamic acid on surgical bleeding: systematic review and cumulative meta-analysis. *BMJ* 2012; 344: e3054. [\[CrossRef\]](#)
5. Benoni G, Fredin H. Fibrinolytic inhibition with tranexamic acid reduces blood loss and blood transfusion after knee arthroplasty. *Bone Joint J* 1996; 78: 434-40. [\[CrossRef\]](#)
6. Ho K, Ismail H. Use of intravenous tranexamic acid to reduce allogeneic blood transfusion in total hip and knee arthroplasty: a meta-analysis. *Anaesth Intensive Care* 2003; 31: 529-37. [\[CrossRef\]](#)
7. Sukeik M, Alshryda S, Haddad F, Mason J. Systematic review and meta-analysis of the use of tranexamic acid in total hip replacement. *J Bone Joint Surg Br* 2011; 93: 39-46 [\[CrossRef\]](#)
8. Gulabi D, Yuce Y, Erkal KH, Saglam N, Camur S. The combined administration of systemic and topical tranexamic acid for total hip arthroplasty: Is it better than systemic? *Acta Orthop Traumatol Turc* 2019; 53: 297-300. [\[CrossRef\]](#)
9. Emara WM, Moez KK, Elkhouly AH. Topical versus intravenous tranexamic acid as a blood conservation intervention for reduction of post-operative bleeding in hemiarthroplasty. *Anesth Essays Res* 2014; 8: 48-53. [\[CrossRef\]](#)
10. Wong J, Abrishami A, El Beheiry H, et al. Topical application of tranexamic acid reduces postoperative blood loss in total knee arthroplasty: a randomized, controlled trial. *J Bone Joint Surg Am* 2010; 92: 2503-13. [\[CrossRef\]](#)
11. Zufferey P, Miquet M, Quenet S, et al. Tranexamic acid in hip fracture surgery: a randomized controlled trial. *Br J Anaesth* 2009; 104: 23-30. [\[CrossRef\]](#)
12. Gausden EB, Qudsi R, Boone MD, O'gara B, Ruzbarsky JJ, Lorich DG. Tranexamic acid in orthopaedic trauma surgery: A meta-analysis. *J Orthop Trauma* 2017; 31: 513-9. [\[CrossRef\]](#)
13. Kolar P, Schmidt-Bleek K, Schell H, et al. The early fracture hematoma and its potential role in fracture healing. *Tissue Eng Part B Rev* 2010; 16: 427-34. [\[CrossRef\]](#)
14. Echeverri L, Herrero M, Lopez J, Oleaga G. Early stages of bone fracture healing: formation of a fibrin-collagen scaffold in the fracture hematoma. *Bull Math Biol* 2015; 77: 156-83. [\[CrossRef\]](#)
15. Einhorn TA. Enhancement of fracture-healing. *J Bone Joint Surg Am* 1995; 77: 940-56. [\[CrossRef\]](#)
16. Grundnes O, Reikerås O. The importance of the hematoma for fracture healing in rats. *Acta Orthop Scand* 1993; 64: 340-2. [\[CrossRef\]](#)
17. Brinker MR, O'Connor DP. The biological basis for nonunions. *JBJS Rev* 2016; 4. pii: 01874474-201606000-00001. [\[CrossRef\]](#)
18. Auer JA, Goodship A, Arnoczky S, et al. Refining animal models in fracture research: seeking consensus in optimising both animal welfare and scientific validity for appropriate biomedical use. *BMC Musculoskelet Disord* 2007; 8: 72. [\[CrossRef\]](#)
19. Iwaki A, Jingushi S, Oda Y, et al. Localization and quantification of proliferating cells during rat fracture repair: detection of proliferating cell nuclear antigen by immunohistochemistry. *J Bone Miner Res* 1997; 12: 96-102. [\[CrossRef\]](#)
20. Bordei P. Locally applied platelet-derived growth factor accelerates fracture healing. *J Bone Joint Surg Br* 2011; 93: 1653-9. [\[CrossRef\]](#)
21. Suen PK, He YX, Chow DHK, et al. Sclerostin monoclonal antibody enhanced bone fracture healing in an open osteotomy model in rats. *J Orthop Res* 2014; 32: 997-1005 [\[CrossRef\]](#)
22. Lane JM, Sandhu H. Current approaches to experimental bone grafting. *Orthop Clin North Am* 1987; 18: 213-25.
23. Tägil M, McDonald MM, Morse A, et al. Intermittent PTH (1-34) does not increase union rates in open rat femoral fractures and exhibits attenuated anabolic effects compared to closed fractures. *Bone* 2010; 46: 852-9. [\[CrossRef\]](#)
24. Schwarzkopf R, Dang P, Luu M, Mozaffar T, Gupta R. Topical tranexamic Acid does not affect electrophysiologic or neurovascular sciatic nerve markers in an animal model. *Clin Orthop Relat Res* 2015; 473: 1074-82. [\[CrossRef\]](#)
25. Huo MH, Troiano NW, Pelker RR, Gundberg CM, Friedlaender GE. The influence of ibuprofen on fracture repair: biomechanical, biochemical, histologic, and histomorphometric parameters in rats. *J Orthop Res* 1991; 9: 383-90. [\[CrossRef\]](#)
26. Lack WD, Crist BD, Seymour RB, Harvin W, Karunakar MA; TXA Study Group. Effect of tranexamic acid on transfusion: A randomized clinical trial in acetabular fracture surgery. *J Orthop Trauma* 2017; 31: 526-30. [\[CrossRef\]](#)
27. Lei J, Zhang B, Cong Y, et al. Tranexamic acid reduces hidden blood loss in the treatment of intertrochanteric fractures with PFNA: A single-center randomized controlled trial. *J Orthop Surg Res* 2017; 12: 124. doi: 10.1186/s13018-017-0625-9. [\[CrossRef\]](#)
28. Watts CD, Houdek MT, Sems SA, Cross WW, Pagnano MW. Tranexamic acid safely reduced blood loss in hemi-and total hip arthroplasty for acute femoral neck fracture: a randomized clinical trial. *J Orthop Trauma* 2017; 31: 345-51. [\[CrossRef\]](#)
29. Kashyap S, Mahajan S, Lal M. Effects of topical tranexamic acid during open reduction and internal fixation of acetabular fractures: A retrospective study. *Acta Orthop Traumatol Turc* 2019; 53: 175-9. [\[CrossRef\]](#)
30. Błanié A, Bellamy L, Rhayem Y, et al. Duration of postoperative fibrinolysis after total hip or knee replacement: a laboratory follow-up study. *Thromb Res* 2013; 131: e6-e11. [\[CrossRef\]](#)
31. Mountziaris PM, Mikos AG. Modulation of the inflammatory response for enhanced bone tissue regeneration. *Tissue Eng Part B Rev* 2008; 14: 179-86 [\[CrossRef\]](#)
32. Xing Z, Lu C, Hu D, Miçlau T, Marcucio RS. Rejuvenation of the inflammatory system stimulates fracture repair in aged mice. *J Orthop Res* 2010; 28: 1000-6. [\[CrossRef\]](#)
33. Benoni G, Lethagen S, Fredin H. The effect of tranexamic acid on local and plasma fibrinolysis during total knee arthroplasty. *Thromb Res* 1997; 85: 195-206. [\[CrossRef\]](#)
34. Carter G, Goss A, Lloyd J, Tocchetti R. Tranexamic acid mouthwash versus autologous fibrin glue in patients taking warfarin undergoing dental extractions: a randomized prospective clinical study. *J Oral Maxillofac Surg* 2003; 61: 1432-5. [\[CrossRef\]](#)
35. Soffer E, Ouhayoun JP, Anagnostou F. Fibrin sealants and platelet preparations in bone and periodontal healing. *Oral Surg Oral Med Oral Pathol Oral Radiol Endod* 2003; 95: 521-8. [\[CrossRef\]](#)