

# Preventive approaches for intrafamilial *H. pylori* transmission as an efficient target strategy to decrease the prevalence of the infection in developing countries

*Gelişmekte olan ülkelerde Helicobacter pylori enfeksiyonunun prevalansını azaltmada aile içi bulaşın önleme yaklaşımları*

Dear Editor,

It is known that the acquisition of primary *Helicobacter pylori* (*H.pylori*) infection occurs predominantly in childhood, and it is lifelong if untreated. It has been previously proposed that treating infected children could reduce the transmission of the infection and prevent or reduce the incidence of gastric cancer in adults. The Maastricht III consensus report and other recommendations aim to protect children from unnecessary diagnostic tests and antibiotic treatments (1-3). However, there is a growing need for strategies to improve prevention of *H. pylori* infection especially in developing countries including Turkey. In this regard, new recommendations should be developed for the prevention and management of *H. pylori* infection in children.

*H. pylori* infection is acquired primarily in childhood, between the ages 1 to 5. The primary route of *H. pylori* transmission still remains unknown, however there is strong evidence to support person-to-person transmission, such as the detection of *H. pylori* and its DNA in saliva, dental plaque, and in feces. Several family studies have shown *H. pylori* infection clustering within families (4), especially the transmission from an infected mother. It is suggested that infected mothers are the main reservoirs of *H. pylori* infection, and transmission occurs via their gastric secretions and saliva. While infected mothers and elderly siblings are the

main risk factors of intrafamilial spread of the infection, younger siblings are considered to be responsible for the reinfection of *H. pylori* in adolescence (5).

The prevention of *H. pylori* transmission from elder family members to children needs to be the first priority. All family members, especially mothers need to be educated on probable *H. pylori* transmission routes and better hygiene practices. High-risk behaviors such as kissing, feeding with pre-masticated food, cleaning pacifiers by mouth, checking the temperature of the milk bottle by mouth, sharing spoons or chopsticks, and sharing a bed need to be avoided in order to prevent the contact of infants with the infected saliva and gastric secretions of the mother. A second priority needs to be the prevention of reinfection, and treatment by routinely screening other family members for *H. pylori* infection, during or after the treatment of the child. When internalized as a routine practice, this strategy may help to eradicate *H. pylori* infection aside from vaccine studies.

In conclusion, especially in developing countries, new recommendations are needed not only for the better treatment of infected children and their family members and for improving family hygiene practices, but also for preventive strategies of the transmission of this bacteria.

## REFERENCES

1. Malfertheiner P, Megraud F, O'Morain C, et al. Current concepts in the management of *Helicobacter pylori* infection: the Maastricht III Consensus Report. *Gut* 2007;56:772-81.
2. Koletzko S, Jones NL, Goodman KJ, et al. Evidence-based guidelines from ESPGHAN and NASPGHAN for *Helicobacter pylori* infection in children. *J Pediatr Gastroenterol Nutr* 2011;53:230-43.

**Address for correspondence:** Yeşim ÖZTÜRK

Dokuz Eylül University School of Medicine, Department of Pediatrics, Izmir, Turkey

Phone: + 90 232 412 36 21

E-mail: yesimzaferozturk@gmail.com

**Manuscript received:** 23.01.2012 **Accepted:** 11.06.2012

doi: 10.4318/tjg.2013.0548

3. Drumm B, Perez-Perez GI, Blaser MJ, Sherman PM. Intra-familial clustering of *Helicobacter pylori* infection. N Engl J Med 1990;322:359-63.
4. Rothenbacher D, Winkler M, Gonser T, et al. Role of infected parents in transmission of *Helicobacter pylori* to their children. Pediatr Infect Dis J 2002;21:674-9.
5. Fialho AM, Braga AB, Braga Neto MB, et al. Younger siblings play a major role in *Helicobacter pylori* transmission among children from a low-income community in the Northeast of Brazil. Helicobacter 2010;15:491-6.

Yeşim ÖZTÜRK<sup>1</sup>, Hasan ÖZEN<sup>2</sup>,  
Ender PEHLİVANOĞLU<sup>3</sup>

Department of <sup>1</sup>Pediatrics, Dokuz Eylül University School of Medicine, İzmir

Department of <sup>2</sup>Pediatrics, Hacettepe University School of Medicine, Ankara, Turkey

Department of <sup>3</sup>Pediatrics, Marmara University School of Medicine, Istanbul, Turkey

## Small bowel volvulus secondary to post appendectomy adhesion band

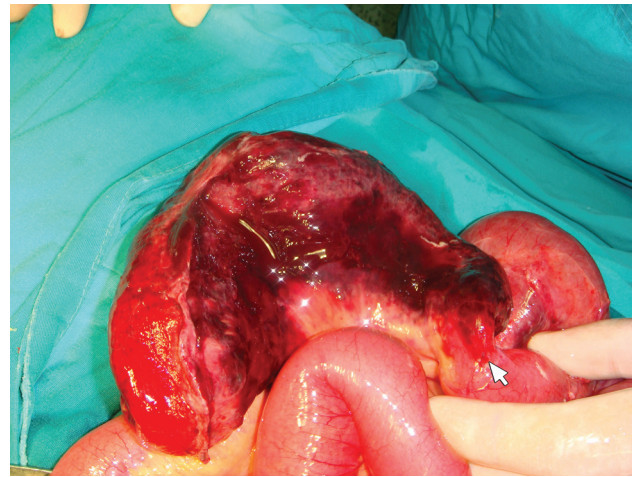
*Apendektomi sonrası gelişen adezyon bandına bağlı incebarsak volvulusu*

*To the Editor,*

A 66-year-old woman was admitted to the emergency department with a complaint of severe abdominal pain, nausea, and vomiting. She had a history of previous appendectomy 36 years ago. The abdominal examination revealed moderate distension and rebound tenderness. The white cell count revealed a leukocytosis (35.500/mm<sup>3</sup>). Abdominal computerized tomography (CT) revealed segmental intestinal dilatation. At laparotomy, a twisted jejunoileal segment 50 cm in length was twisted around a tight adhesion band starting from the appendoceleal peritoneum to the small bowel mesentery. Segmental jejunoileal resection and primary end-to-end anastomosis was performed. The patient was discharged uneventfully on the ninth day of admission.

A 48-year-old woman was admitted to the emergency department with severe abdominal colicky pain. She had a history of previous appendectomy due to perforated appendicitis 18 years ago. Abdominal examination revealed extreme distention and rebound tenderness. She had a leukocytosis of 18.400/mm<sup>3</sup>. Abdominal CT showed diffuse intra-

abdominal fluid accumulation. Laparotomy was performed and an approximately 30 cm ileal volvulus was discovered around an adhesive band beginning from underneath the appendectomy incision to the small bowel mesenteric root (Figure 1).



**Figure 1.** Laparotomy showed a twisted small bowel segment and compressed by adhesive band.

**Address for correspondence:** Zülfikar KARABULUT  
Department of General Surgery, Başkent University Hospital,  
Antalya, Turkey  
E-mail: drkarabulut33@yahoo.com

**Manuscript received:** 27.12.2011 **Accepted:** 13.01.2012

doi: 10.4318/tjg.2013.0486