



Occlusal plane rotation and orthodontic decompensation: influence on the outcome of surgical correction of class III malocclusion

Elif Dilara Seker¹ · Ezgi Sunal Akturk¹ · Hanife Nuray Yilmaz² · Nazan Kucukkeles¹

Received: 23 August 2021 / Accepted: 16 January 2022
© Springer Medizin Verlag GmbH, ein Teil von Springer Nature 2022

Abstract

Purpose The aim of this retrospective multicenter study is to evaluate the influence of surgical manipulation of the upper occlusal plane (UOP) and orthodontic decompensation on the outcome of class III orthognathic surgery.

Methods Incisor inclinations, occlusal plane inclination as well as skeletal and soft tissue changes were assessed in lateral cephalograms of 85 class III patients who had previously undergone orthognathic surgery. Fourteen linear and eight angular measurements were performed on each radiograph at the beginning of treatment (T0), before surgery (T1) and at the end of treatment (T2) using imaging software. After measurement of variables, Mann–Whitney U-test, repeated-measures analysis of variance (ANOVA) with Bonferroni multiple comparison test, and Spearman’s correlation analysis were performed.

Results A statistically significant improvement was observed in both sagittal skeletal and soft tissue measurements ($p < 0.05$). Surgical change in UOP was significantly correlated with changes in overbite, upper lip strain and soft tissue B-point change in the sagittal direction ($p < 0.05$). Overjet change was significantly correlated with changes in the soft tissue and all sagittal skeletal parameters except for SNA. Changes in the incisor inclinations was significantly correlated with changes in the sagittal skeletal parameters and lower facial height. Significant differences were also observed between the groups with induced clockwise or counterclockwise rotation of the mandible in terms of IMPA (long axis of LI to mandibular plane), overbite, upper lip strain and position of soft tissue B-point ($p < 0.05$).

Conclusion Sufficient dental decompensation is crucial for controlling the sagittal as well as the vertical relationship during surgery. Counterclockwise rotation provides an increase in sagittal projection of the mandibular body at the soft tissue B-point.

Keywords Preoperative decompensation · Occlusal plane · Skeletal class III malocclusion · Orthognathic surgery · Incisor inclination

Rotation der Okklusionsebene und kieferorthopädische Dekompensation: Einfluss auf das Ergebnis der chirurgischen Korrektur einer Klasse-III-Malokklusion

Zusammenfassung

Zielsetzung Ziel dieser retrospektiven multizentrischen Studie ist es, den Einfluss chirurgischer Interventionen an der oberen Okklusionsebene (UOP) und kieferorthopädischer Dekompensationen auf das Ergebnis einer kieferorthopädischen Klasse-III-Korrekturoperation zu untersuchen.

Data Availability Statement The data that support the findings of this study are available from the corresponding author upon reasonable request.

✉ Assistant Professor Dr. Elif Dilara Seker
dilaraarsln@hotmail.com, elseker@bezmialem.edu.tr

Assistant Professor Ezgi Sunal Akturk
sunalezgi@gmail.com

Associate Professor Hanife Nuray Yilmaz
hanarikan@yahoo.com

Professor Nazan Kucukkeles
nkucukkeles@yahoo.com

¹ Department of Orthodontics, Faculty of Dentistry, Bezmialem Vakif University, Istanbul, Turkey

² Department of Orthodontics, Faculty of Dentistry, Marmara University, Istanbul, Turkey

Methoden Die Neigung der Schneidezähne, die Neigung der Okklusionsebene sowie Veränderungen des Skeletts und des Weichgewebes wurden bei 85 Klasse-III-Patienten, die sich einem orthognathen Eingriff unterzogen, anhand von seitlichen Kephalogrammen bewertet. Auf jeder Röntgenaufnahme wurden zu Beginn der Behandlung (T0), vor der Operation (T1) und am Ende der Behandlung (T2) mit Hilfe der Bildgebungssoftware 14 lineare und 8 Winkelmessungen durchgeführt. Nach Messung der Variablen wurden ein Mann-Whitney-U-Test, eine Varianzanalyse mit wiederholten Messungen (ANOVA) und Bonferroni-Mehrfachvergleichstest sowie eine Spearman-Korrelationsanalyse durchgeführt.

Ergebnisse Sowohl bei den sagittalen Skelett- als auch bei den Weichgewebemessungen wurde eine statistisch signifikante Verbesserung festgestellt ($p < 0,05$). Die chirurgische Veränderung des UOP korrelierte signifikant mit Veränderungen von Overbite, Oberlippendehnung und Weichgewebe-B-Punkt. Die Veränderung des Overjet korrelierte signifikant mit Veränderungen des Weichgewebes und allen sagittalen skelettalen Parametern (Ausnahme: SNA). Die Veränderungen der Schneidezahnneigungen korrelierten signifikant mit den Veränderungen der sagittalen skelettalen Parameter und der unteren Gesichtshöhe. Signifikante Unterschiede wurden auch zwischen den Gruppen mit induzierter Rotation gegen den Uhrzeigersinn oder im Uhrzeigersinn des Unterkiefers in Bezug auf IMPA (lange Achse des LI zur Unterkieferebene), Overbite, Oberlippendehnung und Position des B-Punkts des Weichgewebes beobachtet ($p < 0,05$).

Schlussfolgerung Eine ausreichende dentale Dekompensation ist entscheidend für die Kontrolle der sagittalen und vertikalen Beziehung während der Operation. Die Rotation gegen den Uhrzeigersinn führt zu einer Zunahme der sagittalen Projektion des Unterkieferkörpers am B-Punkt des Weichgewebes.

Schlüsselwörter Präoperative Dekompensation · Okklusionsebene · Skelettale Klasse-III-Malokklusion · Kieferorthopädische Chirurgie · Neigung der Schneidezähne

Introduction

Skeletal class III malocclusion occurs due to a protrusive mandible, a retrusive maxilla or combinations of these components [1]. Patients with skeletal class III malocclusion generally have dentoalveolar compensations (proclination of maxillary incisors and retroclination of mandibular incisors) to ensure function and mask the underlying skeletal problems [2, 3]. A combined orthodontic/orthognathic surgery treatment is an effective approach for these patients with skeletal class III malocclusion [4]. Appropriate orthodontic treatment planning, realistic prediction of soft tissue response to skeletal changes and adequate surgical anteroposterior movements of the jaws are the cornerstones of this treatment modality [5]. The success of the orthognathic surgery approach relies not only on the correction of skeletal and dental relationships but also on improvement in facial esthetics and balance [6, 7]. Preoperative incisor decompensation, especially for class III surgery patients is one of the most important factors influencing the success of orthognathic surgery. When dental decompensation is incomplete during the presurgical period, surgical movements of the maxilla and the mandible are limited by the incisors [8–10].

Surgical manipulation of the upper occlusal plane (UOP) is another critical factor to be considered for better esthetic outcomes. When the UOP angle is surgically altered according to the vertical facial morphology of the patient, the lower jaw rotates following the upper jaw towards the new occlusal plane [11]. Controlling these factors during the preoperative and the intraoperative periods may provide better

esthetic outcomes. However, although their potential effects on facial appearance are certain, the minimum or maximum thresholds for these parameters that would lead to clinically significant changes in soft tissues remain unclear in the literature.

Currently available data in the relevant literature do not allow precise prediction of soft tissue response to surgical alteration of the occlusal plane in class III cases.

The aim of this study was to determine whether there is a correlation between specific surgical alteration of the occlusal plane and postoperative hard/soft tissue changes. This study also aimed to investigate in further detail the impact of preoperative dental decompensation on treatment outcomes in class III surgery patients. The null hypothesis was that there is no correlation between surgical alteration of the occlusal plane angle and facial esthetics in class III orthognathic surgery patients. We also tested the hypothesis that there is an impact of the amount of dental decompensation on surgical outcomes.

Materials and methods

This retrospective multicenter study was approved by the Local Ethics Committee of Bezmialem Vakif University (01/01, 19.01.2021) and written informed consent was received from all participating patients and their parents or legal guardians for patients under 18. The radiographic records of 112 patients who had been treated from 2013 to 2019 were selected randomly from the Orthodontics De-

Table 1 Patient demographics**Tab. 1** Studienkollektiv, demographische Angaben

<i>Gender</i>	Male	28 (32.9%)
	Female	57 (67.1%)
<i>Age (years ± SD)</i>	–	21.31 ± 3.4
<i>Orthodontic preparation</i>	With extraction	31 (36.5%)
	No extraction	54 (63.5%)
<i>Treatment time (months ± SD)</i>	Preoperative	26.45 ± 8.21
	Postoperative	9.26 ± 4.74
	Total	35.71 ± 9.14

SD standard deviation

partments of two universities Bezmialem Vakif University and Marmara University in Istanbul, Turkey.

A power analysis revealed that a sample size of 56 individuals would provide more than 95% power to detect significant differences by using the values of means and standard deviations of U1-PP. After applying the inclusion and exclusion criteria, 85 patients with class III malocclusion (28 male and 57 female patients) who were treated with combined orthodontic/orthognathic surgery treatment were included in this study. The mean age of the patients was 21.31 ± 3.4 years. The average amount of sagittal and vertical movement of the maxilla were 4.6 ± 2.02 and -2.4 ± 1.7 mm at the level of the mesiobuccal cusp tip of the maxillary first molars, respectively. The average amount of sagittal movement of the mandible at the level of the first molars was -3.7 ± 1.99 mm. The descriptive data of the included patients are presented in Table 1.

The inclusion criteria were (1) patients with class III malocclusion who had undergone combined orthodontic treatment and two-jaw orthognathic surgery (with maxillary impaction/advancement and mandibular setback), (2) patients who wore fixed conventional brackets (0.018-inch slot, Roth prescription, Mini Master Series, American Orthodontics, Sheboygan, WI, USA), (3) available lateral cephalometric records, and (4) good-quality radiographic records before start of orthodontic treatment (T0), approximately 2 weeks before orthognathic surgery (T1) and at the end of orthodontic treatment (T2).

The exclusion criteria were (1) patients treated with a surgery-first orthognathic approach, (2) patients who had genioplasty, (3) patients with a craniofacial syndrome or cleft lip and palate, and (4) any history of trauma.

The patients were divided into two groups: (1) the clockwise group (CW—change of the UOP plane angle $\geq 0^\circ$, $n = 33$) and (2) the counterclockwise group (CCW—change of the UOP plane angle $< 0^\circ$, $n = 52$) based on the surgical alteration of the occlusal plane inclination [12].

Cephalometric evaluation

Pretreatment (T0), preoperative (T1), and posttreatment (T2) lateral cephalometric radiographs were collected for each patient. All cephalograms were digitized and traced by the same operator (E.D.S) using the Dolphin Imaging Program (Version 10.0, Dolphin Imaging & Management Solutions, Chatsworth, CA, USA). A total of 255 lateral cephalometric radiographs of the 85 patients were analyzed. We used the method of Arnett et al. [12] with modifications reported in the studies of Bacetti et al. [13] and Franchi et al. [14]. The measurements were performed with a reference vertical line (VL) that is perpendicular to the Frankfurt plane. This plane is a modification of the true vertical line (TVL) of Arnett et al. [12]. The skeletal, dental, and soft-tissue measurements are presented in Fig. 1.

Statistical analysis

Twenty-one radiographs were randomly selected after 2 weeks and re-analyzed to evaluate the intraexaminer agreement. Bland–Altman plots and the intraclass correlation coefficient (ICC) were used to evaluate intraobserver reliability [15]. Bland–Altman analysis evinced high levels of agreement between the two cephalometric measurements. The average intraobserver ICC was 0.988 (0.970–0.992). The random error of the method was calculated by using the formula described by Dahlberg [16]. The average random error observed was 0.51° , with a range from 0.33 to 0.82° for the SNA value, which may be considered to be without clinical relevance. No systematic error was found.

The data were analyzed with a statistical software package program (SPSS version 12.0; SPSS Inc., Chicago, IL, USA). The data were tested for normal distribution using the Shapiro–Wilk test. Repeated-measures analysis of variance (ANOVA) was used for the comparison of the changes of the cephalometric variables between different time points. A post hoc test with Bonferroni correction was performed to further describe the differences between the treatment stages. Spearman's correlation test was used to determine whether there was a relationship between various cephalometric parameters. The groups (CW and CCW) were statistically compared using the Mann–Whitney U test. The level of statistical significance was set at $p < 0.05$.

Results

Comparison of the cephalometric variables

At T1, the patients presented with skeletal sagittal maxillary deficiency, mandibular excess, and negative ANB and

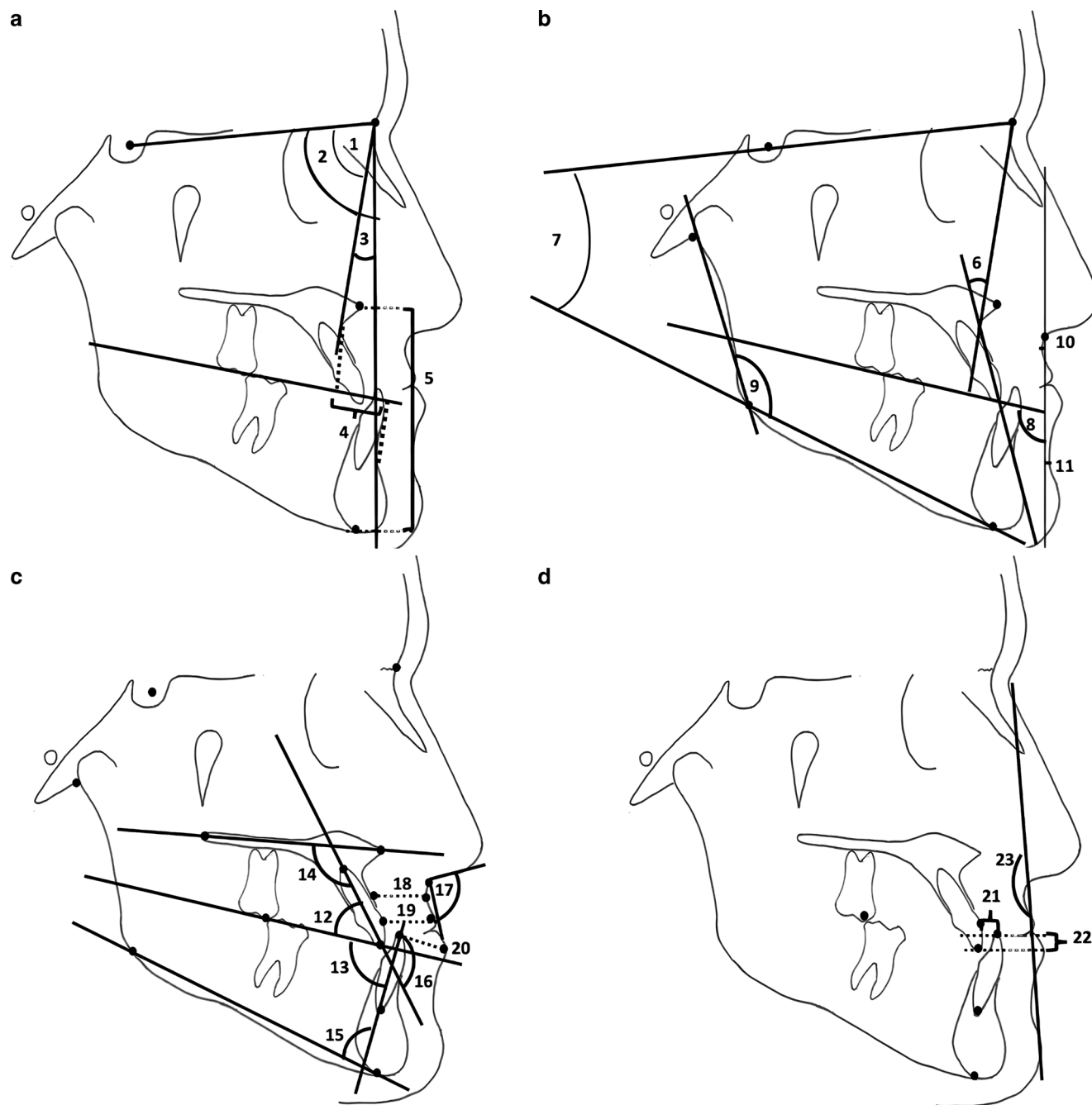


Fig. 1 Cephalometric variables. **a** 1. SNA, 2. SNB, 3. ANB, 4. Wits appraisal, 5. lower facial height (ANS-Gn); **b** 6. convexity angle (N-A-Pog), 7. SN-GoMe, 8. upper occlusal plane angle to vertical line (UOP-VL), 9. gonial angle (Ar-Go-Me), 10. perpendicular distance from the soft tissue A-point to the VL (soft tissue A-point), 11. perpendicular distance from the soft tissue B-point to the VL (soft tissue B-point); **c** 12. long axis of U1 to UOP (U1-UOP), 13. long axis of L1 to LOP (L1-LOP), 14. long axis of U1 to palatal plane (U1-PP), 15. long axis of L1 to mandibular plane (IMPA), 16. interincisal angle (U1-L1), 17. nasolabial angle, 18. basic upper lip thickness, 19. upper lip thickness (lip strain = 18–19), 20. lower lip thickness; **d** 21. overjet, 22. overbite, 23. soft tissue profile

Abb. 1 Kephalmetrische Variablen. **a** 1. SNA, 2. SNB, 3. ANB, 4. Wits-Appraisal, 5. untere Gesichtshöhe (ANS-Gn); **b** 6. Konvexitätswinkel (N-A-Pog), 7. SN-GoMe, 8. Winkel der oberen Okklusionsebene zur vertikalen Linie (UOP-VL), 9. Gonialwinkel (Ar-Go-Me), 10. senkrechter Abstand zwischen dem A-Punkt des Weichgewebes und der VL (A-Punkt des Weichgewebes), 11. senkrechter Abstand zwischen dem B-Punkt des Weichgewebes und der VL (B-Punkt des Weichgewebes); **c** 12. lange Achse von U1 zu UOP (U1-UOP), 13. lange Achse von L1 zu LOP (L1-LOP), 14. lange Achse von U1 zu palatinaler Ebene (U1-PP), 15. lange Achse von L1 zu mandibulärer Ebene (IMPA), 16. Interinzisalwinkel (U1-L1), 17. Nasolabialwinkel, 18. grundlegende Oberlippendicke, 19. obere Lippenstärke (Lippendehnung = 18–19), 20. untere Lippenstärke; **d** 21. Overjet, 22. Overbite, 23. Weichgewebeprofil

Table 2 Comparison of cephalometric variables between T0, T1, and T2
Tab. 2 Vergleich der kcephalometrischen Variablen zwischen T0, T1 und T2

	T0		T1		T2		p-value	p-value (post hoc)			
	Mean	SD	Mean	SD	Mean	SD		T0-T1	T0-T2	T1-T2	
<i>Sagittal</i>											
SNA, °	78.4	3.6	78.3	3.5	82.1	3.7	<0.001	NS	<0.001	<0.001	
SNB, °	82.4	4.3	82.2	4.2	80.1	3.8	<0.001	NS	<0.001	<0.001	
ANB, °	-3.9	2.8	-3.8	2.8	2	2.2	<0.001	NS	<0.001	<0.001	
Wits appraisal, mm	-11.5	4.5	-10.4	5.1	-2.8	2.4	<0.001	NS	<0.001	<0.001	
Convexity angle, °	-9.2	6.7	-9.2	6.8	1.2	5.4	<0.001	NS	<0.001	<0.001	
<i>Vertical</i>											
SN-GoMe, °	38.5	6.1	38.7	6	37.7	5.6	0.008	NS	NS	0.01	
Gonial angle, °	132	8.1	131.6	12.9	131.3	9.4	NS	-	-	-	
Lower facial height, mm	70.3	7.7	71.2	8	69.7	6.63	<0.001	0.04	NS	<0.001	
Upper occlusal plane angle, °	97.4	4.6	98.8	4.5	97.2	4	0.01	0.001	NS	0.04	
<i>Dental</i>											
U1-PP, °	116.6	7.5	114.6	7.2	115.1	7.3	NS	-	-	-	
U1-UOP, °	55.5	6.9	55.1	5.6	54.9	5.1	NS	-	-	-	
IMPA, °	79.4	8.1	87.4	9.8	85.3	7.4	<0.001	<0.001	<0.001	NS	
L1-LOP, °	78.5	6.8	71.6	5.7	72.6	5.8	<0.001	<0.001	0.007	0.01	
Interincisal angle, °	134.4	11	128.4	9.5	130.9	8.2	<0.001	0.006	<0.001	0.008	
Overjet, mm	-2.7	2.1	-6	3.2	2.7	0.9	<0.001	<0.001	<0.001	<0.001	
Overbite, mm	-0.3	3.2	0.6	2.5	1.7	0.9	0.006	0.001	<0.001	<0.001	
<i>Soft tissue</i>											
Nasolabial angle, °	102.2	17.7	101.5	12.9	100.8	10.6	NS	-	-	-	
Upper lip strain, mm	0.7	1.7	0.1	1.8	0.8	1.5	0.002	NS	0.03	0.002	
Lower lip thickness, mm	13.6	2.3	13.8	2.9	12.8	1.9	0.003	NS	0.006	0.01	
Soft tissue A, mm	-1.3	1.4	-1.5	1.7	-0.2	1.5	<0.001	NS	<0.001	<0.001	
Soft tissue B, mm	-0.8	4.4	-0.9	4.2	-6	4.6	<0.001	NS	<0.001	<0.001	
Soft tissue profile, °	174.2	7.1	174.6	7	167.8	5.8	<0.001	NS	<0.001	<0.001	
$\Delta T1-T0$ (1)	Mean	SD	$\Delta T2-T1$ (2)	Mean	SD	$\Delta T2-T0$ (3)	Mean	SD	p-value (post hoc)		
									1-2	1-3	2-3

Table 2 (Continued)
Tab. 2 (Fortsetzung)

<i>Sagittal</i>										
SNA, °	-0.01	1.3	3.7	1.9	3.7	2	<0.001	<0.001	<0.001	NS
SNB, °	-0.2	1.5	-2	1.9	-2.3	2.3	<0.001	<0.001	<0.001	NS
ANB, °	0.1	1.2	5.8	2.2	5.9	2.3	<0.001	<0.001	<0.001	NS
Wits appraisal, mm	1.1	5.4	7.5	5.3	8.6	4.1	<0.001	<0.001	<0.001	NS
Convexity angle, °	-0.02	2.8	10.5	5	10.4	5.2	<0.001	<0.001	<0.001	NS
<i>Vertical</i>										
SN-GoMe, °	1.1	2.4	-0.9	3	-0.8	3.1	0.03	0.04	NS	NS
Gonial angle, °	-0.5	9.9	-0.3	11.1	-0.9	7	NS	-	-	-
Lower facial height, mm	0.8	3.2	-1.5	3.5	-0.6	4	<0.001	<0.001	0.01	NS
Upper occlusal plane angle, °	1.3	3.4	-1.5	5.9	-0.2	6.3	0.002	0.001	NS	NS
<i>Dental</i>										
U1-PP, °	-2	8.4	0.5	5.3	-1.5	8.1	NS	-	-	-
U1-UOP, °	-0.4	6.6	-0.2	4.4	-0.6	6.6	NS	-	-	-
IMPA, °	7.9	9.5	-2	7.8	5.9	6.8	<0.001	<0.001	NS	<0.001
L1-LOP, °	-6.8	6	0.9	4.2	-5.9	6	<0.001	<0.001	NS	<0.001
Interincisal angle, °	5.9	10.3	2.4	7.8	-3.5	10.2	<0.001	<0.001	NS	<0.001
Overjet, mm	-3.2	3	8.7	3.2	5.5	2.2	<0.001	<0.001	<0.001	<0.001
Overbite, mm	1	2.4	1.1	2.3	2.1	3.2	0.02	NS	0.02	0.04
<i>Soft tissue</i>										
Nasolabial angle, °	-0.6	14.6	-0.7	10.6	-1.3	15.6	NS	-	-	-
Upper lip strain, mm	-0.6	1.9	0.7	1.8	0.1	1.9	<0.001	<0.001	NS	NS
Lower lip thickness, mm	0.1	2.3	-0.9	3	-0.8	2.3	0.01	0.02	NS	NS
Soft tissue A, mm	-0.1	1.3	2.1	1.8	1.1	1.7	<0.001	<0.001	<0.001	NS
Soft tissue B, mm	-0.07	2.6	-5.2	4.6	-5.2	4.4	<0.001	<0.001	<0.001	NS
Soft tissue profile, °	0.4	3.1	-6.7	4.6	-6.3	4.6	<0.001	<0.001	<0.001	NS

Repeated-measures analysis of variance (ANOVA) and Bonferroni post hoc test were performed
T0 at the start of the orthodontics treatment, *T1* approximately 2 weeks before the orthognathic surgery, *T2* at the end of the orthodontic treatment, $\Delta T1-T0$ the average value of the difference between *T0* and *T1*, $\Delta T2-T1$ the average value of the difference between *T1* and *T2*, $\Delta T2-T0$ the average value of the difference between *T0* and *T2*, *NS* nonsignificant, *SD* standard deviation

Wits appraisal values. The skeletal, dental and soft tissue cephalometric parameters measured at T0, T1, and T2 are presented in Table 2. Comparison according to the treatment stages showed a statistically significant improvement in both the sagittal skeletal and soft tissue measurements ($p < 0.05$). While a statistically significant increase for the vertical skeletal measurements and the angle of the upper occlusal plane was observed after orthodontic decompensation (T1), a statistically significant decrease for these parameters was found after orthognathic surgery (T2). However, no statistically significant differences were observed for the nasolabial and gonial angles ($p > 0.05$). Comparison of the dental measurements indicated a significant decompensation for the lower incisors from T0 to T1. However, the changes in inclination of the upper incisors were found to be insignificant between the different time points ($p > 0.05$).

The amount of change in the cephalometric parameters after orthodontic decompensation and after orthognathic surgery are presented in Table 2. Significant changes were recorded for the cephalometric parameters measured for $\Delta T1-T0$, $\Delta T2-T0$, and $\Delta T2-T1$ ($p < 0.05$).

Correlation between different cephalometric variables

A significant correlation was observed between the change in UOP to VL and the changes in overbite, upper lip strain and soft tissue B-point from T1 to T2 ($p < 0.05$, Table 3). A significant negative correlation was observed between the change in overjet and the changes in ANB, Wits appraisal, and convexity angle, while a significant positive correlation was observed between the changes in overjet and the changes in SNB, soft tissue B-point, and soft tissue profile from T1 to T2 ($p < 0.05$, Table 3). On the other hand, no significant correlation was found between the change in overbite values and the changes in the cephalometric variables after surgery ($p > 0.05$, Table 3).

Another significant correlation was found between the change in U1-UOP after orthodontic decompensation (T0 to T1) and the changes in lower facial height and the soft tissue profile from T1 to T2, and also between the change in U1-PP after orthodontic decompensation (T0 to T1) and the changes in Wits appraisal and lower facial height from T1 to T2 ($p < 0.05$, Table 4).

Finally, a significant correlation was found between the change in both L1-UOP and IMPA after orthodontic decompensation (T0 to T1) and the changes in SNA, ANB, con-

Table 3 Correlation between changes in occlusal plane angle, overjet, and overbite and vertical and sagittal variables

Tab. 3 Korrelation zwischen Veränderungen des Winkels der Okklusionsebene, Overjet und Overbite und vertikalen bzw. sagittalen Variablen

	$\Delta UOP/VL (\Delta T2-T1)$		$\Delta Overjet (\Delta T1-T0)$		$\Delta Overbite (\Delta T1-T0)$	
	<i>r</i>	<i>p</i> -Value	<i>r</i>	<i>p</i> -Value	<i>r</i>	<i>p</i> -Value
<i>ΔSagittal (ΔT2-T1)</i>						
SNA, °	0.066	0.54	-0.169	0.12	0.088	0.42
SNB, °	-0.123	0.26	0.328	0.002	-0.052	0.63
ANB, °	0.192	0.07	-0.419	<0.001	0.109	0.32
Wits appraisal, mm	0.076	0.48	-0.501	<0.001	0.211	0.052
Convexity angle, °	0.081	0.46	-0.380	<0.001	0.123	0.26
<i>ΔVertical (ΔT2-T1)</i>						
SN-GoMe, °	0.091	0.4	-0.092	0.40	0.028	0.79
Gonial angle, °	0.021	0.85	-0.021	0.84	0.077	0.48
Lower facial height, mm	0.052	0.63	0.208	0.056	-0.142	0.19
<i>ΔSoft tissue (ΔT2-T1)</i>						
Nasolabial angle, °	0.083	0.44	-0.021	0.84	-0.111	0.31
Upper lip strain, mm	0.231	0.03	-0.138	0.2	0.016	0.88
Lower lip thickness, mm	0.081	0.46	0.211	0.053	0.119	0.28
Soft tissue A, mm	-0.032	0.77	0.033	0.76	0.000	0.99
Soft tissue B, mm	-0.140	0.04	0.298	0.006	-0.059	0.59
Soft tissue profile, °	-0.032	0.77	0.299	0.006	-0.131	0.23
<i>ΔDental (ΔT2-T1)</i>						
Overjet, mm	0.097	0.37	-	-	-	-
Overbite, mm	0.227	0.03	-	-	-	-

Spearman correlation test was used

T1 approximately 2 weeks before orthognathic surgery, T2 at the end of orthodontic treatment, *r* correlation coefficient, $\Delta T1-T0$ the average value of the difference between T0 and T1, $\Delta T2-T1$ the average value of the difference between T1 and T2, bold font indicates statistical significance

vexity angle and lower facial height from T1 to T2 ($p < 0.05$, Table 4).

Comparison of the cephalometric variables between the CW and CCW rotation groups

There were statistically significant differences between the clockwise (CW) and counterclockwise (CCW) groups for the changes in IMPA, overbite, upper lip strain, and soft tissue B-point from T1 to T2. The change for these variables from T1 to T2 for the CW group was significantly higher in comparison to the CCW group ($p < 0.05$, Table 5).

Discussion

Bimaxillary orthognathic surgery, in which CW or CCW rotations of the UOP are included in treatment planning, is one of the ways to obtain esthetic and functional treatment outcomes [17]. Another major factor in the success of treatment is the amount of orthodontic decompensation because preoperative dental decompensation affects the amount and type of surgical change [18]. Therefore, this study focused on the effects of specific surgical alterations of the upper occlusal plane and preoperative dental decompensations on the postoperative hard/soft tissue balance in class III surgery patients.

Our samples comprised class III surgery patients who were randomly collected from two different centers. To reduce selection bias, all patients who fulfilled the inclusion criteria were included. The aim of the multicenter design was to include a large number of randomly selected patients in a reasonable time period and to eliminate single-center methodological bias.

Typical orthodontic decompensation treatment aims to increase the severity of the class III dental malocclusion with retroclination of the upper anterior teeth and proclination of the lower anterior teeth to a more normal axial inclination [19, 20]. In this study, the amounts of change in inclination for the maxillary and mandibular incisors were around 2 and 7°, respectively. This finding was in accordance with that of Ahn and Baek [21] for the lower incisors and with that of Kim and Baek [18] for the upper incisors (for the nonextraction group). In many cases, the incisor decompensation in the sagittal dimension was insufficient as was also previously reported by Quast et al. [10]. This finding could be explained by the fact that most of our subjects were treated without premolar extraction.

Improvements of ANB, Wits appraisal, and soft tissues were obtained by maxillary advancement and mandibular setback. In this study, lower lip thickness decreased as previously reported by Altug-Atac et al. [22]. While the significant decrease in lower lip thickness was attributable to the correction of the incisors' position and overjet changes [19], a significant increase in upper lip strain could be ex-

Table 4 Correlation between changes in incisor inclination and vertical and sagittal variables

Tab. 4 Korrelation zwischen Veränderungen der Schneidezahnneigung und vertikalen bzw. sagittalen Variablen

	$\Delta U1-UOP (\Delta T1-T0)$		$\Delta U1-PP (\Delta T1-T0)$		$\Delta L1-LOP (\Delta T1-T0)$		$\Delta IMPA (\Delta T1-T0)$	
	<i>r</i>	<i>p</i> -Value	<i>r</i>	<i>p</i> -Value	<i>r</i>	<i>p</i> -Value	<i>r</i>	<i>p</i> -Value
<i>ΔSagittal (ΔT2-T1)</i>								
SNA, °	0.125	0.25	0.048	0.66	-0.217	0.04	0.254	0.01
SNB, °	-0.064	0.55	0.023	0.83	0.127	0.24	-0.090	0.4
ANB, °	0.157	0.15	0.010	0.93	-0.222	0.04	0.245	0.02
Wits appraisal, mm	0.191	0.08	-0.220	0.04	-0.189	0.08	0.204	0.06
Convexity angle, °	0.196	0.07	-0.84	0.44	-0.236	0.03	0.221	0.04
<i>ΔVertical (ΔT2-T1)</i>								
SN-GoMe, °	-0.036	0.74	0.050	0.65	0.059	0.59	-0.038	0.72
Gonial angle, °	-0.071	0.52	0.003	0.97	-0.009	0.93	0.003	0.97
Lower facial height, mm	-0.249	0.02	0.224	0.04	0.273	0.01	-0.314	0.003
<i>ΔSoft tissue (ΔT2-T1)</i>								
Nasolabial angle, °	0.013	0.90	0.088	0.42	-0.028	0.80	0.088	0.42
Upper lip strain, mm	0.009	0.93	-0.018	0.86	-0.054	0.62	-0.018	0.86
Lower lip thickness, mm	0.078	0.47	-0.069	0.53	0.059	0.58	-0.069	0.53
Soft tissue A, mm	0.040	0.71	0.076	0.49	0.020	0.85	0.076	0.49
Soft tissue B, mm	-0.179	0.10	0.158	0.14	0.140	0.20	0.158	0.14
Soft tissue profile, °	-0.239	0.02	0.157	0.15	-0.001	0.99	0.157	0.15

Spearman correlation test was used

T1 approximately 2 weeks before orthognathic surgery, T2 at the end of orthodontic treatment, *r* correlation coefficient, $\Delta T1-T0$ the average value of the difference between T0 and T1, $\Delta T2-T1$ the average value of the difference between T1 and T2, bold font indicates statistical significance

plained by a stretching of the upper lip following maxillary advancement [22]. However, the change in upper lip strain was minimal and seemed clinically insignificant. Moreover, upper lip response to dentoskeletal changes following orthognathic surgery could not be predicted precisely [23]. Although a significant correlation was revealed between an increasing UOP angle and increasing upper lip strain, for the surgical planning process, it should also be remembered that there are various other factors that are responsible for upper lip strain such as the amount of orthodontic decompensation, sagittal movement of the maxilla, surgical technique, lip morphology, lip tonus, wound healing, and scarring [22, 24].

An increasing UOP angle showed a significant correlation with an increasing overbite and a decreasing soft tissue B-point. This finding was not surprising, considering reports on a decrease in mandibular projection after increasing the upper occlusal plane angle in the literature [12, 25–27].

Interestingly, a significant correlation was found between the amount of pre-operative decompensation of both the upper and lower incisors and lower facial height. This means that when the incisors were not decompensated adequately prior to surgery, control of the vertical dimension was compromised to correct the sagittal relationship. In other words, sufficient dental decompensation would provide better vertical control in class III orthognathic surgery patients. However, achieving an ideal position of the lower incisors is often difficult due to the narrow alveolar width in high-angle patients [21]. Therefore, upper premolar extractions may be included in the treatment plan to achieve sufficient preoperative overjet and consequently, to establish a proper sagittal relationship while controlling the vertical dimension.

The intergroup comparison showed that the CW group obtained a greater amount of mandibular setback than the CCW group at the soft tissue B-point. Although there was no significant difference in the overjet change from T1 to T2 between the groups, the reason for the smaller posterior

Table 5 Comparison of cephalometric variables between the clockwise (CW) and counterclockwise (CCW) groups

Tab. 5 Vergleich der kephalometrischen Variablen zwischen der Gruppe mit induzierter Rechts- (CW) und der mit induzierter Linksdrehung (CCW)

	CCW group (n = 52)		CW group (n = 33)		p-Value
	Mean	SD	Mean	SD	
<i>ΔSagittal (ΔT2–T1)</i>					
SNA, °	3.7	1.8	3.7	1.9	NS
SNB, °	–1.8	1.9	–2.4	1.7	NS
ANB, °	5.6	2	6.2	2.5	NS
Wits appraisal, mm	7.4	4.4	7.7	6.5	NS
Convexity angle, °	10.3	4.7	10.7	5.5	NS
<i>ΔVertical (ΔT2–T1)</i>					
SN-GoMe, °	–1.1	2.9	–0.5	3.1	NS
Gonial angle, °	–1.1	7	1	15.5	NS
Lower facial height, mm	–1.6	3	–1.3	4.2	NS
Upper occlusal plane angle, °	–5.3	3.9	4.3	3	<0.001
<i>ΔDental (ΔT2–T1)</i>					
U1-PP, °	1.1	4.9	–0.39	5.9	NS
U1-UOP, °	–0.5	3.8	0.3	5.1	NS
IMPA, °	–1.6	6.9	–2.6	9.2	0.03
L1-LOP, °	0.4	3.3	1.7	5.3	NS
Overjet, mm	8.4	3.4	9.2	3	NS
Overbite, mm	0.7	2	1.7	2.6	0.04
<i>ΔSoft tissue (ΔT2–T1)</i>					
Nasolabial angle, °	–0.7	10.5	–0.5	10.9	NS
Upper lip strain, mm	0.3	1.9	1.1	1.5	0.04
Lower lip thickness, mm	–0.8	3	–1.1	3.2	NS
Soft tissue A, mm	0.9	1.7	1.7	1.9	NS
Soft tissue B, mm	–4.9	4.7	–5.6	4.6	0.04
Soft tissue profile, °	–7	4.5	–6.3	4.7	NS

Mann–Whitney U test was used

T1 approximately 2 weeks before orthognathic surgery, T2 at the end of orthodontic treatment, SD standard deviation, NS nonsignificant, ΔT2–T1 the average value of the difference between T1 and T2

movement at the soft tissue B-point in the CCW group could be that flattening the occlusal plane increased chin projection [12, 25–27].

IMPA demonstrated a clinically small but statistically significant decrease in the CW group from T1 to T2. A possible explanation is the tendency of the lower incisors to return to their original position because collisions may occur between lower anterior teeth and the palatal surface of upper ones due to short-term skeletal relapse. Similarly, Han et al. [28] reported that clockwise rotation during surgery was more critical than the amount of mandibular setback for short-term postoperative relapse.

The retrospective nature of this study is a concern. However, strict inclusion criteria were applied to the patients to overcome this limitation. Another limitation was the absence of cephalometric evaluations immediately after orthognathic surgery. Further studies are still needed to specify the effects of surgical manipulation of the occlusal plane on facial balance.

Conclusion

- Adequate decompensation of both the upper and lower incisors provides superior improvements of the sagittal skeletal relationship and facial contour. Moreover, incomplete incisor decompensation seems to have negative effects on vertical control during orthognathic surgery.
- Counterclockwise (CCW) rotation of the upper occlusal plane contributed to an increase in sagittal projection of the mandibular body at the soft tissue B-point, while clockwise (CW) rotation of the mandible resulted in a decrease in sagittal projection of the mandibular body at the soft tissue B-point.
- Upper lip strain increased following orthognathic surgery with CW rotation of the upper occlusal plane.

Surgical planning involves examination of not only cephalometric features but also numerous clinical characteristics such as dental and gingival display at rest and during smiling, lip position, and lip activity. Therefore, practitioners should carefully evaluate the response of soft tissues, especially the upper lip, to surgical alteration of the occlusal plane. Furthermore, orthodontists and surgeons should strike a balance between clinical and cephalometric features in surgical planning to achieve better esthetic and functional outcomes.

Funding This research did not receive any specific grant from funding agencies in the public, commercial, or not-for-profit sectors.

Declarations

Conflict of interest E.D. Seker, E. Sunal Akturk, H.N. Yilmaz and N. Kucukkeles declare that they have no competing interests.

Ethical standards The experimental protocols of this study were approved by Bezmialem Vakif University Ethics Committee (01/01, 19.01.2021). Written informed consent was received from all participating patients and their parents or legal guardians for the patients under 18.

References

1. Perillo L, Vitale M, Masucci C, D'Apuzzo F, Cozza P, Franchi L (2016) Comparisons of two protocols for the early treatment of class III dentoskeletal disharmony. *Eur J Orthod* 38:51–56. <https://doi.org/10.1093/ejo/cjv010>
2. Lin J, Gu Y (2003) Preliminary investigation of nonsurgical treatment of severe skeletal class III malocclusion in the permanent dentition. *Angle Orthod* 73:401–410. [https://doi.org/10.1043/0003-3219\(2003\)073\(0401:PIONTO\)2.0.CO;2](https://doi.org/10.1043/0003-3219(2003)073(0401:PIONTO)2.0.CO;2)
3. Ellis E III, McNamara J Jr (1984) Components of adult class III malocclusion. *J Oral Maxillofac Surg* 42:295–305. [https://doi.org/10.1016/0278-2391\(84\)90109-5](https://doi.org/10.1016/0278-2391(84)90109-5)
4. Troy BA, Shanker S, Fields HW, Vig K, Johnston W (2009) Comparison of incisor inclination in patients with class III malocclusion treated with orthognathic surgery or orthodontic camouflage. *Am J Orthod Dentofacial Orthop* 135:146.e1–146.e9. <https://doi.org/10.1016/j.ajodo.2008.07.012>
5. Satrom KD, Sinclair PM, Wolford LM (1991) The stability of double jaw surgery: a comparison of rigid versus wire fixation. *Am J Orthod Dentofacial Orthop* 99:550–563. [https://doi.org/10.1016/S0889-5406\(05\)81632-4](https://doi.org/10.1016/S0889-5406(05)81632-4)
6. Bailey LTJ, Dover AJ, Proffit WR (2007) Long-term soft tissue changes after orthodontic and surgical corrections of skeletal class III malocclusions. *Angle Orthod* 77:389–396. <https://doi.org/10.2319/0003-3219>
7. Proffit WR, Phillips C, Douvartzidis N (1992) A comparison of outcomes of orthodontic and surgical-orthodontic treatment of class II malocclusion in adults. *Am J Orthod Dentofacial Orthop* 101:556–565. [https://doi.org/10.1016/0889-5406\(92\)70131-S](https://doi.org/10.1016/0889-5406(92)70131-S)
8. Capelozza Filho L, Martins A, Mazzotini R, da Silva Filho O (1996) Effects of dental decompensation on the surgical treatment of mandibular prognathism. *Int J Adult Orthodon Orthognath Surg* 11:165–180
9. Potts B, Shanker S, Fields HW, Vig KW, Beck FM (2009) Dental and skeletal changes associated with class II surgical-orthodontic treatment. *Am J Orthod Dentofacial Orthop* 135:566.e1–566.e7. <https://doi.org/10.1016/j.ajodo.2007.08.020>
10. Quast A, Santander P, Leding J, Klenke D, Moser N, Schliephake H et al (2021) Orthodontic incisor decompensation in orthognathic therapy—success and efficiency in three dimensions. *Clin Oral Invest* 25:4001–4010. <https://doi.org/10.1007/s00784-020-03730-6>
11. Tsai I-M, Lin C-H, Wang Y-C (2012) Correction of skeletal class III malocclusion with clockwise rotation of the maxillomandibular complex. *Am J Orthod Dentofacial Orthop* 141:219–227. <https://doi.org/10.1016/j.ajodo.2010.01.038>
12. Arnett GW, Jelic JS, Kim J, Cummings DR, Beress A, Worley CM Jr et al (1999) Soft tissue cephalometric analysis: diagnosis and treatment planning of dentofacial deformity. *Am J Orthod Dentofacial Orthop* 116:239–253. [https://doi.org/10.1016/S0889-5406\(99\)70234-9](https://doi.org/10.1016/S0889-5406(99)70234-9)
13. Baccetti T, Franchi L, Kim LH (2009) Effect of timing on the outcomes of 1-phase nonextraction therapy of class II malocclusion.

- Am J Orthod Dentofacial Orthop 136:501–509. <https://doi.org/10.1016/j.ajodo.2007.08.029>
14. Franchi L, Alvetro L, Giuntini V, Masucci C, Defraia E, Baccetti T (2011) Effectiveness of comprehensive fixed appliance treatment used with the forus fatigue resistant device in class II patients. *Angle Orthod* 81:678–683. <https://doi.org/10.2319/102710-629.1>
 15. Bland JM, Altman DG (2007) Agreement between methods of measurement with multiple observations per individual. *J Biopharm Stat* 17:571–582. <https://doi.org/10.1080/10543400701329422>
 16. Dahlberg G (1940) *Statistical methods for medical and biological students*. Interscience Publications, New York
 17. Parente E, Lacerda G, Silvaes MG (2014) Surgical manipulation of the occlusal plane in class III deformities: 5 features to help planning. *Open J Stomatol* 4:238–242. <https://doi.org/10.4236/ojst.2014.45033>
 18. Kim D-K, Baek S-H (2013) Change in maxillary incisor inclination during surgical-orthodontic treatment of skeletal class III malocclusion: comparison of extraction and nonextraction of the maxillary first premolars. *Am J Orthod Dentofacial Orthop* 143:324–335. <https://doi.org/10.1016/j.ajodo.2012.10.014>
 19. Worms FW, Isaacson RJ, Speidel TM (1976) Surgical orthodontic treatment planning: profile analysis and mandibular surgery. *Angle Orthod* 6:1–25. [https://doi.org/10.1043/0003-3219\(1976\)046](https://doi.org/10.1043/0003-3219(1976)046)
 20. Johnston C, Burden D, Kennedy D, Harradine N, Stevenson M (2006) Class III surgical-orthodontic treatment: a cephalometric study. *Am J Orthod Dentofacial Orthop* 130:300–309. <https://doi.org/10.1016/j.ajodo.2005.01.023>
 21. Ahn H-W, Baek S-H (2011) Skeletal anteroposterior discrepancy and vertical type effects on lower incisor preoperative decompen-
 - sation and postoperative compensation in skeletal class III patients. *Angle Orthod* 81:64–74. <https://doi.org/10.2319/031710-158.1>
 22. Altug-Atac AT, Bolatoglu H, Memikoglu UT (2008) Facial soft tissue profile following bimaxillary orthognathic surgery. *Angle Orthod* 78:50–57. <https://doi.org/10.2319/122206-525.1>
 23. Koh CH, Chew MT (2004) Predictability of soft tissue profile changes following bimaxillary surgery in skeletal class III Chinese patients. *J Oral Maxillofac Surg* 62:1505–1509. <https://doi.org/10.1016/j.joms.2004.04.022>
 24. Lin S-S, Kerr WJS (1998) Soft and hard tissue changes in class III patients treated by bimaxillary surgery. *Eur J Orthod* 20:25–33. <https://doi.org/10.1093/ejo/20.1.25>
 25. Sonogo C, Bobrowski Â, Junior OC, Torriani M (2014) Aesthetic and functional implications following rotation of the maxillo-mandibular complex in orthognathic surgery: a systematic review. *Int J Oral Maxillofac Surg* 43:40–45. <https://doi.org/10.1016/j.ijom.2013.07.738>
 26. Esteves LS, Ávila C, Medeiros PJ (2012) Changes in occlusal plane through orthognathic surgery. *Dental Press J Orthod* 17:160–173
 27. McCollum AG, Reyneke JP, Wolford LM (1989) An alternative for the correction of the class II low mandibular plane angle. *Oral Surg Oral Med Oral Pathol* 67:231–241. [https://doi.org/10.1016/0030-4220\(89\)90344-7](https://doi.org/10.1016/0030-4220(89)90344-7)
 28. Han JJ, Yang HJ, Lee S-J, Hwang SJ (2014) Relapse after SSRO for mandibular setback movement in relation to the amount of mandibular setback and intraoperative clockwise rotation of the proximal segment. *J Craniomaxillofac Surg* 42:811–815. <https://doi.org/10.1016/j.jcms.2013.11.018>

Publisher's Note Springer Nature remains neutral with regard to jurisdictional claims in published maps and institutional affiliations.