

Bilateral Bifid Mandibular Condyle

Bilateral Bifid Mandibular Kondil

*M. Oğuz BORAHAN DDS, PhD, *Birsay Gümrü TARÇIN DDS, PhD, *Filiz PEKİNER DDS, PhD

*Marmara Üniversitesi Dişhekimliği Fakültesi Oral Diagnoz ve Radyoloji Anabilim Dalı

ABSTRACT

Bifid mandibular condyle (BMC) is a rare condition that is frequently diagnosed as an incidental finding in a panoramic radiograph, yet usually with no significant complaints or clinical features, such as pain or restricted movements. In this case report, bilateral bifid mandibular condyle in a 61-year old woman who referred to Marmara University, Department of Oral Diagnosis and Radiology for dental complaints is presented. Realizing the suspicious modification of both mandibular condyle heads in the panoramic radiograph, computed tomography imagining was taken and a "Y appearance" with two distinct medial and lateral heads on both condyles was identified. There were no clinical symptoms in our case, thus no treatment planning was needed. Despite the fact that there is no epidemiological information about its actual incidence, it is thought to be important to identify bilateral bifid mandibular condyle as it is an extremely rare condition.

KEYWORDS

Bifid mandibular condyle, panoramic radiograph, computed tomography

ÖZET

Bifid mandibular kondil (BMC), sıklıkla panoramik radyografide rastlantı bulgusu olarak teşhis edilen nadir bir durumdur ve ağrı/kısıtlı hareket gibi belirgin şikayet veya klinik görüntüsü yoktur. Bu olguda dental şikayetleri nedeni ile Marmara Üniversitesi Dişhekimliği Fakültesi Oral Diagnoz ve Radyoloji Anabilim Dalı'na başvuran 61 yaşındaki hastaya ait bilateral bifid mandibular kondil vakası sunulmaktadır. Alınan panoramik radyografide her iki mandibular kondildeki şüpheli görüntü nedeni ile bilgisayarlı tomografi incelemesi yapılmış ve her iki mandibular kondilde iki ayrı medial ve lateral başı olan "Y" şeklinde bir görüntü saptanmıştır. Sunulan vakada herhangi bir klinik semptom bulunmadığından tedaviye ihtiyaç duyulmamıştır. Bu malformasyon hakkında epidemiyolojik bir bilgi olmamasına rağmen, bifid mandibular kondilin nadir görülen bir durum olması sebebiyle tanıtılması önemli bulunmuştur.

ANAHTAR KELİMELER

Bifid mandibular kondil, panoramik radyografi, bilgisayarlı tomografi

INTRODUCTION

The bifid mandibular condyle (BMC) represents a rare developmental anomaly first described in 1941; only a few cases have been reported since then. It is characterized by the duplicity of the head of the mandibular condyle; thus, it is also known as double-headed condyle¹⁻⁴.

The bifid condyle's etiology and pathogenesis is not known. Several factors have been cited as possible causes of bifid mandibular condyle, including condylar fracture, developmental anomalies, perinatal trauma, teratogenic embryopathy and surgical condylectomy¹. Although not confirmed, infection, irradiation, and genetic discrepancy may also play a role. Bifid mandibular condyle does not usually bring about significant complaints or clinical symptoms, such as pain or restricted movements⁵.

It usually affects only one condyle, and the occurrence of bilateral BMC is exceptionally rare. BMC is usually identified as an incidental finding on routine radiographic examination^{1,7}. Computed tomography (CT) imaging provides radiologists and clinicians with the opportunity of evaluating complex cases in the maxillofacial field and receiving information that leads to more accurate and specific diagnosis of some TMJ pathologic conditions¹.

The purpose of this article is to report a clinical case of bilateral BMC with emphasis on causative factors, diagnosis, radiographic and tomographic features, and management.

Case Report:

A 61-year-old woman was referred to Marmara University, Department of Oral Diagnosis and Radiology with complaints of caries and missing teeth. The patient had not previously had any serious disease, and there was no significant family history of the disease or anomaly.

Intraoral examination revealed caries and 15 teeth missing. The functions of the temporomandibular joint (TMJ) were normal. No facial asymmetry was evident on clinical examination. There was no history of trauma or fracture of mandible, and the patient did not report any pain or trismus.

A panoramic radiograph revealed a discrete modification of both mandibular condyle heads (Figure 1). The TMJs of the patient were imaged using a specific mode of panoramic device which open-closed form of both condyles can be seen to evaluate the shape of condyles (Figure 2). Further investigation with axial computed tomography (CT) confirmed the markedly dissimilar appearance of the condyles. Both condyles had two distinct medial and lateral heads (Figure 3). There were no clinical symptoms in our case, thus, no treatment planning was needed. Prosthodontic treatment proved sufficient for the patient to recover.

DISCUSSION

The first description of BMC was published in the American Journal of Physical Anthropology by Hrdlicka, who found 27 cases of this anomaly while analyzing male and female dried human skulls in a Smithsonian Institution collection. Since then, only a few cases of bilateral BMC have been reported in living human beings. According to de Sales et al¹, 8 clinical cases of

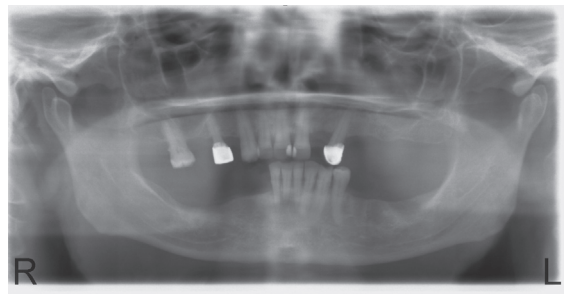


FIGURE 1

Panoramic radiograph of the patient marking a different modification of both condyles

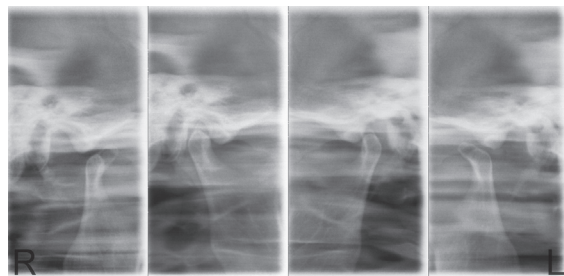


FIGURE 2

An open-closed projection of TMJs showing discrete grooving in both condyles.

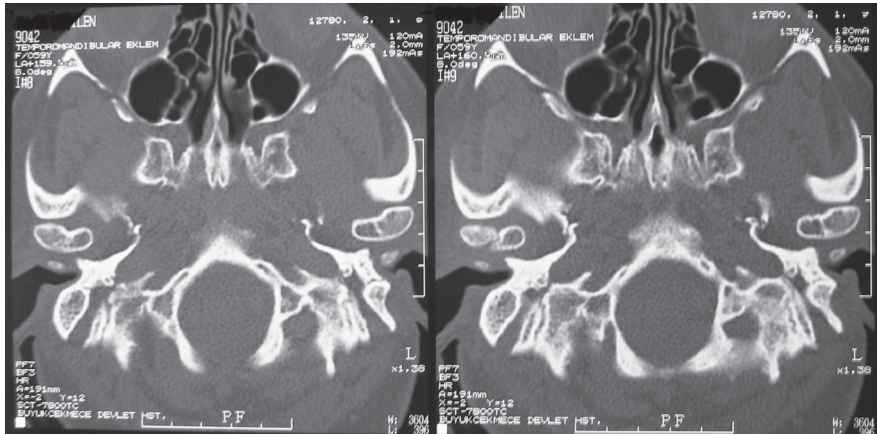


FIGURE 3

Axial CT image through the mandible demonstrate the conjunction of mediolaterally oriented heads of both condyles

bilateral BMC had been reported up to 2004. We have searched for the medical literature on MEDLINE (from April 2004 through December 2007) for English language case reports of BMC in living subjects and we have found that only 5 additional papers, reporting a total of 5 cases, have so far been identified, which yields a total of 13 cases. The fact that there are only a few studies conducted on this subject is indicative of the rarity of this disorder.

The orientation of bifid condyle has been classified as anterior-posterior and mediolateral. Szentpetery et al.⁸ have suggested that when 2 condylar parts lie in the sagittal plane trauma is indicated as the cause and when the parts lie in the coronal plane the persistence of the fibrous septa at the condylar cartilage is likely to be the cause. While this may be true for the majority of cases, some mediolateral bifid condyles have been reported following sagittal fracture through the condylar head^{9,10}.

According to Blackwood¹¹, two articulating surfaces of the BMC were divided by a groove and could be orientated mediolaterally or anteroposteriorly, characterizing a specific entity. In this case report, as postulated above, groove formation and presence of medial and lateral head of both condyles clearly demonstrated the formation of the BMC.

The etiology of bifid mandibular condyle is not fully understood and the literature consider a large

number of postulations¹². For example, Blackwood¹¹ stated that the condylar cartilage, during the early stages of its development, was divided by well-vascularized fibrous septa and suggested that persistence of such a septum, in exaggerated form, within the growing cartilage might lead to an error in development that would in turn give rise to the bifid condition. This author also mentioned the rupture of septal blood vessels as another possible cause of BMC. However, Gundlach and others¹³ found no evidence of persistent septa in the cases of BMC that they examined. Quayle and Adams¹⁴ proposed that endocrine disorders, nutritional deficiency, infection, trauma, irradiation, and genetic factors could be the cause.

It must be stressed that the mandibular condyle region is a crucial centre of facial growth. Thus, injuries during childhood and puberty can lead to condylar malformations including BMC and severe facial asymmetry¹⁵. Szentpetery and others⁸ have stated that the site of the fracture and, most probably, its relation to the insertion of the lateral pterygoid muscle may determine future development of a normal or bifid condyle.

In our case, as there is no history of trauma, it is possible to say that the cause of the bilateral bifid condyle may be the persistence of the fibrous septa.

In the most cases, patients have no symptoms and the majority of cases are detected during radiographic routine examination¹⁶. Accord-

ding to Loh and Yeo⁹, %67 of patients with BMC had no complaints related to the affected condyles: the condition was detected as an incidental finding during dental radiographic examination. However, bifid mandibular condyle has been reported to be associated with symptoms such as pain, swelling, limited mouth opening, and most commonly, TMJ clicking³. These symptoms are often seen when there is a trauma history. In our case, due to the lack of clinical symptom, diagnosis was based on radiological findings.

According to García-González et.al.¹⁷, appropriate treatment for BMC depends on the symptoms. Asymptomatic cases do not require any treatment although long-term follow up is necessary. Patients with internal articular derangement should be treated with occlusal splints and arthroscopic surgery¹⁷. There are no clinical symptoms in our case and no treatment planning is needed.

Although panoramic radiograph was a valid diagnostic tool in the diagnosis of BMC, conventional radiographs were not sufficient to reach a final diagnosis. In the case presented here, the choice for CT scan depicted the advantages of this modality of imaging over other methods. As previously stated by El-Hakim¹⁸, axial and coronal CT images were of great value in illustrating the relation of the vital structures at the base of the skull to the mediolateral heads of bilateral TMJ, thus characterizing a true bifid mandibular condyle.

It can be concluded that bilateral bifid mandibular condyles is an extremely rare condition although there is no epidemiological information about the actual incidence of this malformation.

In our case, it is more likely to be due to some unexplained defect during the development of condylar head rather than trauma.

Geliş Tarihi : 25.02.2008
Kabul Tarihi : 26.05.2008

Received Date : 25 February 2008
Accepted Date : 26 May 2008

REFERENCES

1. Sales MA, Amaral JI, Amorim RF, Almeida Freitas R. Bifid mandibular condyle: case report and etiological considerations. *J Can Dent Assoc.* 2004; 70(3):158-62.
2. Alpaslan S, Ozbek M, Hersek N, Kanli A, Avcu N, Firat M. Bilateral bifid mandibular condyle. *Dentomaxillofac Radiol.* 2004; 33(4):274-7.
3. Antonaides K, Hadjipetrou L, Antoniadis V, Paraskevopoulos K. Bilateral bifid mandibular condyle. *Oral Surg Oral Med Oral Pathol Oral Radiol Endod.* 2004; 97(4):535-8.
4. Corchero-Martin G, Gonzalez-Teran T, Garcia-Reija MF, Sanchez-Santolino S, Saiz-Bustillo R. Bifid condyle: case report. *Med Oral Patol Oral Cir Bucal.* 2005; 10(3):277-9.
5. Sales MA, Oliveira JX, Cavalcanti MG. Computed tomography imaging findings of simultaneous bifid mandibular condyle and temporomandibular joint ankylosis: case report. *Braz Dent J.* 2007; 18(1):74-7.
6. Shriki J, Lev R, Wong BF, Sundine MJ, Hasso AN. Bifid mandibular condyle: CT and MR imaging appearance in two patients: case report and review of the literature. *Am J Neuroradiol.* 2005; 26(7):1865-8
7. Ramos FM, Filho JO, Manzi FR, Boscolo FN, Almeida SM. Bifid mandibular condyle: a case report. *J Oral Sci.* 2006; 48(1):35-7
8. Szentpetery A, Kocsis G, Marcsik A. The problem of the bifid mandibular condyle. *J Oral Maxillofac Surg* 1990; 48:1254-7.
9. Loh FC, Yeo JF. Bifid condyle. *Oral Surg Oral Med Oral Pathol Oral Radiol Endod* 1990; 69:24-7.
10. Wu XG, Hong M, Sun KH. Severe osteoarthritis after fracture of the mandibular condyle: a clinical, histologic study of seven patients. *J. Oral Maxillofac Surg* 1994;52:138-42
11. Blackwood HJ. The double-headed mandibular condyle. *Am J Phys Anthropol* 1957; 15:1-8
12. Artvinli LB, Kansu O. Trifid mandibular condyle: A case report. *Oral Surg Oral Med Oral Pathol Oral Radiol Endod.* 2003; 95(2):251-4
13. Gundlach KK, Fuhrmann A, Beckmann-Van der Ven G. The double headed mandibular condyle. *Oral Surg Oral Med Oral Pathol* 1987; 64(2):249-53
14. Quayle AA, Adams JE. Supplemental mandibular condyle. *Br J Oral Maxillofac Surg* 1986; 24:349-56.
15. Kahl B, Fischbach R, Gerlach KL. Temporomandibular joint morphology in children after treatment of condylar fractures with functional appliance therapy: a follow-up study using spiral computed tomography. *Dentomaxillofac Radiol* 1995; 24(1):37-45.
16. Cowan DF, Ferguson MM. Bifid mandibular condyle. *Dentomaxillofac Radiol.* 1997; 26(1):70-3.
17. Garcia-Gonzales D, Martin-Granizo R, Lopez P. Imaging quiz case 4. Bifid mandibular condyle. *Arch Otolaryngol Head Neck Surg* 2000; 126(6):795-9.
18. El-Hakim IE, Metwalli SA. Imaging of temporomandibular joint ankylosis. A new radiographic classification. *Dentomaxillofac Radiol* 2002;31:19-23.

CORRESPONDING ADDRESS

M. Oğuz BORAHAN DDS, PhD

Marmara University Faculty of Dentistry Department of Oral Diagnosis and Radiology Nişantaşı/İstanbul
Phone: 0 212 2319120/117 Faks : 0 212 2465247