

Cardiac Imaging

PP-001

Evaluation of Association Between Fluoro-D-Glucose Positron Emission Tomography Uptake with Right Ventricular Functions in Patients with Chronic Thromboembolic Pulmonary Hypertension

Murat Sunbul¹, Tarik Kivrak¹, Mustafa Oguz¹, Salih Ozguven², Serkan Gungor², Fuat Dede², Halil Turgut Turoglu², Bedrettin Yildizeli³, Bulent Mutlu¹

¹Marmara University, Faculty of Medicine, Department of Cardiology, Istanbul,

²Marmara University Faculty of Medicine, Department of Nuclear Medicine, Istanbul,

³Marmara University, Faculty of Medicine, Department of Thoracic Surgery, Istanbul

Objective: Chronic thromboembolic pulmonary hypertension (CTEPH) is a progressive disease characterized by increased pulmonary vascular resistance resulting in pulmonary hypertension and right heart failure. Previous studies have shown that right ventricular fluoro-D-glucose positron emission tomography (RV FDG-PET) uptake (RV/LV ratio) was associated with pulmonary vascular resistance in patients with idiopathic pulmonary arterial hypertension (IPAH). Aim of the present study is to explore association of RV FDG-PET uptake with RV functions in patients with CTEPH.

Methods: We enrolled 35 consecutive patients with CTEPH. All patients underwent a transthoracic echocardiogram and FDG-PET for evaluation of cardiac functions. Patients were divided into two groups according to tricuspid annular plane systolic excursion (TAPSE) measurements.

Results: Patients characteristics and clinical data are shown in table. While fifteen patients had higher TAPSE value (≥ 15), twenty patients had decreased TAPSE value (< 15). Patients with higher TAPSE value had higher RVS, PVR, and FDG PET (RV/LV ratio) value (Table).

Conclusion: Higher PDG PET (RV/LV ratio) is associated with impaired RV functions in patients with CTEPH. PDG PET (RV/LV ratio) may be a non-invasive marker for detection of impaired RV functions.

Table 1

	Patients with TAPSE \geq 15 (n=15)	Patients with TAPSE $<$ 15 (n=20)	p
Age (years)	59.3 \pm 12.7	51.6 \pm 12.8	0.099
LVEF (%)	64.3 \pm 5.4	64.1 \pm 7.1	0.894
sPAB (mmHg)	60.9 \pm 25.2	71.2 \pm 32.0	0.282
RVS (cm/s)	12.9 \pm 2.0	9.7 \pm 2.2	<0.001
PVR (mmHg)	8.9 \pm 6.1	13.8 \pm 5.2	0.038
RV/LV FDG PET	0.97 \pm 0.45	1.47 \pm 0.68	0.036

sPAB: Systolic pulmonary artery pressure; RVS: Right ventricular systolic velocity; TAPSE: Tricuspid annular plane systolic excursion; PVR: Pulmonary vascular resistance; LVEF: Left ventricular ejection fraction; RV/LV FDG PET: Right ventricular fluoro-D-glucose positron emission tomography

PP-002

The Implementation of the Golden Ratio to the Healthy Human Heart

Murat Çelik¹, Yalçın Gökoğlan¹, Sedat Develi³, Uygur Çağdaş Yüksel¹, Emre Yalçınkaya¹, Erkan Kaya², Kubilay Karabacak², Barış Buğun¹, Hasan Kutsi Kabul¹, Erkan Yıldırım¹

¹Gulhane Military Medical Academy, Department of Cardiology, Ankara, ²Gulhane Military Medical Academy, Department of Cardiovascular Surgery, Ankara,

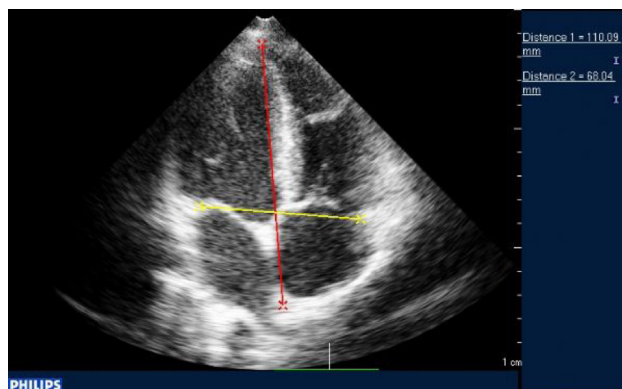
³Gulhane Military Medical Academy, Department of Anatomy, Ankara

Objective: The golden ratio (also called as golden section, golden mean or Fibonacci number) is a sophisticated number series, which are directly and intricately related to another very special math formula, such as 2,3,5,8,13,21,34,55,89, etc. The golden ratio is described, as 'the small is too large as the large is to whole'. It is an irrational, continuous and non-repeating number and goes on forever (identical to this 1.6180339887498948482045868343656381177203091798057.....to infinity. Pythagoras, the thirteenth century mathematician, first described it and it has been found all throughout life and the physical cosmos, especially in biology, great art and architecture. The golden ratio has also been discovered within the proportion of the body parts, especially including extremities and facial structures. We hypothesized that there may be a golden ratio in the structure of the healthy heart.

Material-Methods: Healthy male patients without any cardiovascular risk factors enrolled to this study. Two-D transthoracic echocardiography was performed using a Philips IE 33 6.0 ultrasound system (Philips Medical Systems, Andover, MA, USA) with a 2.5 MHz transducer. We obtained vertical and transvers cardiac dimensions from the 4-chambered echo view at the end of the diastole. Afterwards, the cardiac ratio (golden ratio of the heart) was accepted as the divine of the vertical dimension (large one) to the transvers dimension (small one). Also, left ventricular and the right ventricular ratio were measured using ventricular inlet length and width in the same manner. All measurements were done by two observers, which do not have any information about the patients. All results for continuous variables with normal distribution were expressed as mean \pm standard deviation (SD) and skewed variables as median (interquartile range — IQR).

Results: One hundred and five healthy male patients (median (IQR) age 23 (3) years) The mean height was 174.71 \pm 4.90 cm, and mean weight was 71.08 \pm 7.73 kilograms. The mean cardiac transvers dimension was 11.55 \pm 0.84 cm and the mean cardiac vertical dimension was 7.82 \pm 7.11 cm. The cardiac ratio was continued at approximately 1.6183 (0.02). However, the left ventricular ratio was continued at approximately 1.8922 (0.24) and the right ventricular ratio was 1.5807 (0.29). Also we observed that Mitral E/A value was approximately at 1.6191 (0.47) and tricuspid E/A value was 1.5171 (0.26).

Conclusion: We determined that there is a constant ratio between the overall cardiac vertical and transvers dimension similar to the golden ratio of 1.618 in the healthy heart of the young Turkish male adults. The use of the golden ratio of the heart in daily clinical practice may help us to determine the deviation from the normalcy quickly and easily, and we therefore can manage and treat the patient before irreversible changes occurs.



Results of the Study

	Results (Mean \pm SD / Median (IQR))
Age, (years)	23 (3)
Height, (mm)	174.71 \pm 4.90
Weight, (mm)	71.08 \pm 7.73
Echocardiography	
Cardiac vertical dimension, (cm)	11.55 \pm 0.84
Cardiac transverse dimension, (cm)	7.82 \pm 7.11
Cardiac ratio	1.6183 (0.02)
LV vertical dimension, (cm)	7.20 \pm 0.78
LV transverse dimension, (cm)	4.12 \pm 3.09
LV ratio	1.8922 (0.24)
RV vertical dimension, (cm)	5.34 \pm 0.84
RV transvers dimension, (cm)	3.35 \pm 0.42
RV ratio	1.5807 (0.29)
Mitral E, (cm/sn)	92.71 \pm 15.48
Mitral A, (cm/sn)	59.73 \pm 12.50
Mitral E/A	1.6191 (0.47)
Tricuspid E, (cm/sn)	67.16 \pm 12.22
Tricuspid A, (cm/sn)	45.78 \pm 9.20
Tricuspid E/A	1.5171 (0.26)