

# Two-Suture Fish-Mouth End-to-Side Microvascular Anastomosis With Fibrin Glue

*Bulent Sacak, MD, FEBOPRAS,\* Ugur Tosun, MD,† Onur Egemen, MD,‡ Deniz Ozgur Sucu, MD,§ Ismail Bulent Ozcelik, MD,|| and Kemal Ugurlu, MD#*

**Abstract:** The most decisive step during free tissue transfers and replantation surgery may be respected as microvascular anastomosis. The conventional end-to-side anastomosis technique with simple interrupted sutures is well established and proven to be successful. On the other hand, conventional technique can be time consuming and can cause vascular thrombosis, vessel narrowing, and foreign-body reactions. Search for a more rapid and secure alternative to conventional technique is carried on. In this study, we defined a new technique for end-to-side anastomosis with fish-mouth incisions and application of fibrin glue and compared our results with those we obtained with conventional end-to-side anastomosis. We evaluated end-to-side anastomosis of carotid arteries of a total number of 64 Wistar-Albino rats. In control group (n = 32), conventional anastomoses with 8 to 10 sutures were performed. In experimental group (n = 32), fish-mouth incisions were applied first on the recipient artery, followed by performing anastomosis with only 2 corner sutures and applying commercially available fibrin glue. Time taken to perform the anastomosis was significantly shorter with the experimental group ( $P = 0.001$ ), whereas early and late patency and aneurysm rates were comparable to those achieved with control group. Histological evaluation did not point out any significant differences between the groups. We have defined a rapid and safe alternative technique of end-to-side anastomosis with the use of fibrin glue. This method may be an alternative especially where multiple anastomoses are required or where it is difficult to approach

anastomotic line, as it is easily performed, rapid, safe, and not involving any complex equipments.

**Key Words:** End-to-side anastomosis, fish-mouth incision, fibrin glue

(*J Craniofac Surg* 2012;23: 1120–1124)

Microvascular anastomosis may be accepted as the most decisive step of replantation and free-flap procedures. Among the 2 major anastomotic techniques, end-to-end and end-to-side, the prior is mostly preferred. End-to-end anastomosis is well established, relatively simple, and mostly successful. On the other hand, in circumstances such as to preserve the physiological arterial flow distal to the anastomotic site, to manage size discrepancies, or to avoid possible vascular spasm, end-to-side anastomosis is the technique to be preferred.<sup>1</sup>

Conventionally, either end-to-end or end-to-side anastomosis is performed with simple interrupted microsutures following appropriate approximation of vessel ends. Despite that the conventional method is widely accepted as the criterion standard, several difficult situations are to be met in clinical settings. Most end-to-side anastomoses have to be performed in depth of a wound especially in lower-leg reconstruction, which makes anastomosis technically even more challenging. Thus, simple interrupted sutures may be time consuming, and elongated clamping time and possible iatrogenic intimal injury may cause thrombosis and anastomotic failure.<sup>2–4</sup> Application of tissue adhesives in microsurgery is among several techniques to overcome these disadvantages. Matras<sup>5</sup> described the use of fibrin glue in microvascular anastomosis in detail. Gestring et al<sup>6</sup> used fibrin glue in a sutureless end-to-side anastomosis model. Evidence supporting the application of fibrin glue has expanded since then.<sup>7–11</sup>

This study describes a novel technique for end-to-side anastomosis with fibrin glue in an experimental rat model, presents our results, and discusses the evaluation of methods developed for end-to-side anastomosis.

## MATERIALS AND METHODS

Common carotid arteries of the laboratory rat are a proven and ideal model for end-to-side anastomosis studies.<sup>12</sup> Common carotid arteries are easily accessible and have adequate vessel size and patency. Seventy-five Wistar-Albino rats (250–300 g in weight) are used to complete 2 groups consisting of 32 rats each. Eleven rats, which died most likely because of anesthetic complications or asphyxia during surgical procedure or early postoperatively, were excluded.

From the \*Department of Plastic, Reconstructive and Aesthetic Surgery, Bagcilar Training and Research Hospital, Bagcilar, Istanbul; †Department of Plastic, Reconstructive and Aesthetic Surgery, Tekirdag State Hospital, Tekirdag; ‡Department of Plastic, Reconstructive and Aesthetic Surgery, Okmeydani State Hospital, Istanbul; §Department of Plastic, Reconstructive and Aesthetic Surgery, Sisli Training and Research Hospital, Sisli, Istanbul; ||Microsurgery and Rehabilitation Group, IST-EL Hand Surgery, Gaziosmanpasa, Istanbul; and #Department of Plastic, Reconstructive and Aesthetic Surgery, Sisli Training and Research Hospital, Sisli, Istanbul, Turkey.

Received November 16, 2011.

Accepted for publication January 15, 2012.


Address correspondence and reprint requests to Bulent Sacak, MD, FEBOPRAS, Department of Plastic, Reconstructive and Aesthetic Surgery, Bagcilar Training and Research Hospital, Bagcilar, Istanbul, Turkey; E-mail: bsacak@gmail.com

The authors report no conflicts of interest.

Copyright © 2012 by Mutaz B. Habal, MD

ISSN: 1049-2275

DOI: 10.1097/SCS.0b013e31824e2a39

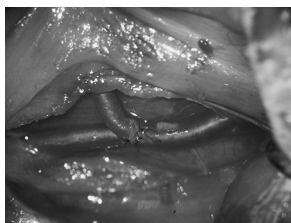

**FIGURE 1.** Left carotid was passed through to the right side, posterior to trachea and paratracheal muscles. An arteriotomy was performed on the side of the right carotid.

Rats were anesthetized with intramuscularly administered ketamine HCl 100 mg/kg (Ketalar, Parke Davis, Morris Plains, NJ) and xylazine 10 mg/kg (Rompun; Bayer, Leverkusen, Germany). No anticoagulants were administered at any time. Institutional guides for the care and use of laboratory animals were followed. Rats were prepared and immobilized supine. All surgical procedures were completed by the same individual. A transversely oriented incision at the caudal end of the trachea was made. Blunt dissection was used to separate sternohyoideus and sternomastoideus muscles to expose the carotid sheath bilaterally. Microvascular dissection was carried on under a Leica (Leica Microsystems CMS GmbH, Wetzlar, Germany) tabletop microscope to expose common carotid arteries without harming vagus nerve or internal jugular vein. Left common carotid artery was ligated proximally, and the cephalic end was passed to the right side through a tunnel posterior to the trachea. After appropriate-size approximating clamps were applied, an arteriotomy was performed with curved microscissors on the right carotid (Fig. 1). In all cases, lidocaine was used to prevent vasospasm.

In the control group, the left common carotid end was anastomosed to the side of the right common carotid artery in standard fashion with 8 simple interrupted 10/0 Ethilon (Ethicon, Somerville, NJ) sutures, placing the 2 initial sutures 180 degrees apart (Fig. 2).

In the experimental group, midlateral fish-mouth incisions were performed on the left carotid, placing the incisions 180 degrees apart. The lengths of the incisions were adjusted as approximately one half to two thirds of the vessel diameter. Two sutures were placed between the apex of the fish-mouth incisions and the most proximal and distal end of the arteriotomy edges. At this point, care was taken to prevent the free edges of the left carotid neither to be folded nor to invert inside the lumen of the right carotid. After placing the sutures, the distal clamp was released temporarily for a very short moment, to prevent vascular collapse. Beriplast-P (Aventis-Behring, Marburg, Germany) fibrin adhesive was applied gently over the anastomosis by dropping 0.2 mL of fibrinogen containing set-I solution and 0.2 mL of thrombin containing set-II solution sequentially, to prevent excess glue deposition (Fig. 3). After waiting for an approximately 5-minute period, clamps were released, and gentle pressure was applied. Anastomosis time was recorded as the time interval between application and release of the clamps. The immediate



**FIGURE 2.** End-to-side anastomosis with conventional simple interrupted sutures. Patency was visually observed.



**FIGURE 3.** Anastomosis with 2 sutures and fibrin glue application.

patency of the anastomosis was checked 20 minutes after clamp removal in both groups, as described by Acland.<sup>13</sup>

Rats were assigned to groups by alternating the technique with each surgery/rat, continuing sequentially throughout the study. Eight rats from each group were killed on the 3rd, 7th, 14th, and 21st days to inspect late patency and aneurysm formations. Vessel specimens containing the anastomosis segment were taken for histologic analysis.

Data, in terms of vessel patency, anastomosis time, and aneurysm formation, were clinically assessed and statistically analyzed. We used the Kruskal-Wallis test to compare the quantitative parametric data and the Dunn test to compare the quantitative non-parametric data among the control and experimental groups. The Fisher exact test was used to compare the qualitative data. In all cases, we adopted a 5% level of significance ( $P < 0.05$ ).

## RESULTS

The results are summarized in Table 1). The time taken to perform the anastomoses in the first group, anastomosis with conventional technique, varied from 26 to 32 minutes (mean, 29.4 minutes), whereas the time taken to perform the anastomoses in the second group, fish-mouth anastomosis with 2 sutures and fibrin glue, varied from 14 to 21 minutes (mean, 17.25 minutes), which was significantly shorter than the first group in statistical terms ( $P = 0.001$ ). In the comparative analysis of the subgroups, there were no significant differences in the conventional anastomosis group ( $P = 0.684$ ) regarding anastomosis time, whereas there was a significant difference between the subgroups of the experimental group ( $P = 0.04$ ). The difference was particular between the 3rd and 14th day and 3rd and 21st day subgroups. This difference between the subgroups of the experimental group may be interpreted as a result of a slight increase in experience.

The immediate patency rate was 100% in both groups. The late patency rate in the control group was 96.6% (31 of 32), whereas it was 93.75% (30 of 32) in the experimental group (Fig. 4). There was no statistical difference between the groups or subgroups (Table 2).

One case of aneurysm formation was clinically observed in the experimental group, at the 21st day. Despite the presence the aneurysm, good patency was noted (Fig. 5). The comparison of groups or subgroups also did not reveal any significant difference (Table 3).

Histological analysis did not reveal any significant difference between 2 groups, presenting evidence of patent anastomosis, completed epithelialization at the 21st day, no sign of fibrin deposits in the experimental group, and a slightly more intense inflammatory response in the control group (Fig. 6).

## DISCUSSION

Although the early and late results of end-to-end and end-to-side anastomoses are clearly proved to be similar,<sup>14-16</sup> end-to-end

TABLE 1. Results Summary

Rat, n	Subgroup	Conventional Anastomosis				Experimental Anastomosis			
		Anastomosis Time, min	Patency		Aneurysm Formation	Anastomosis Time, min	Patency		Aneurysm Formation
			Immediate	Control			Immediate	Control	
8	3rd day	29.1	8/8	8/8	—/8	18.38	8/8	7/8	—/8
8	7th day	29.1	8/8	8/8	—/8	17.38	8/8	8/8	—/8
8	14th day	29.6	8/8	8/8	—/8	16.63	8/8	8/8	—/8
8	21st day	30	8/8	8/8	—/8	16.60	8/8	7/8	1/8
Mean		29.45*				17.25*			

\*P = 0.001.

anastomosis is recognized as easier to perform and widely used. On the other hand, end-to-side anastomosis remains the only option for the microsurgeons in certain circumstances.

A wide range of techniques has been described and advocated, all in common aiming to overcome the complexity of the conventional end-to-side anastomosis procedure with interrupted sutures. In short titles, these techniques can be categorized as continuous and back wall–first suture end-to-side anastomosis techniques, techniques using instruments, rings and prosthesis developed for end-to-side anastomosis, laser-assisted end-to-side anastomosis, and tissue adhesive–aided end-to-side anastomosis techniques.<sup>17–26</sup>

In our study, we used the fish-mouth incision technique and fibrin glue for end-to-side anastomosis. Fish-mouth incision is initially described by Harashina and Irigaray<sup>26</sup> as method to overcome vessel size discrepancies in microvascular anastomosis. Later on, Turan et al<sup>27</sup> used the fish-mouth technique to facilitate anastomosis for the first time by reducing the number of sutures, thus accomplishing end-to-end anastomosis with only 4 sutures. While emphasizing the lesser trauma caused on the vessel walls, they also pointed out the need for extra vessel length at both sides as a drawback. Tellioglu<sup>28</sup> successfully adopted the fish-mouth incision for end-to-side anastomosis, achieved good patency rates with shorter operative time, and defined the technique as end-on-side anastomosis. Egemen et al<sup>29</sup> combined the fish-mouth incision and fibrin-glue application and presented comparable results for end-to-end anastomosis. We similarly benefited the structural advantages of fish-mouth incision for end-to-side anastomosis. Instead of any permanent or temporary lateral mattress sidewall stitches, we applied fibrin glue and completed the anastomosis with only 2 sutures at the apex of fish-mouth incisions. Our results revealed a significant reduction in operative time without any considerable compromise on

patency or aneurysm formation rates. We completed the conventional end-to-side anastomosis at a mean time of 29.4 minutes, which is parallel to data obtained in previous studies.<sup>7,23</sup> The mean operative time spent to complete the anastomosis in the experimental group was significantly shorter than that in the control group. This reduction would be even more significant at the clinical settings, where multiple anastomoses are frequently required.

Among the 2 major types of tissue adhesives, cyanoacrylates and fibrin glue, the latter has been proven to be safe for clinical use and gained popularity since Matras et al<sup>30</sup> successfully introduced the application of fibrin glue in microvascular anastomosis. There are reports of fibrin glue application in replantation and free flap procedures with excellent outcomes.<sup>31,32</sup>

Despite an important number of clinical and experimental studies standing for the use of fibrin glue, there are still some concerns and drawbacks about the application of fibrin glue in microvascular surgery, such as high rate of aneurysm formation, increased thrombogenicity, and disease transmission.<sup>33–35</sup> The tensile strength of fibrin glue–assisted anastomosis is shown to be less than that of conventional anastomosis, which may result in high aneurysm formation rates.<sup>36,37</sup> On the other hand, Isogai et al<sup>9</sup> proved fibrin glue to be efficient to prevent vascular leak in the dopamine-induced hypertensive rats with high arterial pressure rates up to 250 mm Hg. At this point, combination of least possible number of sutures and fibrin glue application appears to obtain optimal results.<sup>8</sup> We used 2 stay-sutures to provide adequate initial strength and observed aneurysm formation at 1 case in the experimental group on the 21st day. Comparing statistically, these data do not reveal any significant difference with the control group. Yet, further studies can provide more detailed information on the relation of aneurysm formation and fibrin glue application in the long term.

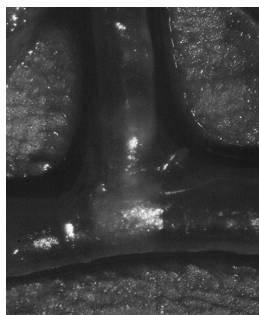


FIGURE 4. End-to-side anastomosis with fish-mouth incision and 2 sutures at the 21st day.

TABLE 2. Patency Rates and Statistical Comparison of the Subgroups

	Patency	Conventional Anastomosis	Experimental Anastomosis	P
3rd day	Patent	8 (100%)	7 (87.5%)	0.302
	Thrombosed	0 (0%)	1 (12.5%)	
7th day	Patent	8 (100%)	8 (100%)	1
	Thrombosed	0 (0%)	0 (0%)	
14th day	Patent	7 (87.5%)	8 (100%)	0.302
	Thrombosed	1 (12.5%)	0 (0%)	
21st day	Patent	8 (100%)	7 (87.5%)	0.302
	Thrombosed	0 (0%)	1 (12.5%)	

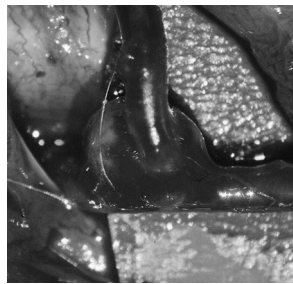


FIGURE 5. Aneurysm formation at the 21st day in the experimental group.

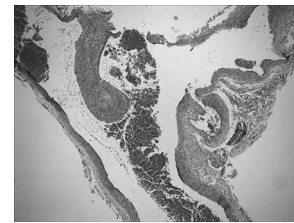


FIGURE 6. Longitudinal section of the carotid artery 21 days after surgery in the experimental group (hematoxylin-eosin stain, original magnification  $\times 40$ ). Re-epithelialization and an open lumen without any evidence of fibrin plugs were noted.

The vascular patency rates were very similar between the experiment and control groups in our study. Our results confirm several previous studies proving there is no increased thrombogenicity with fibrin glue application in microvascular anastomosis.<sup>8</sup>

By mimicking the last steps of the coagulation cascade, thrombogenicity is intentionally induced by fibrin adhesives, to prevent any leakage and hemorrhage at the lumen periphery. On the other hand, leakage of the fibrin adhesive into the lumen is responsible for vascular failure.<sup>38</sup> Regarding the controversy, temporary sutures are among the techniques advised to prevent fibrin leakage into the lumen.<sup>39</sup> While fibrin glue is used to reduce the number of sutures in conventional microvascular anastomosis, the possibility of having open spaces between the sutures is inversely correlated with the number of sutures. With fish-mouth incisions for end-to-side anastomosis, arteriotomy edges are covered, without leaving behind any open space between the lumen and the periphery. Unique structural feature of this technique may attribute to the results in our opinion.

Fibrin glue application theoretically has a potential of disease transmission such as HIV, hepatitis B, hepatitis C, Epstein-Barr virus, and parvovirus B19.<sup>40</sup> More than 1 million of disease-free fibrin glue applications prove it as a safe procedure so far.<sup>41</sup>

Another issue to mention is the additional cost of fibrin glue in short terms. Apparently, fibrin glue application may particularly benefit the costs when multiple sutures are to be performed. Yet, cost-benefit analysis of fibrin glue application is subject to another study.

In conclusion, with fish-mouth incision and fibrin glue application, we managed to complete end-to-side anastomosis in an easier, faster way. This technique may be evaluated as a noteworthy experimental technique, which is relatively easy to learn, and there is no need for any special devices or instruments. Fibrin adhesives are commercially available and already in use for many clinical settings.

Further clinical investigations may be followed by widespread application of fibrin adhesives in a variety of microvascular anastomosis techniques.

REFERENCES

1. Godina M. Preferential use of end-to-side anastomoses in free flap transfers. *Plast Reconstr Surg* 1979;64:673–682
2. Suominen S, Asko-Seljavaara S. Free-flap failures. *Microsurgery* 1995;16:396–399
3. Basu S, Wang S, Robertazzi R. In vitro bursting strength studies of laser-welded tissue and comparison with conventional anastomosis. *J Vasc Surg* 1988;7:420–422
4. Acland RD, Trachtenberg L. The histopathology of small arteries following experimental microvascular anastomosis. *Plast Reconstr Surg* 1977;60:868–875
5. Matras H. Fibrin seal: the state of the art. *J Oral Maxillofac Surg* 1985;43:605–611
6. Gestring GF, Lerner R, Requena R. The sutureless microanastomosis. *Vasc Endovascular Surg* 1983;17:364–367
7. Padubidri AN, Browne E, Kononov A. Fibrin glue-assisted end-to-side anastomosis of rat femoral vessels: comparison with conventional suture method. *Ann Plast Surg* 1996;37:41–47
8. Cho AB, Junior RM. Effect of fibrin adhesive application in microvascular anastomosis: a comparative experimental study. *Plast Reconstr Surg* 2007;119:95–103
9. Isogai N, Fukunishi K, Kamiishi H. Use of fibrin glues to minimize bleeding of microvascular repairs in hypertensive rats. *Microsurgery* 1992;13:321–324
10. Padubidri AN, Browne E. A new method of applying fibrin glue at the microvascular anastomotic site: the “paintbrush” technique. *Microsurgery* 1996;17:428–430
11. Cho AB, Júnior RM. Application of fibrin glue in microvascular anastomoses: comparative analysis with the conventional suture technique using a free flap model. *Microsurgery* 2009;29:80–81
12. Dotson RJN, Bishop AT, Wood MB. End-to-end versus end-to-side arterial anastomosis patency in microvascular surgery. *Microsurgery* 1998;18:125–128
13. Acland RD. *Microsurgical Practice Manual*. St Louis, MO: CV Mosby, 1980:86–99
14. Baş L, May JW, Handren J. End-to-end versus end-to-side microvascular anastomosis patency in experimental venous repairs. *Plast Reconstr Surg* 1986;77:442–450
15. Albertango JB, Rodriguez A, Buncke HJ. A comparative study of flap survival rates in end-to-end and end-to-side microvascular anastomosis. *Plast Reconstr Surg* 1981;67:194–199
16. Samaha FJ, Oliva A, Buncke GM. A clinical study of end-to-end versus end-to-side techniques for microvascular anastomosis. *Plast Reconstr Surg* 1997;99:1109–1111
17. Okazaki M, Asato H, Sarukawa S, et al. Availability of end-to-side arterial anastomosis to the external carotid artery using short-thread double-needle microsuture in free-flap transfer for head and neck reconstruction. *Ann Plast Surg* 2006;56:171–175

TABLE 3. Aneurysm Formation Rates and Statistical Comparison of the Subgroups

	Clinical Assessment	Conventional Anastomosis	Experimental Anastomosis	P
3rd day	Normal	8 (100%)	8 (100%)	1
	Aneurysm	0 (0%)	0 (0%)	
7th day	Normal	8 (100%)	8 (100%)	1
	Aneurysm	0 (0%)	0 (0%)	
14th day	Normal	8 (100%)	8 (100%)	1
	Aneurysm	0 (0%)	0 (0%)	
21st day	Normal	8 (100%)	7 (87.5%)	0.302
	Aneurysm	0 (0%)	1 (12.5%)	

18. Harashina T. Use of a continuous suture for back wall repair of end-to-end or end-to-side anastomoses. *Plast Reconstr Surg* 1982;69:139–144
19. Ragnarsson R, Berggren A, Ostrup LT, et al. Arterial end-to-side anastomosis with the UNILINK system. *Ann Plast Surg* 1989;22:405–415
20. Kirsch WM, Gupta S, Zhu YH. Sutureless vascular anastomosis: the VCS clip. *Cardiovasc Surg* 2001;9:523–525
21. Zeebregts C, Acosta R, Bölander L, et al. Clinical experience with non-penetrating vascular clips in free-flap reconstructions. *Br J Plast Surg* 2002;55:105–110
22. Karamürsel S, Kayıkçıoğlu A, Şafak T. End-to-side microvascular anastomosis using an external metal ring. *Br J Plast Surg* 2000;53:423–426
23. Sartorius CJ, Shapiro SA, Campbell RL, et al. Experimental laser-assisted end-to-side microvascular anastomosis. *Microsurgery* 1986;7:79–83
24. Tulleken CA, Verdaasdonk RM, Mansvelt Beck HJ. Nonocclusive Excimer laser-assisted end-to-side anastomosis. *Ann Thorac Surg* 1997;63:138–142
25. Ruiz-Razura A, Lan M, Cohen BE. The laser-assisted end-to-side microvascular anastomosis. *Plast Reconstr Surg* 1989;83:511–517
26. Harashina T, Irigaray A. Expansion of smaller vessel diameter by fish mouth incision in microvascular anastomosis with marked size discrepancy. *Plast Reconstr Surg* 1980;65:502–503
27. Turan T, Özçelik D, Kuran I, et al. Eversion with four sutures: an easy, fast, and reliable technique for microvascular anastomosis. *Plast Reconstr Surg* 2001;107:463–470
28. Telliöğlu AT. En-on-side microvascular anastomosis: an experimental study. *Ann Plast Surg* 1997;39:117
29. Egemen O, Ugurlu K, Ozkaya O, et al. Anastomosis with fish-mouth technique using fibrin glue. *J Craniofac Surg* 2011;22:1047–1051
30. Matras H, Chiari F, Kletter G. Zur klebung kleinster gefäße im tierversuch. *Dtsch Mund Kiefer Gesichtschir* 1977;1:19
31. Isogai N, Cooley BC, Kamiishi H. Clinical outcome of digital replantation using the fibrin glue-assisted microvascular anastomosis technique. *J Hand Surg (Br)* 1996;21:573
32. Han SK, Kim SW, Kim WK. Microvascular anastomosis with minimal suture and fibrin glue: experimental and clinical study. *Microsurgery* 1998;18:306
33. Sagi A, Yu HL, Ferder M, et al. “No suture” microanastomosis using Vicryl rings and fibrin adhesive system: an unsuccessful attempt. *Plast Reconstr Surg* 1987;79:776
34. Dascombe WH, Dumanian G, Hong C, et al. Application of thrombin based fibrin glue and non-thrombin based batroxobin glue on intact human blood vessels: evidence for transmural thrombin activity. *Thromb Haemost* 1997;78:947–951
35. Marek CA, Amiss LR Jr, Morgan RF, et al. Acute thrombogenic effects of fibrin sealant on microvascular anastomoses in a rat model. *Ann Plast Surg* 1998;41:415–419
36. Flahiff C, Feldman D, Saltz R, et al. Mechanical properties of fibrin adhesives for blood vessel anastomosis. *J Biomed Mater Res* 1992;26:481
37. Maxwell GP, Szabo Z, Buncke HJ Jr. Aneurysms after microvascular anastomoses. Incidence and pathogenesis in experimental animals. *Plast Reconstr Surg* 1979;63:824–829
38. Lemaire D, Mongeau J, Dorion D. Microvascular anastomosis using histoacryl glue and an intravascular soluble stent. *J Otolaryngol* 2000;29:199–205
39. Bowen CV, Leach DH, Crosby NL, et al. Microvascular anastomoses. A comparative study of fibrinogen adhesive and interrupted suture techniques. *Plast Reconstr Surg* 1996;97:792
40. Lee MG, Jones D. Applications of fibrin sealant in surgery. *Surg Innov* 2005;12:203–213
41. Currie LJ, Sharpe JR, Martin R. The use of fibrin glue in skin grafts and tissue-engineered skin replacements: a review. *Plast Reconstr Surg* 2001;108:1713–1726