

# Effects of montelukast sodium on tendon healing: An experimental study

Atilla Polat, Mehmet Kerem Canbora, Dilek Akakin<sup>1</sup>, Faruk Aykanat

## ABSTRACT

**Introduction:** Montelukast sodium (MS) a selective leukotriene antagonist of the cysteinyl leukotriene receptor, has been used in the treatment of asthma and allergic rhinitis. In this study, we evaluated the effect of MS on the early inflammatory phase (histological) of nonsynovial tendon healing.

**Materials and Methods:** Rats were divided randomly into two groups ( $n = 6$  each). MS (Singulair) was administered to one group at 10 mg/kg/day [250 g/day intraperitoneally (i.p.)]. The control group was administered 250 g/day of 0.9% saline i.p. This nonsynovial tendon was longitudinally divided at the midportion, cut transversely and then sutured. In both groups, the rats were sacrificed by decapitation 10 days later.

**Results:** Decreased inflammatory cell infiltration and more properly oriented collagen fibres were observed in the MS group's histopathological specimens as compared to the control group's ( $P < 0.05$ ). Additionally, vascularity was decreased in the MS group.

**Conclusion:** MS decreased tendon healing, apparently by inhibiting the early inflammatory phase of nonsynovial tendon healing.

**Key words:** Achilles tendon, montelukast, rats, tendon

## INTRODUCTION

Montelukast sodium (MS) is a potent, selective antagonist of the cysteinyl leukotriene (CysLT1) receptor and is under investigation for the treatment of bronchial asthma and allergic rhinitis, which are chronic inflammatory disease that affect people worldwide. MS is the drug used for longer periods or lifelong. Their healing effects on patients with tendon injury and fractures have been investigated by many authors. In this study, we investigated the effect of MS on the acute inflammatory phase of tendon healing in injured tendon. The three main stages of tendon healing are inflammation, repair or proliferation and remodeling. We focused on the inflammatory phase of tendon healing because MS is thought to affect only this phase, which lasts approximately 10 days.<sup>1-4</sup>

Some drugs have negative effects on tendon healing, particularly (NSAIDs).<sup>5</sup> In clinical practice; the treatment of common nonsynovial tendon injuries and asthmatic patients with NSAIDs must consider the effects of MS. Although they do not produce CysLTs, neutrophils do possess receptors for LTC<sub>4</sub> and LTD<sub>4</sub>, the activation of which triggers relatively modest pro-inflammatory responses in these cells. Interference with neutrophil activation by CysLTs released from other cell types, such as monocytes and macrophages, mast cells or eosinophils, may therefore underlie the neutrophil-directed therapeutic efficacy of MS.<sup>6,7</sup> In this study, we evaluated the effects of MS on the inflammatory phase of tendon healing in a rat model.

## MATERIALS AND METHODS

This study was approved by local ethics committee and was conducted at the Marmara University Experimental Research and Animal Laboratory.

CysLTs are potent mediators involved in various inflammatory diseases as well as lung disorders such as asthma. MS functions as a CysLT inhibitor during the inflammatory phase of tendon healing, resulting in delayed healing of an injured tendon.<sup>8</sup> Thus, healing of an injured tendon was evaluated histologically in the inflammatory phase. Twelve 6-month old male Sprague–Dawley rats with mean weight of 220 g were included in this study. For anesthesia, the rats received 15 mg/100 g intraperitoneal

Haydarpaşa Numune Research and Educational Hospital, <sup>1</sup>Marmara University Medical Faculty, İstanbul-Turkey

**Address for correspondence:** Dr. Atilla Polat, Haydarpaşa Numune Research and Educational Hospital, İstanbul/Turkey. E-mail: dr.atillapolat@hotmail.com

Access this article online	
Quick Response Code:	Website: www.ijoonline.com
	DOI: 10.4103/0019-5413.118207

(i.p.) ketamine. All the rats underwent full-thickness surgical incision of the Achilles tendon followed by primary repair. A mid longitudinal posterior 10 mm incision was made more than 4 mm proximal to the right. Achilles tendon insertion point of each rat, exposing the Achilles tendon [Figure 1a]. This nonsynovial tendon was longitudinally divided at the midportion in two halves. One half of longitudinally divided tendon was cut transversely and then sutured (synthetic absorbable suture) [Figure 1b]. The skin was also sutured (with 3-0 polyglactine) and the dressing was changed daily. No antibiotic was used for infection prophylaxis.

The 12 rats were divided randomly into two groups ( $n = 6$  each). The recommended dose of MS 10 mg/kg/day, which is that used in humans.<sup>9</sup> MS (Singulair) was administered to the MS group at 10 mg/kg/day (1 ml/100 g animal body weight). The drug was diluted with 2.5 ml of 0.9% saline and administered (i.p.) 1 cm to the left side of the umbilicus. Rats in the control group were administered only 2.5 ml of 0.9% saline (as placebo) similarly. The first dose was administered on the first postoperative day and the dosage was continued until sacrifice.

The two groups were kept in separate cages. The rats had access to standard rat chow and water *ad libitum*. In both groups, all six rats were sacrificed by decapitation 10 days later. The skin suture was reopened and the tendon was cut 5 mm above and 5 mm below the tendon suture site [Figure 1b]. Horizontal and longitudinal sections through the sutured region were obtained.

### Histopathological analysis

The excised tendons from the rats were fixed in 10% neutral buffered formalin overnight and then dehydrated through

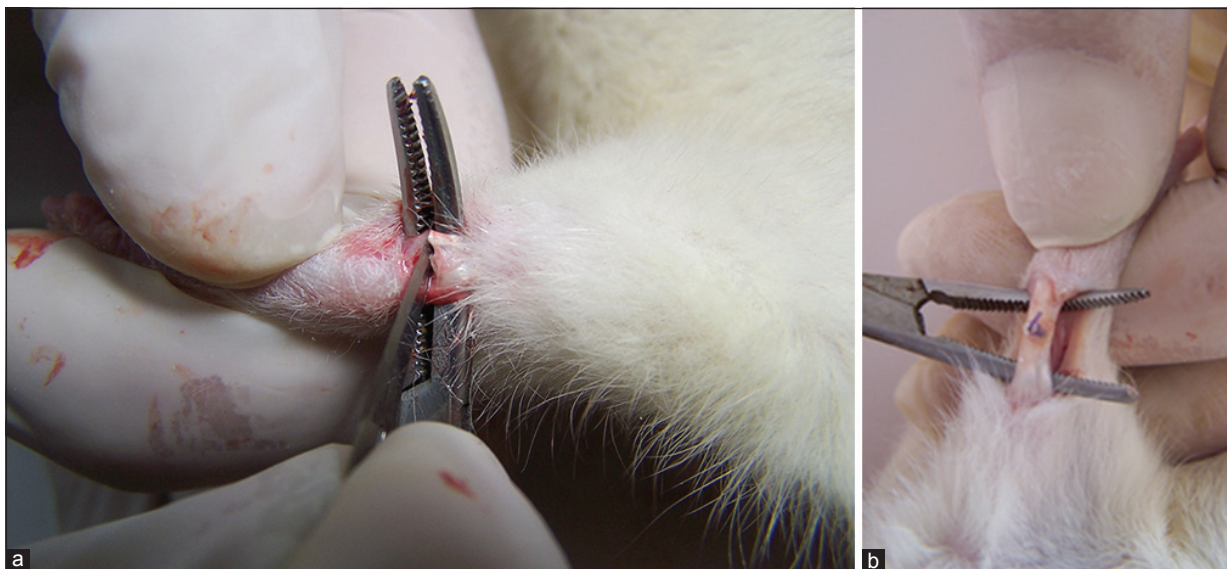
an alcohol solution. The fixed tissues were next processed and embedded in paraffin. Sections that were 5- $\mu$  m thick were obtained using a standard rotary microtome and then were stained with hematoxylin and eosin according to standard protocols. Finally, Achilles tendons sections were examined by light microscopy (Olympus BX51, Tokyo, Japan).

For the histopathological analysis, each group was evaluated for the following features; 1-inflammatory cell infiltration, 2-hemorrhage, 3-collagen fibre orientation and 4-vascularity in the inflammatory phase. Each item was graded by a single histologist without the knowledge of the specimen group according to a semi-quantitative approach as follow; absent (0), mild (1), moderate (2), moderate to severe (3) and severe (4). Statistical analysis was performed using the Chi-squared test. A  $P$  value less than 0.05 was deemed to indicate statistical significance.

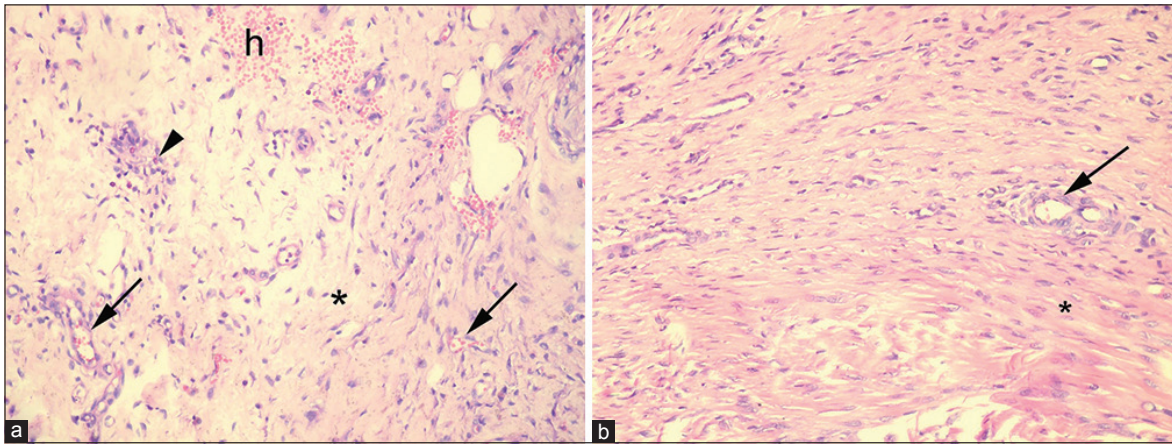
### RESULTS

Histopathological examination of the tissue sections revealed inflammatory cell infiltration, haemorrhage, disorganised collagen fibre orientation and increased vascularity in the control group [Figure 2a]. Decreased inflammatory cell infiltration and more properly oriented collagen fibres were observed in the MS group compared with the control group [Figure 2b]. Vascularity was also somewhat decreased in the MS group.

The differences between the control and study groups regarding inflammatory cell infiltration and collagen fibre orientation were statistically significant ( $P < 0.05$ ) [Tables 1 and 2].



**Figure 1:** Peroperative clinical photographs showing (a) Partial tenotomy was performed before the initiating by montelukast sodium. (b) Ends of tendon was repaired with a single suture



**Figure 2:** Histopathological sections showing (a) Control group. Increased vascularity (arrows), perivascular inflammatory cell infiltration (arrowhead), hemorrhage (h) and disorganised collagen fibre (\*). Montelukast group. (b) Decreased inflammatory cell infiltration, more properly oriented collagen fibre (\*) and somewhat decreased vascularity (arrow). (Hematoxylin and Eosin stain.  $\times 200$ , original magnification)

**Table 1: Histopathological analysis of injured rat Achilles tendons in the montelukast group**

	Inflammatory cell infiltration	Haemorrhage	Collagen fibre orientation	Vascularity in the inflammatory phase
1-MG	0	3	3	2
2-MG	1	4	4	3
3-MG	1	2	4	1
4-MG	0	3	3	3
5-MG	1	4	4	4
6-MG	0	3	4	2

**Table 2: Histopathological analysis of injured rat Achilles tendons in the control group**

	Inflammatory cell infiltration	Haemorrhage	Collagen fibre orientation	Vascularity in the inflammatory phase
1-CG	4	3	2	4
2-CG	4	4	1	4
3-CG	3	4	0	4
4-CG	4	2	1	4
5-CG	4	3	0	4
6-CG	3	4	1	4

## DISCUSSION

NSAIDs have been shown to have a negative effect on tendon healing in the early proliferative phase, but could be beneficial during the remodelling phase when inflammation might impede healing.<sup>10</sup> A significantly lower tensile strength was found in rats administered both parecoxib and indomethacin compared with the control group. Both parecoxib and indomethacin impaired tendon healing; however, the negative effect was most pronounced with parecoxib.<sup>11</sup> Leukotriene receptor antagonists, such as MS, are currently being used to treat rhinitis and asthma; however, their anti-inflammatory role is not well understood.

We investigated whether MS, a selective leukotriene antagonist, had a negative effect on tendon healing and found this to be the case. Although leukotrienes have been conventionally viewed as paracrine mediators of inflammatory disease processes, such as in asthma, more recent information suggests that they are also important participants in disease processes characterized by cellular proliferation and fibrogenesis. Indeed, MS is a potent, CysLT1 receptor antagonist that has a negative effect on tendon healing.<sup>12</sup>

In this study, we evaluated the inflammatory phase of tendon healing. In the initial inflammatory phase, which lasts about 24 h, erythrocytes, platelets and inflammatory cells, such as neutrophils, monocytes and macrophages, migrate to the wound site and eradicate necrotic materials by phagocytosis. Simultaneously, vasoactive and chemotactic factors are released that recruit tendon fibroblasts to begin collagen synthesis and deposition. Nevertheless MS has a significant and progressive inhibitory effect on collagen maturation.<sup>13,14</sup>

We found decreased inflammatory cell infiltration and more properly oriented collagen fibres in the MS group compared with the control group. Vascularity was also somewhat decreased in the montelukast group. The cause of the increase in properly oriented collagen fibre was likely that inactivity markedly decreased collagen turnover. Training leads to a chronically increased collagen turnover and to some degree, depending on the type of collagen, net collagen synthesis.<sup>15</sup> We believe that collagen fibre turnover does not depend on inflammatory situation as well as rats activity because of the remaining intact portion of the tendon.

Yuan *et al.* found that leukotriene D4 stimulated the

migration, but not the proliferation, of endothelial cells, mediated by the CysLT1 receptor and the extracellular signal-regulated kinase (ERK) pathway. This migration was inhibited by MS as a leukotriene receptor antagonist and the ERK1/2 inhibitor UO126.<sup>16</sup>

Ogasawara *et al.* using *in situ* hybridization demonstrated for the first time that mCysLT1 and mCysLT2 were expressed in subcutaneous fibroblasts.<sup>17</sup> Tolazzi *et al.* in their study of 60 rats, showed that MS did not alter the contraction rate of excisional wounds but had a significant and progressively inhibitory effect on collagen maturation.<sup>14</sup> In an investigation of collagen production, a recent *in vitro* study revealed that mast cells express the CysLT1 receptor, human tumour necrosis factor- $\alpha$  (TNF- $\alpha$ ) production by mast cells was increased by incubation with CysLT1 and the latter increase was significantly suppressed by treatment with a selective CysLT1 receptor antagonist, MK571. Thus, because CysLT1 receptor antagonists inhibit TNF- $\alpha$  production by mast cells in the synovium, they may attenuate the development of collagen-induced arthritis in mice. To test this and to further examine the role of mast cells in the pathogenesis of arthritis, the therapeutic effects of a selective CysLT1 receptor antagonist (MS) were assessed in the development of collagen-induced arthritis in mice.<sup>18</sup>

Cyclic stretching of human tendon fibroblasts increases the production of PgE<sub>2</sub> and LTB<sub>4</sub>. Blocking PgE<sub>2</sub> production leads to increased leukotriene B (4) levels and vice versa. It was found that the use of NSAIDs may increase the levels of leukotriene B (4), thus potentially contributing to the development of tendinosis.<sup>19</sup> Çakıcı *et al.*<sup>20</sup> investigated the effects of the leukotriene receptor antagonist MS on histological, radiological and densitometric parameters of fracture healing. No significant differences were found between the two groups regarding any parameter evaluated at either time interval ( $P > 0.05$ ).<sup>20</sup> Our study possessed some limitations. Most importantly, we examined only the effects of MS during the early inflammatory phase in a nonsynovial tendon and did not assess the biomechanical impact and effect of MS on synovial tendons.

To conclude, this study on rats, decreased inflammatory cell infiltration and more properly oriented collagen fibres were observed in the MS-treated group. Thus, MS decreases tendon healing by inhibiting the early inflammatory phase of the healing process. However, the long term effects of this drug on a healing need to be investigated in a biomechanical study.

## REFERENCES

- Balani SK, Xu X, Pratha V, Koss MA, Amin RD, Dufresne C, *et al.* Metabolic profiles of montelukast sodium (Singulair), a potent cysteinyl leukotriene 1 receptor antagonist, in human plasma and bile. *Drug Metab Dispos* 1997;25:1282-5.
- Jones TR, Labelle M, Belley M, Champion E, Charette L, Evans J, *et al.* Pharmacology of montelukast sodium (Singulair), a potent and selective leukotriene D4 receptor antagonist. *Can J Physiol Pharmacol* 1995;73:191-210.
- Aharony D. Pharmacology of leukotriene receptor antagonists. *Am J Respir Crit Care Med* 1998;157:214-5.
- O'Byrne PM. Asthma treatment: Antileukotriene drugs. *Can Respir J* 1998;5 Suppl A: 64A-70A.
- Larfars G, Lantoin F, Devynck MA, Palmblad J, Gyllenhammar H. Activation of nitric oxide release and oxidative metabolism by leukotrienes B4, C4 and D4 in human polymorphonuclear leukocytes. *Blood* 1999;93:1399-405.
- Zhu J, Qiu YS, Figueroa DJ, Bandi V, Galczenski H, Hamada K, *et al.* Localization and upregulation of cysteinyl leukotriene-1 receptor in asthmatic bronchial mucosa. *Am J Respir Cell Mol Biol* 2005;33:531-40.
- Anderson R, Theron AJ, Gravett CM, Steel HC, Tintinger GR, Feldman C. Montelukast inhibits neutrophil pro-inflammatory activity by a cyclic AMP-dependent mechanism. *Br J Pharmacol* 2009;156:105-15.
- Peters SP, Anthonisen N, Castro M, Holbrook JT, Irvin CG, Smith LJ, *et al.* American Lung Association Asthma Clinical Research Centers. Randomized comparison of strategies for reducing treatment in mild persistent asthma. *N Engl J Med* 2007;356:2027-39.
- Turtay MG, Firat C, Samdanci E, Oguzturk H, Erbatur S, Colak C. Effect of montelukast on burn wound healing in rat model. *Clin Invest Med* 2010;33:E413-21.
- Cohen DB, Kawamura S, Ehteshami JR, Rodeo SA. Indomethacin and celecoxib impair rotator cuff tendon-to-bone healing. *Am J Sports Med* 2005;34:362-9.
- Dimmen S, Engebretsen L, Nordsletten L, Madsen JE. Negative effects of parecoxib and indomethacin on tendon healing: An experimental study in rats. *Knee Surg Sports Traumatol Arthrosc* 2009;17:835-9.
- Funk L. Tendon healing mechanobiology. [derdoc.co.uk web site]. Lennard Funk 2007. Medline.info@shoulderdoc.co.uk.
- Golden MP and Brock TG. Intracellular compartmentalization of leukotriene biosynthesis. *Am J Respir Crit Care Med* 2000;161:36-44.
- Tolazzi AR, Tolazzi KD, Garcia M, Graf RM, Freitas RS, Baretta GA, *et al.* Influence of leukotriene inhibitor montelukast on wound contraction and cutaneous healing process in rats. *Aesthetic Plast Surg* 2009;33:84-5.
- Kjaer M, Langberg H, Miller BF, Boushel R, Cramer R, Koskinen S, *et al.* Metabolic activity and collagen turnover in human tendon in response to physical activity. *J Musculoskelet Neuronal Interact* 2005;5:41-52.
- Yuan YM, Fang SH, Qian XD, Liu LY, Xu LH, Shi WZ, *et al.* Leukotriene D (4) stimulates the migration but not proliferation of endothelial cells mediated by the cysteinyl leukotriene CysLT (1) receptor via the extracellular signal-regulated kinase pathway. *J Pharmacol Sci* 2002;109:285-7.
- Ogasawara H, Ishii S, Yokomizo T, Kakinuma T, Komine M, Tamaki K, *et al.* Characterization of mouse cysteinyl leukotriene receptors mCysLT1 and mCysLT2. Differential pharmacological properties and tissue distribution. *J Biol Chem* 2002;277:18763-5.
- Dighe NS, Pattan SR, Merekar AN, Dighe SB, Chavan PA, Musmade DS, *et al.* Leucotrienes and biological activities: A

- review. *J Chem Pharm Res* 2010;2:338-410.
19. Li Z, Yang G, Khan M, Stone D, Woo SL, Wang JH. Inflammatory response of human tendon fibroblasts to cyclic mechanical stretching. *Am J Sports Med* 2004;32:435-40.
  20. Çakıcı H, Hapa O, Gideroğlu K, Öcturan K, Güven M, Yüksel HY, *et al.* The effects of leukotriene receptor antagonist montelukast on histological, radiological and densitometric

parameters of fracture healing. *Eklemler Hastalıkları Cerrahisi* 2011;22:43-7.

**How to cite this article:** Polat A, Canbora MK, Akakin D, Aykanat F. Effects of montelukast sodium on tendon healing: An experimental study. *Indian J Orthop* 2013;47:500-4.

**Source of Support:** Nil, **Conflict of Interest:** None.

#### Announcement

#### Android App



Download  
**Android  
application**

FREE

A free application to browse and search the journal's content is now available for Android based mobiles and devices. The application provides "Table of Contents" of the latest issues, which are stored on the device for future offline browsing. Internet connection is required to access the back issues and search facility. The application is compatible with all the versions of Android. The application can be downloaded from <https://market.android.com/details?id=comm.app.medknow>. For suggestions and comments do write back to us.

Copyright of Indian Journal of Orthopaedics is the property of Medknow Publications & Media Pvt. Ltd. and its content may not be copied or emailed to multiple sites or posted to a listserv without the copyright holder's express written permission. However, users may print, download, or email articles for individual use.