

# First Patient Diagnosed as Feingold Syndrome Type 2 with Alport Syndrome and Review of the Current Literature

Şenol Demir Mehmet A. Söylemez Ahmet Arman Pınar Ata

Department of Medical Genetics, School of Medicine, Marmara University, Istanbul, Turkey

## Established Facts

- Feingold syndrome type 2 (FGLDS2) is characterized by short stature, skeletal abnormalities, brachydactyly, microcephaly, and moderate to severe varying intellectual disabilities.
- FGLDS2 is caused by haploinsufficiency of the *MIR17HG* gene.
- Alport syndrome has a clinical picture with proteinuria and hematuria due to defective synthesis of COL4A3, COL4A4, and COL4A5 proteins forming glomerular basement membrane.

## Novel Insights

- Herein, we present the first case of FGLDS2 in a patient with hematuria and proteinuria that is due to the coexistence of Alport syndrome.
- The patient is the first to be presented with FGLDS2 in the Turkish population.

## Keywords

Feingold syndrome type 2 · *MIR17HG* · Hematuria · Proteinuria · *COL4A5*

## Abstract

**Introduction:** Feingold syndrome type 2 (FGLDS2) is an ultra-rare genetic disorder characterized by short stature, microcephaly, digital abnormalities, and intellectual disability. Until now, 22 patients have been reported in the literature. FGLDS2 is caused by a germline heterozygous deletion of 13q resulting in haploinsufficiency of the *MIR17HG* gene.

**Case report:** In the present study, we evaluated clinical, radiological, and genetic analyses of a 10-year-old Turkish-or-

igin girl with short stature, brachydactyly, intellectual disability, hematuria, and proteinuria. **Conclusion/Discussion:** In the array-CGH analysis, a 15.7-Mb deletion, arr[hg19] 13q22q31.3(78,241,132\_93,967,288)×1, was detected, and this alteration was evaluated to be pathogenic. The deletion of this region covering the *MIR17HG* gene is a potential cause of FGLDS2. Also, at her clinical exome sequencing study, a heterozygous c.2023G>A p.(Gly675Ser) variation was detected in the *COL4A5* gene (NM\_000495.4) that was likely pathogenic in up-to-date databases. As a result, we report on a patient who has FGLDS2 and Alport syndrome. This is the first report of a Turkish-origin FGLDS2 patient. Reporting new cases expands the range of phenotypes, plays a crucial role in understanding the FGLDS2 pathogenesis, and is im-

portant in terms of screening at-risk family members for giving appropriate genetic counseling and preimplantation genetic diagnosis opportunities.

© 2022 S. Karger AG, Basel

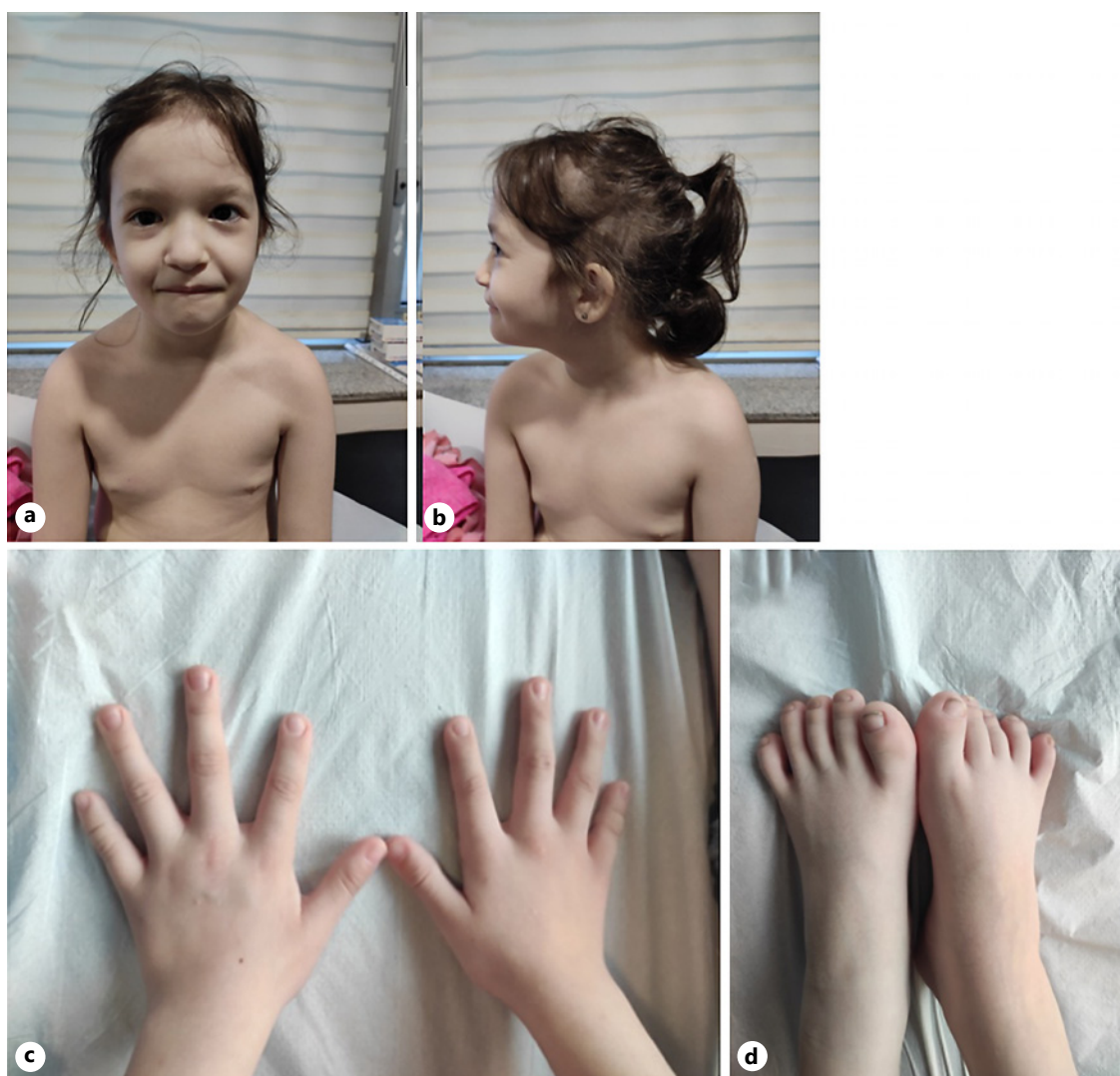
## Introduction

Feingold syndrome is an autosomal dominant genetic disorder, mostly affecting the skeletal system, causing abnormalities. Besides, intellectual disability, cardiovascular system findings, and gastrointestinal system involvement can also be observed. This syndrome has 2 subtypes:

Feingold syndrome type 1 (FGLDS1) is observed as a result of *MYCN* gene variations [van Bokhoven et al., 2005] that is localized at the 2p24 locus encoding N-myc [Chen et al., 2012].

Feingold syndrome type 2 (FGLDS 2) is caused by haploinsufficiency of the 13q region, spanning the *MIR17HG* gene [Sirchia et al., 2017] that encodes miR17-92 cluster containing 6 miRNA subgroups (miR17, miR18a, miR19a, miR19b1, miR20a, miR92) [de Pontual et al., 2011]. These are important in early embryogenesis, especially for the development of the skeletal system.

The phenotypic presentation of this syndrome is microcephaly, short stature, brachymesophalangia, thumb



**Fig. 1.** Clinical photos of the proband. **a, b** Facial dysmorphism. **c** Brachydactyly, clinodactyly, and brachymesophalangia of the bilateral 5th fingers. **d** Partial cutaneous syndactyly in the 2nd and 3rd fingers of the right foot and clinodactyly.

hypoplasia, toe syndactyly, and intellectual disability [Tassano et al., 2013]. The most important difference between FGLDS1 and FGLDS2 is gastrointestinal atresia which is unique for type 1 [Muriello et al., 2019].

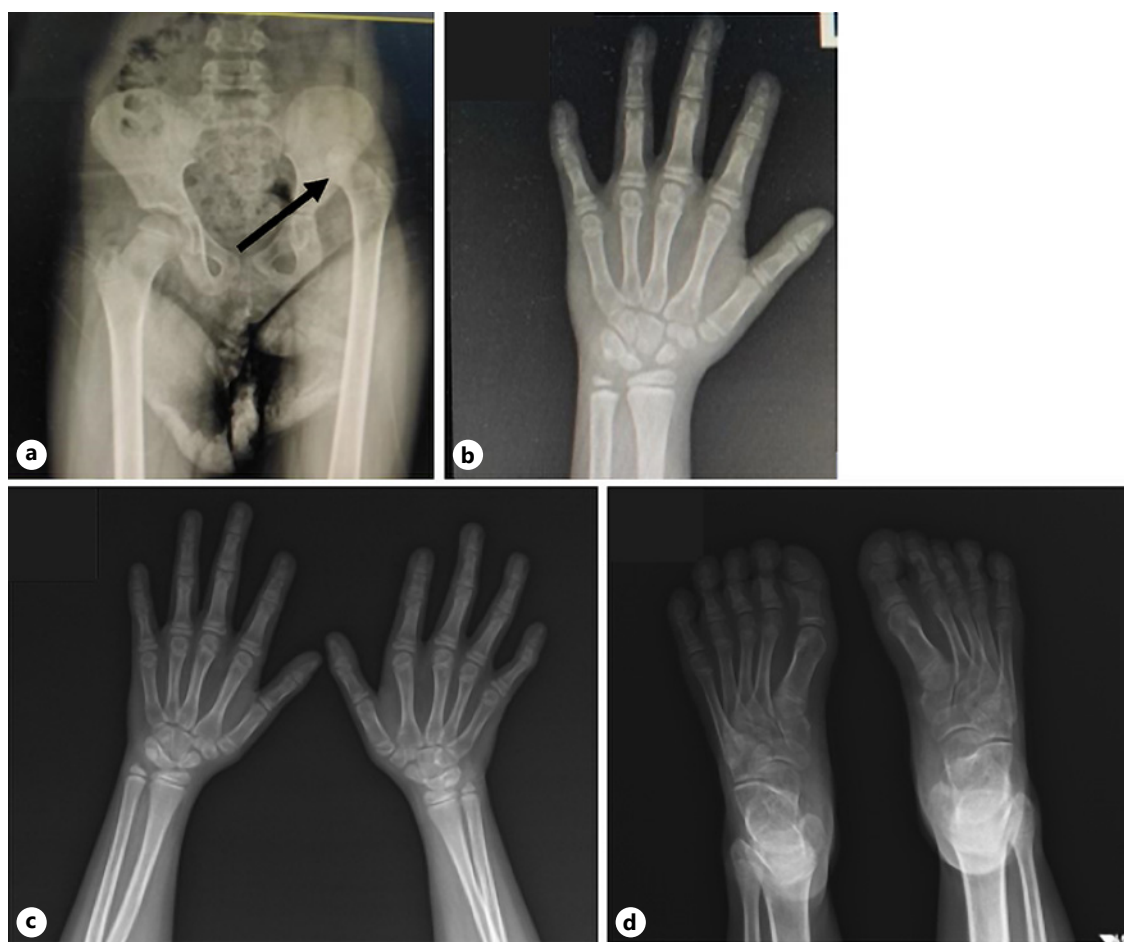
To our knowledge, there is no patient reported with 2 co-existent syndromes, and herein proteinuria and hematuria that are absent in FGLDS2 were noticeable clinical findings in our patient. We have further discussed clinical manifestations of our patient.

## Case Report

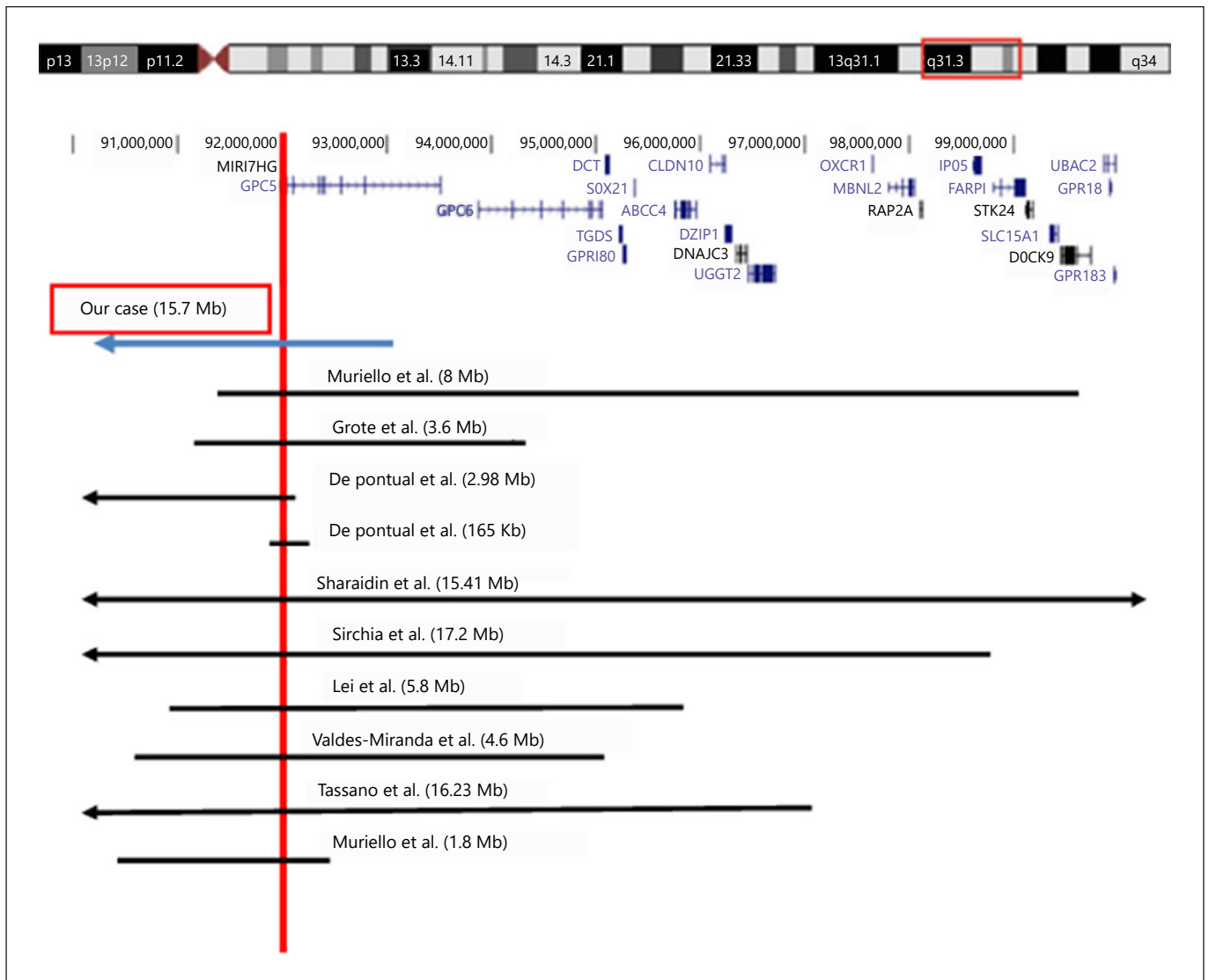
The proband is a 10-year-old girl who was born by normal vaginal delivery at 38 weeks of gestation. There is a first-degree cousin relationship between her parents. Although she did not have any complaints at the early postnatal period, her parents stated that her developmental milestones have been delayed; she started sitting at

the age of 1, walking at the age of 2, and used first sentences at the age of 4, respectively. She was admitted to the hospital when she was 5 years old due to growth retardation and hematuria. There were no abnormalities in her biochemical results but in her urinalysis hematuria and proteinuria were detected and vesicoureteral reflux was diagnosed in her voiding cystourethrography (VCUG). The patient was referred to our medical genetics clinic due to her growth retardation and renal function impairment. In anthropometric measurements, her height was 107 cm ( $-4.3$  SD), head circumference was 47 cm ( $-3.6$  SD), and body weight was 18 kilograms ( $-2.9$  SD).

Physical examination revealed microcephaly, prominent forehead, hypertelorism, nasal root flattening, upslanting palpebral fissure, anteverted nares, and long philtrum. Her mouth was wide with her narrow high palate and she had posteriorly rotated low set ears. Brachydactyly, which was affecting her both hands, was especially prominent in the 5th finger. The patient had bilateral partial cutaneous syndactyly in the 2nd and 3rd toes and had clinodactyly in the 4th and 5th toes (Fig. 1).



**Fig. 2.** Bone radiographic imaging. **a** The patient had an advanced stage developmental dysplasia of the hip with a very shallow left acetabulum and significant degeneration in the femoral head (indicated with an arrow). **b, c** Brachydactyly, brachymesophalangia, and clinodactyly in the fifth finger are observed in the radiograph of the hands. **d** Clinodactyly is observed in both toes.

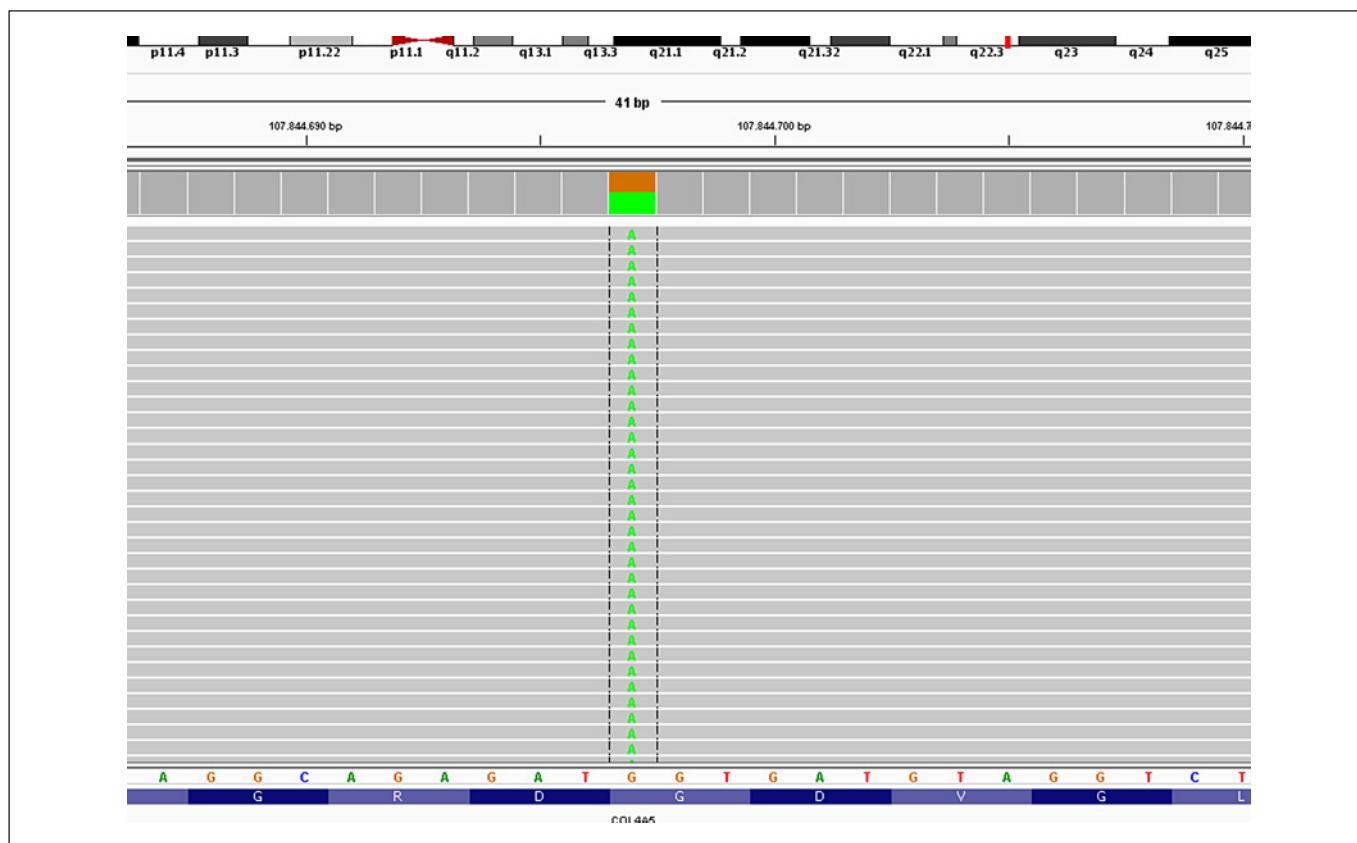

**Fig. 3.** Schematic representation and comparison of the deletion and genes in the region identified in our case with the patients in the literature.

Compared to her peers, she had severe retardation in the developmental test. Although she passed the hearing test, on eye examination amblyopia and myopia were detected. Cranial MR imaging, abdominal USG, echocardiography, and metabolic tests were normal. In her renal doppler USG, at the left kidney 11 × 7 mm sized focal caliectasis was detected. The bone radiography revealed brachydactyly in both hands and brachymesophalangia in the 5th finger. In addition, she had an advanced stage developmental dysplasia of the hip with a very shallow left acetabulum and significant degeneration of the femoral head so that the left femoral head was located 3 cm more proximal compared to the right (Fig. 2)

### Discussion and Conclusion

At her conventional cytogenetic G-band karyotype analysis, a deletion of the long arm of chromosome 13 was found. DNA sample isolated from peripheral blood was studied using Affymetrix Cytoscan Optima (315K) microarray system, and the results were analyzed using CHAS 3.2.0/GRCh 37/hg19 analysis program. In the array comparative genomic hybridization analysis, a deletion of 15.7 Mb in the 13q22q31.3 region was detected. This region covers the *MIR17HG* gene, and its heterozygous deletions are responsible for the FGLDS2 phenotype



**Fig. 4.** IGV Data image. A heterozygous c.2023G>A p.(Gly675ser) variation in the *COL4A5* gene was detected.

(Fig. 3). Confirming that the deletion was de novo, the parents had normal array-CGH results. Since her CGH findings did not clarify the patient's hematuria and proteinuria, she was further analyzed with next-generation sequencing (NGS) (Fig. 4). The obtained heterozygous c.2023G>A p.(Gly675Ser) variation (according to HGVS) in the *COL4A5* gene (NM\_000495.4) was defined as pathogenic at up-to-date analysis programs (Clinvar, Provan, SIFT). This variation is classified as likely pathogenic (PM2, PM1, PP2, PP3) at ACMG confirming its pathogenicity. The patient was diagnosed as having Alport syndrome additional to her Feingold phenotype, and segregation analysis revealed the same heterozygous *COL4A5* gene variation in her father.

Herein, we present a 10-year-old Turkish girl with a 15.7-Mb heterozygous deletion located in the 13q22q31 region. This deletion encompassed *MIR17HG*, *GPC5*, and *GPC6* genes. Previously reported FGLDS2 patients also had deletions of the *MIR17HG* gene. Thus *MIR17HG* appears to be the most likely disease-causing gene in this syndrome [de Pontual et al., 2011; Lei et al., 2021]. Until

now, 16 FGLDS2 patients (9 [56%] females, 7 [44%] males) have been reported in the literature (summarized in Table 1) [Firth et al., 2009; de Pontual et al., 2011; Sharaidin et al., 2013; Tassano et al., 2013; Ganjavi et al., 2014; Valdes-Miranda et al., 2014; Grote et al., 2015; Low et al., 2015; Sirchia et al., 2017; Muriello et al., 2019; Lei et al., 2021]. Although the sizes of the deleted regions were different, this gene was deleted in all the patients diagnosed with FGLDS2. The size of the deletion located at the 13q region in these patients varied between 165 kb and 17.2 Mb (Fig. 3) [de Pontual et al., 2011; Sirchia et al., 2017; Muriello et al., 2019].

The skeletal system is one of the most affected systems in FGLDS2. Particularly, short stature, microcephaly, 5th finger clinodactyly, and brachymesophalangia can be observed in these patients. It was reported that the *MIR17HG* gene is important for osteoblast proliferation and differentiation in mice [Zhou et al., 2014]. Another group reported that homozygous deletions of the *MIR17HG* gene in mice caused perinatal lethality, however, heterozygous deletions revealed skeletal developmental disorders and

**Table 1.** Comparison of our patient's clinical findings with DECIPHER and patients in the literature

Feature	Present study	DECIPHER cases	Literature	Total
Number of patients	1	6	16	23
Deletion size	15.7 Mb	180 kb–5.8 Mb	165 kb–17.2 Mb	165 kb–17.2 Mb
Gender	Female	3 female, 2 male, 1 NR	9 female, 7 male	13 female, 9 male, 1 NR
Intellectual disability	Yes	4/6 (2 NR)	15/16	20/23 (2 NR)
Microcephaly	Yes	4/6 (2 NR)	14/16	19/23 (2 NR)
Short stature	Yes	3/6 (3 NR)	13/16 (1 NR)	17/23 (3 NR)
Brachymesopthalangia	Yes	5/6 (1 NR)	16/16	22/23 (1 NR)
5th finger clinodactyly	Yes	2/6 (4 NR)	11/16 (5 NR)	14/23 (9 NR)
Toes anomalies	Partial cutaneous syndactyly	Syndactyly, 3/6 (3 NR)	10/16 (1 NR) Syndactyly (8) Brachydactyly (2)	14/23 (4 NR) Syndactyly (9) Brachydactyly (2)
Cardiac anomalies	No	1/6 (5 NR)	5/16 (2 NR)	6/23 (7 NR)
Hearing loss	No	6 NR	2/16 (9 NR)	2/23 (15 NR)
Proteinuria	Yes	6 NR	0/16	1/23 (6 NR)
Hematuria	Yes	0/6	0/16	1/23
Gastrointestinal atresia	No	0/6	0/16	0/23

NR, not reported.

brachymesopthalangia [de Pontual et al., 2011]. Brachymesopthalangia was seen in all of the previously reported patients (16/16), short stature in 81% (13/16), and 5th finger clinodactyly in 68% (11/16), respectively. Compared to those cases, our patient's skeletal developmental abnormalities were severe: short stature, brachydactyly in hands, 5th finger clinodactyly, and brachymesopthalangia that were present simultaneously (Fig. 1). Additionally, our case had severe developmental dislocation of the hip with acetabular degeneration that was detected at her X-ray radiography (Fig. 2).

The *COL4A5* gene variation detected in our patient has been associated with X-linked Alport syndrome (XLAS) [Barker et al., 1990; Tryggvason, 1996] that is characterized by hematuria, proteinuria, hearing loss, and ocular defects. In the extensive study of XLAS patients, 95% had hematuria, 75% proteinuria, 28% hearing loss, and 18% ocular defects [Jais et al., 2003]. While genotype-phenotype correlation was present in male XLAS patients, it was not obvious in XLAS females [Jais et al., 2000, 2003; Gross et al., 2002; Bekheirnia et al., 2010; Yamamura et al., 2017].

Along with *FGLDS2*, our patient had hematuria and proteinuria indicating renal dysfunction due to the presence of Alport syndrome, and these 2 syndromes have not been reported together in the literature so far. Although in a study impaired renal function was observed in mice due to *MIR17HG* gene inactivation and miRNAs regulatory function at the stage of nephrogenesis encoded by

*MIR17HG* [Marrone et al., 2014], this should be further evaluated with functional studies in our case.

So our patient's renal dysfunction could be due to the co-incident presence of the *COL4A5* gene variation. In conclusion, the case discussed here is the first reported case with co-incident Alport syndrome and *FGLDS2* covering their specific clinical presentations. It should be kept in mind that multiple syndromes can contribute to the phenotype in patients with complex genotypes.

### Acknowledgement

We thank the patient's parents for their kind participation and support.

### Statement of Ethics

This study was performed in accordance with the Declaration of Helsinki principles. Written informed consent was obtained from the patient's parents for the publication of this case report and accompanying images. As a result of the evaluation of the Ethics Committee of Marmara University, study approval statement was not required for this study in accordance with local/national guidelines.

### Conflict of Interest Statement

The authors have no conflicts of interest to declare.

## Funding Sources

There are no funding sources to report.

## Author Contributions

S.D. prepared the array-CGH analysis and the manuscript as well as the study. M.A.S. made the patient's physical examination. A.A. and P.A. critically reviewed the manuscript.

## Data Availability Statement

All data generated or analysed during this study are included in this. Further enquiries can be directed to the corresponding author.

## References

- Barker D, Hostikka S, Zhou J, Chow L, Oliphant A, Gerken S, et al. Identification of mutations in the COL4A5 collagen gene in Alport syndrome. *Science*. 1990;248(4960):1224–7.
- Bekheirnia MR, Reed B, Gregory MC, McFann K, Shamshirsaz AA, Masoumi A, et al. Genotype-phenotype correlation in X-linked Alport syndrome. *J Am Soc Nephrol*. 2010; 21(5):876–83.
- Chen C-P, Lin S-P, Chern S-R, Wu P-S, Chang S-D, Ng S-H, et al. A de novo 4.4-Mb microdeletion in 2p24.3--> p24.2 in a girl with bilateral hearing impairment, microcephaly, digit abnormalities and Feingold syndrome. *Eur J Med Genet*. 2012;55(11):666–9.
- de Pontual L, Yao E, Callier P, Faivre L, Drouin V, Cariou S, et al. Germline deletion of the miR-17 approximately 92 cluster causes skeletal and growth defects in humans. *Nat Genet*. 2011;43(10):1651026–1030.
- Firth HV, Richards SM, Bevan AP, Clayton S, Corpas M, Rajan D, et al. DECIPHER: Database of Chromosomal Imbalance and Phenotype in Humans Using Ensembl Resources. *Am J Hum Genet*. 2009;84(4):524–33.
- Ganjavi H, Siu VM, Speevak M, MacDonald PA. A fourth case of Feingold syndrome type 2: psychiatric presentation and management. *BMJ Case Rep*. 2014;2014:bcr2014207501.
- Gross O, Netzer KO, Lambrecht R, Seibold S, Weber M. Meta-analysis of genotype-phenotype correlation in X-linked Alport syndrome: impact on clinical counselling. *Nephrol Dial Transplant*. 2002;17(7):1218–27.
- Grote LE, Repnikova EA, Amudhavalli SM. Expanding the phenotype of feingold syndrome-2. *Am J Med Genet A*. 2015;167A(12): 3219–25.
- Jais JP, Knebelmann B, Giatras I, De Marchi M, Rizzoni G, Renieri A, et al. X-linked Alport syndrome: natural history and genotype-phenotype correlations in girls and women belonging to 195 families: a "European Community Alport Syndrome Concerted Action" study. *J Am Soc Nephrol*. 2003;14(10):2603–10.
- Jais JP, Knebelmann B, Giatras I, De Marchi M, Rizzoni G, Renieri A, et al. X-linked Alport syndrome: natural history in 195 families and genotype-phenotype correlations in males. *J Am Soc Nephrol*. 2000;11(4):649–57.
- Lei J, Han L, Huang Y, Long M, Zhao G, Yan S, et al. Feingold syndrome type 2 in a patient from China. *Am J Med Genet A*. 2021;185(7): 2262–6.
- Low KJ, Buxton CC, Newbury-Ecob RA. Tetralogy of Fallot, microcephaly, short stature and brachymesophalangy is associated with hemizygous loss of noncoding MIR17HG and coding GPC5. *Clin Dysmorphol*. 2015;24(3): 113–4.
- Marrone AK, Stolz DB, Bastacky SI, Kostka D, Bodnar AJ, Ho J. MicroRNA-17~92 is required for nephrogenesis and renal function. *J Am Soc Nephrol*. 2014;25(7):1440–52.
- Muriello M, Kim AY, Sondergaard Schatz K, Beck N, Gunay-Aygun M, Hoover-Fong JE. Growth hormone deficiency, aortic dilation, and neurocognitive issues in Feingold syndrome 2. *Am J Med Genet A*. 2019;179(3): 410–6.
- Sharaidin SH, Knipe S, Bain N, Goel H. Clinical features associated with a 15.41 Mb deletion of chromosome 13q encompassing the MIR17HG locus. *Clin Dysmorphol*. 2013; 22(2):68–70.
- Sirchia F, Di Gregorio E, Restagno G, Grosso E, Pappi P, Talarico F, et al. A case of Feingold type 2 syndrome associated with keratoconus refines keratoconus type 7 locus on chromosome 13q. *Eur J Med Genet*. 2017;60(4):224–7.
- Tassano E, Di Rocco M, Signa S, Gimelli G. De novo 13q31.1-q32.1 interstitial deletion encompassing the miR-17-92 cluster in a patient with Feingold syndrome-2. *Am J Med Genet A*. 2013;161A(4):894–6.
- Tryggvason K. Mutations in type IV collagen genes and Alport phenotypes. *Contrib Nephrol*. 1996;117:154–71.
- Valdes-Miranda JM, Soto-Alvarez JR, Toral-Lopez J, González-Huerta L, Perez-Cabrera A, Gonzalez-Monfil G, et al. A novel microdeletion involving the 13q31.3-q32.1 region in a patient with normal intelligence. *Eur J Med Genet*. 2014;57(2-3):60–4.
- Van Bokhoven H, Celli J, van Reeuwijk J, Rinne T, Glaudemans B, van Beusekom E, et al. MYCN haploinsufficiency is associated with reduced brain size and intestinal atresias in Feingold syndrome. *Nat Genet*. 2005;37(5): 465–7.
- Yamamura T, Nozu K, Fu XJ, Nozu Y, Ye MJ, Shono A, et al. Natural History and Genotype-Phenotype Correlation in Female X-Linked Alport Syndrome. *Kidney Int Rep*. 2017;2(5):850–5.
- Zhou M, Ma J, Chen S, Chen X, Yu X. MicroRNA-17-92 cluster regulates osteoblast proliferation and differentiation. *Endocrine*. 2014; 45(2):302–10.