






Original Article

Does Maxillary Protraction with Alt-RAMEC Protocol Affect Inferior Sclera Exposure? A Controlled 3dMD Study

Yasemin Bahar Acar , Hanife Nuray Yılmaz , Elvan Önem Özbilen 

Department of Orthodontics, Marmara University, Faculty of Dentistry, Istanbul, Turkey

Cite this article as: Acar YB, Yılmaz HN, Özbilen EÖ. Does maxillary protraction with Alt-RAMEC protocol affect inferior sclera exposure? A controlled 3dMD study. *Turk J Orthod.* 2022;35(1):1-6.

Main Points

- Sella-nasion-A point angle (SNA) increased in the study group. However, this increase was limited compared to many studies on alternate rapid maxillary expansions and constrictions in the literature.
- The ratio of S : E in percentage was calculated to standardize the sclera exposure relative to the overall eye height.
- The ratio of S : E in percentage decreased significantly in both study and control groups on right and left sides.
- Intergroup comparisons revealed that the increase in SNA was highly significant whereas the decrease in S : E ratio was not significant.

ABSTRACT

Objective: The purpose of this controlled retrospective study was to measure and evaluate the inferior sclera exposure changes using 3dMD stereophotogrammetric images in a prepubertal Class III patient sample that underwent maxillary protraction with alternate rapid maxillary expansions and constrictions protocol followed by facemask.

Methods: The study group included 15 prepubertal patients (mean age: 9.85 ± 1.44 years) with Class III malocclusion due to maxillary retrognathism. Nine weeks of alternate rapid maxillary expansions and constrictions protocol was followed prior to 7 months of face mask treatment and 3 months of retention with Bionator. Pretreatment (T0) and post-retention (T1) lateral cephalometric radiographs and 3dMD images were retrieved from clinical archive. The same records were used for a control group of 15 well-matched, untreated patients (mean age: 9.4 ± 0.79 years). The distance between the upper eyelid margin and the lower eyelid margin was recorded as the overall eye height (E), and the distance between inferior limbus and the lower eyelid margin was recorded as inferior sclera exposure (S). The S : E ratio in percentage was calculated. Sella-nasion-A point angle (SNA) was used as the skeletal variable.

Results: SNA angle, right S : E, and left S : E changed significantly in both groups at T1-T0. The intergroup comparison was highly significant for SNA angle but was not significant for right and left S : E variables.

Conclusion: The S : E ratio decreased significantly in both alternate rapid maxillary expansions and constrictions/facemask and the control groups. However, the change in S : E ratio between groups was not significant.

Keywords: Alt-RAMEC, Angle Class III, maxillary retrusion, sclera, stereophotogrammetry

INTRODUCTION

Maxillary retrognathism has an important contribution in the etiology of skeletal Class III problems. Many researchers reported that 60% of Class III malocclusions are related with maxillary deficiency.^{1,2} In growing patients with Class III malocclusion of maxillary origin, orthopedic treatment with facemask (FM) therapy has become a conventional technique with well-documented effects.^{3,4} The rapid maxillary expansion (RME) prior to FM application facilitates the circummaxillary sutural response.^{5,6}

In 2005, Liou and Tsai⁷ introduced an alternative method called “alternate rapid maxillary expansions and constrictions” (Alt-RAMEC) with a double-hinged expansion screw. This protocol proposed sequential expansion and constriction sets for 7-9 consecutive weeks prior to FM to increase the disarticulation of circummaxillary sutures.^{7,8} The reported amounts of maxillary protraction with the Alt-RAMEC protocol were significantly more (4-6 mm in 5 months) in a shorter treatment duration^{7,9} than the conventional method with RME (1.5-3 mm in 10-12 months).^{10,11} Wang et al¹² concluded that the sutural opening was quantitatively more in the Alt-RAMEC group than the conventional RME.¹²

Anterior maxillary deficiency has several facial characteristics such as flat or sunken cheekbones, flat and long midface, flattened paranasal area, and prominent chin, resulting in a concave profile. Another common facial feature of these patients is increased scleral exposure of the eyes due to the decreased anterior maxillary projection of the underlying skeletal structures. Increased scleral exposure is associated with an undesirable elderly appearance and therefore is clinically undesirable.^{13,14} Orthopedic and surgical (i.e., orthognathic) interferences can have an indirect impact on the periorbital area. The effect of orthognathic surgery on the scleral exposure has been documented in a limited number of studies, and they have agreed on the positive effects of maxillary advancement on inferior sclera exposure.¹⁵⁻¹⁸ To the best of our knowledge, only one study has investigated the changes in inferior sclera exposure after maxillary protraction on facial photographs.¹⁹

The purpose of this controlled study is to measure and evaluate the inferior sclera exposure changes using 3dMD stereophotogrammetric images in a growing Class III patient sample that underwent maxillary protraction treatment with Alt-RAMEC protocol followed by FM.

METHODS

This controlled cohort retrospective study was approved by the ethical committee of Marmara University, Dental School (approval date: 01.06.2020, İstanbul; protocol number: 2020-401) and was conducted in accordance with the Declaration of Helsinki of 1975 as revised in 2013.

G*Power (version 3.1.9.4) software was used for the power analysis. The sample size was calculated based on a previous study²⁰ with a significance level of .05 and a power of 95% to detect a clinically meaningful difference of $1.43^\circ (\pm 1.15^\circ)$ for Sella-nasion-A point angle (SNA) between the groups. The power analysis showed that 15 patients in each group were required. The study sample was derived from the population of patients who presented to the Department of Orthodontics Marmara University, Dental School for evaluation and management of skeletal Class III malocclusion from January 1, 2009 through January 1, 2018. Inclusion criteria were anterior crossbite ≥ 1 mm; skeletal Class III malocclusion due to maxillary hypoplasia (diagnosed by decreased distance from N perpendicular to A point (< -1 mm), SNA ($< 80^\circ$), and maxillary depth ($< 90^\circ$)); normal to low-angle vertical growth pattern (Sella-Nasion to Gonion-Menton angle (SN-GoMe) $\leq 32 \pm$

6°); Wits appraisal < -1 mm; age between 8 and 11 years; prepubertal growth stage according to the cervical vertebral maturation method; no previous orthodontic treatment; maxillary protraction treatment with FM; complete records. Exclusion criteria were patients with a large mandible (corpus length \geq anterior cranial base + 7 mm); pseudo Class III malocclusion; high-angle vertical growth pattern; presence of systemic diseases; craniofacial anomalies or temporomandibular joint disorders; history of facial trauma and orbital surgery; patients who failed to follow the treatment protocol. The informed consent was obtained from all the patients included in the study and the control group.

The study group (Alt-RAMEC/FM) comprised 15 patients (8 males, 7 females; mean age: 9.85 ± 1.44 years). Alternate rapid maxillary expansions and constrictions protocol was followed with the double-hinged screw (US patent number: 6334771B1) attached to posterior acrylic bite blocks with bilateral hooks for the attachment of elastics. The screw was activated 1 mm/day (twice in the morning and twice in the evening) for the first week and closed at the same rate for the second week. The expansion and constriction sets were continued for 9 weeks in total. A Petit-type FM (Adjustable Dynamic Protraction Facemask™, Ormco, Orange, Calif, USA) was then prescribed for a minimum of 16 h/day and 500 g/side until a full Class II molar and canine relationship was achieved. The duration of face mask treatment was 7 months on average. Patients were then given Bionator for retention for 3 months. At Pretreatment (T0) and after FM + Bionator (T1), lateral cephalometric radiographs and 3dMD stereophotogrammetric images were derived from the clinical archive of the department of orthodontics.

The control group comprised 15 subjects (9 males, 6 females; mean age: 9.4 ± 0.79 years). Lateral cephalometric radiographs and 3dMD stereophotogrammetric images were acquired initially (T0) and at the end of 9-months of observation period (T1). No orthodontic treatment was performed during that observation period.

T0 and T1 lateral cephalometric radiographs were traced to analyze the skeletal changes on NemoStudio NX Pro 10.4.2 cephalometric tracing software (Nemotech, Madrid, Spain). SNA angle was taken into consideration as a study variable for maxillary changes. 3dMDface system (3dMD Inc., Atlanta, Ga, USA) was established in a separate room using 2 modular units of 6 medical-grade, machine-vision cameras. For standardization, the 3dMD cameras were calibrated prior to every use with its calibration tray. The lighting was standardized with the powerful industrial-grade flash systems of the 3dMD module. Patients were positioned on a height-adjustable chair, looking into a mirror to establish natural head position. The position of the mirror was fixed on the wall between the cameras and opposite to the patient. The operator could manipulate the patient's head for orientation, adjusted the chair height for the patients to face the mirror, and instructed the patients to look directly into their eyes on their reflection in the mirror. Every image was quality-checked immediately on a 20-inch desktop computer screen for artifacts, and shooting was repeated when necessary. The acquired images were saved automatically in a .tbs (tricolor surface binary) format. A template was customized for landmark

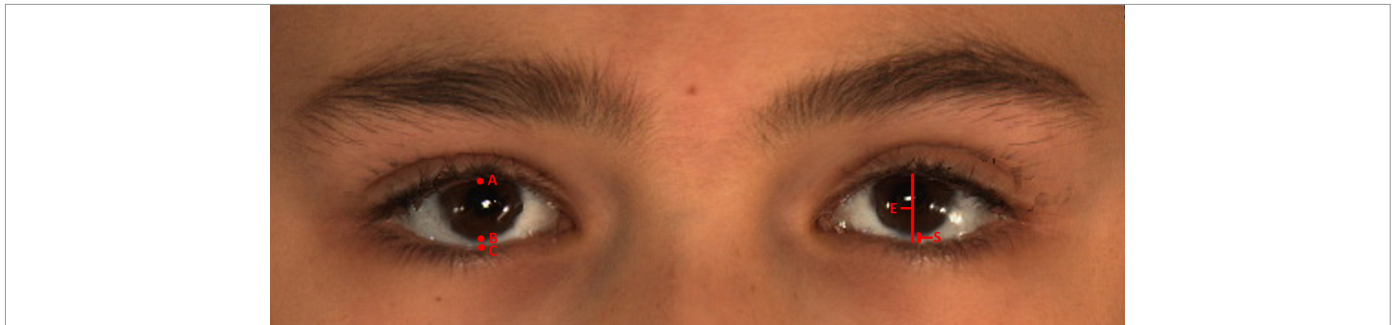

Figure 1. The landmarks used in 3dMD stereophotogrammetric images: upper eyelid margin (A), the inferior limbus (B), and lower eyelid margin (C). The proportional relation between the inferior sclera exposure (S) and eye height (E).

measurements using 3dMDvultus software (3dMD Inc.). One investigator, blinded to the cephalometric analyses, measured inferior sclera exposure on both sides. The landmarks were upper eyelid margin (A), the inferior limbus (B), and lower eyelid margin (C). The distance between the upper eyelid margin and the lower eyelid margin was recorded as the overall eye height (E), and the distance between inferior limbus and the lower eyelid margin was recorded as inferior sclera exposure (S) (Figure 1). The S : E ratio in percentage was calculated to standardize the sclera exposure relative to the overall eye height.¹⁷

Statistical Analysis

During the assessment of the data obtained in the study, the IBM Statistical Package for the Social Sciences software (IBM SPSS Statistics for Windows, Version 22.0. Armonk, NY, USA) was used for statistical analysis. Data were analyzed using descriptive statistical methods (mean, standard deviation). T0 and T1 values were compared statistically by the Wilcoxon signed-rank test while Mann–Whitney *U* test was used for intergroup comparisons. Significance was evaluated at a level of *P* < .05. To assess the intraexaminer reliability, 2 weeks after the first measurements, 20% of all the records were randomly selected and analyzed by the same examiner.

RESULTS

The intraclass correlation coefficient of all parameters showed a high rate of consonance between the measurements and ranged

from 0.820 to 0.958. The groups presented comparable values in all of the cephalometric analyses except Incisor-Mandibular plane angle (IMPA) which was higher in the control group (*P* < .05) (Table 1).

Table 2 summarizes the changes in study variables in both groups. SNA angle increased $2.12 \pm 1.2^\circ$ (*P* < .001) in Alt-RAMEC/FM group and $0.87 \pm 0.92^\circ$ (*P* < .01) in control group. The decreases in S : E ratios in percentage were 1.82 ± 2.75 (*P* < .05) and 1.68 ± 2 (*P* < .01) for the right and left eye, respectively, in Alt-RAMEC/FM group. In the control group, the decreases in S : E ratios in percentage were 1 ± 1.59 (*P* < .05) and 1.37 ± 2.02 (*P* < .05) for the right and left eye, respectively. All changes were found statistically significant.

Table 3 shows the comparison of the changes in S : E ratios (T1-T0) between the groups. The change in SNA between groups was statistically significant (*P* < .01), whereas the changes in S : E ratios in percentage were not significant.

DISCUSSION

In the literature, there are studies that evaluated the alteration of inferior sclera exposure after orthognathic surgery, and they all agree on the improving effects of maxillary advancement. In this study, we hypothesized that a similar improvement in the scleral

Table 1. Evaluation of the homogeneity between the initial (T0) cephalometric values of the groups

Variables	Alt-RAMEC/FM Mean ± SD	Control Mean ± SD	<i>P</i>
SNA	77.84 ± 2.33	78.07 ± 3.15	.823
SNB	77.96 ± 2.27	79.13 ± 3.44	.280
ANB	-0.12 ± 1.18	-1.06 ± 2.12	.142
FMA	26.45 ± 3.7	29.2 ± 5.12	.102
U1-SN	100.11 ± 5.76	102.27 ± 9.3	.452
IMPA	84.57 ± 4.1	89.4 ± 5.71	.013*

Mann–Whitney *U* test **P* < .05.
 Alt-RAMEC, alternate rapid maxillary expansions and constrictions; FM, face-mask; SNA, Sella-nasion-A point angle; SNB, Sella-Nasion-B point angle; ANB, A point-Nasion-B point angle; U1-SN, Upper incisor to Sella-Nasion angle.

Table 2. Analyses of the changes in study variables in both groups

Groups	Variables	T0		T1		Difference Mean ± SD	<i>P</i>
		Mean ± SD	Mean ± SD	Mean ± SD	Mean ± SD		
Alt-RAMEC/FM	SNA	77.84 ± 2.33	79.96 ± 2.58	2.12 ± 1.2	.001**		
	FMA	26.45 ± 3.7	26.68 ± 2.9	0.23 ± 1.39	.427		
	Right S : E	7.08 ± 3.51	5.26 ± 3.69	-1.82 ± 2.75	.017*		
	Left S : E	6.97 ± 3.61	5.29 ± 3.37	-1.68 ± 2	.008**		
Control	SNA	78.07 ± 3.15	78.93 ± 2.81	0.87 ± 0.92	.008**		
	FMA	29.2 ± 5.12	29.33 ± 5.6	0.13 ± 2.39	.812		
	Right S : E	4.29 ± 4.33	3.29 ± 3.5	-1 ± 1.59	.01*		
	Left S : E	4.31 ± 4.81	2.94 ± 3.74	-1.37 ± 2.02	.031*		

Wilcoxon signed-rank test **P* < .05; ***P* < .01.
 Alt-RAMEC, alternate rapid maxillary expansions and constrictions; FM, face-mask; SNA, sella-nasion-A point angle; E, overall eye height; S, inferior sclera exposure; S : E, ratio of sclera exposure relative to the overall eye height in percentage.

Table 3. Comparison of the changes in S : E ratios (T1-T0) between the groups

Variables	Alt-RAMEC/FM Mean \pm SD	Control Mean \pm SD	P
SNA	2.12 \pm 1.2	0.87 \pm 0.92	.003**
Right S : E	-1.82 \pm 2.75	-1 \pm 1.59	.325
Left S : E	-1.68 \pm 2	-1.37 \pm 2.02	.679

Mann-Whitney U test; **P < .01.
Alt-RAMEC, alternate rapid maxillary expansions and constrictions; FM, face-mask; SNA, sella-nasion-A point angle; E, overall eye height; S, inferior sclera exposure; S : E, ratio of sclera exposure relative to the overall eye height in percentage.

exposure to that achieved by maxillary advancement surgery could be detected in the maxillary protraction treatment as well. Our primary aim was to measure the inferior sclera exposure on 3dMD images before and after maxillary protraction with Alt-RAMEC/FM protocol in prepubertal Class III subjects and compare the results with a well-matched untreated control group.

4 Studies that evaluated the periorbital changes after orthognathic surgery were performed on standardized facial photographs. In the present study, 3dMDface system, which provides stereophotogrammetric images, was used. Stereophotogrammetry is a non-invasive method that offers clinicians a comprehensive 3-dimensional representation of the craniofacial complex. In 2-dimensional photography, there are several factors that must be controlled for standardization. The distance between the object and camera, camera angulation, amount of magnification, lightning, and head orientation are some of these variables. In a clinical setting, stereophotogrammetry is advantageous over conventional photography by the reduced number of these variables and by its ability to reproduce 1 : 1 surface imaging. Lightning conditions, camera angulations are more standardized because of the fixed nature of the 3dMDface system apparatuses. Furthermore, the system is calibrated prior to every use, and the resultant image can immediately be evaluated on a computer screen for artifacts. The precision and reliability of 3D anthropometric data collected with the 3dMDface system have been found to be high and useful for phenotypic measures by many studies.²¹⁻²⁴

Natural head posture is the upright position of the head, while it is balanced by the post-cervical and masticatory-suprahyoid-in frahyoid muscle groups, with the eyes directed forward so that the visual axis is parallel to the floor.²⁵ Three-dimensional images captured in natural head position are advantageous for several reasons: they are shown to be highly reproducible,²⁶ allow standardized patient orientation, and the visual axis is parallel to the floor during capturing also allowing more standardized eyelid and eye globe positions. Krause et al²⁷ has used the same method of stereophotogrammetry in natural head position for 3-dimensional analysis of changes in scleral show after surgical treatment of endocrine orbitopathy. They concluded that this method proved to be effective as it allowed exact analysis of lid contour and proptosis measurement and comparison even in cases where the bony orbit was changed.

In the Alt-RAMEC protocol, Liou⁸ introduced a double-hinged screw and explained that the center of rotation of the maxilla would be located near the maxillary tuberosity. Moreover, the resistance structures are weakened, and more mobilization in the sutures is expected due to the repeated expansion and constriction sets, resulting in the forward movement of tuber maxilla without any resorption and enhanced anterior displacement of the A-point.⁸ The amount of protraction with the Alt-RAMEC protocol in many studies was found greater than the conventional RME+FM protocol. Liou and Tsai⁷ reported 5.8 \pm 2.3 mm; Canturk and Celikoglu²⁸ reported 3.84 mm; and Isci et al⁹ reported 4.13 mm forward movement of A-point. However, Vieira et al²⁹ reported less advancement (1.92 mm) with the Alt-RAMEC in comparison to the RME (2.74 mm) protocol. The promising results of the Alt-RAMEC protocol encouraged the authors to use this method in the present study where the SNA changed 2.12 \pm 1.2°. Masucci et al³⁰ reported 2.7° and Do-de Latour et al³¹ reported 1.4° improvement. These variations might result from several factors such as the severity of Class III malocclusion, age, timing of the record collection, type of expansion device, patient cooperation, and treatment duration.

To the best of our knowledge, only one study by Kale et al¹⁹ evaluated the change in inferior sclera exposure after maxillary protraction with and without skeletal anchorage. They used facial photographs to evaluate scleral changes and concluded that in both methods the visibility of sclera reduced significantly with more improvement in the skeletal anchorage group. However, they lacked a control group, and the question remained unanswered as to whether this result was a pure effect of the treatment intervention or an effect to be expected with normal growth. In the present study, the S : E ratio decreased significantly in both Alt-RAMEC/FM and the control groups. However, when the change in S : E ratio between 2 groups was compared, there was no significant difference. Therefore, we interpret the improvement in the scleral exposure as an effect of active growth rather than an effect of the maxillary protraction. The hypothesis was rejected. Moreover, unlike the study of Kale et al.¹⁹ the present study was conducted on stereophotogrammetry which has advantages over conventional photography by more standardized conditions such as lightning, camera angulations, etc., as was already mentioned above. Therefore, the measurements performed on stereophotogrammetric images can be considered more reliable and precise.

In the literature, age-related soft tissue changes of the palpebral fissure were evaluated by Hreczko et al.³² They evaluated the surface measurements and age-related changes of the palpebral fissure in 1552 healthy Caucasian subjects between 2 and 18 years of age. They concluded that (1) at age 2, the height of the palpebral fissure was the most developed feature by 93.3%; (2) the measurements reached adult size between ages 8 and 16; and (3) the periods with minimal growth were at ages 5-7 and 9-10.³² The age group of the present sample corresponds with these minimal growth periods. As a further precaution to maximize standardization of the sclera shown by the size of the eye, the S : E ratio was calculated as in the study by Norouzi et al.¹⁷ Regarding the age-related surface remodeling of the maxillary base and orbital floor, Björk and Skieller³³ found that apposition

occurs on the orbital floor and that the sutural lowering of the maxillary body is compensated by the lowering of the orbital floor. Iseri et al³⁴ conducted an implant study including 8- to 25-year-old female subjects. They reported a posterosuperior relocation of the orbital floor during the growth period and that not only the sutural lowering but also the forward displacement of the maxilla was compensated by the appositional growth on the orbital floor. However, they also added that the amounts of true rotation and the surface remodeling of maxilla are much smaller than those of the mandible; therefore, the errors incurred by superimposition will probably be relatively small in the analysis of relatively short periods of growth or treatment such as 1 year.³⁴ In the present study, this interval was 9-10 months.

In the present study, sclera exposure might not have been affected from the vertical changes since the Frankfort horizontal line to mandibular plane Angle (FMA) angle did not show any significant change after the treatment. In the literature, there are studies^{28,30} reporting an increase in the vertical height while some others report no changes^{20,35} as it was in the present study. The unchanged vertical height might be the result of the continued growth in the posterior face height and possible control of the vertical dimension with the posterior acrylic bite block. The studies in the literature evaluated the effects of maxillary advancement with or without impaction by orthognathic surgery or maxillary protraction with FM on sclera exposure. To the best of our knowledge, there is no study evaluating the effects of down-fracture or the increase in vertical dimension on sclera exposure. However, Soydan et al¹⁵ reported that the impact of sagittal movement was being superior to the impact of vertical movement on the reduction of inferior sclera exposure. Moreover, they asserted that a severe amount of isolated maxillary impaction such as more than 3 mm might have some effects on exposition of inferior sclera. In the light of this information, we might infer that the increase in the vertical dimension should be in severe amounts in order to affect the sclera exposure.

A limitation of this study can be considered as the small number of subjects, which was due to the retrospective study design. The change in SNA was limited also (i.e., smaller than previous reports on Alt-RAMEC/FM). However, the T1 measurements in this study were collected after a 3-month retention period with Bionator. Most studies reflected immediate effects of Alt-RAMEC/FM protocol. For future studies, different treatment protocols (like corticotomy-assisted FM treatment where greater maxillary movement is anticipated) with larger group of subjects can be considered. Using pretreatment and posttreatment cone-beam computed tomography (CBCT) images could be beneficial to document more precise skeletal effects of the treatment. However, in that case, taking CBCT from an untreated control group can be questionable in terms of ethical concerns.

CONCLUSION

Within the limitations of this study, we conclude that the observed reduction in the inferior sclera exposure after the 9-week Alt-RAMEC protocol and 7 months of FM treatment

followed by 3 months of retention was an effect of continuing active growth rather than the treatment intervention.

Ethics Committee Approval: Ethics committee approval was received from the Ethical Committee of Marmara University, Dental School, Istanbul, Turkey (approval date and number: 01.06.2020, 2020/35; protocol number: 2020/401).

Informed Consent: Written informed consent was obtained from the parents of all patients.

Peer-review: Externally peer-reviewed.

Author Contributions: Concept - H.N.Y.; Design - E.Ö.Ö.; Supervision - H.N.Y.; Data Collection and/or Processing - E.Ö.Ö.; Analysis and/or Interpretation - Y.B.A.; Literature Review - Y.B.A.; Writing - Y.B.A.; Critical Review - H.N.Y.

Conflict of Interest: The authors have no conflict of interest to declare.

Financial Disclosure: The authors declared that this study has received no financial support.

REFERENCES

1. Ellis E 3rd, McNamara JA Jr. Components of adult class III malocclusion. *J Oral Maxillofac Surg.* 1984;42(5):295-305. [\[CrossRef\]](#)
2. Guyer EC, Ellis EE 3rd, McNamara JA Jr, Behrents RG. Components of class III malocclusion in juveniles and adolescents. *Angle Orthod.* 1986;56(1):7-30. [\[CrossRef\]](#)
3. McNamara JA Jr. An orthopedic approach to the treatment of class III malocclusion in young patients. *J Clin Orthod.* 1987;21(9):598-608.
4. Baik HS. Clinical results of the maxillary protraction in Korean children. *Am J Orthod Dentofacial Orthop.* 1995;108(6):583-592. [\[CrossRef\]](#)
5. Turley PK. Orthopedic correction of class III malocclusion with palatal expansion and custom protraction headgear. *J Clin Orthod.* 1988;22(5):314-325.
6. Baccetti T, Franchi L, McNamara JA Jr. Treatment and posttreatment craniofacial changes after rapid maxillary expansion and facemask therapy. *Am J Orthod Dentofacial Orthop.* 2000;118(4):404-413. [\[CrossRef\]](#)
7. Liou EJ, Tsai WC. A new protocol for maxillary protraction in cleft patients: repetitive weekly protocol of alternate rapid maxillary expansions and constrictions. *CleftPalateCraniofacJ.* 2005;42(2):121-127. [\[CrossRef\]](#)
8. Liou EJ. Effective maxillary orthopedic protraction for growing class III patients: a clinical application simulates distraction osteogenesis. *Prog Orthod.* 2005;6(2):154-171.
9. Isci D, Turk T, Elekdag-Turk S. Activation-deactivation rapid palatal expansion and reverse headgear in class III cases. *Eur J Orthod.* 2010;32(6):706-715. [\[CrossRef\]](#)
10. Williams MD, Sarver DM, Sadowsky PL, Bradley E. Combined rapid maxillary expansion and protraction facemask in the treatment of class III malocclusions in growing children: a prospective long-term study. *Semin Orthod.* 1997;3(4):265-274. [\[CrossRef\]](#)
11. Foersch M, Jacobs C, Wriedt S, Hechtner M, Wehrbein H. Effectiveness of maxillary protraction using facemask with or without maxillary expansion: a systematic review and meta-analysis. *Clin Oral Investig.* 2015;19(6):1181-1192. [\[CrossRef\]](#)
12. Wang YC, Chang PM, Liou EJ. Opening of circumaxillary sutures by alternate rapid maxillary expansions and constrictions. *Angle Orthod.* 2009;79(2):230-234. [\[CrossRef\]](#)
13. Pessa JE, Zadoo VP, Mutimer KL, et al. Relative maxillary retrusion as a natural consequence of aging: combining skeletal and soft-tissue changes into an integrated model of midfacial aging. *Plast Reconstr Surg.* 1998;102(1):205-212. [\[CrossRef\]](#)

14. Pessa JE. An algorithm of facial aging: verification of Lambros's theory by three-dimensional stereolithography, with reference to the pathogenesis of midfacial aging, scleral show, and the lateral suborbital trough deformity. *Plast Reconstr Surg*. 2000;106(2):479-488; discussion 489-490. [\[CrossRef\]](#)
15. Soydan SS, Bayram B, Sar C, Uckan S. Change in inferior sclera exposure following Le Fort I osteotomy in patients with midfacial retrognathia. *J Oral Maxillofac Surg*. 2014;72(1):166.e1-166.e5. [\[CrossRef\]](#)
16. Posnick JC, Sami A. Individuals With a long face growth pattern and excess inferior scleral exposure: is there improvement after maxillary (Le Fort I) advancement and vertical shortening? *J Oral Maxillofac Surg*. 2015;73(9):1809-1815. [\[CrossRef\]](#)
17. Norouzi A, Chi G, Shafae Fard S, et al. Scleral exposure alterations following Le Fort I osteotomy (with and without maxillary impaction) in skeletal class III patients: a before-and-after clinical trial. *J Craniomaxillofac Surg*. 2018;46(9):1480-1483. [\[CrossRef\]](#)
18. Magraw CB, Garaas R, Shaw A, Phillips C, Turvey TA. Changes in scleral exposure following modified Le Fort III osteotomy. *Oral Surg Oral Med Oral Pathol Oral Radiol*. 2015;120(2):119-124.e1. [\[CrossRef\]](#)
19. Kale B, Buyukcavus MH, Esenlik E. Comparison of the change in inferior sclera exposure after maxillary protraction with or without skeletal anchorage. *Niger J Clin Pract*. 2018;21(7):854-858. [\[CrossRef\]](#)
20. Sitaropoulou V, Yilmaz HN, Yilmaz B, Kucukkeles N. Three-dimensional evaluation of treatment results of the Alt-RAMEC and face-mask protocol in growing patients. *J Orofac Orthop*. 2020;81(6):407-418. [\[CrossRef\]](#)
21. Ort R, Metzler P, Kruse AL, et al. The reliability of a three-dimensional photo system- (3dMDface-) based evaluation of the face in cleft lip infants. *Plast Surg Int*. 2012;2012:138090. [\[CrossRef\]](#)
22. Dindaroğlu F, Kutlu P, Duran GS, Görgülü S, Aslan E. Accuracy and reliability of 3D stereophotogrammetry: a comparison to direct anthropometry and 2D photogrammetry. *Angle Orthod*. 2016;86(3):487-494. [\[CrossRef\]](#)
23. Aldridge K, Boyadjiev SA, Capone GT, DeLeon VB, Richtsmeier JT. Precision and error of three-dimensional phenotypic measures acquired from 3dMD photogrammetric images. *Am J Med Genet A*. 2005;138A(3):247-253. [\[CrossRef\]](#)
24. Lane C, Harrell W Jr. Completing the 3-dimensional picture. *Am J Orthod Dentofacial Orthop*. 2008;133(4):612-620. [\[CrossRef\]](#)
25. Ozbek MM, Miyamoto K, Lowe AA, Fleetham JA. Natural head posture, upper airway morphology and obstructive sleep apnoea severity in adults. *Eur J Orthod*. 1998;20(2):133-143. [\[CrossRef\]](#)
26. Chiu CS, Clark RK. Reproducibility of natural head position. *J Dent*. 1991;19(2):130-131. [\[CrossRef\]](#)
27. Krause M, Kruber D, Hümpfner-Hierl H, Sterker I, Hierl T. Three-dimensional changes of scleral show after surgical treatment of endocrine orbitopathy. *J Craniomaxillofac Surg*. 2018;46(1) :44-49. [\[CrossRef\]](#)
28. Canturk BH, Celikoglu M. Comparison of the effects of face mask treatment started simultaneously and after the completion of the alternate rapid maxillary expansion and constriction procedure. *Angle Orthod*. 2015;85(2):284-291. [\[CrossRef\]](#)
29. da Luz Vieira G, de Menezes LM, de Lima EM, Rizzatto S. Dentoskeletal effects of maxillary protraction in cleft patients with repetitive weekly protocol of alternate rapid maxillary expansions and constrictions. *Cleft Palate Craniofac J*. 2009;46(4):391-398. [\[CrossRef\]](#)
30. Masucci C, Franchi L, Giuntini V, Defraia E. Short-term effects of a modified Alt-RAMEC protocol for early treatment of Class III malocclusion: a controlled study. *Orthod Craniofac Res*. 2014;17(4):259-269. [\[CrossRef\]](#)
31. Do-de Latour TB, Ngan P, Martin CA, Razmus T, Gunel E. Effect of alternate maxillary expansion and contraction on protraction of the maxilla: a pilot study. *Hong Kong Dent J*. 2009;6:72-82.
32. Hreczko T, Farkas LG, Katic M. Clinical significance of age-related changes of the palpebral fissures between age 2 and 18 years in healthy Caucasians. *Acta Chir Plast*. 1990;32(4):194-204.
33. Björk A, Skieller V. Growth of the maxilla in three dimensions as revealed radiographically by the implant method. *Br J Orthod*. 1977;4(2):53-64. [\[CrossRef\]](#)
34. Iseri H, Solow B. Average surface remodeling of the maxillary base and the orbital floor in female subjects from 8 to 25 years: an implant study. *Am J Orthod Dentofacial Orthop*. 1995;107(1):48-57. [\[CrossRef\]](#)
35. Kaygisiz E, Tuncer BB, Yüksel S, Tuncer C, Yildiz C. Effects of maxillary protraction and fixed appliance therapy on the pharyngeal airway. *Angle Orthod*. 2009;79(4):660-667. [\[CrossRef\]](#)