



Reconstruction of advanced periacetabular metastatic lesions with modified Harrington procedure

Bülent EROL, Ahmet Nadir AYDEMİR, Tolga ONAY, Mert Osman TOPKAR

Marmara University Pendik Training and Research Hospital, Department of Orthopaedics and Traumatology, İstanbul, Turkey

Objective: The purpose of this study was to assess the outcomes of patients who had been treated by a modified Harrington procedure for advanced periacetabular metastases.

Methods: Between 2006 and 2013, 16 patients with a mean age of 57 years (range: 28–73 years) were treated using a modified Harrington technique. Extensive (class II/III) periacetabular defects were due to metastatic carcinoma or multiple myeloma. Surgical procedure included total hip replacement and acetabular reconstruction using threaded pins, cemented acetabular reinforcement ring, and/or polyethylene cup.

Results: All patients improved in regard to pain and walking ability. Mean preoperative and postoperative Musculoskeletal Tumour Society (MSTS) functional scores were 52.8% (range: 33.3–73.3%) and 72% (range: 56.6–90%), respectively ($p < 0.05$). There were 5 (31%) early or late complications requiring additional surgery. Implant survival was 75% and 37.5% at 12 and 18 months, respectively. Mean survival of the patients was 21 months (range: <1–6 years). Six remained alive, with a mean survival of 27 months (range: 18 months to 5 years).

Conclusion: This modified Harrington procedure can be used for reconstruction of advanced periacetabular metastatic lesions.

Keywords: Harrington procedure; periacetabular metastasis; surgical treatment.

Level of Evidence: Level IV - Case series, Therapeutic study.

Metastatic bone disease is common in cancer patients. Approximately half of all primary cancers spread to the skeleton, which is the third most frequent site of metastases after the lungs and liver.^[1] Treatment of bone metastases is usually palliative, with goals of orthopedic management being adequate control of pain, prevention or stabilization of pathological fractures, and improvement of function and ambulation.

The proximal femur and periacetabular region are the most common sites of metastatic involvement in the appendicular skeleton.^[2–4] This is also a common site of

pathological fracture because of the significant forces on this region while standing. Periacetabular metastatic lesions frequently cause severe pain and disability. In addition, they may lead to hip instability by disrupting acetabular integrity.^[5]

The management of destructive periacetabular metastases presents a treatment challenge. Palliative radiation therapy can control the bone pain from metastasis. However, stabilization of the joint by surgical intervention frequently is required for weight bearing and ambulation.^[6] Stable fixation decreases the morbidity of


Correspondence: Mert Osman Topkar, MD. Marmara Üniversitesi Pendik Eğitim ve Araştırma Hastanesi, Ortopedi ve Travmatoloji Kliniği, İstanbul, Turkey.

Tel: +90 216 – 625 45 45 e-mail: drmerttopkar@gmail.com

Submitted: February 03, 2015 **Accepted:** August 31, 2015

©2016 Turkish Association of Orthopaedics and Traumatology

Available online at
www.aott.org.tr
doi: 10.3944/AOTT.2015.15.0076
QR (Quick Response) Code



metastatic bone disease by relieving pain, maintaining mobility, and improving the quality of life.^[2,7-15]

Harrington described a long-lasting reconstruction technique of the ilium in cases of extensive periacetabular destruction.^[2] The author used threaded pins inserted retrograde through the acetabular roof and into the iliac wing. The pins were cemented together with an acetabular support ring into which a polyethylene socket was then cemented. Subsequently, a number of authors have presented their results using similar or modified techniques.^[7,10-14] The aim of this study was to review the outcome of patients who had been treated by a modified Harrington procedure for advanced periacetabular metastases.

Patients and methods

The data for this study were obtained retrospectively from our extensive orthopedic oncology files, which include initial and follow-up clinical and radiological

evaluations, as well as operation and pathology reports (Table 1). Between 2006 and 2013, 16 patients with advanced periacetabular metastatic destruction were operated on using a combination of total hip replacement and acetabular reconstruction with threaded pins. Each operation was performed by the senior author at a single institution. All patients were assessed preoperatively by a multidisciplinary oncology team: they were unable to bear weight as a result of impending or established pathological fracture, able to ambulate before disease progression, able to tolerate extensive surgery, and had a life expectancy of more than 3 months. The indication for acetabular reconstruction was extensive supra-acetabular destruction where conventional arthroplasty, or enhancement with only a reinforcement ring, was judged to be insufficient.

The patients had plain radiographs and magnetic resonance imaging of the pelvis and the entire ipsilateral

Table 1. Demographic data, diagnosis, local and systemic spread of disease, treatment, complications, functional status, and oncological follow-up of patients.

Case	Age (y), gender	Primary tumor	Extent of disease	Extent of pelvic lesion	Reconstruction	Postoperative RT	Complications	MSTS score	F-U (months)
1	59, F	Breast Ca	Multiple metastases	Class II	TP + AR + AC	+	–	83.3%	21
2	28, F	Breast Ca	Multiple metastases	Class II	TP + AC (cement-within-cement)	–	Hematoma formation	80%	23
3	63, M	Lung Ca	Multiple metastases	Class III	TP + AR + AC	+	–	66.6%	8
4	51, F	Lung Ca	Multiple metastases	Class II	TP + AC	+	–	70%	14
5	59, M	Lung Ca	Multiple metastases	Class II	TP + AR + AC	+	Deep infection	70%	13
6	65, M	Multiple myeloma	Multiple metastases	Class III	TP + AC	+	Wound problem	66.6%	16
7	47, M	Lung Ca	Multiple metastases	Class III	TP + AC (cement-within-cement)	–	–	73.3%	14
8	61, M	Renal cell Ca	Solitary metastasis	Class III	TP + AC	+	Dislocation	70%	16
9	56, M	Multiple myeloma	Multiple metastases	Class II	TP + AC	+	–	90%	12
10	69, F	Breast Ca	Multiple metastases	Class II	TP + AC	+	Femoral stem fracture	76.6%	70
11	70, F	Breast Ca	Multiple metastases	Class III	TP + AR + AC	–	–	60%	19
12	68, M	Renal cell Ca	Multiple metastases	Class III	TP + AC (cement-within-cement)	–	–	56.6%	6
13	73, M	Prostate Ca	Multiple metastases	Class III	TP + AC	+	–	63.3%	9
14	37, F	Breast Ca	Multiple metastases	Class II	TP + AC	+	–	90%	59
15	55, M	Multiple myeloma	Multiple metastases	Class III	TP + AC	–	–	60%	18
16	51, F	Breast Ca	Multiple metastases	Class III	TP + AC	–	–	76.6%	24

F: Female; M: Male; Ca: Carcinoma; TP: Threaded pin; AR: Acetabular ring; AC: Acetabular cup; RT: Radiation therapy; F-U: Follow-up.

femur (Figures 1a–c, 2a, b). Seven patients also underwent computerized tomography of the pelvis. A whole-body radioisotope bone scan revealed multiple osseous involvement in all patients, except for 1 who had a solitary metastasis of renal cell carcinoma.

The study consisted of 9 men and 7 women with a mean age of 57 years (range: 28–73 years). They had a known primary tumor reported as breast (6), lung (4), renal cell (2), prostate (1) carcinoma, and multiple myeloma (3). Mean time from diagnosis of the primary

tumor was 2 years (range: 10 months to 5 years). All patients in this series were receiving chemotherapy, and 8 patients received radiation therapy for osseous metastases including pelvis prior to surgery.

Periacetabular defects were categorized based on Harrington's classification: class I: periacetabular lesion with intact roof, medial wall and lateral cortices; class II: deficient medial wall; and class III: deficient roof and lateral cortices.^[2] Radiological assessment revealed Harrington class II lesions in 7 and class III lesions in

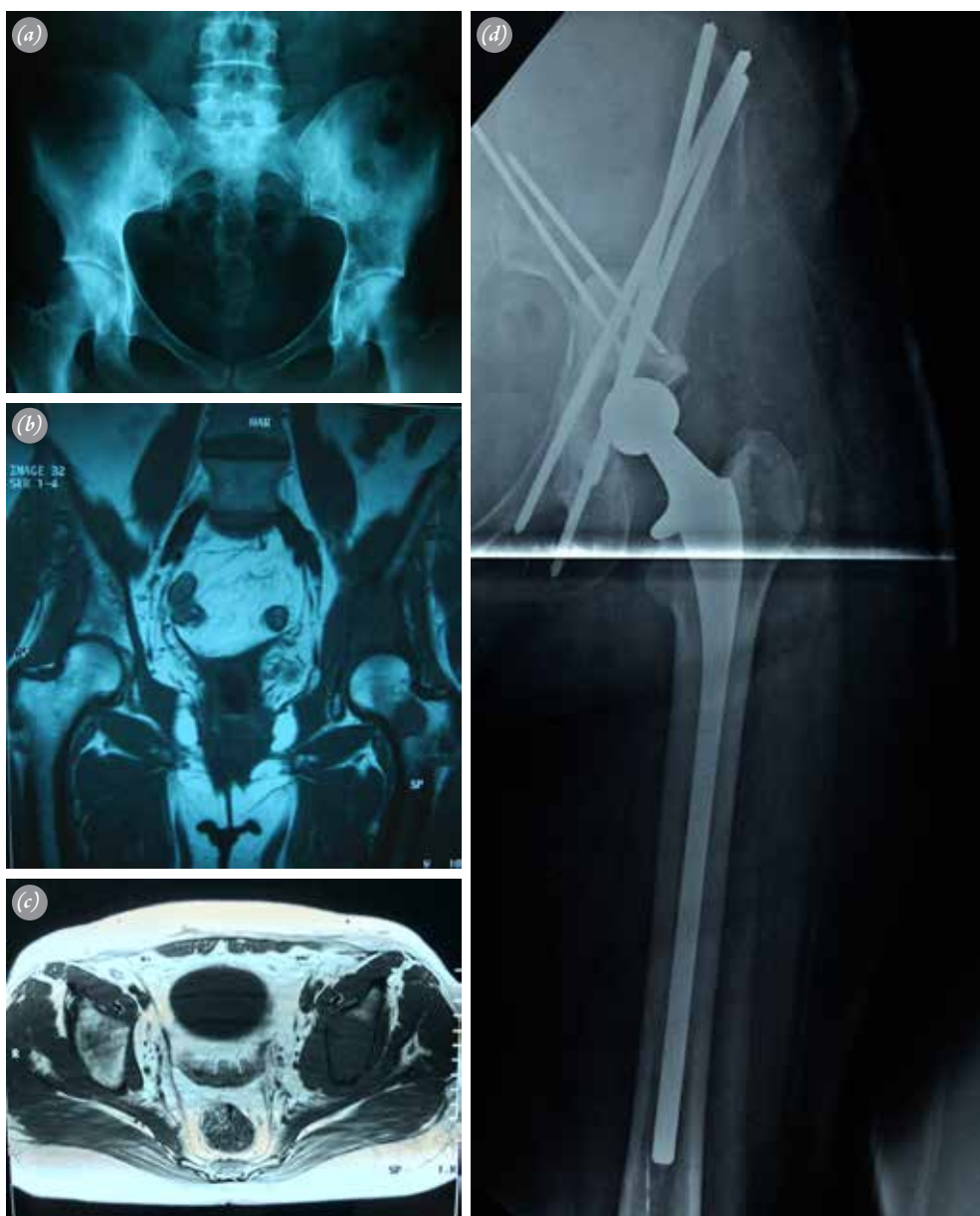

Fig. 1. 48-year-old female with metastatic breast carcinoma. Radiograph and magnetic resonance imaging of the pelvis showed extensive involvement of the periacetabular region. A metastatic lesion in the femoral neck was also seen (a–c). This Harrington class III lesion was managed by total hip replacement and acetabular reconstruction with threaded pins and cemented acetabular cup (d). Postoperative radiation therapy was also applied. [Color figures can be viewed in the online issue, which is available at www.aott.org.tr]

9 patients. Four patients had extensive involvement of the neck and/or pertrochanteric region(s) of the proximal femur with actual (2) or impending (2) pathological fractures.

Six patients underwent preoperative embolization of the metastatic deposit within 2 days of their definitive surgery, which included a combination of total hip replacement and acetabular reconstruction (Figures 1d, 2c, d). Reconstruction of the femoral side was provided by modular endoprosthesis in 3 patients who had seg-

mental proximal femoral resection. The remaining patients had standard (6 patients) or 175–225 mm long-stemmed (7 patients) femoral components. The first step of acetabular reconstruction was antegrade insertion of fully or partially threaded Steinmann pins through the ilium down to the acetabular floor. The number of threaded pins varied according to the anatomy of the defect. Threaded Steinmann pins were supplemented by unthreaded pins or K-wires in some cases. The second step consisted of cementing an acetabular reinforcement

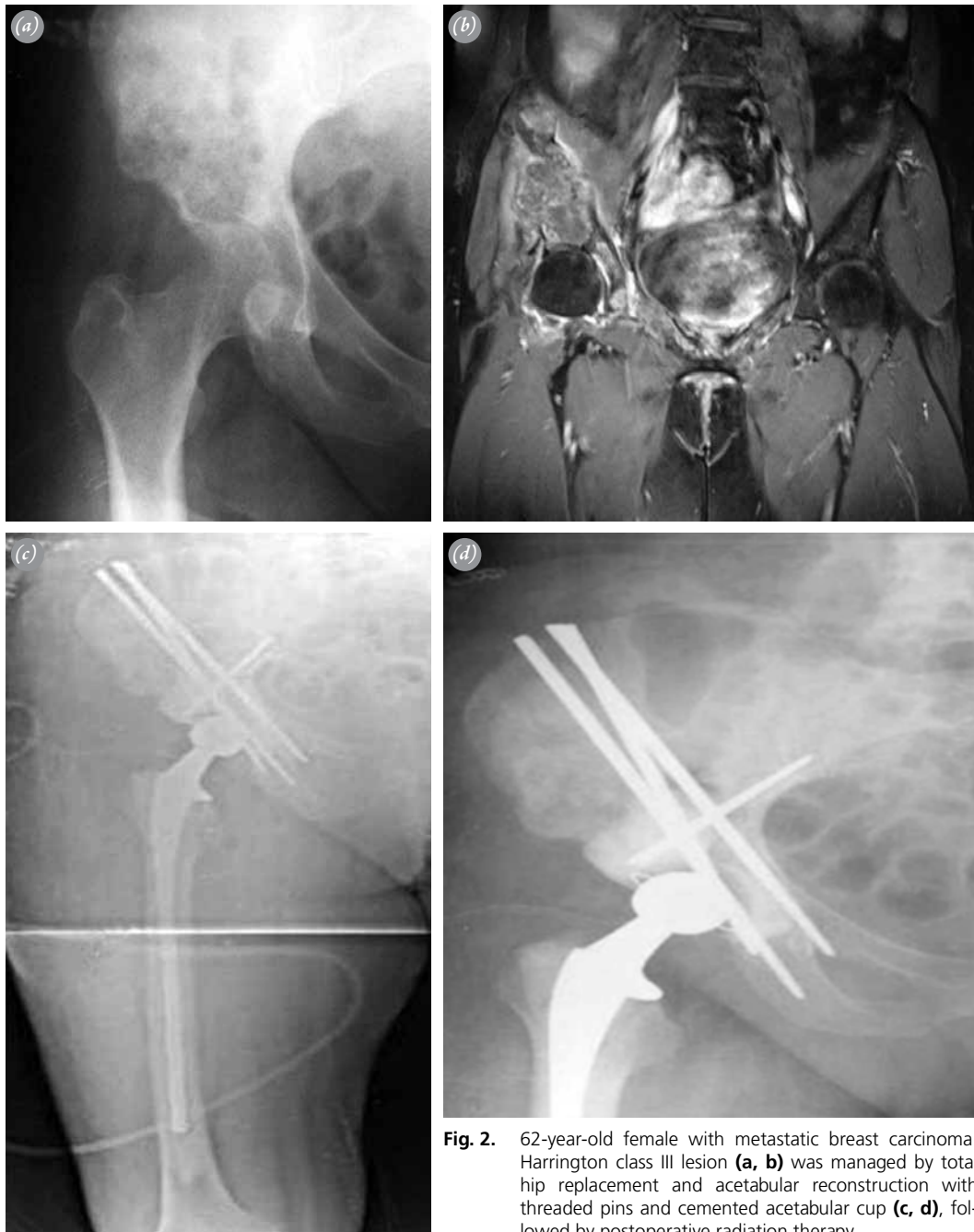

Fig. 2. 62-year-old female with metastatic breast carcinoma. Harrington class III lesion (**a, b**) was managed by total hip replacement and acetabular reconstruction with threaded pins and cemented acetabular cup (**c, d**), followed by postoperative radiation therapy.

ring and/or polyethylene acetabular cup onto this scaffold. One or 2 mixes of gentamycin-containing bone cement were required to fill the defects.

An extended anterolateral approach was used with the patient in a lateral decubitus position. The acetabulum was fully exposed, and metastatic tumorous tissue was curetted until a supra-acetabular bony defect was created. A separate transverse incision was made over the iliac crest, and 2–4 6-mm diameter threaded Steinmann pins were inserted from proximal to distal into the iliac crest and diverted in front, behind, and medial to the floor of the acetabulum. Once the correct positioning of the pins was observed in the acetabular floor, anterior and posterior pins were advanced into the superior pubic rami and ischium, respectively, to further stabilize the acetabular columns. When required, under fluoroscopic guidance, additional pins directed from the defect to or across the sacroiliac joint were used for augmentation. In all stages of the procedure, great care was taken to not direct the pins medially into the pelvis, so as to avoid damage to vital structures such as the iliac vessels and bladder.

In 4 patients, the pins were cemented together with an acetabular support ring into which a polyethylene socket was then cemented. In the remaining 12 patients, an acetabular ring was not used, and reconstruction of the acetabular side was provided by a conventional cemented acetabular component. A cement-within-cement technique was used in 3 patients, and a 40–42-mm x 28-mm acetabular cup was implanted into the firm socket formed by the initially applied cement, filling the defect.^[12,16] In 9 patients, the defect was filled with cement, and the acetabular cup was applied directly onto the multiple pin scaffold in correct inclination and version. Following cemented implantation of the modular, standard, or long-stemmed femoral component, the procedure was completed in a standard fashion.

Following surgery, the majority of patients were as mobile as after a conventional cemented total hip arthroplasty, allowing full weight bearing from the second or third day. Mobilization occasionally was delayed due to impaired general health condition of the patients after surgery. Walking aids were used in all patients postoperatively. Mean postoperative hospital stay was 17 days (range: 12–35 days).

Mean operating time was 180 minutes (range: 150–240 minutes), and mean blood transfusion (preoperative and postoperative) was 3.5 units (range: 2–8 units). All patients routinely received standard doses of low-molecular weight heparin derivatives as thrombosis prophylaxis for 4 weeks. Cephalosporin antibiotic pro-

phylaxis was given at induction and for up to 24 hours postoperatively.

Postoperatively, 10 patients (2 previously irradiated and 8 who had not received any prior radiation therapy) received external beam radiation therapy. A total dose of 30 Gy was given in 10 fractions over 2 weeks. Radiation treatment was generally started within 3–5 weeks of surgery.

Functional and radiological follow-up was performed in 3-month intervals in the first year and in 6-month intervals throughout the rest of follow-up. No patient was lost to follow-up. Functional evaluation was conducted via the Musculoskeletal Tumour Society (MSTS) scoring system;^[17] preoperative and postoperative final follow-up MSTS scores were measured and analyzed statistically. In addition to MSTS scoring, pain and walking ability of the patients were assessed as separate functional parameters preoperatively and postoperatively. The need for analgesics was tabulated to measure severity of pain. A functional system—'mobility grading': grade 1 (bedridden) to grade 7 (no walking aids)—designed for patients undergoing complex periacetabular reconstruction for metastatic disease was used to evaluate walking ability.^[7] Perioperative and postoperative early and late complications were tabulated.

The data obtained were processed using SPSS software (version 11.0, SPSS Inc., Chicago, IL, USA). The Wilcoxon signed-rank test was used for non-parametric comparison of individual patients' preoperative and postoperative functional scores. Kaplan-Meier survival analysis was performed to calculate implant and patient survival.

Results

All patients improved postoperatively in regard to pain at rest, weight bearing, and walking ability/mobility. Severe pain requiring regular use of analgesics was a predominant feature in the preoperative period for all patients. The need for analgesics was reduced considerably after surgery. Except for 3 patients who reported mild pain on weight bearing, the patients were ambulating pain free. These 3 patients did not require regular analgesics.

Walking ability of the patients was graded as 1 to 4 preoperatively; 2 patients were grade 1 (bedridden), 5 grade 2 (wheelchair), 8 grade 3 (no weight bearing, no household tasks), and 1 grade 4 (partial weight bearing, household tasks). All patients demonstrated significantly improved walking ability in the postoperative period and were graded as 6 (partial weight bearing, community activities; 3 patients) or 7 (no walking aids; 13 pa-

tients). Six patients required the aid of a walking stick or a frame for a considerable time; 3 used walking aids for 6 months, and 3 walked with a stick or a cane throughout follow-up.

Mean preoperative and postoperative final follow-up MSTS functional scores were 52.8% (range: 33.3–73.3%) and 72% (range: 56.6–90%), respectively. A statistically significant improvement was achieved in MSTS functional scores ($p < 0.05$).

There were no deaths and no intraoperative complications; in particular, no vascular, nerve, or bladder injuries occurred. One patient had a superficial infection managed by oral antibiotics. Three complications (deep infection, hematoma formation, and other wound problems) were seen in the early postoperative period, and all required surgical debridement and parenteral antibiotics. There was 1 dislocation treated by closed reduction under general anesthesia. The patient used an abduction orthosis for 3 months without any further dislocation. In 1 patient a loosened threaded pin had migrated to the iliac crest subcutaneous tissue without disrupting the integrity of the reconstruction. The pin was removed under local anesthesia. One patient with a modular endoprosthesis had fracture of the femoral stem 2 years after reconstruction and required revision of the femoral component. Loosening in any component of the reconstructions or mechanical failure was not observed in the remaining patients. Implant survival was 75% and 37.5% at 12 and 18 months, respectively.

Ten patients had died by the time of study completion, usually from systemic progression of the metastatic disease. Seven of these patients had survived for more than 12 months postoperatively. Mean survival of the entire study group was 21 months (range: <1–6 years). Mean follow-up of the 6 survivors was 27 months (range: 18 months to 5 years). Kaplan-Meier survivorship curve showed 75% and 37.5% patient survival at 12 and 18 months, respectively.

Discussion

Destruction of the pelvis is a common problem in patients with skeletal metastasis. The pain and disability secondary to pelvic metastases are often very significant. In addition, these lesions frequently lead to mechanical failure, resulting in acetabular protrusion, central fracture-dislocation, or pelvic discontinuity.^[2,5] Limited weight bearing and palliative radiotherapy are well-established treatments to control the bone pain from metastasis; however, in order to permit weight bearing and ambulation, surgical intervention is required to stabilize the joint.^[2,5–15]

The goals of surgical reconstruction are to relieve pain and improve hip function, allowing early mobilization with immediate stability in the postoperative period. In cases where the structural integrity of the acetabulum is maintained, these goals are best accomplished by reconstruction with cemented arthroplasty. However, total hip replacement with or without acetabular support ring is seldom sufficient for treating extensive periacetabular destruction. In these cases, a special surgical technique is required to prevent acetabular component migration and loosening with greater destruction.

Harrington classified metastatic lesions of the acetabulum and described a method for extensive periacetabular reconstruction to improve fixation and allow weight transfer from the acetabular roof to the entire pelvis and spine.^[2] He reduced pain and improved function in 25 class III periacetabular reconstructions by using retrograde pins from the acetabular roof to the iliac wing. There was 1 intraoperative hemorrhage, leading to death postoperatively, and 2 further perioperative deaths in his study. With the exception of 1 femoral nerve palsy, no other major complications, including deep infection or loss of fixation, were seen.

Other studies have used Harrington's method and confirmed his findings. Allan et al. used 2 modifications of the Harrington reconstruction and reported satisfactory results in 25 patients, with 1 loosening of the acetabular cup.^[7] Nilsson et al. modified the technique by using retrograde and antegrade pins in 33 hips with advanced periacetabular defects.^[11] The authors reported improved results after surgery in regard to pain and walking ability. There were 3 cases of severe hemorrhage, 2 of which were fatal. Two dislocations, 1 deep infection, and 2 periprosthetic fractures distal to the femoral component were seen. Faisham et al. used a modified Harrington procedure in 12 patients,^[10] 11 of whom were able to walk pain free with a mean MSTS score of 80. The authors concluded that combination of acetabular reconstruction and postoperative external radiation improved quality of life by improving early ambulation and pain relief.

Tillman et al. reported 19 patients who had been treated by the 3-pin modified Harrington technique.^[12] The surgical procedure involved the insertion of 3 fully threaded 6.5-mm rods/pins from the iliac crest to the acetabular floor. The pins were placed at the anterior, posterior, and medial of the remaining acetabulum and formed a secure scaffold. The defect was filled by bone cement to create a firm socket, and a conventional acetabular cup was then implanted into this socket by cement-within-cement technique. There were no peri-

operative deaths or complications, including injury to a nerve, the blood vessels, or the bladder. Only 1 patient required revision, at 8.9 years after reconstruction.

Some recent reports suggested the modified Harrington reconstruction as an effective and long-lasting method in the management of advanced periacetabular metastatic disease. Ho et al., in a retrospective analysis of 37 patients, reported significantly improved postoperative results in terms of pain, mobility, and function.^[13] Multiple long (60–100 mm) 3.5-mm diameter periacetabular screws, cement, and total hip arthroplasty were used for reconstruction. Vielgut et al. also obtained improved functional results with low complication rates by using a modified technique of this procedure in a limited number of patients.^[14]

The functional results of the current study were comparable with other series using the original or modified Harrington technique for acetabular reconstruction.^[10–14] All defects were reconstructed, and the method promptly relieved pain and restored walking ability. Even though a statistical analysis was not performed, pain and ambulatory ability of the patients were improved significantly after surgical intervention. The need for analgesics was reduced postoperatively, providing pain-free ambulation in the majority of the patients. The stable reconstruction of the periacetabular region, and of the proximal femur when required, also provided increased mobility; each patient improved by at least 3 levels on the mobility grading system of Allan.^[7] The patients were able to walk in their non-hospital community with or without walking aids. In addition to these parameters, the difference between the mean preoperative and postoperative MSTTS scores demonstrated a statistically significant improvement in overall functional status of the patients.

There were 5 (31%) early or late complications requiring additional surgery. Early surgical complications (18.6%)—including deep infection, hematoma formation, and other wound issues—were managed by surgical debridement, without removal or revision of the implants. Dislocation was observed only in 1 patient (6.2%) and was treated by closed reduction. The only complication requiring revision was a femoral stem fracture (6.2%). None of the remaining reconstructions required revision for loosening or mechanical failure throughout follow-up or until the patient died. Our overall complication rate was comparable with the previously reported series.^[11–14]

Ho et al. reported 59% implant and 55% patient survival at 2 years, and 49% implant and 39% patient survival at 5 years.^[13] In the current series, Kaplan-Meier

survivorship curves showed 75% and 37.5% implant and patient survival at 12 and 18 months. A longer survival analysis was not possible due to the limited number of patients with a follow-up of longer than 24 months.

In all reconstructions in this series, antegrade threaded pins from the iliac wing to the acetabular floor were used to create a stable scaffold. However, acetabular components were applied by using various techniques: a polyethylene acetabular cup was cemented directly onto the multiple-pin scaffold or into a cemented acetabular ring, or it was implanted by a cement-within-cement technique. These alternative techniques were applied randomly and did not correlate with the degree of periacetabular destruction. Loosening or mechanical failure of the acetabular reconstruction was not observed in any patients. Based on these findings, we can conclude that when a secure scaffold is created at the acetabular floor, a stable acetabular reconstruction can be obtained by various techniques.

We recognize limitations in this study. First, it is a retrospective study with a limited number of patients. Advanced metastatic lesions of the periacetabular region which require reconstruction are relatively rare. In addition, various surgical techniques have been described to achieve a stable reconstruct in this region.^[18] These factors limit the overall number of modified Harrington procedures performed at any single location. The second limitation is short duration of follow-up. Even though a longer follow-up would be required to evaluate extended implant and patient survival, it should be noted that nearly all patients in this series had widespread metastatic disease. Thirdly, there is no control group for comparison, so similar series in the literature were discussed to evaluate our results. However, strengths of the present study are that all procedures were performed in a standard approach by the same surgeon in the same institution. In addition, the patients were followed extensively with detailed clinical, functional, and oncological records.

Hip reconstruction using a modified Harrington procedure achieves good pain control and functional outcome in patients with acetabular insufficiency due to metastatic disease. Creation of a secure scaffold at the acetabular floor is the primary objective of the procedure, and similar results can be obtained by using various acetabular reconstruction techniques. Modified Harrington procedure provides a long-lasting reconstruction with low rates of loosening and mechanical failure, but it carries a moderate risk of surgical complications. According to our study, this technique can effectively relieve pain, increase ambulatory ability and function, and improve

quality of life in patients with advanced periacetabular metastases.

Conflicts of Interest: No conflicts declared.

References

1. Hage WD, Aboulaflia AJ, Aboulaflia DM. Incidence, location, and diagnostic evaluation of metastatic bone disease. *Orthop Clin North Am* 2000;31:515–28. [CrossRef](#)
2. Harrington KD. The management of acetabular insufficiency secondary to metastatic malignant disease. *J Bone Joint Surg Am* 1981;63:653–64.
3. Ward WG, Spang J, Howe D. Metastatic disease of the femur. Surgical management. *Orthop Clin North Am* 2000;31:633–45. [CrossRef](#)
4. Wunder JS, Ferguson PC, Griffin AM, Pressman A, Bell RS. Acetabular metastases: planning for reconstruction and review of results. *Clin Orthop Relat Res* 2003;(415 Suppl):187–97. [CrossRef](#)
5. Marco RA, Sheth DS, Boland PJ, Wunder JS, Siegel JA, Healey JH. Functional and oncological outcome of acetabular reconstruction for the treatment of metastatic disease. *J Bone Joint Surg Am* 2000;82:642–51.
6. Townsend PW, Rosenthal HG, Smalley SR, Cozad SC, Hassanein RE. Impact of postoperative radiation therapy and other perioperative factors on outcome after orthopedic stabilization of impending or pathologic fractures due to metastatic disease. *J Clin Oncol* 1994;12:2345–50.
7. Allan DG, Bell RS, Davis A, Langer F. Complex acetabular reconstruction for metastatic tumor. *J Arthroplasty* 1995;10:301–6. [CrossRef](#)
8. Böhm P, Huber J. The surgical treatment of bony metastases of the spine and limbs. *J Bone Joint Surg Br* 2002;84:521–9. [CrossRef](#)
9. Capanna R, Campanacci DA. The treatment of metastases in the appendicular skeleton. *J Bone Joint Surg Br* 2001;83:471–81. [CrossRef](#)
10. Faisham WI, Muslim DAJ, Bhavaraju VMK, Nawaz AH, Zulmi W. Modified Harrington procedure for acetabular insufficiency due to metastatic malignant disease. *Malays Orthop J* 2009;3:36–41. [CrossRef](#)
11. Nilsson J, Gustafson P, Fornander P, Ornstein E. The Harrington reconstruction for advanced periacetabular metastatic destruction: good outcome in 32 patients. *Acta Orthop Scand* 2000;71:591–6. [CrossRef](#)
12. Tillman RM, Myers GJ, Abudu AT, Carter SR, Grimer RJ. The three-pin modified ‘Harrington’ procedure for advanced metastatic destruction of the acetabulum. *J Bone Joint Surg Br* 2008;90:84–7. [CrossRef](#)
13. Ho L, Ahlmann ER, Menendez LR. Modified Harrington reconstruction for advanced periacetabular metastatic disease. *J Surg Oncol* 2010;101:170–4.
14. Vielgut I, Sadoghi P, Gregori M, Kovar FM, Pichler K, Maurer-Ertl W, et al. The modified Harrington procedure for metastatic peri-acetabular bone destruction. *Int Orthop* 2013;37:1981–5. [CrossRef](#)
15. Kiatisevi P, Sukunthanak B, Pakpianpairoj C, Liupolvanish P. Functional outcome and complications following reconstruction for Harrington class II and III periacetabular metastasis. *World J Surg Oncol* 2015;13:4. [CrossRef](#)
16. Lieberman JR, Moeckel BH, Evans BG, Salvati EA, Ranawat CS. Cement-within-cement revision hip arthroplasty. *J Bone Joint Surg Br* 1993;75:869–71.
17. Enneking WF, Dunham W, Gebhardt MC, Malawar M, Pritchard DJ. A system for the functional evaluation of reconstructive procedures after surgical treatment of tumors of the musculoskeletal system. *Clin Orthop Relat Res* 1993;286:241–6. [CrossRef](#)
18. Issack PS, Kotwal SY, Lane JM. Management of metastatic bone disease of the acetabulum. *J Am Acad Orthop Surg* 2013;21:685–95. [CrossRef](#)